



# Endoscopic Coil Embolization for Refractory Intrahepatic Biliary Duct Leak

Barbara Dutra, MD, RD<sup>1</sup>, Macartney Welborn, MD<sup>1</sup>, Nirav C. Thosani, MD, MHA<sup>1</sup>, Ricardo Badillo, MD<sup>1</sup>, Tomas DaVee, MD, MSCI<sup>1</sup>, and Dimpal Bhakta, MD<sup>1</sup>

<sup>1</sup>Department of Internal Medicine, University of Texas Health Science Center at Houston, Houston, TX

## ABSTRACT

Bile leaks may be seen after blunt and penetrating trauma, as well as iatrogenic injury from surgical procedures. There are many articles on endoscopic treatment options for the management of biliary leaks, including sphincterotomy, endoscopic stent, or nasobiliary drain placement. Data, however, are scarce regarding the management of persistent biliary leaks after the initial intervention. We present a case of endoscopic coil embolization to treat a refractory bile leak after initial endoscopic sphincterotomy and stent placement in a patient with a grade IV liver laceration due to a gunshot wound.

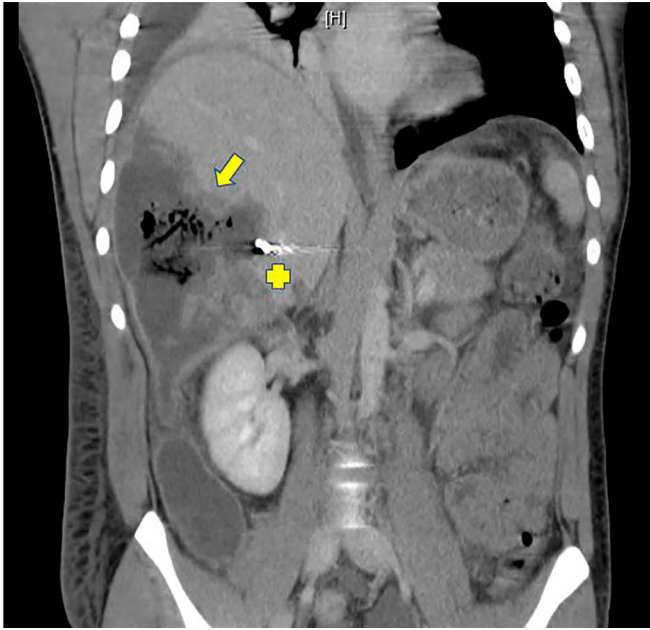
## INTRODUCTION

Biliary leaks are seen after abdominal trauma and surgical cholecystectomy.<sup>1–3</sup> The American Society for Gastrointestinal Endoscopy has recommended sphincterotomy, endoscopic stent, or nasobiliary drain placement as options for the management of postoperative bile leaks.<sup>4</sup> These modalities have been used as primary interventions for bile leaks from other etiologies.<sup>5–8</sup> Although successful treatment of biliary leaks with endoscopic intervention has been reported to be as high as 80%–100%, there is no consensus on the preferred endoscopic modality for managing biliary leaks.<sup>4</sup> Furthermore, data are scarce regarding the management of refractory biliary leaks. Given the risks associated with persistent bile leaks and lack of consensus in therapeutic choices, innovative endoscopic modalities have been pursued, including the use of endovascular coils for biliary leak embolization.<sup>9–15</sup> We present a case of endoscopically placed metallic coils for embolization of a refractory bile leak after penetrating abdominal trauma.

## CASE REPORT

A 21-year-old man without significant medical history presented after gunshot wounds to the right upper quadrant and right shoulder. On presentation, the patient was found to have radiographic evidence of grade IV liver laceration, pneumoperitoneum, right pneumothorax, and multiple rib fractures. His hospital course was complicated by persistent low-grade fevers, leukocytosis, and right upper quadrant pain. Imaging revealed a complex right hepatic lobe necrotic collection measuring 13 by 8 cm with internal gas bubble formation, for which interventional radiology placed a 22 French intrahepatic drain (Figure 1). Interventional gastroenterology was consulted because of concern for biliary leak on postoperative day 15 due to voluminous bile draining from the right intrahepatic drain.

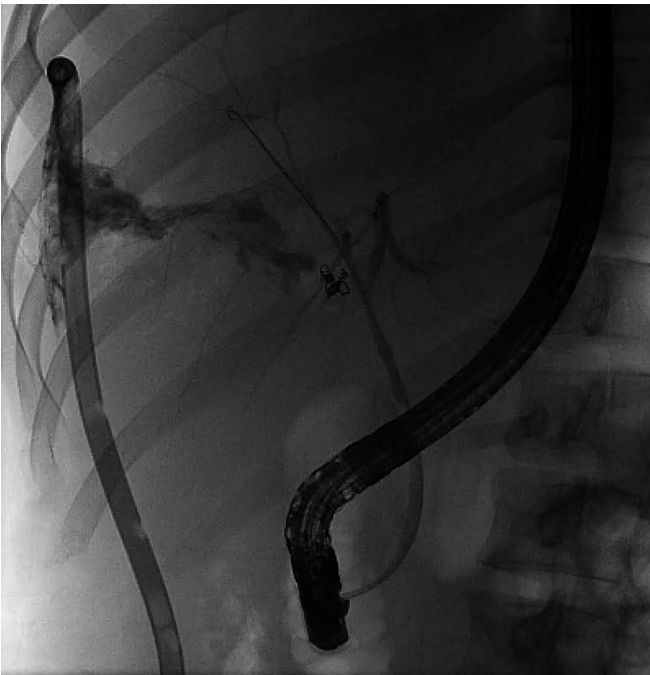Endoscopic retrograde cholangiopancreatography (ERCP) was recommended. Cholangiograms noted early contrast extravasation concerning for a high-grade bile leak from the right hepatic duct (RHD) just above the hilar bifurcation, for which biliary sphincterotomy was performed followed by the placement of an 8.5 French × 12 cm plastic biliary stent bridging across the leak for preferential drainage (Figure 2). The patient initially improved; however, 3 days after the ERCP, there was increased bilious output (900 mL/d) from the percutaneous intrahepatic drain. Therefore, the patient underwent a second ERCP. After stent removal, cholangiograms noted improvement of the RHD bile leak; however, a second high-grade bile leak was noted off the RHD intrahepatic branches (Figure 3). The RHD intrahepatic bile leak was not noted on the index ERCP. However, this was thought to be secondary to the high-grade nature of the primary bile leak noted at the RHD just above the hilar bifurcation. Given the length of the plastic biliary



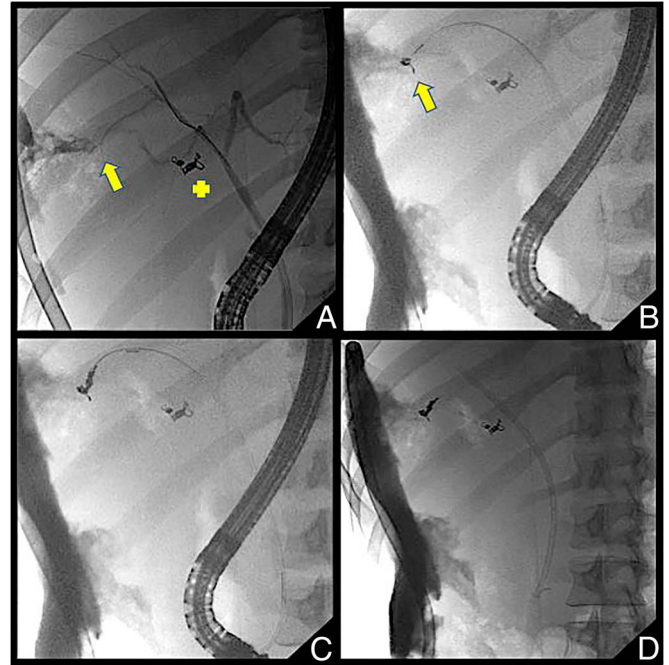
**Figure 1.** Complex right hepatic lobe necrotic collection measuring 13 by 8 cm with internal gas bubble formation (yellow arrow) with endovascular coils noted in branches of the hepatic artery (yellow cross).

stent placed at the index ERCP, this should have sufficed for preferential drainage for both leaks (RHD and RHD intrahepatic branch).

Owing to the peripheral location and refractory nature of the bile leak, biliary embolization was deemed necessary. Selective



**Figure 2.** Index endoscopic retrograde cholangiopancreatography with cholangiogram with high-grade bile leak from the right hepatic duct just above the bifurcation.

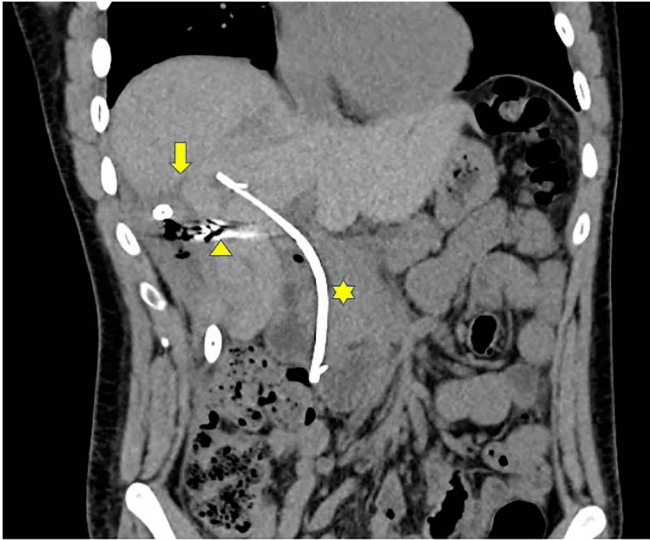


**Figure 3.** Sequential cholangiograms. (A) Bile leak from the right intrahepatic branch (yellow arrow), (B and C) placement of intra-ductal biliary coils at the bile leak site and (D) plastic biliary stent in place.

intrahepatic branch cannulation was performed with a long-wire sphincterotome (Cotton CannulaTome; Cook Medical) over an angle tipped 0.035 inches by a 450-cm guidewire (Jagwire; Boston Scientific). Sterile water was flushed through the sphincterotome after guidewire removal. Endobiliary coils (Tornado 0.035 inch, 5–3 mm; Cook Medical) were loaded and deployed by pushing them through the sphincterotome with the guidewire. A total of 3 endobiliary coils were deployed. The biliary stent was replaced (Figure 3). Biliious drain output markedly decreased. This improvement in biliious drain output was attributed to biliary coil embolization because the length of the plastic stent placed during the second ERCP was the same as the index procedure. Pain control and diet tolerance were achieved. He was discharged home with the right intrahepatic drain in position. Six weeks after biliary coil embolization, the patient continued to improve and reported low-volume drainage with improvement in the size of right lobe necrotic collection (Figure 4).

**DISCUSSION**

Bile leaks are classified as low-grade or high-grade based on cholangiograms performed during ERCP, with high-grade leaks identified before intrahepatic opacification vs low-grade leaks which require complete or near-complete filling of intrahepatic ducts to be identified.<sup>16,17</sup> Our patient had a refractory, high-grade intrahepatic leak, and the decision was made to embolize the duct with metallic coils. To the best of our knowledge, this is the third reported case of endobiliary coil placement alone, all of which lead to the resolution of a refractory biliary leak after initial failure at intervention.



**Figure 4.** Six weeks after endobiliary coil embolization showing right lobe necrotic collection and intrahepatic drain (yellow arrow), endobiliary coils (yellow arrowhead), and the biliary stent (yellow star).

For complex or refractory biliary leaks, innovative endoscopic modalities have been pursued. Kahaleh et al<sup>11</sup> described a series of 16 patients who failed to respond to conventional endoscopic management of bile leaks who subsequently underwent the placement of a covered self-expandable metal stent with 15 patients with eventual bile leak resolution. The advantage of metal stents is thought to be their larger diameter and longer patency; however, migration of the stent is an important concern as was noted in 2 patients and the overall cost-effectiveness.

Injection of N-butyl-2-cyanoacrylate (CYA), a tissue glue monomer that solidifies on contact with body fluids at neutral pH, is another such novel method. Seewald et al<sup>12</sup> described a series of 9 patients in which primary endoscopic treatment was unsuccessful who then underwent CYA occlusion during ERCP resulting in the successful resolution of bile leak in 7 patients. Schelhammer et al<sup>13</sup> first described the successful embolization of a cystic duct stump after cholecystectomy. In addition, Brown et al<sup>14</sup> reported the successful treatment of a persistent biliary leak from the cystic duct stump after cholecystectomy using percutaneous transabdominal access of the cystic duct and coil embolization. Kirtane et al<sup>15</sup> reported the first successful intrahepatic coil embolization for persistent biliary leak after abdominal trauma. Although the use of endoscopic coil embolization has also been performed in conjunction with CYA,<sup>16,18</sup> there has been at least 1 case report of cholangitis due to CYA and coil migration.<sup>16</sup> Coil embolization has also been accomplished successfully through a percutaneous approach.<sup>19,20</sup> At least 2 cases of complications because of coil migration with the percutaneous approach have been reported.<sup>21,22</sup>

Our case adds to limited data on the effective use of endobiliary coils for refractory bile leaks. This report was written with the intention of detailing a new method and instruments to be

considered in cases of refractory bile leaks after initial interventions have failed, including sphincterotomy and biliary stent placement for preferential biliary drainage. In addition, patients should have close postprocedure monitoring, given the potential complications associated with this technique, such as coil migration and cholangitis.

## DISCLOSURES

Author contributions: D. Bhakta and T. DaVee wrote and approved the article. B. Dutra and M. Welborn reviewed the literature. All authors edited and revised the article for intellectual content. D. Bhakta is the article guarantor.

Financial disclosure: None to report.

Informed consent was obtained for this case report.

Received September 28, 2020; Accepted September 22, 2021

## REFERENCES

- Hollands MJ, Little JM. Post-traumatic bile fistulae. *J Trauma*. 1991;31(1):117–20.
- Sugimoto K, Asari Y, Sakaguchi T, Owada T, Maekawa K. Endoscopic retrograde cholangiography in the nonsurgical management of blunt liver injury. *J Trauma*. 1993;35(2):192–9.
- Fong ZV, Pitt HA, Strasberg SM, et al. Diminished survival in patients with bile leak and ductal injury: Management strategy and outcomes. *J Am Coll Surg*. 2018;226(4):568–76.e1.
- Chathadi KV, Chandrasekhara V, Acosta RD, et al. The role of ERCP in benign disease of the biliary tract. *Gastrointest Endosc*. 2015;81:795–803.
- Abbas A, Sethi S, Brady P, Taunk P. Endoscopic management of post-cholecystectomy biliary leak: When and how? A nationwide study. *Gastrointest Endosc*. 2019;90:233.
- Spinn MP, Patel MK, Cotton BA, Lukens FJ. Successful endoscopic therapy of traumatic bile leaks. *Case Rep Gastroenterol*. 2013;7(1):56–62.
- Sharma BC, Mishra SR, Kumar R, Sarin SK. Endoscopic management of bile leaks after blunt abdominal trauma. *J Gastroenterol Hepatol*. 2009;24:757–61.
- Anand RJ, Ferrada PA, Darwin PE, Bochicchio GV, Scalea TM. Endoscopic retrograde cholangiopancreatography is an effective treatment for bile leak after severe liver trauma. *J Trauma*. 2011;71(2):480–5.
- Seewald S, Groth S, Sriram PV, Xikun H, Akaraviputh T, Mendoza G. Endoscopic treatment of biliary leakage with N-butyl-2 cyanoacrylate. *Gastrointest Endosc*. 2002;56:916–9.
- Krige J, Bornman P, Beningfield S et al. Endoscopic embolization of external biliary fistulae. *Br J Surg*. 1990;77(5):581–3.
- Kahaleh M, Sundaram V, Condrion SL, et al. Temporary placement of covered self-expandable metallic stents in patients with biliary leak: Mid-term evaluation of a pilot study. *Gastrointest Endosc*. 2007;66(1):52–9.
- Seewald S, Groth S, Sriram PV, et al. Endoscopic treatment of biliary leakage with n-butyl-2 cyanoacrylate. *Gastrointest Endosc*. 2002;56(6):916–9.
- Schelhammer F, Dahl SV, Heintges T, Fürst G. A multimodal approach in coil embolization of a bile leak following cholecystectomy. *Cardiovasc Intervent Radiol*. 2007;30(3):529–30.
- Brown CS, Sanogo M, Patel A, Schulman AR, Raghavendran K, Georgoff PE. Management of a persistent cystic duct stump leak following cholecystectomy with percutaneous transabdominal cystic duct stump embolization. *ACG Case Rep J*. 2019;6(8):e00162.
- Kirtane T, Goyal D, Rahimi E, Ertan A, Bynon JS, Thosani N. Refractory bile leak with biliocutaneous fistula treated by endobiliary coil placement. *Endoscopy*. 2017;49(12):1280–1.
- Wahaibi AA, Alnaamani K, Alkindi A, Qarshoubi IA. A novel endoscopic treatment of major bile duct leak. *Int J Surg Case Rep*. 2014;5(4):189–92.

17. Sandha GS, Bourke MJ, Haber GB, Kortan PP. Endoscopic therapy for bile leak based on a new classification: Results in 207 patients. *Gastrointest Endosc.* 2004;60(4):567–74.
18. Ganguly EK, Najarian KE, Vecchio JA, Moses PL. Endoscopic occlusion of cystic duct using N-butyl cyanoacrylate for postoperative bile leakage. *Dig Endosc.* 2010;22(4):348–50.
19. Hunt JA, Gallagher PJ, Heintze SWDF, Waugh R, Shiel AGR. Percutaneous microcoil embolization of intraperitoneal intrahepatic and extrahepatic biliary fistulas. *ANZ J Surg.* 1997;67:424–7.
20. Oliva VL, Nicolet V, Soulez G, et al. Bilomas developing after laparoscopic biliary surgery: Percutaneous management with embolization of biliary leaks. *J Vasc Interv Radiol.* 1997;8:469–73.
21. Sandroussi C, Lemech LD, Grunewald B, Abraham N, Gallagher PJ. Late complication following coil embolization of a biliary leak. *ANZ J Surg.* 2005;75:614–5.
22. Altun R, Yildirim AE, Ocal S, et al. Coil migration into the common bile duct as a cause of cholangitis. *Endoscopy.* 2011;43(Suppl 2):E33.

---

**Copyright:** © 2022 The Author(s). Published by Wolters Kluwer Health, Inc. on behalf of The American College of Gastroenterology. This is an open access article distributed under the Creative Commons Attribution License 4.0 (CCBY), which permits unrestricted use, distribution, and reproduction in any medium, provided the original work is properly cited.