

A comparative study of pedicle screw fixation in dorsolumbar spine by freehand versus image-assisted technique

A cadaveric study

Archit Agarwal, Vijendra Chauhan, Deepa Singh¹, Raghuvanshi Shailendra², Rajesh Maheshwari, Anil Juyal

ABSTRACT

Background: New and expensive technology such as three-dimensional computer assisted surgery is being used for pedicle screw fixation in dorsolumbar spine. Their availability, expenses and amount of radiation exposure are issues in a developing country. On the contrary, freehand technique of pedicle screw placement utilizes anatomic landmarks and tactile palpation without fluoroscopy or navigation to place pedicle screws. The purpose of this study was to analyze and compare the accuracy of freehand and image-assisted technique to place pedicle screws in the dorsolumbar spine of cadavers by an experienced surgeon and a resident. Evaluation was done using dissection of pedicle and computed tomography (CT) imaging.

Materials and Methods: Ten cadaveric dorsolumbar spines were exposed by a posterior approach. Titanium pedicle screws were inserted from D5 to L5 vertebrae by freehand and image-assisted technique on either side by an experienced surgeon and a resident. CT was obtained. A blinded radiologist reviewed the imaging. The spines were then dissected to do a macroscopic examination. Screws, having evidence of cortical perforation of more than 2 mm on CT, were considered to be a significant breach.

Results: A total of 260 pedicle screws were placed. The surgeon and the resident placed 130 screws each. Out of 130 screws, both of them placed 65 screws each by freehand and image-assisted technique each. The resident had a rate of 7.69% significant medial and 10.76% significant lateral breach with freehand technique while with image-assisted had a rate of 3.07% significant medial and 9.23% significant lateral breach. The expert surgeon had a rate of 6.15% significant medial and 1.53% significant lateral breach with freehand technique while with image-assisted had a rate of 3.07% significant medial and 6.15% significant lateral breach on CT evaluation.

Conclusion: Freehand technique is as good as the image-assisted technique. Under appropriate supervision, residents can safely learn to place freehand pedicle screws with an acceptable violation rate.

Key words: Dorsolumbar spine, freehand, pedicle screw, fluoroscopy

MeSH terms: Orthopaedic equipment, fluoroscopy, spine, bone screws

Departments of Orthopaedics, ¹Anatomy, and ²Radio-diagnosis and Imaging, Himalayan Institute of Medical Sciences, Swami Rama Himalayan University, Dehradun, Uttarakhand, India

Address for correspondence: Dr. Vijendra Chauhan, Himalayan Institute of Medical Sciences, Swami Rama Himalayan University, Dehradun - 248 140, Uttarakhand, India. E-mail: vchauhan16@yahoo.co.in

Access this article online	
Quick Response Code:	Website: www.ijoonline.com
	DOI: 10.4103/0019-5413.181779

INTRODUCTION

The placement of pedicle screws is independent of facet or laminar integrity and thus has been very useful in deformity correction, traumatic, degenerative

This is an open access article distributed under the terms of the Creative Commons Attribution-NonCommercial-ShareAlike 3.0 License, which allows others to remix, tweak, and build upon the work non-commercially, as long as the author is credited and the new creations are licensed under the identical terms.

For reprints contact: reprints@medknow.com

How to cite this article: Agarwal A, Chauhan V, Singh D, Shailendra R, Maheshwari R, Juyal A. A comparative study of pedicle screw fixation in dorsolumbar spine by freehand versus image-assisted technique: A cadaveric study. Indian J Orthop 2016;50:243-9.

and oncologic pathologies.¹ A variety of techniques are currently being used for the placement of thoracolumbar pedicle screws.² The new and expensive technology such as three-dimensional (3D) computer assisted surgery and computer-assisted fluoroscopy are not available in most places and requires high doses of radiation.³

The “freehand” technique for the placement of pedicle instrumentation relies completely on the use of visible as well as palpable anatomic landmarks for accurate pedicle screw placement. It is dependent on a clear exposition and identification of the posterior bony landmarks, including the lateral border of the pars interarticularis, the entire transverse process and the caudal and cephalad facet joints.¹

This study evaluates the safety and accuracy of pedicle screw placement with a freehand technique versus image-assisted technique in cadavers as done by residents and expert surgeon. A misplaced screw does not necessarily have clinical consequences. A low rate of clinically relevant complications has been found in the literature.⁴ Improvement in accuracy with the accumulation of experience for the resident was also evaluated.

MATERIALS AND METHODS

This observational cadaveric study was carried out over a period of 1 year after the approval by the Institutional Ethical Committee. Ten Indian cadavers from the Department of Anatomy were selected. The study was conducted by an orthopedic resident who, prior to study, had no experience at all with thoracic and lumbar pedicle screw placement and other, an experienced spine surgeon. Both surgeons placed pedicle screws by freehand and image-assisted techniques.

Operative procedure

Freehand technique

The cadavers were positioned prone and a standard posterior approach was used. The spinal level was confirmed clinically. Pedicle screws were inserted using the freehand technique and the point of entry was as described by the AO ASIF principles.⁵

Thoracic spine – the point of entry was just below the rim of the upper facet joint, 3 mm lateral to the center of the joint near the base of the transverse process. This screw was angled 7–10° toward the midline and 10–20° caudally.

Lumbar spine – the long axis of the pedicle pierced the lamina at the intersection of the two lines: A vertical line tangential to the lateral border of the superior articular process and a horizontal line bisecting the transverse process. Their point of intersection lay in the angle

between the superior articular process and the base of the transverse process. The screws were converged by 5° at the thoracolumbar junction and by 10–15° as one progressed from L2 to L5.

After the initial exposure, each step was repeated sequentially at each level to be instrumented. A small pilot hole was made with an awl. A curved pedicle probe was then introduced with the tip pointing laterally till a depth of approximately 20 mm. The probe was then completely removed, rotated until it was pointing medially, reinserted to its depth of 20 mm down the previously made track and subsequently medial until 30 mm. The sagittal trajectory of the probe was based upon the external anatomy of the posterior thoracic spine – the lamina and spinous processes. The medial – lateral angulation of the probe was based upon the level of the thoracic spine. The hole was then palpated with a ball-tipped probe. If no breach was palpated that was subsequently dilated with a straight pedicle probe (4.2 or a 5.2 mm depending upon the level), the hole was palpated again. The hole was then tapped 1 mm smaller than the proposed screw diameter. That was palpated again followed by screw insertion. One single fluoroscopic image was taken to confirm that the length of the very first screw was appropriate and that the level instrumented was correct. Further screw lengths were then based upon the length of the first screw and the subsequent levels of the thoracic spine and lumbar spine. Fluoroscopy was not used during actual screw placement, but it was used to confirm good placement after the screws had been placed.

Image assisted technique

C-arm (Allengers HF 59 R) multi-planar fluoroscopic imaging was used. Cadavers were placed prone on a radiolucent table. A standard midline incision was used and the posterior elements were exposed from D5 to L5. Image was kept parallel to the superior endplate with spinous process in the center between the pedicles. This ensured that the fluoroscopic beam was parallel to the desired pedicle in the sagittal plane. In order to reduce parallax, each spinal level was centered in the fluoroscopic beam. This enabled us to visualize the pedicle round with sharp cortical margins. The pilot pedicle entry hole was marked. Awl was then inserted into the pilot hole, parallel to the radiographic beam of the C-arm. Probe was then passed to check for any perforations. Length of the implant was measured with depth gauze and tapping was done if needed, followed by screw insertion. Placement was verified by taking a lateral view with the C-arm.

Evaluation of the pedicle screw insertion

The vertebral column from T5 to L5 was dissected out en-bloc. Scanning was done by a 64 slice computed tomography (CT) scanner SOMATOM Sensation, SIEMENS

(Germany). Axial and multi-planar reformatted images were used for evaluating the exact position of the implant. Radiologist was blinded regarding the technique used for screw insertion. Subsequently, dissection was done and sections were cut at each vertebral level as shown in Figure 1. Macroscopic examination was done at each level for damage to the pedicular cortex which was recorded as either medial or lateral. From the CT, violations were quantified in millimeters and graded as either: No violation, <2 mm violation and >2 mm violation. Violation of more than 2 mm medially or laterally was recorded as a significant breach [Figure 2]. Encroachment in the foramina was checked on the 3D reconstruction of images.

Data were analyzed by using Microsoft Excel 2010 and statistical software IBM SPSS version 22.0 (SSPS south asia pvt. Ltd. Banglore, India). Chi-square test (Fischer exact test) was used to check the proportion of significant medial and lateral violations by both the techniques for resident and expert surgeon. The specificity and sensitivity of CT was estimated. $P < 0.05$ was considered to be significant.

RESULTS

Pedicle screws were placed from D5 to L5 level in 10 cadavers. A total of 260 pedicle screws were inserted. The surgeon and the resident placed 130 screws each. Out of 130 screws, each of them placed 65 screws by freehand and 65 by image-assisted technique.

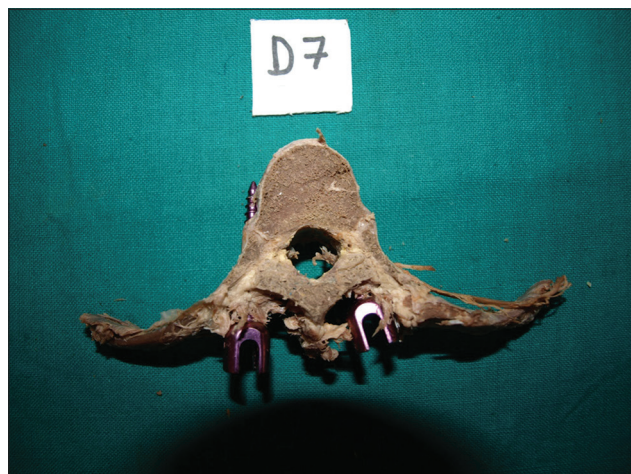

Figure 1: Lateral wall violation as seen on macroscopic examination

Results of macroscopic evaluation, total number of breach on CT evaluation and significant breach are shown in Table 1.

The difference between the significant medial violations by both techniques was found to be statistically insignificant for resident as well as expert surgeon.

Similarly, difference between the significant lateral violations by both techniques was found to be statistically insignificant for the resident as well as an expert surgeon [Table 2].

Sensitivity and specificity of CT scan to evaluate pedicle violation with respect to macroscopic evaluation was calculated. Sensitivity and specificity of CT was found to be 91.52% and 95.02%, respectively.

Significant breach rates for dorsal and lumbar spine were further calculated separately. In the dorsal spine, the resident had a significant medial and lateral breaches of 10 and 15% with a free hand technique. Whereas, with the image assisted technique, the significant medial and lateral breaches were 0 and 10% respectively. The expert surgeon had a significant medial and lateral breach of 10 and 2.5% respectively with the free hand technique; with image assisted technique the significant medial and lateral breaches were 5 and 7% respectively.

The significant breaches were less in the lumbar region. The resident had a rate of 4% each medial and lateral breaches with the free hand technique; with image assisted technique it was 8% each medially and laterally. On the

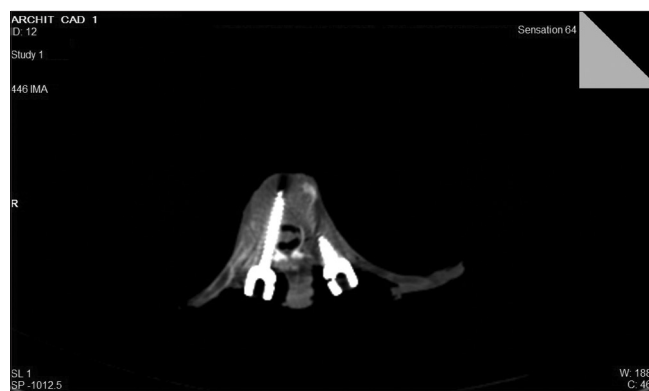

Figure 2: Computed tomography scan showing medial pedicle wall violation

Table 1: Results of macroscopic and CT evaluation

Findings	Resident				Expert surgeon			
	Freehand		Image-assisted		Freehand		Image-assisted	
	Medial	Lateral	Medial	Lateral	Medial	Lateral	Medial	Lateral
Macroscopic	3.07	18.46	0	16.92	3.07	7.69	0	18.46
Total number breach on CT	10.7	21.5	7.69	20	9.23	6.15	4.61	18.46
Significant breach on CT	7.69	10.76	3.07	9.23	6.15	1.53	3.07	6.15

All values in percentage. CT=Computed tomography

other hand the expert surgeon did not have any significant breach with the free hand technique; with image assisted technique there were 4% significant lateral breaches and none medially [Table 3].

The difference between the breach rates of lumbar and dorsal spine was evaluated using the Chi-square test. The *P* value by Chi square test for violations in both the techniques by surgeons (resident and expert surgeon) was statistically not significant [Table 4].

Number of correctly placed screws by resident in each cadaver was recorded [Table 5] and a bar diagram was made [Figure 3]. A trend line was drawn to see the improvement in accuracy with experience.

Number of images taken during image-assisted placement of pedicle screws at each level was recorded for resident and the expert surgeon. Mean of total number of images at each level was calculated. The average number of images per screw taken by the resident was 5.26 while the expert surgeon took 4.55.

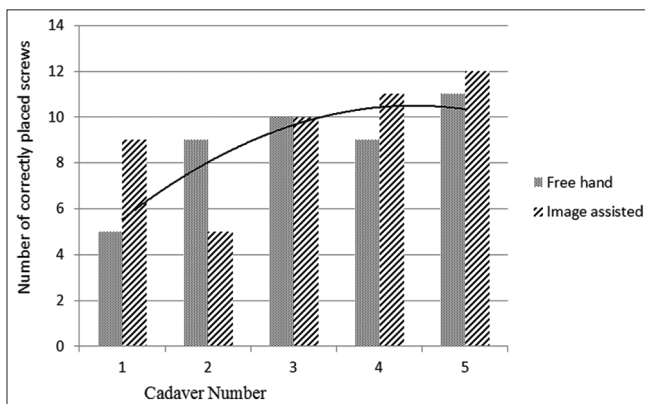


Figure 3: Bar diagram showing correctly placed screws by resident in each cadaver by freehand and image-assisted technique

Table 2: *P* values by Chi-square test for violations in both the techniques by surgeons

Surgeon	Violation	<i>P</i>
Resident	Medial	0.233
	Lateral	0.331
Expert surgeon	Medial	0.183
	Lateral	0.699

P<0.05=Significant

Table 3: Significant breach rates for dorsal and lumbar spine for both the surgeons in each technique

Spinal segment	Resident				Expert surgeon			
	Freehand		Image-assisted		Freehand		Image-assisted	
	Medial	Lateral	Medial	Lateral	Medial	Lateral	Medial	Lateral
Dorsal spine	10	15	0	10	10	2.5	5	7
Lumbar spine	4	4	8	8	0	0	0	4

All values in percentage

DISCUSSION

Spinal canal is not violated if a pedicle screw is completely contained within the pedicle. Pedicle screws that violate the medial pedicle cortex may increase the risk of neurologic deficit. Pedicle screws that violate the lateral pedicle cortex may increase the risk of vascular or visceral complications and loss of fixation if it occurs at the lower end of a construct.⁶ Different studies^{2,7-12} have come up with different violation rates with freehand technique [Table 6].

Wang *et al.* (2010)¹³ did a study on freehand thoracic pedicle screws placed by neurosurgery residents. On CT analysis, they were found to have 6% of medial cortical violation while 8.9% of lateral cortical violation. In our study, the orthopedic resident had a rate of 10.7% medial and 21.5% lateral violation.

Carbone *et al.* (2003)¹⁴ did a study to evaluate fluoroscopically assisted technique of thoracic pedicle screw insertion in unstable thoracic and thoracolumbar injuries. They had 10.3% of lateral and 2.4% of medial violation. 5.6% penetrated the vertebral body cortex. With the image-assisted technique in our study, the resident had a rate of 3.07% significant medial and 9.23% significant lateral breach. While the expert surgeon had a rate of 3.07% significant medial and 6.15% of significant lateral breach.

Misenhimer *et al.* (1989)¹⁵ documented that once the screw diameter exceeds the endosteal diameter of the pedicle or is >80% of the outer cortical diameter, then pedicle will adapt in one of the three ways: Pedicle expansion, pedicle cut out by screw threads, or pedicle fracture. In 72% of the cases, the fracture occurred laterally. At all levels, the medial cortex were 2–3 times thicker than the lateral cortex. Even in our study, there were 69.23% and 64% lateral wall violation by resident and expert surgeon, respectively. Similarly, Parker *et al.* (2011)¹² had 61.3% of lateral violations.

The acceptable degree of medial and lateral pedicle breach is still controversial as it has varied in different studies. Gertzbein and Robbins¹⁶ (1990) believed that “safe zone” of allowable medial encroachment was 4 mm in relation to the intradural contents. They found that a CT myelogram postoperatively demonstrated 2 mm of the epidural space

Table 4: P values by Chi-square test for violations in both the techniques by surgeons in dorsal and lumbar spine

Surgical technique	Resident	Expert surgeon
Freehand	0.08	0.06
Image-assisted	0.474	0.249

Table 5: Number of correctly placed screws by the resident in each cadaver

Cadaver number	Freehand (n=13)	Image-assisted (n=13)
1	5	9
2	9	5
3	10	10
4	9	11
5	11	12

Table 6: Violation rates with freehand technique in different series

Authors	Medial violation rate (%)	Lateral violation rate (%)
Karapinar <i>et al.</i> ²	1.87	2.81
Vaccaro <i>et al.</i> ⁷	23.33	17.71
Fisher <i>et al.</i> ⁸	13.4	17.9
Kim <i>et al.</i> ⁹	1.4 (senior spine surgeon) 2.4 (spine fellow)	7 (senior spine surgeon) 6.8 (spine fellow)
Lee <i>et al.</i> ¹⁰	1	2.3
Fennell <i>et al.</i> ¹¹	0	4.1
Parker <i>et al.</i> ¹²	0.57	1.07
Our study	9.23 (expert surgeon) 10.7 (resident)	6.15 (expert surgeon) 21.5 (resident)

with 2 mm of subarachnoid space from T10 to L4. They reported that 81% of screws were placed within 2 mm of medial border of pedicle and 6% had 4–8 mm of canal encroachment, out of which 2 of their patients developed temporary neurological complications. In another study, Belmont *et al.* (2002) are of the opinion that acceptable limits were 2 mm for medial wall penetration and 6 mm for lateral wall penetration.¹⁷ In our study, we considered 2 mm medially as well as laterally to be the safe limit. The resident had a rate of 7.69% medial and 10.76% lateral breach in which violation was more than 2 mm with freehand technique while with image-assisted 3.07% medial and 9.23% lateral breach of more than 2 mm. While the expert surgeon had a rate of 6.15% medial and 1.53% lateral breach in which violation was more than 2 mm with freehand technique while with image-assisted 3.07% medial and 6.15% lateral breach of more than 2 mm.

Upendra *et al.*¹⁸ (2008) carried out a study to find the reason for the gap between high rates of pedicle screw violation and low rates of reported complications. The literature confirmed that only a small percentage of the misplaced screws actually cause any complication and some misplacement can be acceptable both in terms of safety and their biomechanical strength. They gave a concept of acceptable screw placements. It helped to differentiate

between the benign marginal misplacements (acceptable) and those with dangerous placements of (unacceptable) screw. Reichle *et al.*¹⁹ (2002) in their study demonstrated that the thoracic pedicle screw which did not have a pure trabecular position and minimally perforated the pedicle wall was as good as the one which had pure trabecular position. For example, the in-out-in screws that had 70% strength of intrapedicular screws with <2 mm penetration through any of the cortices was considered acceptable.²⁰

Correct pedicle screw placement requires use of the correct entry point on the posterior vertebral cortex, followed in the correct direction to stay within the cortex of the pedicle. The optimal anatomic location for screw entry in the thoracic spine is much more difficult to determine in comparison to the lumbar level. The generally considered rule that craniocaudal center of the pedicle is at the midpoint of the transverse process is not always true because of anatomic variability in the thoracic spine. The cross-sectional morphology of a single thoracic pedicle is widely variable in the coronal plane unlike large ovoid lumbar pedicle.²¹

In the lumbar spine, pedicles show an even greater variation in their orientation in the horizontal plane from L5 through L1. However, because of the large transverse diameter of lumbar pedicles, a violation of the pedicle cortex is less likely to occur, even when the screw is not exactly aligned with the pedicle axis. On the contrary, in the thoracic spine, a slight mismatch between the axis of the pedicle and that of the screw results in a violation of the pedicle cortex except for the lower three thoracic vertebrae.⁸ This is evident even in our study as well. Parker *et al.*¹² too had statistically significant difference in number of breaches in the dorsal and lumbar spine.

In our study, we did not include deformed spine although it has been seen that accuracy of pedicle screw insertion by freehand technique is not significantly affected by it. Gruenberg *et al.*²² (2010) found no statistical difference in the rate of incorrectly placed screws in a scoliotic spine and a normal spine. Cui *et al.* (2012)²³ found that just with freehand technique, the accuracy of lumbar pedicle screws was high enough for the experienced spine surgeons to not use a navigation system for lumbar pedicle screw placement. Therefore, they concluded that intraoperative CT navigation was helpful in placing difficult pedicle screws as in thoracic and cervical spine during spinal deformity correction surgery. In another study by Samdani *et al.*, (2010)²⁴ on thoracic pedicle screws, placed by freehand technique in adolescent idiopathic scoliosis, there was 6.42% medial and 5.72% lateral violation. They concluded that these breaches did not cause any neurological injury. Modi *et al.* (2009)²⁵ used ideal pedicle entry point in thoracic spine by freehand technique in the treatment of adolescent idiopathic and

neuromuscular scoliosis. They had an acceptable accuracy rate of 93% and found it to be a safe and reliable method.

The conduct of the procedure becomes efficient enough for its use in humans with experience, first in a supervised manner and then in an unsupervised clinical setting.²⁶ Gonzalvo *et al.* (2009)²⁷ assessed learning curve of pedicle screw placement by a spine fellow who had no previous experience and found that the technique for an inexperienced spine fellow, reached after the placement of certain number of pedicle screws (80 pedicle screws in this study) correct. Gang *et al.*²⁸ (2012) did a study on learning curve of thoracic pedicle screw placement using freehand technique in scoliosis for an inexperienced surgeon. They concluded that for an apprentice, an experience of at least 60 screw placements under the guidance of an experienced spine surgeon was required to use the technique independently. Similarly, in our study, accuracy was achieved by the inexperienced surgeon after placing approximately 60 screws. Thus, it is seen that by repeating an activity the efficiency to accomplish increases with time.

The use of fluoroscopy and exposure to ionizing radiation is a major concern to the spine surgeon. Surgeons can protect themselves with eyewear, thyroid shields and lead aprons. However, the surgeon's hands are at the highest risk of radiation exposure. Rampersaud *et al.*³ (2000) evaluated the amount of radiation exposure to the surgeon's neck and dominant hand during placement of pedicle screws from T11 to S1 using lateral fluoroscopy only in a cadaveric model. Average fluoroscopy exposure time was 9.3s/screw. The average number of fluoroscopic images taken per screw was 8.5. They reported a significant increase in hand dose rate when placement of the screw was on the same side of the beam source as well as when a heavier cadaver was imaged. In our study, average number of images taken per screw by the resident was 5.26 while the expert surgeon took 4.55. On comparing their data to other studies, Rampersaud *et al.* found that spine surgeons had a 10–12 fold increase in hand radiation exposure compared with other musculoskeletal extremity procedures.

CONCLUSION

We conclude that freehand technique of pedicle screw placement when performed in a step-wise manner is an accurate, reliable, safe, less time-consuming, with lesser radiation and cost effective method of insertion to treat a variety of spinal disorders.

Under appropriate supervision, residents can safely learn to place freehand pedicle screws with an acceptable violation rate.

Financial support and sponsorship

Financial assistance from the Indian Council of Medical Research under section of grant for thesis in MD/MS program.

Conflicts of interest

There are no conflicts of interest.

REFERENCES

- Mattei TA, Meneses MS, Milano JB, Ramina R. "Free-hand" technique for thoracolumbar pedicle screw instrumentation: Critical appraisal of current "state-of-art". *Neurol India* 2009;57:715-21.
- Karapinar L, Erel N, Ozturk H, Altay T, Kaya A. Pedicle screw placement with a free hand technique in thoracolumbar spine: Is it safe? *J Spinal Disord Tech* 2008;21:63-7.
- Rampersaud YR, Foley KT, Shen AC, Williams S, Solomito M. Radiation exposure to the spine surgeon during fluoroscopically assisted pedicle screw insertion. *Spine (Phila Pa 1976)* 2000;25:2637-45.
- Gautschi OP, Schatlo B, Schaller K, Tessitore E. Clinically relevant complications related to pedicle screw placement in thoracolumbar surgery and their management: A literature review of 35,630 pedicle screws. *Neurosurg Focus* 2011;31:E8.
- Aebi M, Thalgott JS, Webb JK. *AO ASIF Principles in Spine Surgery*. 1st ed. India: AO Publishing; 2002.
- Ebraheim NA, Jabaly G, Xu R, Yeasting RA. Anatomic relations of the thoracic pedicle to the adjacent neural structures. *Spine (Phila Pa 1976)* 1997;22:1553-6.
- Vaccaro AR, Rizzolo SJ, Balderston RA, Allardyce TJ, Garfin SR, Dolinskas C, *et al.* Placement of pedicle screws in the thoracic spine. Part II: An anatomical and radiographic assessment. *J Bone Joint Surg Am* 1995;77:1200-6.
- Fisher CG, Sahajpal V, Keynan O, Boyd M, Graeb D, Bailey C, *et al.* Accuracy and safety of pedicle screw fixation in thoracic spine trauma. *J Neurosurg Spine* 2006;5:520-6.
- Kim YJ, Lenke LG, Bridwell KH, Cho YS, Riew KD. Free hand pedicle screw placement in the thoracic spine: Is it safe? *Spine (Phila Pa 1976)* 2004;29:333-42.
- Lee CH, Hyun SJ, Kim YJ, Kim KJ, Jahng TA, Kim HJ. Accuracy of free hand pedicle screw installation in the thoracic and lumbar spine by a young surgeon: An analysis of the first consecutive 306 screws using computed tomography. *Asian Spine J* 2014;8:237-43.
- Fennell VS, Palejwala S, Skoch J, Stidd DA, Baaj AA. Freehand thoracic pedicle screw technique using a uniform entry point and sagittal trajectory for all levels: Preliminary clinical experience. *J Neurosurg Spine* 2014;21:778-84.
- Parker SL, McGirt MJ, Farber SH, Amin AG, Rick AM, Suk I, *et al.* Accuracy of free-hand pedicle screws in the thoracic and lumbar spine: Analysis of 6816 consecutive screws. *Neurosurgery* 2011;68:170-8.
- Wang VY, Chin CT, Lu DC, Smith JS, Chou D. Free-hand thoracic pedicle screws placed by neurosurgery residents: A CT analysis. *Eur Spine J* 2010;19:821-7.
- Carbone JJ, Tortolani PJ, Quartararo LG. Fluoroscopically assisted pedicle screw fixation for thoracic and thoracolumbar injuries: Technique and short-term complications. *Spine (Phila Pa 1976)* 2003;28:91-7.

15. Misenhimer GR, Peek RD, Wiltse LL, Rothman SL, Widell EH Jr. Anatomic analysis of pedicle cortical and cancellous diameter as related to screw size. *Spine (Phila Pa 1976)* 1989;14:367-72.
16. Gertzbein SD, Robbins SE. Accuracy of pedicular screw placement *in vivo*. *Spine (Phila Pa 1976)* 1990;15:11-4.
17. Belmont PJ Jr, Klemme WR, Robinson M, Polly DW Jr. Accuracy of thoracic pedicle screws in patients with and without coronal plane spinal deformities. *Spine (Phila Pa 1976)* 2002;27:1558-66.
18. Upendra BN, Meena D, Chowdhury B, Ahmad A, Jayaswal A. Outcome-based classification for assessment of thoracic pedicular screw placement. *Spine (Phila Pa 1976)* 2008;33:384-90.
19. Reichle E, Morlock M, Sellenschloh K. Definition of pedicle malposition, primary stability and loosening characteristics of pedicle screws in relation to position: Spongy anchoring, cortical anchoring, perforation and malposition. *Orthopade* 2002;31:402-5.
20. Belmont PJ Jr, Klemme WR, Dhawan A, Polly DW Jr. *In vivo* accuracy of thoracic pedicle screws. *Spine (Phila Pa 1976)* 2001;26:2340-6.
21. Xing WH, Jia LS, Hio H, Yang X. Anatomic characteristics of thoracic pedicle rib complex for internal fixation. *J Clin Rehabil Tissue Eng Res* 2011;43:8063-8.
22. Gruenberg M, Petracchi M, Valacco M, Solá C. The influence of anatomy (normal versus scoliosis) on the free-hand placement of pedicle screws: Is misplacement more frequent in patients with anatomical deformity? *Evid Based Spine Care J* 2010;1:11-7.
23. Cui G, Wang Y, Kao TH, Zhang Y, Liu Z, Liu B, *et al.* Application of intraoperative computed tomography with or without navigation system in surgical correction of spinal deformity: A preliminary result of 59 consecutive human cases. *Spine (Phila Pa 1976)* 2012;37:891-900.
24. Samdani AF, Ranade A, Sciubba DM, Cahill PJ, Antonacci MD, Clements DH, *et al.* Accuracy of free-hand placement of thoracic pedicle screws in adolescent idiopathic scoliosis: How much of a difference does surgeon experience make? *Eur Spine J* 2010;19:91-5.
25. Modi H, Suh SW, Song HR, Yang JH. Accuracy of thoracic pedicle screw placement in scoliosis using the ideal pedicle entry point during the freehand technique. *Int Orthop* 2009;33:469-75.
26. Nowitzke AM. Assessment of the learning curve for lumbar microendoscopic discectomy. *Neurosurgery* 2005;56:755-62.
27. Gonzalvo A, Fitt G, Liew S, de la Harpe D, Turner P, Ton L, *et al.* The learning curve of pedicle screw placement: How many screws are enough? *Spine (Phila Pa 1976)* 2009;34:E761-5.
28. Gang C, Haibo L, Fancai L, Weishan C, Qixin C. Learning curve of thoracic pedicle screw placement using the free-hand technique in scoliosis: How many screws needed for an apprentice? *Eur Spine J* 2012;21:1151-6.

Author Help: Reference checking facility

The manuscript system (www.journalonweb.com) allows the authors to check and verify the accuracy and style of references. The tool checks the references with PubMed as per a predefined style. Authors are encouraged to use this facility, before submitting articles to the journal.

- The style as well as bibliographic elements should be 100% accurate, to help get the references verified from the system. Even a single spelling error or addition of issue number/month of publication will lead to an error when verifying the reference.
- Example of a correct style
Sheahan P, O'leary G, Lee G, Fitzgibbon J. Cystic cervical metastases: Incidence and diagnosis using fine needle aspiration biopsy. *Otolaryngol Head Neck Surg* 2002;127:294-8.
- Only the references from journals indexed in PubMed will be checked.
- Enter each reference in new line, without a serial number.
- Add up to a maximum of 15 references at a time.
- If the reference is correct for its bibliographic elements and punctuations, it will be shown as CORRECT and a link to the correct article in PubMed will be given.
- If any of the bibliographic elements are missing, incorrect or extra (such as issue number), it will be shown as INCORRECT and link to possible articles in PubMed will be given.