



## Case report

## Mechanical small bowel obstruction following a blunt abdominal trauma: A case report



Samira Zirak-Schmidt, Alaa El-Hussuna\*

Slagelse Hospital, Department of Gastrointestinal Surgery, Fælledvej 1, 4200 Slagelse, Denmark

## HIGHLIGHTS

- A 51-year old male with a history of previous abdominal surgery admitted after trauma.
- The patient had an open tibia fracture but uneventful diagnostic imaging.
- Explorative laparotomy 3 days after showed mechanical small bowel obstruction.
- Fibrous adhesion's band can cause intestinal obstruction following abdominal trauma.
- High index of suspicion in trauma patients with abdominal pain, vomiting and constipation.

## ARTICLE INFO

## Article history:

Received 15 April 2015

Received in revised form

31 August 2015

Accepted 23 September 2015

## Keywords:

Intestinal obstruction

Ileus

Abdominal trauma

Adhesions

Trauma CT

## ABSTRACT

**Introduction:** Intestinal obstruction following abdominal trauma has previously been described. However, in most reported cases pathological finding was intestinal stenosis.

**Presentation of the case:** A 51-year-old male was admitted after a motor vehicle accident. Initial focused abdominal sonogram for trauma and enhanced computerized tomography were normal, however there was a fracture of the tibia. Three days later, he complained of abdominal pain, constipation, and vomiting. An exploratory laparotomy showed bleeding from the omentum and mechanical small bowel obstruction due to a fibrous band.

**Discussion:** The patient had prior abdominal surgery, but clinical and radiological findings indicate that the impact of the motor vehicle accident initiated his condition either by causing rotation of a bowel segment around the fibrous band, or by formation of a fibrous band secondary to minimal bleeding from the omentum.

**Conclusion:** High index of suspicion of intestinal obstruction is mandatory in trauma patients presenting with complaints of abdominal pain, vomiting, and constipation despite uneventful CT scan.

© 2015 The Authors. Published by Elsevier Ltd on behalf of IJS Publishing Group Limited. This is an open access article under the CC BY-NC-ND license (<http://creativecommons.org/licenses/by-nc-nd/4.0/>).

## 1. Introduction

The most common causes of small bowel obstruction are adhesions, hernias, and malignancy. Clinical features include abdominal pain and distension, nausea, vomiting, and dehydration [1]. Intestinal obstruction following abdominal trauma has previously been described. However, in most reported cases pathological finding was intestinal stenosis [2,3]. To our knowledge, there are no previous reports on intestinal obstruction due to a single, definite fibrous band occurring few days after blunt abdominal trauma.

Prior abdominopelvic surgery is a well-known risk factor for adhesive intestinal obstruction [4,5]. This might be especially important in patients presenting with blunt abdominal trauma, as shown in the following case.

## 2. Presentation of the case

A 51-year-old male was admitted after a motor vehicle accident. The patient was the driver of a vehicle that had collided with another vehicle at a speed of about 80 km per hour. The patient had used his seat belt at the time of accident, and the event had activated airbags with an estimated deformation of about 30–50 cm in the vehicle. The patient presented with an open fracture of the left tibia, but was hemodynamically stable. There were no visible deformities or abrasions of the thorax or abdomen. Focused

\* Corresponding author.

E-mail addresses: [lg211@alumni.ku.dk](mailto:lg211@alumni.ku.dk) (S. Zirak-Schmidt), [alaanewemail@gmail.com](mailto:alaanewemail@gmail.com) (A. El-Hussuna).

Assessment with Sonography in Trauma (FAST) and Enhanced Computed Tomography (CT) scans were normal, apart from the tibial fracture. The patient was transferred to an orthopedic service for treatment of his tibial fracture.

His past medical history included a splenectomy 33 years ago, after a motocross accident, followed by exploratory laparotomy, through a midline incision, a month later due to mechanical intestinal obstruction. This was performed without any bowel resection, and the patient had a normal bowel function and was discharged shortly after operation. Furthermore, he had prostate cancer under active surveillance at the time of the current event. The patient was otherwise in good physical condition, and did not consume any prescription drugs.

Three days after admission, the patient complained of abdominal pain and constipation. His abdomen was distended and tender on palpation. This was initially interpreted as constipation due to use of opioid painkillers, and laxatives were prescribed. However, the condition worsened with several episodes of vomiting and increasing abdominal pain.

All vital parameters were within normal range. White blood cells count had increased from  $13.1$  to  $19 \times 10^9/l$ , and C-reactive protein from  $115$  to  $199$  mg/l over the course of 24 h. Acute CT scan of the abdomen is the standard investigation in the authors' department. This showed dilated small bowel with calibre change close to the ileocaecal region, and thus raising suspicion of mechanical small bowel obstruction (Fig. 1).

The necessity of surgical intervention was evident partly because of the failure of conservative treatment and partly to exclude serious abdominal injury. A laparoscopic approach was unfavorable due to the deteriorating condition of the patient and the high risk of conversion in regards to the patient's prior surgical procedures. An acute exploratory laparotomy was therefore performed. It showed that close to the ileocaecal valve a segment of 40 cm of the small bowel had rotated about  $180^\circ$  around a fibrous

band, causing necrosis of the mucosal layer. Parts of the omentum were found adherent to the abdominal wall with erosion and subsequent hemorrhage. The pelvis contained transudate with coagulated blood. There was no evidence of fecal contamination. The affected bowel segment was resected, and a primary side-to-side staple anastomosis was performed.

Histopathology of the resected segment showed necrosis of the mucosal and submucosal layers, consistent with acute inflammation with abundance of neutrophil granulocytes and fibrin coating. There were no signs of transmural perforation, polyps, or tumors.

The patient was discharged from the surgical department six days later with normal bowel function to an orthopedic service for final treatment of his tibial fracture. The latest follow-up nine months after the operation was uneventful.

A second review of the initial trauma CT concluded that a small amount of free fluid was found adjacent to the bowels with Hounsfield units consistent with blood. There were no indications of adhesions or small bowel obstruction.

### 3. Discussion

Pathophysiological causes of small bowel obstruction include adhesions, bowel perforation, mesenteric defect, intramural hemorrhage, and localized ischemia [3]. Intestinal obstruction after trauma is rare with only few reported cases [2,3,6,7]. In a majority of these cases, the pathology of obstruction was intestinal stenosis, mainly in the terminal ileum [2,3].

Symptoms of intestinal obstruction can occur years after a trauma event. This has been reported in patients with intestinal stenosis where localized ischemia after blunt abdominal trauma lead to healing with fibrosis of the abdominal wall [2]. Intra-abdominal bleeding was considered the mechanism behind intestinal obstruction after blunt abdominal trauma in another case report [7]. Previous abdominopelvic surgery is a known risk factor

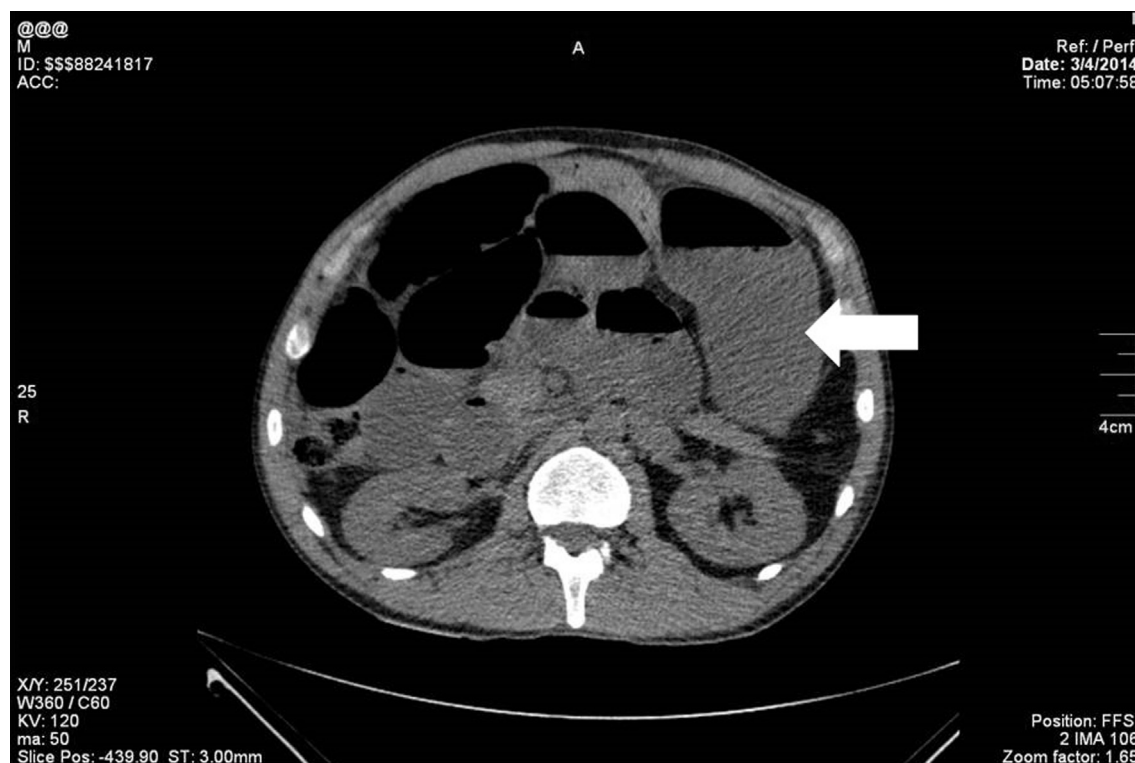


Fig. 1. Abdominal CT scan three days after motor vehicle trauma showing intestinal obstruction with a dilated calibre (white arrow) as well as normal small bowel segments.

for adhesive intestinal obstruction [4,5]. Barmparas et al. found, in a retrospective review, a significant incidence of in-hospital small bowel obstruction after exploratory laparotomy for trauma of which a fifth of the patients required surgical adhesiolysis, and in some cases resection of ischemic small bowel [8].

This patient had previous abdominal operations, which might be the cause of formation of the fibrous band. Differential diagnoses were cancer and metastases. However, the patient did not present with any symptoms of small bowel obstruction before this event. Either the blunt abdominal trauma caused bowel rotation around a pre-existing fibrous adhesion band, especially considering that the patient developed adhesions after his splenectomy, or possibly omental bleeding with consequent formation of a fibrous adhesion band was the cause of bowel obstruction. The question remains whether a fibrous band can be formed within four days. Prominence of postoperative adhesions is usually expected after 2–3 weeks [5], but formation of adhesions after trauma cannot be excluded.

Enhanced CT is generally considered to be sensitive in terms of demonstrating hemorrhaging, perforations, and organ damage. However, missed injuries do occur, as findings can be nonspecific and subtle [3], as demonstrated in this case.

To our knowledge, this is the first report on adhesive obstruction following trauma where a definite fibrous band was found. Hefny et al. described adhesive intestinal obstruction in a patient with no former abdominal surgery seven weeks after blunt abdominal trauma, without any single, definite fibrous band [6].

In our department, trauma guidelines dictate admission for at least 12 h for patients with no apparent injuries. This period cannot exclude intestinal obstruction such as in this case. Had the patient not presented with his tibial fracture, he would have most likely been discharged after 12 h. The question remains how to prevent a similar incident, and whether this can be achieved by altering our guidelines or simply increasing awareness of mechanical obstruction as a complication to abdominal trauma. Although this case report is limited by its nature, it has the potential of raising awareness and triggering future studies with the purpose of developing adequate guidelines for trauma patients.

#### 4. Conclusion

High index of suspicion of intestinal obstruction is needed in trauma patients presenting with complaints of abdominal pain, vomiting and constipation despite uneventful trauma CT scan.

Awareness of a patient's surgical history and appropriate monitoring for early and late complications is important. Moreover, patient-tailored approach is highly recommended for trauma

patients. Patients presenting with risk factors for complications after trauma should not be discharged early.

#### Contribution to medical literature

This case report adds another dimension to trauma literature. It raises the index of suspicion of intestinal obstruction after blunt abdominal trauma in patients with past history of exploratory laparotomy.

#### Ethical approval

None declared.

#### Funding

None declared.

#### Author contribution

Both authors contributed to idea, planning, data collection, writing the article and proof readings.

#### Conflicts of interest

None declared.

#### Guarantor

Alaa El-Hussuna.

#### References

- [1] P. Stonebridge, D. Smith, L. Duncan, A. Thompson (Eds.), *Surgery: an Oxford Core Text*, first ed., Oxford University Press, Oxford, 2006.
- [2] J. Gray, I. Garstin, Intestinal obstruction following blunt abdominal trauma, *Ulster Med. J.* 71 (2002) 139–141.
- [3] G. Kaban, R.A.B. Somani, J. Carter, Delayed presentation of small bowel injury after blunt abdominal trauma: a case report, *J. Trauma* 56 (2004) 1144–1145.
- [4] J.J. Duron, Pathologie occlusive postopératoire: 2. Occlusions mécaniques postopératoires du grêle par brides ou adhérences, *J. Chir.* 140 (2003) 325–334.
- [5] A.H. Maciver, M. MacCall, A.M.J. Shapiro, Intraabdominal adhesions: cellular mechanisms and strategies for prevention, *Int. J. Trauma* 9 (2011) 589–594.
- [6] A.F. Hefny, K. Lunsjo, S. Joshi, F.M. Abu-Zidan, Adhesive intestinal obstruction following blunt abdominal trauma, *Saudi Med. J.* 26 (2005) 1464–1467.
- [7] E.G. Lampert, J.G. Goodfellow, T.J. Wachowskil, Traumatic subserosal hemorrhage causing small bowel obstruction, *Ann. Surg.* 140 (5) (1954) 768–770.
- [8] G. Barmparas, B.C. Branco, B. Schnüringer, et al., In-hospital small bowel obstruction after exploratory laparotomy for trauma, *J. Trauma* 71 (2) (2011) 486–490.