



Abscess of the caudate lobe of the liver, a rare disease with a challenging management: a case report

Nasser A. Al Amer^a, Walid M. Abd El Maksoud^{b,✉}

^aConsultant of General Surgery, Aseer Central Hospital, Abha, Saudi Arabia;

^bAssistant Professor, General Surgery Department, Faculty of Medicine, King Khalid University, Abha, Saudi Arabia.

Received 18 April 2013, Revised 20 May 2013, Accepted 23 May 2013, Epub 10 August 2013

Abstract

We reported a rare case of abscess of the caudate lobe of the liver in a 60-year old man. We first tried computed tomography (CT) guided percutaneous drainage of the abscess but failed to eradicate the infection. Deterioration of the general condition of the patient necessitated open surgical drainage, which resulted in cure of the abscess. The peculiar anatomical location of caudate lobe abscess introduces a great challenge for the surgeon in planning the appropriate management and paucity of patients with caudate lobe abscess has led to lack of guidelines for management. The non-operative interventional radiology approach has become the therapeutic choice for pyogenic liver abscess, but is it applicable also for caudate lobe abscess?

Keywords: caudate lobe, percutaneous drainage, open surgical drainage, pyogenic liver abscess

INTRODUCTION

Pyogenic liver abscess remains a rare disease with a high risk of mortality, up to 19 %^[1,2]. Advances in imaging have allowed earlier diagnosis and a shift in management away from open drainage to percutaneous aspiration or tube (catheter) drainage^[3]. Although, a non-operative interventional radiology approach has become the therapeutic choice for pyogenic liver abscess, surgical treatment is still necessary in some cases, although its proper indications remain unclear. Many studies have discussed factors affecting the failure of percutaneous aspiration for pyogenic liver abscess^[4]. But, what about difficult location - is it one of these factors? Here, we report a case of a patient with an abscess of segment I of the liver that was ini-

tially unsuccessfully managed through percutaneous drainage, necessitating open drainage.

CASE REPORT

A 60-year-old man was admitted to the Emergency Department, Aseer Central Hospital, Abha, Saudi Arabia, because of epigastric pain for 3 days. He had diabetes mellitus and hypertension. He received open cholecystectomy and choledochoduodenostomy 20 years ago. The patient developed pyogenic liver abscess in segment VI of the liver one year ago, which was treated successfully by computed tomography (CT) guided percutaneous drainage, antibiotics and close follow-up with CT scan. On admission, the patient complained of epigastric pain, radiated to the right upper quadrant of the abdomen, for 3 days,

✉ Corresponding author: Dr. Walid M. Abd El Maksoud. Assistant Professor, General Surgery Department, Faculty of Medicine, King Khalid University, P.O.: 641. Abha. Saudi Arabia. Tel/Fax:

00966543128555, E-mail: dr.waleedmaksoud@gmail.com.

The authors reported no conflict of interests.

which was accompanied by nausea, vomiting, and fever with chills. He also noticed yellowish discoloration of his sclera with dark urine. On examination, the patient was in pain and jaundiced. His blood pressure was 147/78 mm Hg, with tachycardia (121 beats/min), and fever (38.7°C). Abdominal examination revealed tenderness and rebound tenderness in the epigastric and right hypochondrial regions. The rest of abdominal examination was unremarkable. No abdominal mass was felt. Bowel sounds were positive. Laboratory investigations are shown in **Table 1**. An abdominal CT scan was performed (**Fig. 1A**), which showed newly developed cavity lesion in segment I of the liver with air fluid level. The lesion measured 3 cm X 4.2 cm in size. Hypodense lesion of the previous abscess was in segment VI.

Initial resuscitation was done. The patient received piperacillin and tazobactam 4.5 g given intravenously (IV) ter in die, three times a day (TID) and metronidazole 500 mg IV TID. Endoscopic retrograde cholangio-pancreatography (ERCP) was done and revealed the status of intact choledocho-duodenostomy with prominent common bile duct. No communication between the biliary system and the abscess cavity was noticed in ERCP. Sphincterotomy was done. CT guided percutaneous drainage of the liver abscess was done and only 30 mL pus mixed with blood was aspirated and sent for culture and antibiotic sensitivity test, which revealed *E. coli* and *Klebsiella spp* that were sensitive to the antibiotics given. A pig tail draining catheter was inserted in the abscess cavity. For one day after percutaneous drainage, the catheter yielded traces of pus and the abdominal pain was slightly improved, but the patient still complained of nausea, vomiting and fever. Laboratory investigations showed improvement (**Table 1**). Three days later, the patient's general condition started to deteriorate, the

pain became more severe, and the leukocyte count was 16,000/mm³. Nothing was drained from the draining catheter during the previous 48 hours. Follow-up CT was done (**Fig. 1B**) and revealed the tip of the drainage tube had retracted away from the abscess cavity to the parenchyma. Abscess cavity increased in size and measured 5 cm X 5 cm in dimension. A minimal amount of subhepatic fluid collection was noted; minimal right pleural effusion was noticed. A second trial of CT guided percutaneous drainage failed to drain any pus from the abscess cavity.

Surgical drainage of the abscess was decided as the patient condition was further deteriorated and he became toxic. High risk consent was taken from the patient. During the operation, the area was found to be amalgamated with excessive adhesions around the area of the previous choledocho-duodenostomy. The duodenum was identified, and then the anastomosis between the duodenum and the common bile duct was used as a guide to reach the porta hepatis. Gentle blunt dissection was done with a finger beneath the liver; a bulge was felt and after careful dissection it was found to be the caudate lobe. A big needle was inserted into the caudate lobe, with aspiration of pus. The cavity in the caudate lobe was drained and about 40 mL pus came out. Irrigation of the cavity was then done, a big drain was inserted inside the cavity and another drain was put around the porta hepatis, and then the abdomen was closed.

The postoperative course showed dramatic improvement of the patient's general condition; abdominal pain improved, and fever subsided. The drain in the abscess cavity yielded 50 mL serosanguinous fluid during the first 72 hours. On the third postoperative day, the patient's laboratory investigations showed apparent improvement (**Table 1**). Follow-up CT was done on the 5th postoperative day (**Fig. 1C**) that re-

Table 1 Laboratory investigations of the patient during different stages of treatment.

Investigation	On admission	After ERCP and One day after Percutaneous drainage of abscess cavity	3 days after open drainage of abscess cavity	Normal range
WBCs (/mm ³)	21,000	13,000	8,000	4,000-11,000
Platelet (/mm ³)	137,000	175,000	235,000	150,000-400,000
Hemoglobin (g/dL)	15	14.6	15.1	13.5-17.5
INR	1.0	1.0	1.0	1.0
Serum glucose level (mg/dL)	339	208	154	70-110
Bilirubin				
Total (mg/dL)	8.9	2.4	0.6	0.1-1.0
Direct (mg/dL)	6.4	1.8	0.4	0.0-0.3
AST (U/L)	147	46	36	8-48
ALT (U/L)	289	175	61	7-55
Alkaline phosphatase (U/L)	126	110	67	45-115
GGT (U/L)	115	109	50	9-48
LDH (mmol/L)	22	27	23	122-222
Serum amylase (U/L)	253	134	67	25-125

WBCs: white blood cells; INR: international normalized ratio; AST: aspartate aminotransferase; ALT: alanine aminotransferase; GGT: gamma-glutamyltransferase; LDH: lactate dehydrogenase.

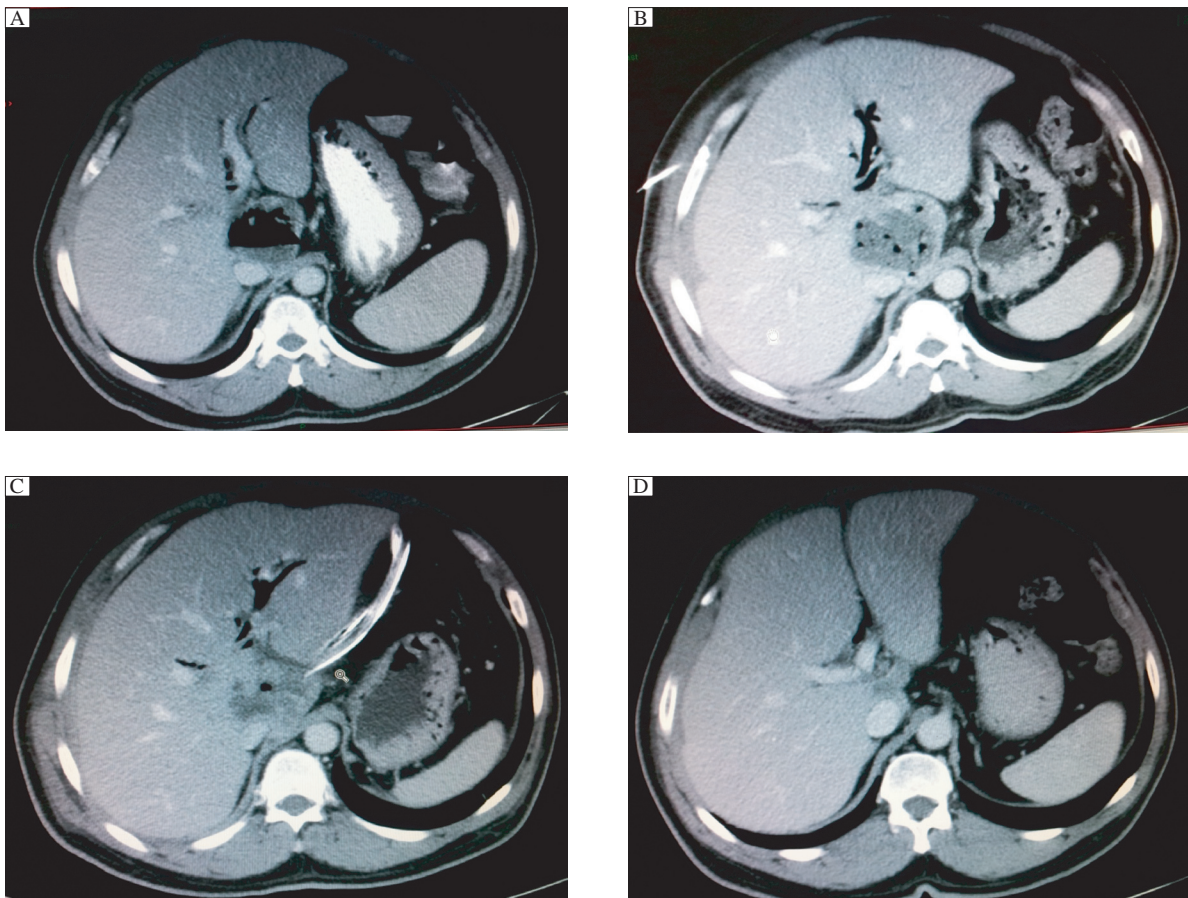


Fig. 1 CT results of the patient. A: CT on admission showing caudate lobe abscess; B: CT after percutaneous drainage showing persistence of caudate lobe abscess; C: CT on the fifth post operative day showing obvious regression of the abscess cavity; D: Follow up CT two weeks after surgical drainage showing significant regression of the abscess cavity.

vealed obvious regression of the abscess cavity, and the internal end of the drain was seen at the site of collection. No intra-abdominal free-fluid collection was seen. The drain was removed and the patient was discharged on the 9th day. Two weeks later, follow-up CT was done (**Fig. 1D**) and revealed significant regression of the abscess cavity. Follow-up of the patient after 3 and 6 months was uneventful.

DISCUSSION

Pyogenic liver abscess is a rare but life-threatening disease with the reported incidence ranging from 446 per 100,000 hospital admissions in some locations to 22 per 1,000,000 hospital admissions in others^[5]. Patients who are immunocompromised or diabetic are especially prone to developing pyogenic liver abscess; diabetic persons have a 3.6-fold increased risk for developing pyogenic liver abscess compared with the general population^[6].

The underlying pathophysiological mechanism for pyogenic liver abscess is a matter of controversy. Many authors suggest that spread of infection from

the biliary system is the most common cause^[7,8] while others suggest cryptogenic etiology^[9] or spread of infection via the hepatic portal vein to be the commonest causes^[10]. Among large-scale surveillance of patients with pyogenic liver abscess, the first 3 major possible etiologies are cryptogenic, diabetic, and biliary in origin. Cheng et al^[9]. speculated that a difference may exist in the pathophysiologic consequences or even the recurrence rates among these groups. They found that patients with underlying biliary disease are more prone to recurrence of liver abscess than those with diabetes or of cryptogenic origin. On the other hand, pyogenic liver abscess in diabetic patients tend to be polymicrobial. Patients with cryptogenic pyogenic liver abscess tend to have the lowest recurrence rate. Their source of infection can be attributed to a subclinical periodontal infection and is usually monomicrobial. In the reported case, we think that choledocho-duodenostomy performed 20 years ago is an obvious cause of the recurrent liver abscesses in this patient. As the patient was diabetic, the risk of recurrence of pyogenic liver abscess was

increased. Our findings support the results of Cheng et al.

Pyogenic liver abscess is usually located in the right lobe of the liver. This predilection for the right lobe can be explained anatomically. The right hepatic lobe receives blood from both the superior mesenteric and portal veins, whereas the left lobe receives inferior mesenteric and splenic drainage. It also contains a denser network of biliary canaliculi and, overall, accounts for more hepatic mass^[11]. Gram-negative aerobes are found to be the major abscess pathogens in pyogenic liver abscess. *E. coli* is the most common pathogen in most of European studies, but in Asian countries, other distributions are seen (with high proportions of *Klebsiella spp.*)^[12]. Both organisms were found to be the causative organisms in our case.

In the past, liver abscesses were considered a clear indication for surgical drainage. In recent years, a more conservative approach has been adopted and percutaneous drainage is now considered the procedure of choice with favorable outcomes^[1]. However, percutaneous therapy frequently fails, with rates ranging from 15% to 36%^[1,13]. The causes of failed pyogenic liver abscess treatment include multiple abscesses with multiple loculations, large abscesses (>5 cm) containing thick pus with necrotic tissue, issues directly linked to the drainage catheter (blockage, slippage, and chest empyema due to transpleural drainage), and technical difficulties associated with performing safe drainage. The ideal management of pyogenic liver abscess is still a controversy due to the rarity of this disease process. The literature regarding this topic mainly consists of case reports, small case series, and only a few large retrospective or case-controlled studies. As a result of the lack of sizable studies and lack of a true classification scheme for these abscesses, confusion continues regarding the optimal treatment strategies based on size and characteristics of these abscesses^[5].

There are three porta-hepatis in the liver. The first porta-hepatis denotes the hilum in a general sense; the second porta-hepatis denotes the confluence of major hepatic veins, and the third porta-hepatis denotes the segment of the retro-hepatic inferior vena cava with a series of short hepatic veins. The caudate lobe is, thus, surrounded by the three porta-hepatis, all of which consist of important and potentially dangerous structures in terms of performing any invasive or even minimally invasive procedure^[14]. In addition to the special location that puts a risk of failure for percutaneous drainage of caudate lobe abscess, there are growing opinions now recommending surgical drainage instead of percutaneous drainage as a first-

line treatment of pyogenic liver abscess, in general, in septic patients. This is based on the idea that delay or failure of adequate drainage would increase morbidity and mortality (published overall mortality rates between 6%-14%)^[15]. Recently, a low mortality rate of 4.5% has also been reported by Tan et al., who managed patients with pyogenic liver abscess > 5 cm in size by surgical drainage as first-line treatment^[2]. In our reported case, percutaneous drainage was decided first as the patient was not toxic. The procedure was difficult; later, the tube was dislodged from its accurate placement and failed to be re-inserted in a second attempt. As a result our patient was deteriorating, necessitating open drainage. The main difficulty we found was severe adhesions which resulted from previous biliary enteric anastomosis. Identification of the caudate lobe abscess was unexpectedly not difficult due to its tense consistency, and gentle finger dissection was the method to drain it. Sound understanding of the anatomy of this region protects the surgeon from injuring the surrounding important structures.

We think that more studies regarding caudate lobe abscess should be performed and collaboration among liver disease centers should be done to find an appropriate number of cases to provide guidelines for its management. There is a very important role for open surgical drainage for caudate lobe abscess, as the failure rate of percutaneous drainage seems high. The surgeon should not hesitate to take the decision of open drainage, as it is lifesaving, keeping in mind that identification of the abscess will not be difficult but injury of its surrounding structures may lead to greater morbidity or even mortality.

References

- [1] Alkofer B, Dufay C, Parienti JJ, Lepennec V, Dargere S, Chiche L. Are pyogenic liver abscesses still a surgical concern? A Western experience. *HPB Surg* 2012; 2012: 316013.
- [2] Tan YM, Chung AY, Chow PK, Cheow PC, Wong WK, Ooi LL, et al. An appraisal of surgical and percutaneous drainage for pyogenic liver abscesses larger than 5 cm *Ann Surg* 2005; 241: 485-90.
- [3] Jepsen P, Vilstrup H, Schonheyder HC, Sorensen HT.. A nationwide study of the incidence and 30-day mortality rate of pyogenic liver abscess in Denmark, 1977-2002. *Aliment Pharmacol Ther* 2005; 21: 1185-8.
- [4] Chung YF. Pyogenic liver abscess-predicting failure to improve outcome. *Neth J Med* 2008; 66: 183-4.
- [5] Hope WW, Vrochides DV, Newcomb WL, Mayo-Smith WW, Iannitti DA. Optimal treatment of hepatic abscess. *Am Surg* 2008; 74: 178-82.
- [6] Thomsen RW, Jepsen P, Sorensen HT. Diabetes mellitus and pyogenic liver abscess: risk and prognosis. *Clin In-*

- fect Dis* 2007; 44: 1194-201.
- [7] Wong WM, Wong BC, Hui CK, Ng M, Lai KC, Tso WK, et al. Pyogenic liver abscess: retrospective analysis of 80 cases over a 10-year period. *J Gastroenterol Hepatol* 2002; 17: 1001-7.
- [8] Malik AA, Bari SU, Rouf KA, Wani KA. Pyogenic liver abscess: Changing patterns in approach. *World J Gastrointest Surg* 2010; 2: 395-401.
- [9] Cheng HC, Chang WL, Chen WY, Kao AW, Chuang CH, Sheu BS. Long-term outcome of pyogenic liver abscess: factors related with abscess recurrence. *J Clin Gastroenterol* 2008; 42: 1110-5.
- [10] Mohsen AH, Green ST, Read RC, McKendrick MW. Liver abscess in adults : ten years experience in a UK centre. *QJM* 2002; 95: 797-802.
- [11] Albuquerque A, Magro F, Rodrigues S, Lopes S, Pereira P, Melo RB, et al. Liver abscess of the caudate lobe due to *Staphylococcus aureus* in an ulcerative colitis patient: first case report. *J Crohns Colitis* 2011; 5: 360-3.
- [12] Rahimian J, Wilson T, Oram V, Holzman RS. Pyogenic liver abscess: recent trends in etiology and mortality. *Clin Infect Dis* 2004; 39: 1654-9.
- [13] Chen SC, Tsai SJ, Chen CH, Huang CC, Lin DB, Wang PH, et al. Predictors of mortality in patients with pyogenic liver abscess. *Neth J Med* 2008; 66: 196-203.
- [14] Wen ZQ, Yan YQ, Yang JM, Wu MC. Precautions in caudate lobe resection: report of 11 cases. *World J Gastroenterol* 2008; 14: 2767-70.
- [15] Yu SC, Ho SS, Lau WY, Yeung DT, Yuen EH, Lee PS, Metreweli C. Treatment of pyogenic liver abscess: prospective randomized comparison of catheter drainage and needle aspiration. *Hepatology* 2004; 39: 932-8.

CLINICAL TRIAL REGISTRATION

The *Journal* requires investigators to register their clinical trials in a public trials registry for publication of reports of clinical trials in the *Journal*. Information on requirements and acceptable registries is available at www.icmje.org/faq_clinical.html.