

Bacteremia caused by *Eggerthella lenta* in an elderly man with a gastrointestinal malignancy: A case report

Davie Wong MD¹, Fred Aoki MD², Ethan Rubinstein MD²

D Wong, F Aoki, E Rubinstein. Bacteremia caused by *Eggerthella lenta* in an elderly man with a gastrointestinal malignancy: A case report. *Can J Infect Dis Med Microbiol* 2014;25(5):e85-86.

Eggerthella lenta is an anaerobic, Gram-positive bacillus commonly found in the human digestive tract. Occasionally, it can cause life-threatening infections. Bacteremia due to this organism is always clinically significant and is associated with gastrointestinal diseases and states of immune suppression. The authors report a case involving an elderly man with a newly diagnosed gastrointestinal malignancy who developed bacteremia caused by *E lenta*, treated successfully using empirical therapy with vancomycin and piperacillin-tazobactam, followed by directed therapy with metronidazole once the identity and antibiotic susceptibility of the organism was established. The present case reinforces the connection between *E lenta* bacteremia with gastrointestinal malignancy and highlights the importance of searching for a source of bacteremia due to this organism.

Key Words: Bacteremia; *Eggerthella lenta*; Gastrointestinal; Immunocompromised; Malignancy

CASE PRESENTATION

An 86-year-old man was admitted to hospital with dehydration following an acute diarrheal illness, presumably due to a food-borne disease, acute kidney injury secondary to dehydration and rhabdomyolysis caused by prolonged bed rest of four days' duration. His medical history was significant for type 2 diabetes mellitus, hypertension, gout and stage IV chronic kidney disease, the cause of which was not known. After rehydration with intravenous (IV) fluids, his condition improved. On day 3 of admission, his temperature rose transiently to 38°C. He developed swelling, erythema and tenderness of the first metatarsophalangeal joints bilaterally and a diagnosis of an acute flare of gouty arthritis was made. After initiation of colchicine, the inflammation of his metatarsophalangeal joints improved and he defervesced within 24 h. On day 7 of admission, he developed fevers, chills, rigors and dyspnea.

On examination, he appeared unwell and was experiencing intense rigors. His temperature was 38.6°C, heart rate 110 beats/min and regular, blood pressure 144/67 mmHg, respiratory rate 22 breaths/min and oxygen saturation 98% on room air. Respiratory examination revealed only diffuse wheezing. Inflammation of the first metatarsophalangeal joints bilaterally had improved from the previous examination. Oral hygiene was unremarkable. The rest of his physical examination was normal. A possible nosocomial pneumonia was diagnosed and therapy with IV vancomycin and piperacillin-tazobactam was initiated.

Laboratory investigations revealed an elevated white blood cell count of $17.6 \times 10^9/L$ (neutrophil count $10.22 \times 10^9/L$), a microcytic anemia (hemoglobin level 102 g/L), and persistently elevated cholestatic liver enzyme levels (gamma glutamyltransferase 170 U/L [normal

Une bactériémie causée par l'*Eggerthella lenta* chez un homme âgé atteint d'un cancer gastro-intestinal : un rapport de cas

L'*Eggerthella lenta* est un bacille anaérobique à Gram positif présent dans le tube digestif humain. Il cause parfois des infections au potentiel mortel. La bactériémie attribuable à cet organisme est toujours grave sur le plan clinique et s'associe à des maladies gastro-intestinales et à des états immunosuppresseurs. Les auteurs présentent le cas d'un homme âgé atteint d'un cancer gastro-intestinal diagnostiqué qui a souffert d'une bactériémie causée par l'*E lenta* et qui a reçu un traitement empirique fructueux à la vancomycine et à la pipéracilline-tazobactam, suivi d'une thérapie dirigée au métronidazole une fois l'organisme connu et la susceptibilité à l'organisme établie. Ce cas renforce le lien entre la bactériémie causée par l'*E lenta* et le cancer gastro-intestinal et fait ressortir l'importance d'en chercher la source.

5 U/L to 29 U/L], alkaline phosphatase 233 U/L [normal <120 U/L] and total bilirubin 62 µmol/L [normal 3 µmol/L to 22 µmol/L]). A chest x-ray demonstrated only atelectasis in the left lower lobe. Urinalysis and urine culture were unremarkable. Serial blood cultures and a computed tomography scan of his abdomen were performed.

DIAGNOSIS

Blood cultures from day 3 of admission were negative. By 72 h, a single anaerobic blood culture bottle from day 7 of admission grew small, Gram-positive bacilli subsequently identified as *Eggerthella lenta* by VITEK 2 ANC identification card (bioMérieux Canada Inc, Canada). Etest (bioMérieux Canada Inc) results demonstrated sensitivity to clindamycin (minimum inhibitory concentration [MIC] 0.125 µg/mL) and metronidazole (MIC 0.25 µg/mL), but resistance to penicillin (MIC 4 µg/mL). A computed tomography scan of the patient's abdomen revealed mass-like thickening of the second portion of the duodenum. Histological examination of biopsy specimens obtained from the abnormal duodenum via esophagogastroduodenoscopy demonstrated poorly differentiated invasive carcinoma (Figure 1).

DISCUSSION

E lenta is an anaerobic, nonsporulating, nonmotile, Gram-positive bacillus commonly found in the flora of the healthy human digestive tract (1,2). Formerly a *Eubacterium* species, it has been reclassified under the bacterial genus *Actinobacteria* in the family *Coriobacteriaceae* (1,2). Microbiologically, it is catalase positive (1), indole negative (3) and occurs singly or in short chains (4). It derives its name from Arnold Eggerth, who initially described the bacterium in 1935 (2,4).

¹Internal Medicine; ²Section of Infectious Diseases, Department of Internal Medicine, University of Manitoba, Winnipeg, Manitoba

Correspondence: Dr Davie Wong, 139 Brunet Drive, Winnipeg, Manitoba R2J 0A1. Telephone 204-229-1569, e-mail davie1985@hotmail.com



This open-access article is distributed under the terms of the Creative Commons Attribution Non-Commercial License (CC BY-NC) (<http://creativecommons.org/licenses/by-nc/4.0/>), which permits reuse, distribution and reproduction of the article, provided that the original work is properly cited and the reuse is restricted to noncommercial purposes. For commercial reuse, contact support@pulsus.com

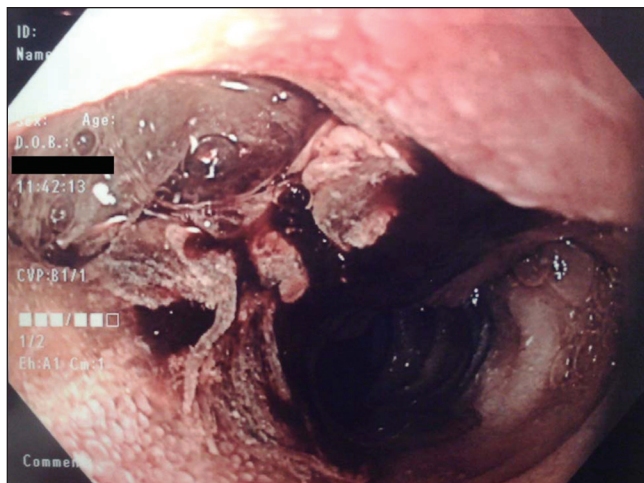


Figure 1) Upper endoscopy demonstrating an ulcerating mass in the patient's duodenum

Historically, the organism was difficult to culture and identify due to its slow growth and labour-intensive methods of speciation. Recently, however, the emergence of 16S ribosomal RNA gene sequencing has led to more rapid and accurate identification (3).

Bacteremia associated with this organism is polymicrobial in up to 50% of cases, and patients typically present with fever, hypotension and leukocytosis (1,5). *E. lenta* has been isolated from blood, abscesses, wounds, skin ulcers, obstetric and genitourinary tract infections, and intra-abdominal infections (1,6). Risk factors include states of impaired immune function (steroid use, recent chemotherapy, end-stage renal disease and diabetes), malignancies and gastrointestinal diseases such as ulcerative colitis and Crohn disease (2,4,7). Normally, a healthy duodenum is free of obligate anaerobes owing to intrinsic antimicrobial defense mechanisms including low pH, proteolytic enzymes, presence of oxygen and rapid peristalsis (8).

Bacteremia due to this organism is always clinically significant given its high mortality rate, and warrants a prompt search for a source. The 30-day all-cause mortality rate was 36% (nine of 25) in a retrospective review of patients with decubitus ulcers, diabetes

mellitus and solid-tumour malignancies whose source of bacteremia was primarily abdominal (5). Seventy-eight percent (seven of nine) of patients who died and 81% (13 of 16) of patients who survived had received appropriate anaerobic coverage; antibiotic data were not available for the remaining two patients who died. Risk factors that were independently associated with death were absence of fever and admission to the intensive care unit (5). Lee et al (7) reported a lower 30-day all-cause mortality rate of 14% (one of seven) in patients with end-stage renal disease, malignancy and a compromised immune system. The choice of antimicrobial was not reported for the single patient who died. Although clinical guidelines are lacking, previous case reports have reported successful treatment using monotherapy with a broad-spectrum β -lactam, such as a carbapenem or piperacillin-tazobactam, or combination therapy with metronidazole plus a β -lactam (2-5).

In our patient, infection presented with high fevers and leukocytosis. His risk factors included a gastrointestinal malignancy, diabetes mellitus and chronic kidney disease. The most likely explanation for his bacteremia was translocation of the organism from the gastrointestinal tract due to disrupted mucosal integrity caused by the small bowel malignancy. Identification of the bacterium was performed using Clinical and Laboratory Standards Institute-approved reference methods (9). The antibiogram of the isolate was concordant with that described in the literature, except the reported rate of clindamycin resistance was high (63%) (7,10).

Our patient received three days of IV vancomycin and piperacillin-tazobactam, with prompt resolution of his fever, symptoms and leukocytosis. Afterwards, a 10-day course of IV metronidazole was completed on the recommendation of the infectious diseases service. Given his poor performance status and medical comorbidities, the patient was deemed too high a risk for chemotherapy or surgery; therefore, he was transitioned to palliative care.

The present case report reinforces the association between *E. lenta* infection with malignancy, diabetes mellitus and chronic kidney disease, and highlights the importance of searching for a source of bacteremia due to this organism.

INSTITUTION: This case report originated from the University of Manitoba (Winnipeg, Manitoba).

REFERENCES

- Könönen E. Anaerobic Gram-positive nonsporulating bacilli. In: Mandell GL, Bennett JE, Dolin R, eds. Principles and Practice of Infectious Diseases, 7th edn. Philadelphia: Elsevier, 2010:3125-7.
- Salameh A, Klotz SA, Zangeneh TT. Disseminated infection caused by *Eggerthella lenta* in a previously healthy young man: A case report. *Case Rep Infect Dis* 2012;2012:517637.
- Elias RM, Khoo SY, Pupaibool J, et al. Multiple pyogenic liver abscesses caused by *Eggerthella lenta* treated with ertapenem: A case report. *Case Rep Med* 2012;2012:718130.
- Thota VR, Dacha S, Natarajan A, et al. *Eggerthella lenta* bacteremia in a Crohn's disease patient after ileocecal resection. *Future Microbiol* 2011;6:595-7.
- Venugopal AA, Szpunar S, Johnson LB. Risk and prognostic factors among patients with bacteremia due to *Eggerthella lenta*. *Anaerobe* 2012;18:475-8.
- Liderot K, Larsson M, Borang S, et al. Polymicrobial bloodstream infection with *Eggerthella lenta* and *Desulfovibrio desulfuricans*. *J Clin Microbiol* 2010;48:3810-2.
- Lee MR, Huang YT, Liao CH, et al. Clinical and microbiological characteristics of bacteremia caused by *Eggerthella*, *Paraeggerthella*, and *Eubacterium* species at a university hospital in Taiwan from 2001 to 2010. *J Clin Microbiol* 2012;50:2053-5.
- Wilson M. The indigenous microbiota of the gastrointestinal tract. In: Wilson M, ed. Bacteriology of Humans: An Ecological Perspective. Hoboken: Wiley-Blackwell, 2008:277-8.
- Clinical Laboratory Standards Institute. Methods for Antimicrobial Susceptibility Testing of Anaerobic Bacteria; Approved Standard – 8th edn. CLSI document M11-A8. Wayne: Clinical and Laboratory Standards Institute; 2012.
- Gardiner BJ, Korman TM, Junckerstorff RK. *Eggerthella lenta* bacteremia complicated by spondylodiscitis, psoas abscess and meningitis. *J Clin Microbiol* 2014;52:1278-80.