

Triorchidism: presenting as undescended testis in a case of indirect inguinal hernia

Ajay H. Bhandarwar, Saurabh S. Gandhi, Chintan B. Patel, Amol N. Wagh, Virendra Gawli, Nimesh A. Jain

Division of Gastrointestinal, Hepatobiliary & Pancreatic, Minimal Access, Bariatric & Metabolic Surgery, Department of Surgery, Grant Government Medical College & Sir J.J. Group of Hospitals, Byculla, Mumbai, Maharashtra, India

Abstract

Triorchidism is the commonest variety of polyorchidism, an entity with more than two testis is an extremely rare congenital anomaly of the testis. Although excision of the abnormal testis is a safer alternative proposed, recent literature suggests more conservative approach in normal testes with watchful regular follow up to screen for malignancy. This case presented as a left inguinal swelling diagnosed as indirect left inguinal hernia. The left side testis was of smaller size (about half) with normal sperm count, morphology and motility. Intraoperatively indirect inguinal hernia was noted with supernumerary testis at deep ring in addition to normal left testis in left scrotal sac. The ectopic testis were small (2.5×2.5×1 cm) lacking epididymis and with short vas deferens. An evident normal semen analysis and varied anatomy, the decision for orchidectomy of ectopic testis was taken. The histopathological finding was consistent with arrest in germ cell development.

Introduction

Polyorchidism is the incidence of more than two testes.¹ The finding is an extremely rare congenital anomaly, but well documented in literature. The first case was been reported in 1880.² There are about 190 cases reported with higher prevalence of diagnosis in pediatric age group.³ With first histological confirmation in 1895 there are about 140 histologically proven cases.^{2,4} Polyorchidism can clinically have varied presentations as inguinal swelling, cryptorchidism, testicular torsion, hydrocele and varicocele with majority being asymptomatic. The most common form of polyorchidism is triorchidism (or 3 testes) with left sided predominance (65%) over the right.¹ A higher tendency for malignant transformation in non-functional

testis necessitates the radiological and functional assessment of polyorchid testes. We hereby report a case of 24-year old male with left side super-numerary non-functional testis, presenting as left sided inguinal hernia.

Case Report

A 24-year old young male came with reducible swelling in left inguinal region since 4 years without associated history of trauma or pain. On detailed local examination, a reducible swelling in the left inguinal region with positive cough impulse and positive deep ring occlusion test was noted. The right testis was normal in size, whereas left testis was smaller in size 3×3×2 cm (about 50%) compared to the right side. The vas deferens on both sides was distinct and normally palpable. Sensation over testis was normal without any significant inguinal lymphadenopathy.

The patient was investigated for surgical fitness. Semen analysis showed normal sperm count, morphology and motility. The patient was operated for left inguinal hernioplasty. Intraoperative findings of indirect inguinal hernia sac was present with small undescended super-numerary testis of size 2.5×2.5×1 cm at the deep inguinal ring (Figure 1) having short vas deferens and a normally located left testis with epididymis and vas deferens in the scrotal sac. Due to anomalous anatomy of super-numerary inguinal testis, orchidectomy with excision of indirect sac was performed. The normally located left testis in scrotal sac was preserved. Patient recovered uneventfully. The histopathological examination of the specimen reported thickened capsule of testis and tubules with arrest of development of the germ cells (Figure 2). A prominence of Sertoli and Leydig cells along with hyalinised, thickened basement membrane of seminiferous tubules and dense intervening stroma was found. A follow up tumor marker assay showed negative study, which can likely be present in burned out tumor in spite of negative histology.

Discussion

Polyorchidism presents itself more commonly in the 2nd to 3rd decade, with approximately 50% of cases reported between 15 to 25 years of age.⁵ The exact etiology is unknown. The common presentations of polyorchidism manifests as maldescent (40%), hernia (30%), torsion (15%), hydrocele (9%), malignancy (6%),^{5,6} infertility and epididymitis.¹

Table 1 describes the Bergholz classification of polyorchidism.⁵

The testis takes its origin from the medial

Correspondence: Ajay H. Bhandarwar, Division of Gastrointestinal, Hepatobiliary & Pancreatic, Minimal Access, Bariatric & Metabolic Surgery, Department of Surgery, Grant Government Medical College & Sir J.J. Group of Hospitals, Byculla, Mumbai - 400008, Maharashtra, India. E-mail: abhandarwar@gmail.com

Key words: Undescended; triorchidism; polyorchidism; ectopic.

Conflict of interest: the authors declare no potential conflict of interest.

Received for publication: 8 May 2015.

Revision received: 24 March 2016.

Accepted for publication: 25 March 2016.

This work is licensed under a Creative Commons Attribution NonCommercial 4.0 License (CC BY-NC 4.0).

©Copyright A.H. Bhandarwar et al., 2016
Licensee PAGEPress, Italy
Clinics and Practice 2016; 6:786
doi:10.4081/cp.2016.786

part of primitive genital ridge while the epididymis and vas deferens develop from the Wolffian duct. The exact etiology of polyorchidism is unclear, however accidental division of genital ridge before 8 week of gestation could be a possible cause.² There are theories proposing the probable presence of multiple testes first being duplication of longitudinal genital ridge resulting into separate testes so total volume of testis exceeds of one. The second theory explains transverse division of genital ridge at different levels resulting into different combination of testes, epididymis and vas deferens.⁷

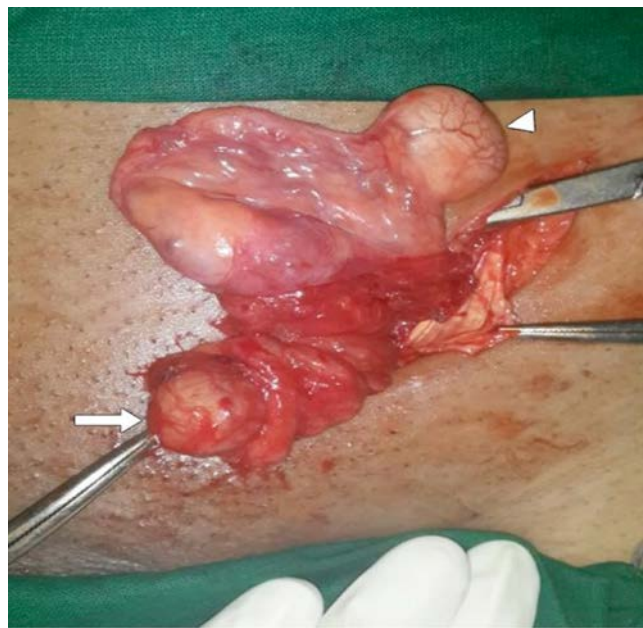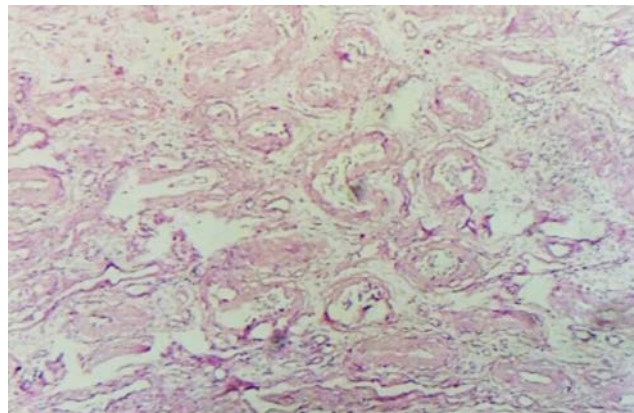
There are various types of classifications for polyorchidism. Based on site of testes they can be classified as scrotal (66%), inguinal (23%) and abdominal (9%).³ Leung (1988) classified polyorchidism based on embryological development with possible anatomical distinct epididymis or vas deferens.¹ Singer (1992) and colleagues proposed classification based on anatomical and functional potential of supernumerary testis to epididymis and finally by vas deferens.³

An effort to restore the functionality of undescended testes can be attempted if surgically corrected before age of 4-5 years. A significant risk of malignancy is reported in undescended non-functional testis before puberty being 2.2% while after puberty it rises substantially to 5.4%.⁴ Recent publications also suggest higher incidence of testicular malignancies (4 to 6%)³ in cryptorchid testis compared to normal testis. There is higher risk of testicular malignancy in polyorchidism cases of about 7% especially in non-scrotal testis.⁸ Of

Table 1. The Bergholz classification of polyorchidism.

Type A 1 (17%)	Type A 2 (14%)	Type A 3 (27%)	Type A 4 (24%)	Type B 1 (10%)	Type B 2* (8%)
Testis with own epididymis and vas deferens	Testis with own epididymis but common vas deferens of neighboring testis	Testis share epididymis and vas deferens of neighboring testis	Testis with own vas deferens but common epididymis	Testis has its own epididymis	Testis lacks epididymis

*Present case.

**Figure 1. Intraoperative photo showing undescended testis (arrow head) at deep inguinal ring and normal testis (arrow) delivered through inguinal incision along with normal cord structures.****Figure 2. Histopathological slide of inguinal testis showing arrest of germ cells.**

these 88.8% are malignant namely seminoma, teratoma, yolk sac tumors and choriocarcinoma.⁴ About 20% of polyorchidism patients seek the help of doctors for infertility issues.²

The management of supernumerary testes has been a topic of much debate and different factors like age of patient, location of testes, functional status and lastly compliance and accessibility for follow up have to be taken into consideration. Broadly in pediatric age group or patients with reproductive desire and uncomplicated polyorchidism should have conservative approach like orchidopexy,⁸ however a strict vigilant follow up is mandatory. While adults without reproductive desire, complicated polyorchidism and with inaccessibility for follow up should not be considered for conservative management.

In our view supernumerary testis with complications like cryptorchidism, torsion and intraoperative non-functional testis *i.e.*, without a draining vas deferens or epididymis,^{7,8} excision can be performed due to higher risk of malignancy in polyorchidism. While conservative approach is recommended for uncomplicated polyorchidism in functional testis^{2,8,9} with a dedicated follow up. Current review of

literature recommends conservative management for uncomplicated functional testes and regular follow up in polyorchidism.²

Conclusions

The diagnosis of uncomplicated polyorchidism is rarely non-incidental and management being controversial.

A surgical approach is advisable in complicated, non-compliant and non-reproductive patients in view of higher risk of malignancy in these patients.

References

1. Kundu AK, Deb D, Pradhan P, et al. Triorchidism: an incidental finding and review of literature. *J Anat Soc India* 2001;50:37-9.
2. Sonmez NC, Kılınc F, Arisan S, Caliskan KC. Polyorchidism: a case report and

review of the literature. *Andrology* 2012;1:102.

3. Sa lam HS, Öno l FF, Avcı E, Ergüven A. Report of a boy with polyorchidism and a review of current knowledge regarding this unusual anomaly. *Turk J Urol* 2013;39: 119-21.
4. Petterson A, Richiardi L, Nordenskjöld A, et al. Age at surgery for undescended testis and risk of testicular cancer. *N Engl J Med* 2007;356:1835-41.
5. Bayraktar A, Olcucuoglu E, Sahin I, et al. Management of polyorchidism: surgery or conservative management? *J Hum Reprod Sci* 2010;3:162-3.
6. Bergholz R, Wenke K. Polyorchidism: a meta-analysis. *J Urol* 2009;182:2422-7.
7. Haddock G, Burns HJ. Polyorchidism. *Postgrad Med J* 1987;63:703-5.
8. Parihar D, Kadian YS, Rattan KN. Polyorchidism: a rare finding in inguinal swelling. *APSP J Case Rep* 2013;4:28.
9. Khedis M, Nohra J, Dierickx L, et al. Polyorchidism: presentation of 2 cases, review of the literature and a new management strategy. *Urol Int* 2008;80:98-101