

A case of neurofibromatosis 1 presenting with optic pathway glioma with an early onset and an aggressive course

*Suma Ganesh, MS; Archana Gupta, DNB;
Manish Sharma, MS; Sandeep Bhuttan, MS*

Optic pathway glioma associated with neurofibromatosis 1 has a classically indolent course. However, involvement of the optic radiations is relatively rare and is associated with a more aggressive course. A three-year-old girl presented with strabismus and loss of vision in the left eye with relative afferent pupillary defect and optic disc pallor. She had multiple café au lait spots. Visually evoked potential was suggestive of an optic nerve conduction defect and magnetic resonance imaging of the brain was suggestive of an optic pathway glioma involving the optic nerves, the optic chiasma and the optic tracts. The optic radiations and the dentate nuclei had hamartomas. Optic nerve biopsy confirmed pilocytic astrocytoma. Radical radiotherapy under general anesthesia was subsequently given. This case report aims to highlight the involvement of the optic radiations and the unusually aggressive clinical course in this case.

Key words: Glioma, neurofibromatosis 1, optic radiations

Indian J Ophthalmol 2008;56:161-2

Neurofibromatosis Type 1 (NF-1) is a relatively common (incidence 1 in 3000) autosomal dominant disorder.¹ In addition to multiple peripheral neurofibromas, NF-1 predisposes to central nervous system (CNS) tumors. Most of these are pilocytic astrocytomas, arise in children and are located in the optic pathways or in the brainstem.² A majority of the gliomas arising in association with NF-1 are indolent³ and in the younger age group do not require active intervention until progression is documented or the disease is severe enough to affect visual outcome. However, optic pathway gliomas in NF-1 may rarely involve the optic radiations. Optic radiation involvement may signal a more aggressive optic pathway glioma in patients with NF-1.⁴ We report the case of a three-year-old girl presenting with an unusually aggressive optic pathway glioma involving the optic radiations associated with NF-1 and treated with radiotherapy.

Case Report

A three-year-old female child presented in the last week of April 2005 with a history of the left eye squinting intermittently and not focusing well since 10 days. There were pigmented skin lesions present since infancy.

On ophthalmic evaluation, the best-corrected vision in the right eye was 20/40 (N9) and in the left eye was counting fingers at one foot with accurate projection of rays. There was left eye exotropia with poor fixation without any abnormal head posture. There was no nystagmus. Corneal reflex test showed a deviation of 10 degrees. Prism bar cover test showed a deviation of 20 prism diopters for distance and near.

The extraocular movements were full. She had a relative afferent pupillary defect (RAPD) in the left eye. The skin showed multiple café au lait spots, [Fig. 1] some larger than 5 mm in the greatest diameter. Axillary and inguinal freckles were also present.

Visually evoked potential showed an optic nerve conduction defect and delayed latency in the left eye as compared to the right with normal amplitudes in both. Electroretinography was normal.

A brain magnetic resonance imaging (MRI) [Fig. 2] performed in May 2005 showed a fusiform enlargement of the left optic nerve with a thickened right optic nerve.

The optic chiasma showed enhancement extending to involve the optic tracts bilaterally. Posteriorly non-enhancing altered signals appearing hyperintense were seen along the optic radiations. A non-enhancing hyperintense signal was seen in the dentate nuclei bilaterally - consistent with the classic hamartomatous CNS fibromas of NF-1.

The patient was referred to a neurosurgeon and the biopsy of the optic nerve was done through left frontal temporal craniotomy, which revealed Rosenthal fibers with eosinophilic globular bodies [Fig. 3] strongly positive for Glial Fibrillary Acidic Protein (GFAP) stain confirming a diagnosis of pilocytic astrocytoma of the optic nerve.

A diagnosis of NF-1 with bilateral optic pathway glioma - pilocytic astrocytoma was made.

Radical radiotherapy under general anesthesia was given in September 2005; post radiotherapy, the gliomas significantly regressed in size with reduced enhancement on a repeat MRI done in April 2006. The altered signal in the dentate nuclei however was unchanged. On post radiotherapy follow-up, visual acuity in the right eye was 20/40 and in the left eye was no perception of light. The fundus examination showed disc pallor both eyes, left eye more than right.

Discussion

The most common differential diagnosis of a child with painless loss of vision, RAPD, strabismus and an abnormal disc includes optic glioma, optic nerve meningioma, optic neuritis and Autosomal Dominant Optic Atrophy (ADOA). The diagnosis of optic nerve glioma associated with NF-1 in this case was suggested by café au lait spots, asymmetric disc presentation and later supported by MRI findings and finally the biopsy report.

NF-1 is a rare condition characterized by hamartomas of neural crest origin. It has an autosomal dominant inheritance although half the cases are new mutations.⁵

Among the various clinical manifestations, astrocytomas are the major type of CNS tumors in NF-1 and pilocytic astrocytoma

Pediatric Ophthalmology Department, Dr. Shroff's Charity Eye Hospital, Daryaganj, New Delhi, India

Correspondence to Dr. Ganesh Suma, Dr. Shroff's Charity Eye Hospital, Kedarnath Road, Daryaganj, New Delhi - 110 002, India. E-mail: drsumaganesh@yahoo.com

Manuscript received: 18.08.06; Revision accepted: 10.07.07

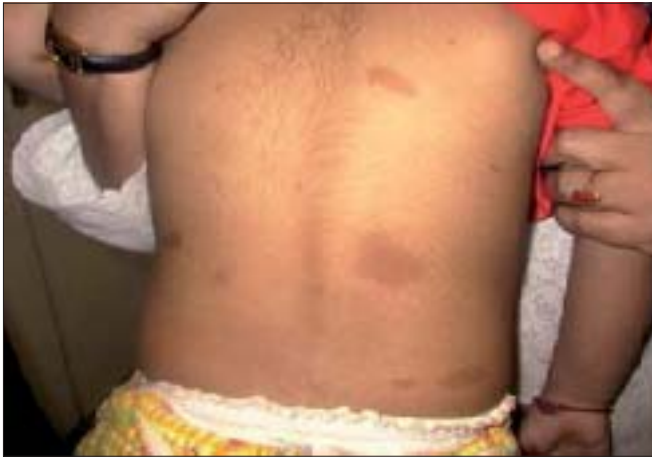

Figure 1: Café au lait spots

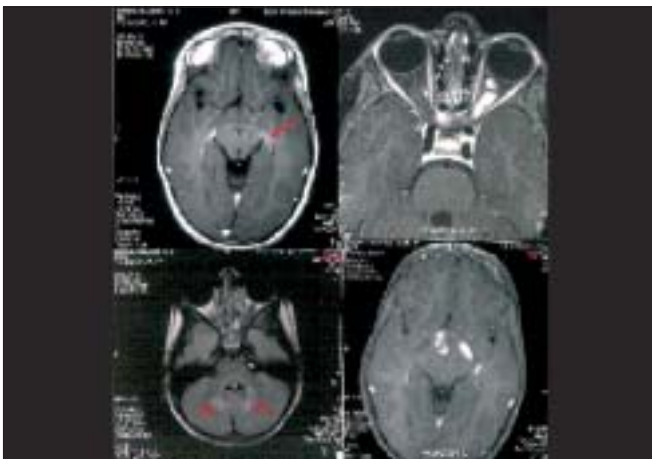

Figure 2: MRI showing involvement of the optic tracts and optic radiations (left top and bottom), the fusiform dilatation showing the optic nerve glioma (on the top right) and a post radiotherapy image showing some regression of the involvement of the optic radiations (bottom right)

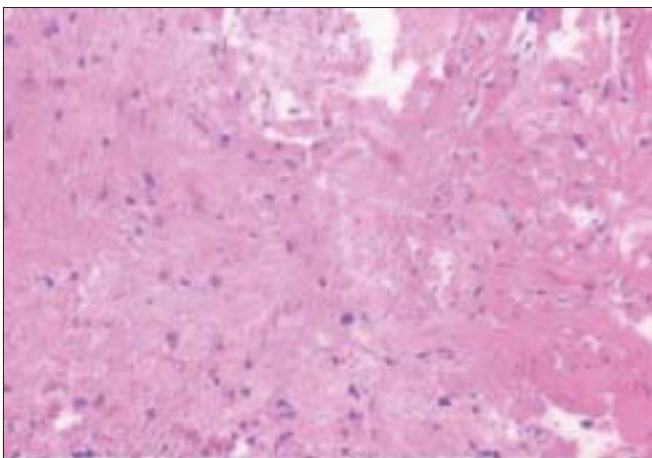


Figure 3: Histopathological slide showing Rosenthal fibers and eosinophilic granular bodies suggestive of pilocytic astrocytoma. Glial fibrillary acidic protein (GFAP) stain with magnification, x100

(WHO Grade I) the main histological subtype.² A stable or a very slow progressive course that may account for the overall good prognosis of CNS tumors in NF-1 usually characterizes pilocytic astrocytomas. Optic radiation involvement though rare may signal a more aggressive optic pathway glioma in patients with neurofibromatosis.^{4,6}

In pediatric patients with NF-1 and optic pathway gliomas, the likelihood of visual loss is dependent on the extent and location of the tumor by MRI and is particularly associated with the involvement of post chiasmal structures.⁷

Considering the risk of visual loss, the NF-1 optic pathway glioma task force⁸ has recommended annual screening including neuroimaging, for children with asymptomatic NF-1 till the age of six. Thereafter, the interval is yearly for those with optic pathway glioma and two-yearly for the rest. Recommended guidelines for therapy include observation in the case of a stable painless intraorbital tumor and good vision; a tumor causing disfiguring proptosis and poor vision should be excised. Progressive chiasmal tumors should be treated with radiotherapy. Juvenile pilocytic astrocytoma has a better prognosis among all the histological subtypes and a five-year survival rate of 80 to 100% has been documented.⁹

Our case was unusual in presenting with an unusually aggressive course at a younger age with involvement of the optic radiations requiring radiotherapy for the same. We would like to reiterate the importance of a thorough systemic evaluation of any child presenting with unexplained visual loss and strabismus along with the importance of neuroimaging in the diagnosis and prognostication of neurofibromatosis and optic nerve glioma. Finally, optic nerve glioma involving the post chiasmal structures including the optic radiations can present as a more aggressive variant and warrants intervention for the same.

References

1. Mario FJ Jr, Ramsby G. Magnetic resonance imaging lesion analysis in neurofibromatosis type 1. *Arch Neurol* 1998;55:500-5.
2. Guillamo JS. Prognostic factors of CNS tumours in Neurofibromatosis 1 (NF1): A retrospective study of 104 patients. *Brain* 2002;26:152-60.
3. Astrup J. Natural history and clinical management of optic pathway glioma. *Br J Neurosurg* 2003;17:327-35.
4. Liu GT. Optic radiation involvement in optic pathway gliomas in neurofibromatosis. *Am J Ophthalmol* 2004;137:407-14.
5. Theos A, Korf BR. Pathophysiology of neurofibromatosis type 1. *Ann Intern Med* 2006;144:842-9.
6. Di Mario, Francis J, Ramsby F. Magnetic resonance imaging lesion analysis in neurofibromatosis type I. *Arch Neurol* 1998;55:500-5.
7. Balcer LC, Liu GT. Visual loss in children with neurofibromatosis type 1 and optic pathway gliomas: Relation to tumor location by magnetic resonance imaging. *Am J Ophthalmol* 2001;131:442-5.
8. Pinson S. Neurofibromatosis 1: Recommendations for management. *Arch Pediatr* 2002;9:49-60.
9. Mamelak AN, Prados MD, Obana WG, Cohen PH. Treatment options and prognosis for multicentric juvenile pilocytic astrocytoma. *J Neurosurg* 1994;81:24-30.