

# Long-standing aggressive angiomyxoma as a paratesticular mass: A case report and review of literature

SAGE Open Medical Case Reports  
Volume 5: 1–4  
© The Author(s) 2017  
Reprints and permissions:  
sagepub.co.uk/journalsPermissions.nav  
DOI: 10.1177/2050313X17712090  
journals.sagepub.com/home/sco



Ahmet M Aydin<sup>1</sup>, Kubra Katipoglu<sup>2</sup>, Dilek E Baydar<sup>2</sup>  
and Cenk Y Bilen<sup>1</sup>

## Abstract

**Objectives:** Aggressive angiomyxoma is known as a mesenchymal tumor of premenopausal women and it is extremely rare in men.

**Methods:** Herein, we report a 66-year-old male with a firm scrotal mass that had gradually enlarged over 20 years.

**Results:** Radiological studies revealed 10 × 15 cm mass lesion confined to right scrotum with neither local invasion nor distant metastasis. Inguinal orchiectomy was performed and histopathology showed characteristic features of an aggressive angiomyxoma occupying paratesticular region, which was a challenging diagnosis due to its unexpected occurrence in the male gender.

**Conclusion:** Aggressive angiomyxoma is mostly considered as a benign tumor in females despite its propensity for local recurrence. Whether it may show a divergent biological behavior in men is unknown as the reported cases are too few.

## Keywords

Aggressive angiomyxoma, mesenchymal tumor, orchiectomy, paratesticular mass, scrotum

Date received: 8 February 2017; accepted: 2 May 2017

## Introduction

Aggressive angiomyxoma (AAM) is a rare mesenchymal tumor mostly seen in women at reproductive ages, and less than 15 scrotal cases have been reported so far. It is a locally invasive tumor and has a high tendency to recur. However, distant metastasis is rare and it shows benign histological features without cytological atypia and pleomorphism. Herein, we report a male patient with a scrotal mass of 20-year duration that was diagnosed as paratesticular AAM of scrotum following inguinal orchiectomy. To our knowledge, this is the first reported case of AAM in a patient with such a long clinical course.

## Case report

A 66-year-old male presented with a huge right scrotal mass, which had been approximately 3–4 cm in diameter when he had first noted it 20 years ago. It enlarged gradually; however, the patient did not opt for any treatment since it caused no significant discomfort except for feeling of mild heaviness. During physical examination, a firm 10 × 15 cm painless mass was palpated within the right scrotum. It had soft contours, did not trans-illuminate and

was mobile without fixation to scrotal skin. The serum tumor biomarkers including alpha-fetoprotein, beta-human chorionic gonadotropin, lactate dehydrogenase and prostate-specific antigen levels were all within normal limits. In scrotal ultrasonography, it was seen as a solid hypoechoic lesion with thin echogenic septa. Further imaging studies excluded distant spread. The patient then underwent right inguinal orchiectomy.

On gross pathological examination, an 11.5 × 7.5 × 7 cm solid lobulated mass, which was originated from the parietal layer of anterior tunica vaginalis and grewed into scrotal sac was noted (Figure 1). It had a cream to gray-colored gelatinous cut surface with hemorrhagic areas and was

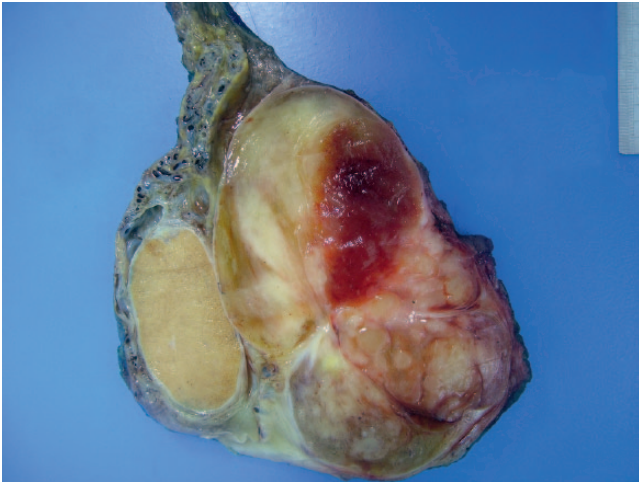
<sup>1</sup>Department of Urology, Faculty of Medicine, Hacettepe University, Ankara, Turkey

<sup>2</sup>Department of Pathology, Faculty of Medicine, Hacettepe University, Ankara, Turkey

### Corresponding Author:

Cenk Y Bilen, Department of Urology, Faculty of Medicine, Hacettepe University, Sıhhiye, 06100 Ankara, Turkey.  
Email: cybilen@yahoo.com





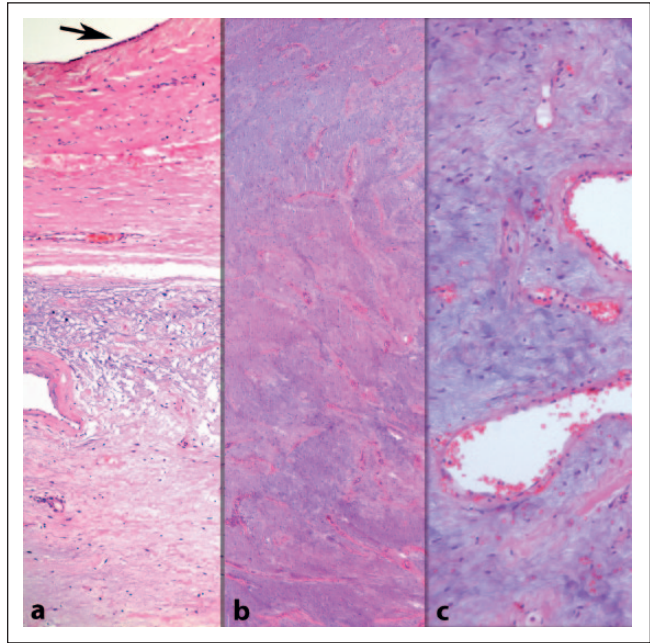
**Figure 1.** Macroscopic appearance of the tumor.

well-circumscribed by a fibrous capsule. Microscopical examination showed that the lesion was hypocellular and composed of short spindle cells within abundant myxoid extracellular matrix, which was collagenous in some areas (Figure 2). There was a rich network of small to large blood vessels, some with hyalinized thick walls. Neither cellular atypia nor mitotic activity was noted. Immunohistochemical studies revealed diffuse and strong expression of CD34, estrogen receptor (ER) and progesterone receptor (PR) by neoplastic cells (Figure 3). Scattered cells were positive for desmin, whereas no reaction for pan-cytokeratin, smooth muscle actin, S-100, calretinin, CD117, MUC 4, CDK4 or MDM2 was observed. Morphological findings were found consistent with AAM. Invasion into surrounding tissues was not observed and surgical margins were free of tumor. The patient has been well with no evidence of disease for 6 months following surgery.

## Discussion

AAM is a benign mesenchymal tumor that arises mostly from the soft tissues of pelvic region in the premenopausal women. It shows female predominance and only less than 50 male cases have been reported so far. Among them, 38% originated from scrotum, while 33% from spermatic cord, 13% from perineum, 8% from pelvic organs and 8% from bladder.<sup>1</sup>

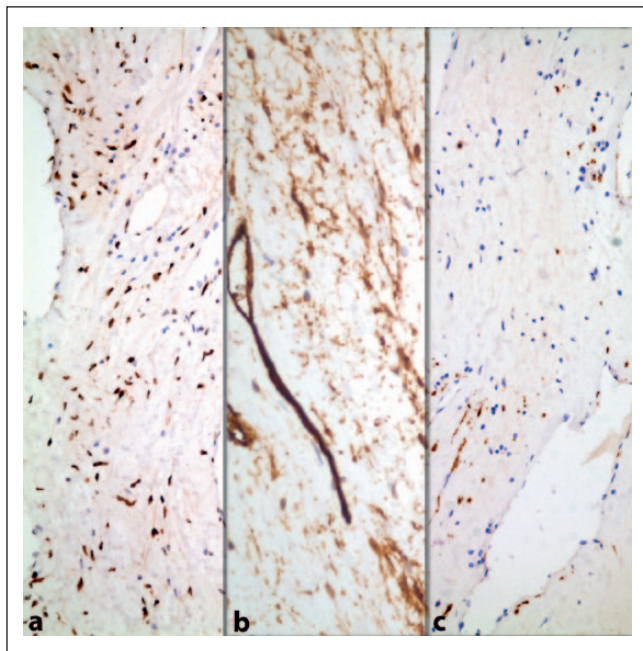
AAM of scrotum can be mistaken as other common diseases such as testicular tumor, varicocele and inguinal hernia during physical examination.<sup>2</sup> Scrotal ultrasonography finds a hypoechoic or cystic mass with internal vascularity and is incapable of differentiating AAM from other mesenchymal tumors. Magnetic resonance imaging and computed tomography with contrast can be considered as the most useful radiologic modalities for diagnosis of AAM since they can sometimes reveal distinctive “swirled” appearance of fibromuscular stroma.



**Figure 2.** Hypocellular and highly myxoid lesion consisting of small spindle cells and blood vessels of varying sizes. A black arrow in (a) points to the mesothelial lining of parietal tunica vaginalis (a) H&E:  $\times 100$ ; (b) H&E:  $\times 40$ ; (c) H&E:  $\times 200$ ).

On microscopic examination, AAM appears as a paucicellular neoplasm consisting of small spindle to pale satellite cells along with vessels varying in caliber size and thickness. The neoplastic cells are scattered in a collagen containing loose or myxoid stroma and look bland without atypia or pleomorphism. They are characteristically immunoreactive for ER and PR, and focally for desmin. ERs are usually present in AAM irrespective of gender, although male cases with androgen receptor and PR but without ER have also been reported.<sup>1</sup> Desmin and CD34 positivity are present in almost half of the cases. Negative staining for S-100 excludes the diagnosis of neurofibroma which has a significant light microscopical similarity to AAM. Angiomyofibroblastoma is distinguished by its small size (usually  $< 5$  cm), their cells appear more plump or epithelioid than those of AAM and often aggregate around blood vessels. Multinucleated giant cells with linearly arranged nuclei are another histologic feature favoring angiomyofibroblastoma. Superficial angiomyxoma arising in the dermis or subcutis is a similar myxoid and vascular lesion, but lacks large-caliber vessels seen in AAM and is generally negative for ER and PR.

Primary sarcomas are the most common malignancies of paratesticular location and constitute about 2% of all soft tissue sarcomas.<sup>3</sup> Majority of them show cytologic atypia, increased mitotic activity, large size and infiltrative growth in the histopathological examination and they can be easily differentiated from AAM. Their prognosis is very poor despite chemotherapy and radiotherapy. Low-grade



**Figure 3.** Neoplastic cells showing diffuse (a) estrogen receptor, (b) CD34 and (c) focal desmin immunoreactivity (immunohistochemistry: (a) anti-ER Ab,  $\times 200$ ; (b) anti-CD34 Ab,  $\times 400$ ; (c) anti-desmin Ab,  $\times 200$ ).

fibromyxoid sarcoma is one malignant mesenchymal neoplasia consisting of bland cells that has been reported in the paratesticular region and might be challenging to distinguish morphologically from AAM. However, it has characteristic whorled growth pattern, curvilinear vasculature and immunohistochemical MUC4 (mucin 4) expression that lack in AAM. Additionally, low-grade fibromyxoid sarcoma does not show ER and/or PR immunostaining. Another consideration in the differential diagnosis of paratesticular AAM would be dedifferentiated liposarcoma (DDLs), a tumor which may mimic wide variety of mesenchymal lesions histologically. Careful evaluation of the tumor reveals may identify associating well-differentiated liposarcoma component, allowing correct diagnosis. Documenting MDM2 (murine double minute 2) amplification will also favor DDLs. Immunohistochemical markers MDM2 and CDK4 (cyclin-dependent kinase 4) are of uncertain significance and have been shown variably positive in AAM.<sup>4,5</sup>

Approximately one third of AAMs harbor rearrangement of *HMGA2* gene on chromosome 12q15 that encodes a member of the high-mobility group of proteins.<sup>6</sup> Immune stain detection of this fusion product has a limited value in the diagnosis since the *HMGA2* gene rearrangement is not always associated with the aberrant protein expression.<sup>7</sup> Given the absence of exclusively specific markers, the diagnosis and differentiation of AAM from other benign and malignant mesenchymal tumors is a difficult task, mainly

based on morphology in hematoxylin–eosin-stained sections and exclusion of mimicking lesions with the help of immunohistochemistry.

The mainstay treatment of AAM is complete surgical resection. Hormonal therapy is also effective in the settings of neoadjuvant therapy for decreasing tumor size or adjuvant therapy after incomplete surgical resection. Recurrence usually occurs within the 5 years after complete surgical excision.<sup>8</sup> Most information regarding recurrence of AAM has been obtained from female patients. Bigby et al.<sup>5</sup> speculated that hormonal status might be more better predictor of treatment failure than extend of surgical resection. Considering that the estrogen and progesterone hormone dynamics are related to age and sex, the tumor aggressiveness, growth rate and its metastatic potential in male patients might reasonably vary from the females.

In the literature, two metastatic AAMs (to lung and mediastinum) have been reported so far, both seen in female patients.<sup>9</sup> One patient died of disease 4 years after initial diagnosis. However, no single metastasis of AAM has been reported in men up to this date. Our patient is highly notable here that his tumor has shown no signs of aggressive behavior, neither locally nor in the form of distant spread, despite 20-year-long history. Is that attributable to the male gender? Are the men AAMs completely benign lesions? These are open questions awaiting more cases to be reported.

In conclusion, AAM should be considered in the differential diagnosis of patients presenting with a gradually enlarged scrotal mass. It is a difficult pathological diagnosis which can be mimicked by a variety of other proliferations. Nevertheless, paratesticular AAM should be carefully managed, at least for the time being since there exist only a few data regarding its prognosis.

### Acknowledgements

All authors contributed equally to this work.

### Declaration of conflict of Interest

The author(s) declared no potential conflicts of interest with respect to the research, authorship and/or publication of this article.

### Funding

The author(s) received no financial support for the research, authorship and/or publication of this article.

### Informed consent

Written informed consent was obtained from the patient for publication of this case report.

### References

1. Chihara Y, Fujimoto K, Takada S, et al. Aggressive angio-myxoma in the scrotum expressing androgen and progesterone receptors. *Int J Urol* 2003; 10(12): 672–675.
2. Karwacki GM, Stockli M, Kettelhack C, et al. Radiographic diagnosis and differentiation of an aggressive angio-myxoma in a male patient. *J Radiol Case Rep* 2013; 7(7): 1–6.

3. Unlu Y, Huq GE, Ozyalvacli G, et al. Paratesticular sarcomas: a report of seven cases. *Oncol Lett* 2015; 9(1): 308–312.
4. Van Roggen JF, Van Unnik JA, Briaire-de Bruijn IH, et al. Aggressive angiomyxoma: a clinicopathological and immunohistochemical study of 11 cases with long-term follow-up. *Virchows Arch* 2005; 446(2): 157–163.
5. Bigby SM, Symmans PJ, Miller MV, et al. Aggressive angiomyxoma [corrected] of the female genital tract and pelvis—clinicopathologic features with immunohistochemical analysis. *Int J Gynecol Pathol* 2011; 30(5): 505–513.
6. Medeiros F, Erickson-Johnson MR, Keeney GL, et al. Frequency and characterization of HMGA2 and HMGA1 rearrangements in mesenchymal tumors of the lower genital tract. *Genes Chromosomes Cancer* 2007; 46(11): 981–990.
7. Rabban JT, Dal Cin P and Oliva E. HMGA2 rearrangement in a case of vulvar aggressive angiomyxoma. *Int J Gynecol Pathol* 2006; 25(4): 403–407.
8. Haldar K, Martinek IE and Kehoe S. Aggressive angiomyxoma: a case series and literature review. *Eur J Surg Oncol* 2010; 36(4): 335–339.
9. Blandamura S, Cruz J, Faure Vergara L, et al. Aggressive angiomyxoma: a second case of metastasis with patient's death. *Hum Pathol* 2003; 34(10): 1072–1074.