



Contents lists available at ScienceDirect

International Journal of Surgery Case Reports

journal homepage: www.casereports.com

Giant inguinal hernia: Report of a case and reviews of surgical techniques



Atthaphorn Trakarnsagna, Vitoon Chinswangwatanakul, Asada Methasate, Jirawat Swangsri, Chainarong Phalanusitthepha, Thammawat Parakonthon, Voraboot Taweerutchana, Thawatchai Akaraviputh*

Minimally Invasive Surgery Unit, Division of General Surgery, Department of Surgery, Faculty of Medicine Siriraj Hospital, Mahidol University, Bangkok 10700, Thailand

ARTICLE INFO

Article history:

Received 2 June 2014

Accepted 12 October 2014

Available online 18 October 2014

Keywords:

Giant inguinal hernia

Treatment

Hernioplasty

ABSTRACT

INTRODUCTION: Inguinal hernia is one of the most surgical common diseases. Giant inguinal hernia is more unusual and significantly challenging in terms of surgical management. It is defined as an inguinal hernia that extends below the midpoint of inner thigh when the patient is in standing position.

PRESENTATION OF CASE: A 67-year-old male presented with giant right-side inguinal hernia with symptoms of partial colonic obstruction and significant weight loss. Barium enema revealed ascending colon, cecum and ileum contained in hernia sac without significant lesions of large bowel. He underwent hernia repair with omentectomy. Hernioplasty with polypropylene mesh was performed without any complications. He recovered uneventfully.

DISCUSSION: There were several repair techniques suggested by published articles such as resection of the content and increased intraabdominal volume procedure. Many key factors for management of the giant inguinal hernia were discussed. A new classification of the giant inguinal hernia was described.

CONCLUSION: Surgical repair for the giant inguinal hernia is challenging and correlated with significant morbidity and mortality due to increased intra-abdominal pressure.

© 2014 The Authors. Published by Elsevier Ltd. on behalf of Surgical Associates Ltd. This is an open access article under the CC BY-NC-ND license (<http://creativecommons.org/licenses/by-nc-nd/3.0/>).

1. Introduction

Inguinal hernia is one of the most surgical common diseases in clinical practice. The history of inguinal hernia repair originated in the ancient times¹ and the treatment has evolved, developed and changed since. The most recent one is the concept of tension-free repair which remains popular among surgeons today. It is interesting to note, though, that numerous literatures have been published on this disease in the small anatomical space despite its simplicity. In the past couple of years, most publications focused on laparoscopic surgery and the different types of prosthetic mesh.

Giant inguinal hernia, however, is more unusual and significantly challenging in terms of surgical management. It is defined as an inguinal hernia that extends below the midpoint of inner thigh when the patient is in standing position.² No treatment has been adopted as standard procedure for this uncommon disease and several repair techniques are suggested by published articles and case reports. Further, the absence of large scale comparative study is expected to continue due to the relatively low number of cases.

As a result, choosing a surgical procedure is made difficult and the decision must be made intraoperatively.

This article is an examination of a very rare case of giant right inguinal hernia containing right side of colon and greater omentum. This was corrected by simple hernioplasty and omentectomy. Various surgical techniques reported in previous publications are discussed below as well.

2. Presentation of case

A 67-year-old healthy male has been affected by long-standing, gradually enlarging of right-side inguinal hernia for the past 30 years. His symptom of abdominal discomfort after meal has worsened over time and he had lost 30 kg of weight in the past year. Physical examination revealed cachexia and large irreducible right-side inguinal hernia extending to the level of lower thigh (Fig. 1). Barium enema demonstrated ascending colon, cecum and ileum contained in hernia sac without any lesion of the large bowel (Fig. 2).

For the operation, after general anesthesia was administered, standard transverse incision at right inguinal area was performed. Hernia sac was dissected and separated from spermatic cord (Fig. 3A). After the hernia sac was opened, terminal ileum, cecum,

* Corresponding author. Tel.: +66 2419 8006; fax: +66 2412 1370.
E-mail address: thawatchai.aka@mahidol.ac.th (T. Akaraviputh).

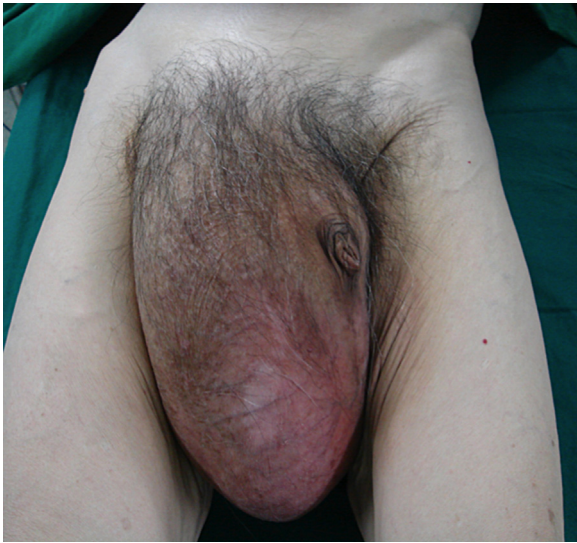

Fig. 1. The hernia sac extended to level of lower thigh. The patient was on supine position.

ascending colon and omentum were found inside the hernia sac (Fig. 3B). An attempt was made at manual reduction but it was unsuccessful due to the massive size of the contents. At this point, lateral extension of internal ring was performed, followed by partial omentectomy. Manual reduction was then reattempted and on this occasion it was possible to reduce the contents into the abdominal cavity. Intra-abdominal pressure was measured and confirmed by intravesicular technique. Internal ring was repaired with interrupted Prolene #2/0. Lichtenstein's tension-free technique was performed with polypropylene mesh. Hemostasis was checked and vacuum drain was placed due to the extent of raw surface. Patient was extubated and transferred to recovery room in stable condition.

He recovered uneventfully and the drain was removed before he was discharged on the seventh postoperative day. The patient was able to eat and has gradually regained weight. Small postoperative

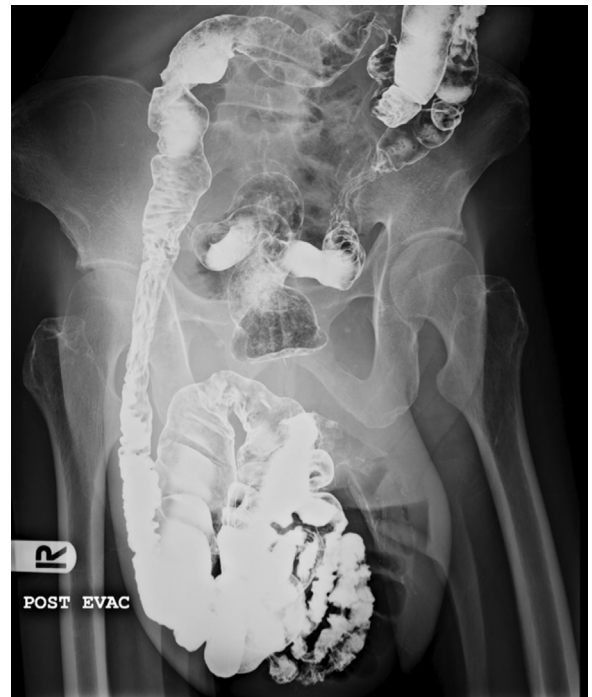

Fig. 2. Barium enema revealed ascending colon, cecum and ileum containing in the hernia sac without significant lesions of the large bowel.

scrotal hematoma was treated non-operatively and resolved within few weeks. No evidence of recurrent inguinal hernia has been detected at 4 years after the operation.

3. Discussion

3.1. Key factors in the management of giant inguinal hernia

1. Preoperative colonic evaluation should be considered although the correlation between colon cancer and inguinal hernia is

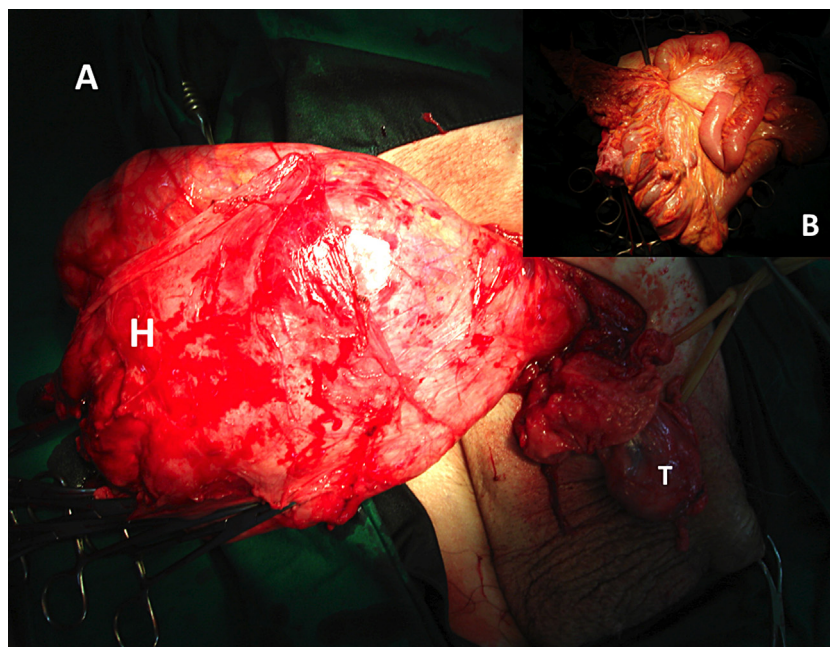


Fig. 3. Intraoperative findings: the huge hernia sac (H) was separated from right testis (T) (A). Terminal ileum, cecum, ascending colon and omentum were found as the contents of the hernia sac (B).

not clearly identified. Statistics indicates that colon cancer is detected by preoperative barium enema in 1.8–2.5% of patients who are older than 40 years and have undergone inguinal hernia repair.^{3–5} Moreover, as colonic resection may be required as a part of treatment of giant inguinal hernia, it is recommended that the patient is given a preoperative colonic evaluation. From our point of view, barium enema is more of a preferred method than colonoscopy for the reason that colonoscopy in the colon within hernial sac, is associated with high risk of colonic perforation.⁶

2. Bowel preparation should be considered in all cases, especially the ones where hernial sac extends beyond the imaginary line between superior borders of patellar bone. Colonic resection may be necessary as a part of the treatment. The details of which are discussed later.
3. Attempts must be made to prevent excessive intra-abdominal and intrathoracic pressure caused by reduction of massive contents into limited domain of abdominal cavity.
4. Spermatic cord can be easily stretched as a result of long-standing of hernia. In some cases, the spermatic cord is twisted, causing testicular atrophy. Therefore, preoperative testicular examination should be performed in all patients and orchidectomy may be needed to prevent undesirable events.
5. Scrotal hematoma is commonly found after the operation. Dense adhesion is usually detected due to the chronicity of the disease. Extensive lysis of adhesion can cause hematoma. Given these circumstances, a closed drainage system should be implemented. It is important to note, though, that such system cannot always prevent postoperative hematoma. This is true for our case. Meticulous hemostasis and close observation are the most important steps toward prevention and early detection.
6. An informed consent is needed to cover all possible operative procedures because final decision will be made intraoperatively. All of these options must be explained to the patient as well as their family members.

3.2. Intraabdominal hypertension

Intraabdominal hypertension can develop because of the disproportion of abdominal domain and the large amount of content in the hernial sac. The high rate of mortality is clearly observed following forced reduction of giant inguinal hernia.⁷ Intraabdominal hypertension can immediately develop after reduction of contents or later in the postoperative period due to ileus of the bowel.

Excessive increase of intra-abdominal pressure generally affects regional blood flow in abdominal cavity, other organs outside abdomen, as well as the cardiovascular and respiratory systems. Intrathoracic pressure is raised as a result of cephalic displacement of diaphragm through the increase of intra-abdominal pressure.⁸

Venous return, cardiac output and blood pressure are decreased by this phenomenon. Moreover, increase of intrathoracic pressure causes increase of inspiratory rate and mean airway pressure, while tidal volume and pulmonary compliance are reduced.⁸ Therefore, vital signs and urine output should be closely monitored. Respiratory support may be needed until ileus starts to resolve.⁹

3.3. What do we learn from previous publications?

According to previous literatures, hernioplasty with forced reduction is feasible for the treatment of giant inguinal hernias extending below mid inner thigh but above imaginary line at lower thigh, the line between the middle point of inner thigh and suprapatellar.^{10,11} Intra-abdominal and intrathoracic pressure must be closely observed after the reduction as mentioned above.

Most hernia sacs, which extend below the imaginary line at lower thigh but above the line between superior borders of patellar bone require additional procedures rather than simple hernioplasty alone,^{9,12,13} except only one case reported by Coetzee et al.¹² The additional operations were introduced to prevent intra-abdominal hypertension. In cases that the hernia sac extends below the line between superior borders of patellar bone, additional procedures are almost always needed in addition to forced reduction and simple hernioplasty.^{14–21} The two major techniques required are resection of hernia contents and intra-abdominal volume increase procedure (Table 1).

4. Surgical techniques

4.1. Resection of the contents

Giant inguinal hernia is a type of hernia with massive contents inside the hernia sac and limited domain of abdominal cavity. The surgeon's decision regarding the prevention of intraabdominal hypertension is a crucial stage of overall management. Forced reduction is feasible in cases with mild form of this disease (type I, Fig. 4). Resection or debulking of the contents is an option to prevent intraabdominal hypertension, with resected organs usually being the colon, the small bowel, or the omentum. The benefit is that it is a single-stage operation. The limitations are rate of the failure of anastomosis, the changing of bowel function and the infection of prosthesis from resection of the bowel.

4.2. Intra-abdominal volume increase procedure

Loss of domain of intra-abdominal cavity is one of the main problems in the management of giant inguinal hernia. Forced reduction and simple hernioplasty may not be the appropriate

Table 1
Summarized of previous publications that correlated with new classification of the giant inguinal hernia and the operative techniques.

Author	Year	Number	Classification	Operation
Tsutsumi et al. ¹⁰	2008	One	Type I	Hernioplasty with PHS
Tay et al. ¹¹	1999	One		Hernioplasty
This case	2011	One	Type II	Omentectomy with hernioplasty
Coetzee et al. ¹²	2011	One		Hernioplasty
Valliatu et al. ¹³	2008	One		Bilateral muscle component separation
Mehendale et al. ⁹	2000	One		Right hemicolectomy with hernioplasty and flap
Kovachev et al. ¹³	2010	Two cases		Pneumoperitoneum with Stoppa technique
Monestiroli et al. ¹⁴	2007	One	Type III	Left hemicolectomy with hernioplasty (preperitoneal approach)
El Saadi et al. ¹⁵	2005	One		Two-stage procedure; resection and hernia repair
Ek et al. ¹⁷	2006	One		Two-stage procedure; rotating flap
Imisairi et al. ¹⁸	2011	One		Right hemicolectomy with danning
King et al. ¹⁹	1986	One		Extended right hemicolectomy with McVey-Usher
Patsas et al. ²⁰	2010	One		Extended right hemicolectomy and splenectomy with hernioplasty
Vasiliadis et al. ²¹	2010	One		Extended right hemicolectomy with hernioplasty

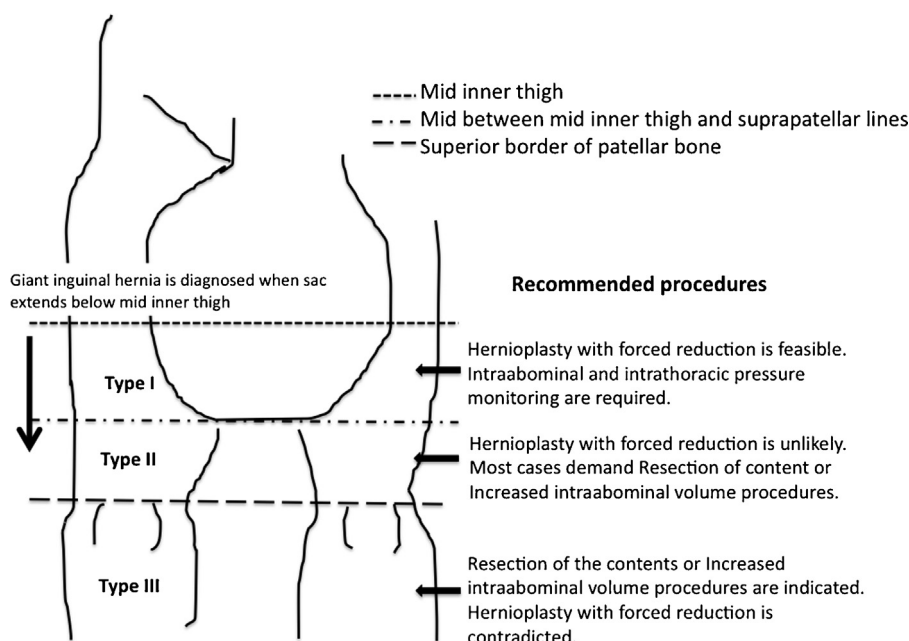


Fig. 4. New classification of giant inguinal hernia and recommended procedure.

procedure for moderate and severely enlarged giant inguinal hernia (type II and III, Fig. 4). Several techniques were proposed to avoid bowel resection, including preoperative progressive pneumoperitoneum and lengthening of the abdominal wall by mesh or rotation of viable tissue.

4.2.1. Preoperative progressive pneumoperitoneum

Moreno first reported the application of preoperative progressive pneumoperitoneum to ventral hernias²² and this technique was subsequently applied to giant inguinal hernia repair.²³ The concept is to preoperatively ensure adequate room in abdominal cavity by pneumoperitoneum before reduction of the hernial contents. This technique involves gradually insufflating the gas into abdominal cavity via placed catheter in situ, usually in increments from 500 cc to 2000 cc per day over 7–14 days.^{7,24} From previous literatures, gas choices include natural ambient air, oxygen,⁷ carbon dioxide and nitrous oxide.²⁵ The contraindications are abdominal infection, decompensated cardiac conditions, small neck of the hernia and strangulation.⁷ The limitations of this technique are prolonged preoperative hospitalization, spread of air into hernial sac and technical unsuccessful.

4.2.2. Rotation of viable tissue

Rotation of viable tissue is the other technique to increase intra-abdominal volume by increasing surface of the abdominal wall. Several techniques have been proposed in the literatures. For scrotal skin flap,^{17,26} midline anterior abdominal defect was created to increase space of abdominal cavity. Inguinal hernia orifice and midline anterior abdominal wall defect was repaired by prosthetic mesh, then cover the midline mesh with myocutaneous scrotal flap. A modification was proposed by using hernia sac as peritoneal flap and cover with mesh on top at anterior midline defect.²⁷ Similarly, tensor fascia latae musculocutaneous flap was alternatively used to cover mesh at anterior abdominal wall defect.⁹ Component separation technique is one used to advanced rectus muscle by freeing external oblique from internal oblique muscle.¹³ The advantage of rotation of viable tissue is that it is a single-stage procedure but surgical expertise is required to prevent complications.

5. Conclusion

Giant inguinal hernia is an uncommon condition defined as an hernial sac extending below mid-inner thigh in the standing position. Surgical repair is challenging and correlated with significant morbidity and mortality due to increased intra-abdominal pressure. We categorize giant inguinal hernia into three types, depending on its location and choice of operations. Surgical techniques, in addition to forced reduction with simple hernioplasty, are resection of contents and intra-abdominal volume increase procedure, combined with repair of hernia. The majority of publications on the subject are case reports and small case series, making it difficult to compare between the procedures. Application of appropriate technique for the individual patients is the key to success treatment and that is more important than strict adherence to any one technique.

Conflict of interest

Nothing to declare.

Funding

Nothing to declare.

Ethical approval

Ethics approved by the Ethical Committee of Siriraj Institutional Review Board, Siriraj Hospital, Mahidol University, Bangkok, Thailand.

Author contributions

Trakarnsagna A, Chinswangwatanakul V, Methasate A, Swangsri J, Phalanusitthepha C, Parakonthon T and Taweerutchana V performed the acquisition of data, analysis and interpretation of data; Trakarnsagna A drafted the article and revised it critically for important intellectual content; Akaraviputh T did final approval of the version to be submitted.

References

- Lau WY. History of treatment of groin hernia. *World J Surg* 2002;**26**(6):748–59.
- Hodgkinson DJ, McIlrath DC. Scrotal reconstruction for giant inguinal hernias. *Surg Clin North Am* 1980;**64**:307–13.
- Terezis NL, Davis WC, Jackson FC. Carcinoma of the colon associated with inguinal hernia. *N Engl J Med* 1963;**268**:774–6.
- Maxwell JW, Davis WC, Jackson FC. Colon carcinoma and inguinal hernia. *Surg Clin North Am* 1965;**45**(5):1165–71.
- Day T, Ferrara JJ. Preoperative barium contrast enema in patients with inguinal hernia. *South Med J* 1986;**79**(11):1339–41.
- Leisser A, Delpre G, Kadish U. Colonoscope incarceration: an avoidable event. *Gastrointest Endosc* 1990;**36**(6):637–8.
- Barst HH. Pneumoperitoneum as an aid in the surgical management of giant inguinal hernia. *Br J Surg* 1972;**59**(5):360–4.
- Papavramidis TS, Marinis AD, Pliakos I, Kesisoglou I, Papavramidou N. Abdominal compartment syndrome-intraabdominal hypertension: defining, diagnosing and managing. *J Emerg Trauma Shock* 2011;**4**(2):279–91.
- Mehendale FV, Taams KO, Kingsnorth AN. Repair of a giant inguinoscrotal hernia. *Br J Plast Surg* 2000;**53**(6):525–9.
- Tsutsumi N, Guntani A, Rikimaru T, Watanabe A, Kohnoe S. Giant inguinal hernia containing right colon repaired using the prolene hernia system. *ANZ J Surg* 2008;**78**(3):219.
- Tay E, Gray E, Morgan MW. Repair of a massive inguinal hernia. *J R Soc Med* 1999;**92**(11):586–7.
- Coetzee E, Price C, Boutall A. Simple repair of a giant inguinoscrotal hernia. *Int J Surg Case Rep* 2011;**2**:32–5.
- Valliattu AJ, Kingsnorth AN. Single-stage repair of giant inguinoscrotal hernias using the abdominal wall component separation technique. *Hernia* 2008;**12**(3):329–30.
- Kovachev LS, Paul AP, Chowdhary P, Chowdhary P, Filipov ET. Regarding extremely large inguinal hernias with a contribution of two cases. *Hernia* 2010;**14**(2):193–7.
- Monestiroli M, Bondurri A, Gandini F, Lenna G, Vellini S, Danelli P. Giant inguinoscrotal hernia. *Tech Coloproctol* 2007;**11**(3):283–5.
- El Saadi AS, Al Waden AH, Hamerna S. Approach to a giant inguinoscrotal hernia. *Hernia* 2005;**9**(3):277–9.
- Ek EW, Ek ET, Bingham R, Wilson J, Mooney B, Banting S, et al. Component separation in the repair of a giant inguinoscrotal hernia. *ANZ J Surg* 2006;**76**(10):950–2.
- Imisairi AH, Hadi SM. Giant inguinal hernia. *ANZ J Surg* 2011;**81**(6):488.
- King JN, Didlake RH, Gray RE. Giant inguinal hernia. *South Med J* 1986;**79**(2):252–3.
- Patsas A, Tsiaousis P, Papaziogas B, Koutelidakis I, Goula C, Atmatzidis K. Repair of a giant inguinoscrotal hernia. *Hernia* 2010;**14**(3):305–7.
- Vasiliadis K, Knaebel HP, Djakovic N, Nyarangi-Dix J, Scahmidt J, Bucher M. Challenging surgical management of a giant inguinoscrotal hernia: report of a case. *Surg Today* 2010;**40**(7):684–7.
- Moreno IG. Chronic eventrations and large hernias; preoperative treatment by progressive pneumoperitoneum; original procedure. *Surgery* 1947;**22**(6):945–53.
- Connolly DP, Perri FR. Giant hernias managed by pneumoperitoneum. *J Am Med Assoc* 1969;**209**:71–4.
- Mayagoitia JC, Suarez D, Arenas JC, Diaz de Leon V. Preoperative progressive pneumoperitoneum in patients with abdominal-wall hernias. *Hernia* 2006;**10**(3):213–7.
- Piskin T, Aydin C, Barut B, Dirican A, Kayaalp C. Preoperative progressive pneumoperitoneum for giant inguinal hernias. *Ann Saudi Med* 2010;**30**(4):317–20.
- Merrett ND, Waterwoth MW, Green MF. Repair of giant inguinal hernia using marlex mesh and scrotal skin flap. *ANZ J Surg* 1994;**64**(5):380–3.
- El Dessouki NI. Preperitoneal mesh hernioplasty in giant inguinoscrotal hernias: a new technique with dual benefit in repair and abdominal rooming. *Hernia* 2001;**5**(4):177–81.

Open Access

This article is published Open Access at sciedirect.com. It is distributed under the [IJSCR Supplemental terms and conditions](#), which permits unrestricted non commercial use, distribution, and reproduction in any medium, provided the original authors and source are credited.