

A Rare Case of Neuromuscular Oculoauditory Syndrome

To the editor,

An 18-month-old male child presented with complaints of not being able to fixate on objects and hard of hearing since 4 months of age. He is third born of a nonconsanguineous marriage and his two elder sisters are asymptomatic. His mother had two abortions at 3 months and 4 months of gestation. He was a term child with a birth weight of 2.6 kg; his antenatal period and perinatal transition were uneventful. He attained head control at 6 months, rolling over at 8 months, sitting with support at 10 months and could walk without support by 18 months of age (DQ = 83%). He could recognize mother by 6 months and developed stranger anxiety by 7 months of age. He had not attained separation anxiety (DQ = 33%). He currently uses monosyllables (DQ = 33%) and had a mature pincer grasp (DQ = 66%).

Child was noticed to have infantile spasms during the hospital stay [Video 1]. On probing, the mother gave a history of similar episodes noticed 3 to 4 times per week for the last 4 months associated with ictal cry. On examining, he had variable tone, predominantly hypotonic and reflexes were elicitable. He had bilateral hearing loss. Ophthalmological examination revealed bilateral perception of light rays, nystagmus and bilateral retinal pigmentary mottling with amaurotic pupils, rising a clinical suspicion of Leber's congenital amaurosis (LCA). We had also kept a possibility of neuronal ceroid lipofuscinosis (NCL). Visual evoked potential showed abnormal N2P2 latencies with normal amplitude [Figure 1]. An electroretinogram to confirm LCA was planned. However, it could not be done successfully due to age constraints, nystagmus and the inability to fixate. Brainstem evoked response audiometry (BERA) revealed bilateral severe sensorineural hearing loss. MRI (magnetic resonance imaging) of the brain with MRS (magnetic resonance spectroscopy) was normal. EEG (electroencephalogram) suggested modified hypsarrhythmia [Figure 2]. He was started on prednisolone and valproate following which frequency of spasms reduced.

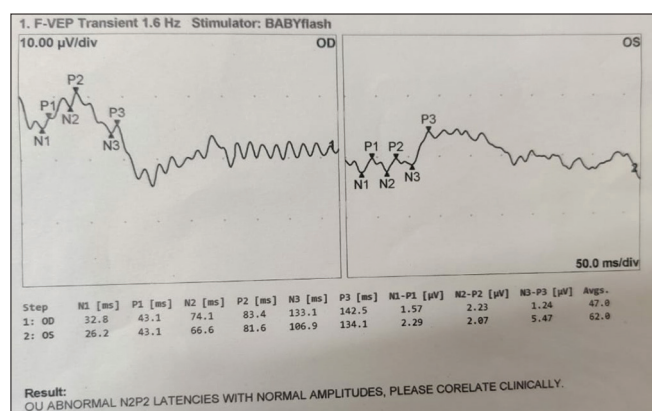


Figure 1: Visual evoked potential showing abnormal N2P2 latencies

Clinical exome sequencing was sent which tested negative for all reported genes of LCA and NCL. It revealed a variant of unknown significance with heterozygous missense variation in exon 9 of the DHX16 gene (chr6:g.30662726C>T; Depth: 200x) that results in the amino acid substitution of histidine for arginine at codon 482 (p.Arg482His; ENST00000376442.8). Only 4 cases have been reported in literature till date.^[1] The p.Arg482His variant has not been detected so far.

A possible diagnosis of LCA was thought of. He was also noticed to have frequent stereotypic poking, pressing and rubbing of eyelids, which is often seen in LCA. The mechanism is not well understood but could be due to the generation of phosphenes which satisfy the patient by bringing up sparks of light (Franceschetti's oculo-digital sign).^[2,3] Mental retardation and seizures have been reported in 17% of cases of LCA.^[3] But infantile spasms have not been reported in LCA yet and hearing loss in LCA is less likely. Other associations of LCA like Senior Loken syndrome and Joubert syndrome were also considered.^[4] A likelihood of Batten's disease (NCL) was kept in mind in view of infantile onset visual loss, nystagmus with developmental delay and seizures, however, imaging was normal. We had also kept a plausibility of Alstrom syndrome since it can present with visual loss in infancy, nystagmus, retinal degeneration, hearing loss, seizures and developmental delay.^[3]

Neuromuscular oculo auditory syndrome (NMOAS) (OMIM: 603405) is caused by a heterozygous mutation in DHX16 gene on chromosome 6p21 which can arise *de novo*. It can also be autosomal dominant in inheritance (OMIM: 618733). Treatment for this condition is largely supportive with the institution of early intervention services. Until now, 4 individuals with mutation in DHX16 have been reported, of which 3 had *de novo* mutations. Three individuals share features of Central Nervous System (CNS) anomalies and seizures. The first individual was a female who presented with agenesis of the corpus callosum, seizures, and chorioretinal lacunae. Trio Exome Sequencing (Trio-ES) identified a variant in DHX16 (GenBank:

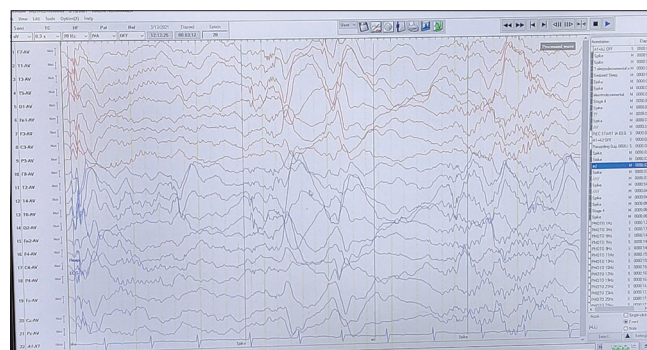


Figure 2: EEG showing modified hypsarrhythmia

NM_003587.4; c.1744T>A [p.Phe582Ile]). The second individual was a female who presented with dysmorphic features and cystic kidneys; she died on day of life 16. Trio ES identified a variant in DHX16 (GenBank: NM_003587.4; c.2091G>T [p.Gln697His]). The third individual presented with severe hypotonia and joint contractures, sensorineural deafness, a mixed axonal sensory and demyelinating motor neuropathy with feeding difficulties, and growth delay. He died at 4 months of age due to respiratory failure. Trio-ES identified a de novo variant in DHX16 (GenBank: NM_003587.4; c.1280G>A [p.Gly427Glu]). The fourth individual was a male who presented with tonic-clonic seizures, neuropathy, myopathy, developmental delay without intellectual disability, and retinopathy. Trio ES found a de novo variant in DHX16 (GenBank: NM_003587.4; c.2021C>T [p.Thr674Met]).

In conclusion, NMOAS can have varied presentations and can be suspected in a young infant with weakness, seizures, blindness and deafness. Early recognition is important to aid in reproductive counselling.

Informed consent

Written informed consent for publication of the child's clinical details was obtained from the concerned parents.

Financial support and sponsorship

Nil.

Conflicts of interest

There are no conflicts of interest.

Arumugom Archana, Tamil Selvan, Venkatraman R. Kumar, Abinaya K, Nirupama Kasturi¹

Departments of Pediatrics and ¹Ophthalmology, Jawaharlal Institute of Postgraduate Medical Education and Research (JIPMER), Pondicherry, India

Address for correspondence: Dr. Tamil Selvan, Professor, Department of Pediatrics, Jawaharlal Institute of Postgraduate Medical Education and Research (JIPMER), Pondicherry---605 006, India.
E-mail: drselvntg@yahoo.com

REFERENCES

1. Paine I, Posey JE, Grochowski CM, Jhangiani SN, Rosenheck S, Kleyner R, *et al.* Paralog studies augment gene discovery: DDX and DHX genes. *Am J Hum Genet* 2019;105:302-16.
2. Chacon-Camacho OF, Zenteno JC. Review and update on the molecular basis of Leber congenital amaurosis. *World J Clin Cases* 2015;3:112-24.
3. Den Hollander AI, Roepman R, Koenekoop RK, Cremers FP. Leber congenital amaurosis: Genes, proteins and disease mechanisms. *Prog Retin Eye Res* 2008;27:391-419.
4. Kumaran N, Moore AT, Weleber RG, Michaelides M. Leber congenital amaurosis/early-onset severe retinal dystrophy: Clinical features, molecular genetics and therapeutic interventions. *Br J Ophthalmol* 2017;101:1147-54.

Video available on: www.annalsofian.org

Submitted: 20-Jan-2022 **Revised:** 14-Jun-2022 **Accepted:** 15-Jun-2022

Published: 15-Jul-2022

This is an open access journal, and articles are distributed under the terms of the Creative Commons Attribution-NonCommercial-ShareAlike 4.0 License, which allows others to remix, tweak, and build upon the work non-commercially, as long as appropriate credit is given and the new creations are licensed under the identical terms.

DOI: 10.4103/aian.aian_67_22