

Exacerbation of IgA nephropathy in a patient receiving dupilumab



Masako Yamamoto, MD,^a Yuriko Kawase, MD, PhD,^a Emi Nakajima, MD, PhD,^b Yoshiaki Matsuura, MD, PhD,^b Wataru Akita, MD, PhD,^b Ryouusuke Aoki, MD, PhD,^c Yusuke Suzuki, MD, PhD,^c and Hiroshi Mitsui, MD, PhD^d
Tokyo, Japan

Key words: atopic dermatitis; dupilumab; IgA nephropathy; renal dysfunction; toll-like receptor.

INTRODUCTION

Dupilumab is the first targeted antibody drug that inhibits the type 2 cytokines interleukin (IL) 4 and IL-13. It has become an essential agent for treating moderate to severe atopic dermatitis (AD) in recent years.¹ Dermatologists consider dupilumab to have a good safety profile and to be less likely to cause renal adverse effects. However, we describe a case in which decreased renal function became apparent after starting dupilumab treatment.

CASE REPORT

A 55-year-old Japanese woman had AD since early childhood. There were no major diseases other than AD, but slight hematuria and proteinuria were first noted during a transient fever 2 years ago. At that time, her serum creatinine level was 0.9 mg/dL. She had not been diagnosed with glomerulonephritis. For AD, skin symptoms were primarily treated using topical steroidal ointments, topical tacrolimus, and oral fexofenadine. However, the AD was insufficiently controlled. From the age of 53 years and 11 months, the patient received dupilumab injections at a maintenance dose of 300 mg every other week (Fig 1). The calculated Eczema Area and Severity Index score decreased from 21.2 to 1.4 after 5 months of therapy. The patient maintained Eczema Area and Severity Index 90 for the next 4 months. Although the eczema improved, hematuria and proteinuria progressively increased after dupilumab therapy initiation, and her serum creatinine levels increased from 0.92 to 1.93 mg/dL during the 9 months of treatment (Fig 1). Serum antibodies

Abbreviations used:

AD:	atopic dermatitis
Gd-IgA1:	undergalactosylated IgA1
IgA-N:	IgA nephropathy
IL:	interleukin
RF:	rheumatoid factor
Th:	helper T
TLR:	toll-like receptor

against the following autoantigens were negative: nucleus, neutrophil cytoplasm, and glomerular basement membrane. Antibodies against hepatitis B and C virus were negative. Serum IgA and C-reactive protein were in the normal range throughout the dupilumab treatment. The patient stopped dupilumab injections at 54 years and 9 months. After dupilumab discontinuation, a renal biopsy revealed primary IgA nephropathy (IgA-N) (Figs 2 and 3). The serum creatinine level declined slightly to 1.78 mg/dL 3 months after discontinuing dupilumab before administering systemic steroids.

The patient underwent bilateral tonsillectomy and steroidal pulse therapy for glomerulonephritis. The tonsillectomy was conducted for the purpose of lowering the concentration of pathognomonic IgA antibody. After finishing steroidal pulse therapy, the patient received oral prednisone 30 mg once every 2 days for 2 months.

From 1 year before starting dupilumab treatment, blood analysis showed a slightly elevated serum IgM-rheumatoid factor (RF) level. Serum IgM-RF levels increased from 46 to 130 IU/mL during 9 months of dupilumab treatment and decreased to

From the Department of Dermatology,^a and Department of Nephrology, Fraternity Memorial Hospital, Tokyo, Japan^b; Department of Nephrology, Juntendo University Graduate School of Medicine, Tokyo, Japan^c; and Department of Dermatology, Tokyo Teishin Hospital, Tokyo, Japan.^d

Funding sources: None.

IRB approval status: We acknowledge that the case report was prepared in accordance with Declaration of Helsinki.

Correspondence to: Yuriko Kawase, MD, PhD, Department of Dermatology, Fraternity Memorial Hospital, 2-1-11 Yokoami,

Sumida-ku, Tokyo 130-8587, Japan. E-mail: yurikokawase20@gmail.com.

JAAD Case Reports 2022;21:150-3.

2352-5126

© 2022 by the American Academy of Dermatology, Inc. Published by Elsevier, Inc. This is an open access article under the CC BY-NC-ND license (<http://creativecommons.org/licenses/by-nc-nd/4.0/>).

<https://doi.org/10.1016/j.jidcr.2022.01.009>

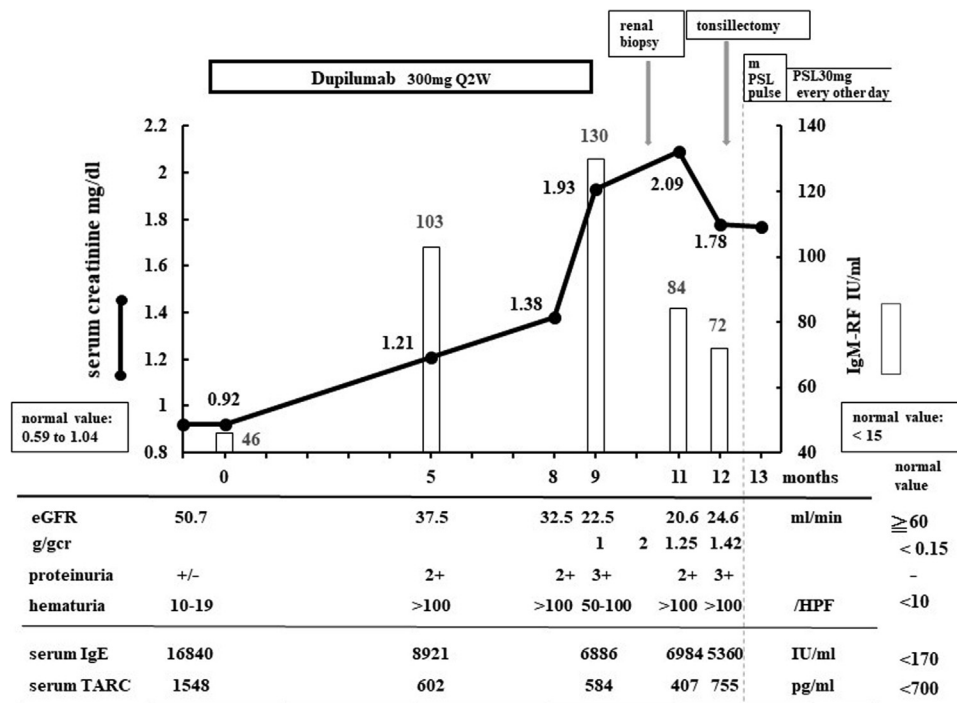


Fig 1. Clinical and laboratory course of the case. The serum creatinine levels were elevated during dupilumab treatment and did not completely normalize even after discontinuing injections because of irreversible destruction of approximately half of the glomeruli (Fig 2). Proteinuria, +/-: 0.2 to 0.4 g/day, 2+: 1.5 to 4.4 g/day, 3+: 4.5 to 14.9 g/day; hematuria, /HPF: number of red blood cells/high power field. *eGFR*, Estimated glomerular filtration rate; *PSL*, prednisolone; *TARC*, thymus and activation-regulated chemokine.

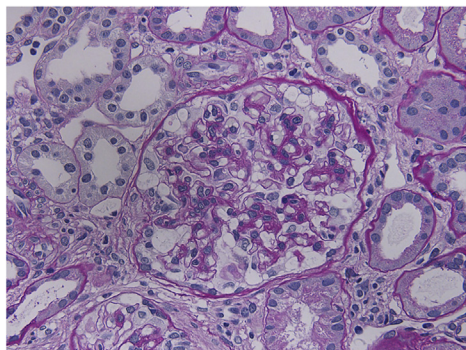


Fig 2. Renal biopsy. The histology shows mesangial expansion and hypercellularity. There was no amyloid deposit on the glomerulus or tubule interstitium. Four of the 27 glomeruli revealed complete sclerosis, and 5 of the 27 glomeruli showed focal segmental sclerosis. Four glomeruli showed cellular crescents, 2 had fibrocellular crescents, and 5 had fibral crescents. (Histologic grade III; periodic acid–Schiff stain; original magnification: ×400.)

72 IU/mL 3 months after discontinuing dupilumab before the administration of systemic steroids (Fig 1). Serum anticyclic citrullinated peptide antibody was negative before and during dupilumab therapy. The

patient had no complaints of arthralgia throughout the treatment.

DISCUSSION

During clinical trials and the 3-year postmarketing surveillance, no patient discontinued dupilumab because of renal impairment.¹ Therefore, we initially believed that dupilumab and renal damage were unrelated in our case. Before treatment, our patient had no diagnosis of glomerulonephritis but did have minor renal dysfunction. After starting dupilumab, the patient showed a rapid renal deterioration compared with the general course of IgA-N, whereby renal function gradually declines over 10 to 30 years.² The rapid decline in the renal function suddenly stopped after dupilumab withdrawal. Ultimately, we suspected that the IL-4 receptor α inhibitor might have played a role in IgA-N exacerbation.

IgA-N is a complex disease involving various immune responses.² The so-called “four-hit” theory is an explanatory hypothesis for the process of developing IgA-N.² First is the overproduction of undergalactosylated IgA1 (Gd-IgA1). Second is the

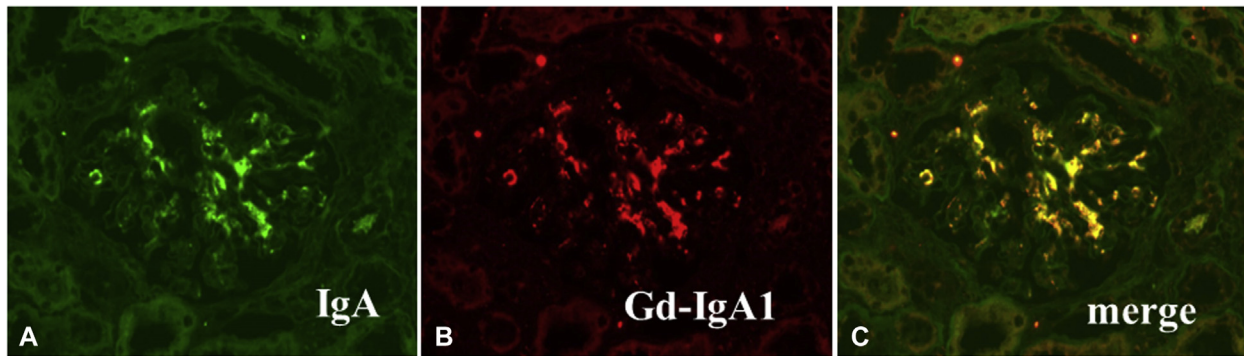


Fig 3. **A**, Immunofluorescence staining for IgA showed positive luminescence in the mesangium. **B**, Undergalactosylated IgA1 colocalized with IgA. This result provided the diagnosis of primary IgA nephropathy. (**A**, Immunofluorescence stain; **B**, monoclonal antibody KM55; original magnifications: **A**, $\times 400$; **B**, $\times 400$; **C**, Merged figure of **A** and **B**, $\times 400$.)

production of IgG antibody, which specifically binds to the aberrant Gd-IgA1. Third is the deposition of immune complexes in the kidney glomeruli. Fourth is inflammation in the lesion. IL-4 stimulates the production of Gd-IgA1 in the first process and promotes inflammation in the final process. Helper T (Th)17, Th22, and cytotoxic T cells are also involved in the fourth process.²

Because excessive Th2 cell activity is associated with IgA-N onset and progression, dupilumab is one of the proposed biologic agents for treating IgA-N.² Tanczosova et al³ reported a patient with both AD and IgA-N in whom symptoms of both diseases improved with dupilumab treatment. The authors explained that the improvement was the result of serum IgE levels decreasing from 12500 to 3490 IU/mL within 9 months.³ Although in our patient serum IgE levels reduced from 16840 to 6984 IU/mL within a similar timeframe, there was an unpredicted worsening of IgA-N. The reason for this converse finding remains unknown. More patient data are needed to confirm whether dupilumab is effective in IgA-N because of the clinical heterogeneity of the disease.²

In our case, there are 2 possible etiologies for dupilumab being involved in the development of IgA-N. First, the immunologic effect of dupilumab induces the activation of Th17 cells, leading to glomerular injury. Dupilumab very rarely causes autoimmune adverse effects, but cases of enthesitis and arthritis have been reported.⁴ The authors of these cases noted that the activation of Th17 cells might have been related to pathogenesis. We presumed a similar mechanism in IgA-N development, but this remains unclear.

Second, IL-4 neutralization activates toll-like receptor (TLR) signaling, promoting excess Gd-IgA1 production in B cells. In recent years, there have been

multiple reports that innate immunity plays a considerable role in the pathogenesis of IgA-N. In humans, TLR9 activation promotes Gd-IgA1 production in IgA-N.^{5,6} Moreover, human CD19⁺TLR7⁺ B cells produce causative antibodies and infiltrate renal tissue.⁶ Because IL-4 suppresses TLR function, removing the suppression of TLR signaling by dupilumab might promote excess production of Gd-IgA1 and eventually exacerbate IgA-N.⁷ Unfortunately, we have no direct data to prove this inference. Instead, in our case, there was an elevation of serum IgM-RF levels in synchrony with serum creatinine levels. There have been many IgA-N cases with high IgM-RF levels without rheumatism, but no attention has been paid to whether the levels are related to IgA-N progression. Our case may provide an indirect clue indicating the involvement of TLRs because TLR signaling activation also induces IgM-RF overexpression by innate immune B cells.⁸ Storan et al⁹ reported 4 patients with AD with molluscum contagiosum lesions that regressed after receiving dupilumab. The authors suggested probable involvement of plasmacytoid dendritic cells in virus elimination, which require TLR7/9 to exert their function.¹⁰

We thank Helen Robertson from Edanz (<https://jp.edanz.com/ac>) for editing a draft of this manuscript.

Conflicts of interest

None disclosed.

REFERENCES

1. Beck LA, Thaçi D, Deleuran M, et al. Dupilumab provides favorable safety and sustained efficacy for up to 3 years in an open-label study of adults with moderate-to-severe atopic dermatitis. *Am J Clin Dermatol*. 2020;21:567-577.
2. Magistroni R, D'Agati VD, Appel GB, Kiryluk K. New developments in the genetics, pathogenesis, and therapy of IgA nephropathy. *Kidney Int*. 2015;88:974-989.

3. Tanczosova M, Arenberger P, Rychlik I, Arenbergerova M, Gkalpakiotis S. Improvement of atopic dermatitis and IgA nephropathy in a patient treated by dupilumab. *Dermatol Ther.* 2021;34:e14708.
4. Willmore ZN, Woolf RT, Hughes C, et al. Development of inflammatory arthritis and enthesitis in patients on dupilumab: a case series. *Br J Dermatol.* 2019;181:1068-1070.
5. Muto M, Manfroi B, Suzuki H, et al. Toll-like receptor 9 stimulation induces aberrant expression of a proliferation-inducing ligand by tonsillar germinal center B cells in IgA nephropathy. *J Am Soc Nephrol.* 2017;28:1227-1238.
6. Zheng N, Xie K, Ye H, et al. TLR7 in B cells promotes renal inflammation and Gd-IgA1 synthesis in IgA nephropathy. *JCI Insight.* 2020;5:e136965.
7. Sriram U, Xu J, Chain RW, et al. IL-4 suppresses the responses to TLR7 and TLR9 stimulation and increases the permissiveness to retroviral infection of murine conventional dendritic cells. *PLoS One.* 2014;9:e87668.
8. Hardy RR, Hayakawa K, Shimizu M, Yamasaki K, Kishimoto T. Rheumatoid factor secretion from human Leu-1+ B cells. *Science.* 1987;236:81-83.
9. Storan ER, Woolf RT, Smith CH, Pink AE. Clearance of molluscum contagiosum virus infection in patients with atopic eczema treated with dupilumab. *Br J Dermatol.* 2019;181:385-386.
10. Gilliet M, Cao W, Liu YJ. Plasmacytoid dendritic cells: sensing nucleic acids in viral infection and autoimmune diseases. *Nat Rev Immunol.* 2008;8:594-606.