

ORIGINAL ARTICLE

# Quantitative analysis of T2 relaxation times of the patellofemoral joint cartilage 3 years after anterior cruciate ligament reconstruction



Chang-Wan Kim <sup>a,b</sup>, Ali Hosseini <sup>a</sup>, Lin Lin <sup>a,c</sup>, Yang Wang <sup>d</sup>,  
Martin Torriani <sup>e</sup>, Thomas Gill <sup>a</sup>, Alan J. Grodzinsky <sup>d</sup>,  
Guoan Li <sup>a,\*</sup>

<sup>a</sup> Orthopaedic Biomechanics Laboratory, Newton-Wellesley Hospital/Harvard Medical School, Newton, MA, USA

<sup>b</sup> Department of Orthopedic Surgery, Busan Paik Hospital, Inje Medical School, Inje University, Busan, Republic of Korea

<sup>c</sup> Institute of Sports Medicine, Peking University Third Hospital, North Garden Road, Haidian District, Beijing, 100191, PR China

<sup>d</sup> Department of Bioengineering, Massachusetts Institute of Technology, Cambridge, MA, USA

<sup>e</sup> Division of Musculoskeletal Imaging and Intervention, Massachusetts General Hospital and Harvard Medical School, Boston, MA, USA

Received 31 March 2017; received in revised form 8 June 2017; accepted 15 June 2017  
Available online 2 July 2017

## KEYWORDS

ACL;  
ACL reconstruction;  
cartilage;  
patellofemoral joint;  
T2 mapping

**Summary Objective:** To evaluate patient-specific patellofemoral joint (PFJ) cartilage 3 years postoperatively using T2 mapping magnetic resonance imaging and the uninjured contralateral side as control.

**Hypothesis:** The cartilage of the PFJ in the anterior cruciate ligament (ACL) reconstructed knees would show increased T2 values compared to the uninjured contralateral knees at 3-year follow-up, and the femoral (trochlear) cartilage would be more susceptible than the patella in degeneration in ACL-reconstructed knees.

**Methods:** Ten patients with clinically successful ACL-reconstructed knees were prospectively enrolled 3 years postoperatively. Sagittal images of both knees were obtained using T2 mapping. Cartilage over the medial, central, and lateral regions of the trochlea and patella was divided into superficial and deep regions. Average T2 values of the cartilage at each region

\* Corresponding author. Orthopaedic Biomechanics Laboratory, Newton-Wellesley Hospital/Harvard Medical School, Newton, MA, USA.  
E-mail address: [gli1@partners.org](mailto:gli1@partners.org) (G. Li).

of interest of the ACL-reconstructed and uninjured contralateral knees were compared for each individual patient.

**Results:** Overall, the T2 values at the superficial layers of the medial and central trochlear cartilage of the ACL-reconstructed knees were significantly higher than those of the uninjured contralateral knees by  $4.23 \pm 9.09$  milliseconds (8.9%;  $p = 0.043$ ) and  $5.94 \pm 8.12$  milliseconds (10.9%;  $p = 0.019$ ), respectively. No significant difference was found in other cartilage areas of the trochlea and patella. In individual patient analysis, increased T2 values of ACL-reconstructed knees were found in all 10 patients in at least one superficial region and eight patients in at least one deep region of the trochlear cartilage, five patients in at least one superficial region, and eight patients in at least one deep region of the patellar cartilage.

**Conclusion:** Despite a clinically satisfactory ACL reconstruction (with negative anteroposterior drawer and pivot shift tests), all patients showed at least one region with increased T2 value of the PFJ cartilage 3 years after ACL reconstruction, especially at the medial compartment of the trochlear cartilage.

**The Translational Potential of this Article:** Little data has been reported on PFJ cartilage condition after ACL reconstruction. This study could help develop noninvasive diagnostic methods for detection of early PFJ cartilage degeneration after ACL reconstruction.

© 2017 The Authors. Published by Elsevier (Singapore) Pte Ltd on behalf of Chinese Speaking Orthopaedic Society. This is an open access article under the CC BY-NC-ND license (<http://creativecommons.org/licenses/by-nc-nd/4.0/>).

## Introduction

While satisfactory clinical outcomes regarding the functional stability of the knee after anterior cruciate ligament (ACL) reconstruction have been widely reported, recent mid- to long-term follow-up studies have revealed prevalent development of radiographic osteoarthritis (OA) in ACL-reconstructed knees [1–6]. Although numerous studies have reported on the development of OA in the tibiofemoral joint (TFJ) after ACL reconstruction, postoperative radiographic OA in the patellofemoral joint (PFJ) has been reported in 11–90% (median 36%) of patients 2–15 years after the surgery [1,4,6]. Radiographic PFJ OA may be more common than TFJ OA and associated with worse knee-related symptoms, including anterior knee pain and decreased functional performance [7,8].

Any interventions targeted at preventing OA development after ACL reconstruction—at its earliest and responsive (i.e., reversible) stage—would therefore be of the greatest value to the young patient population with ACL injuries. Considerable progress has been made in recent years by detecting changes in the biochemical compositions of cartilage using magnetic resonance imaging (MRI) techniques such as T1 $\rho$ , T2, dGEMRIC, and sodium MRI [9–18]. Changes in collagen integrity, proteoglycan, and water contents are some of the most broadly discussed histological measurements of cartilage degradation and early indicators of cartilage degeneration [9,10,13,14,18]. Recent studies have focused on correlations between T1 $\rho$  values and proteoglycan content, and between T2 values and water/collagen content [10,13–15]. Significant differences in the average of T1 $\rho$  and T2 values between asymptomatic and osteoarthritis symptomatic patients were reported [11,16,19–21]. However, most of these advanced MRI investigations of early knee OA have been focused on the TFJ. Using these advanced MRI techniques to detect early onset

OA of the PFJ of the knee after ACL reconstruction is yet to be investigated.

Therefore, the objective of this study was to quantitatively evaluate the biochemical composition changes of the articular cartilage of the PFJ after ACL reconstruction using T2 relaxation times (T2 mapping) at 3-year follow-up. The uninjured, contralateral knee was used as a control for comparison. This technique has been used previously to investigate early OA of the TFJ cartilage after ACL reconstruction [19]. In this study, we hypothesized that: (1) the cartilage of the PFJ in the ACL-reconstructed knees would show increased T2 values compared to the uninjured contralateral knees at 3-year follow-up; and (2) the femoral (trochlear) cartilage would be more susceptible than the patella in degeneration in ACL-reconstructed knees.

## Methods

### Patients

Ten patients (20 knees) who underwent ACL reconstruction due to unilateral ACL rupture were recruited at 3 years after surgery (Partners Human Research Committee, 2003P000337/PHS). The inclusion criteria were an acute unilateral ACL rupture without other ligament injury, no evidence of cartilage damage at the time of ACL injury confirmed by MRI and arthroscopy, less than 4 months from injury to surgical operation, and no history of injury or pain on the contralateral knee. No patients had additional injury to either knee after ACL reconstruction.

This study complied with the Declaration of Helsinki after obtaining approval from the Institutional Review Board of the local institution. A written informed consent was obtained from each patient before any test.

## Surgery

Arthroscopic ACL reconstructions were performed within 4 months after injury, by a single surgeon using a modified transtibial technique. All ACL reconstructions were performed through the usual sequences: arthroscopic examination, identification of ACL rupture site and removal of ruptured ACL, graft preparation, tibial tunnel preparation (using 55° tibial guide), femoral tunnel preparation (using offset guide centred at the 10:30 position for right knees or 1:30 for left knees), graft passage, femoral side fixation, cyclic loading, graft tensioning with full extension position, tibial side fixation, and wound closure. Eight patients were operated on using patella tendon grafts (fixed using interference screws) and two patients (Patient 6 and Patient 10 in Table 1) using quadruple hamstring tendon grafts (fixed using EndButton techniques). At the time of ACL reconstruction, partial medial meniscus tears were found in two patients, partial lateral meniscus tears in five patients, and both partial medial and lateral meniscus tears in one patient. All the meniscus tears were treated with partial (less than one third) meniscectomy (Table 1).

Postoperatively, we applied a simple knee brace for immobilization of the knee joint. Isometric exercises of the quadriceps muscle were started from the next day of surgery. Range of motion of the knee and weight-bearing exercise were started 3–4 days after the surgery, with gradual progression. Full weight-bearing without a crutch was encouraged within the first 4 weeks. Various sporting activities were allowed between 6 months and 9 months after surgery, if the patient had achieved at least 80% of the knee extension strength of the uninjured leg. Three years after surgery, the patients were recruited and evaluated using the Tegner activity level scale, the Lysholm knee scoring scale, and the knee injury and osteoarthritis outcome score (KOOS) for clinical evaluation, and an MRI scan for T2 mapping on both knees.

## Imaging protocols

All knees were scanned using a 3T MR scanner with an eight-channel knee coil (Magnetom Trio, Siemens, Malvern, PA,

USA) at 3 years (range 42–50 months) after ACL reconstruction. Before scanning, the patient rested in a relaxed sitting position for 1 h to minimize the weight-induced compression of the cartilage. During scanning, the patient laid supine with both knees in a fully relaxed extension position and scanned at the same session. A multiple-echo time (TE) fast-spin echo sagittal pulse sequence was used for T2 relaxometry images. The method to obtain T2 images was as follows. Repetition time: 1700 milliseconds; 10 echo times (10.6, 21.2, 31.8, 42.4, 53.0, 63.6, 74.2, 84.8, 95.4, and 106 milliseconds); matrix: 384 × 384; field of view: 18 cm × 18 cm; slice thickness: 3.0 mm; slice gap: 0 mm; number of slices: 26–30; bandwidth: 250 Hz/pixel; and total scan time: 11 min per knee. The same imaging parameters were used for both knees of each patient.

## Cartilage segmentation and quantification of T2 relaxation times

Quantifications of the T2 relaxation time were conducted using the open-source DICOM viewer software (OsiriX; Pixmeo Sarl, Bernex, Switzerland). The articular cartilage of the PFJ was evenly divided into three compartments: medial compartment, lateral compartment, and central compartment. We outlined the articular cartilage of the patella and trochlea without any subchondral bone and synovial fluid. Each compartment of the cartilage was evenly divided into two layers, representing superficial and deep layers [or region of interest (ROI)]. The T2 time was measured for each pixel of the cartilage (Figure 1). ROI analysis was performed on two consecutive slice images on each compartment from the areas with largest sagittal cross-sectional dimension of the PFJ. The average of the T2 values of the consecutive images was defined as the T2 value of the ROI. The first echo time images in each calculation were excluded to avoid overestimation of T2 values [11,19].

## Data analysis

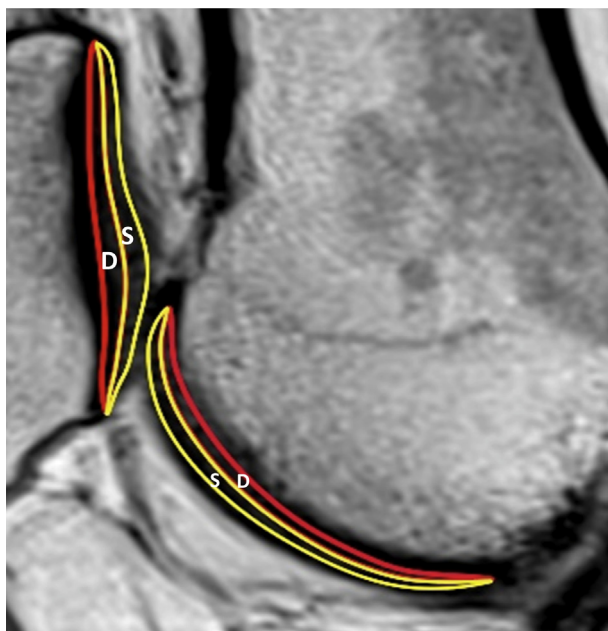
This was a prospective, single-cohort, case series study. Average T2 value changes of all patients at each

**Table 1** Preoperative patient characteristics.

Patients	Sex/age (y)	BMI (kg/m <sup>2</sup> )	Injured knee	Meniscus tear	Treatment of meniscus tear	Follow-up duration (mo)
1	F/31	25.1	Left	LMPH	Partial meniscectomy	43
2	M/32	23.6	Right	LMPH	Partial meniscectomy	44
3	M/28	26.4	Right	LMPH	Partial meniscectomy	45
4	M/34	27.3	Left	NONE	No	44
5	M/43	27.4	Left	MMPH	Partial meniscectomy	43
6	M/46	30.8	Right	MMPH/LMAH	Partial meniscectomy	46
7	F/20	22.8	Right	NONE	No	42
8	M/25	25.8	Right	MMAH	Partial meniscectomy	50
9	M/36	35.9	Left	LMMB	Partial meniscectomy	44
10	F/43	29.3	Right	LMMB	Partial meniscectomy	45

Patients 6 and 10 were reconstructed using Hamstring tendon grafts and other using BPTB grafts.

AH = anterior horn; BMI = body mass index; F = female; LM = lateral meniscus; M = male; MB = midbody; MM = medial meniscus; NONE = no meniscal tear; PH = posterior horn.



**Figure 1** Regions of interest of the patellofemoral joint cartilage. D = deep layer; S = superficial layer.

individual ROI were analysed. For individual patient analysis, we defined an increase of T2 value by larger than 3% compared to the contralateral side as a risk factor for OA. Previous studies have found that normal controls have between 3% and 12% lower T2 values than individuals with OA or risk factors for OA [22–24]. All data analyses were performed with SPSS statistical software, version 21.0 (SPSS Inc., Chicago, IL, USA). Descriptive statistics, including the mean, standard deviation, and 95% confidence interval were calculated for T2 values of each ROI in each compartment. T2 values of both the superficial layer and deep layer of the cartilage of the ACL-reconstructed knee were compared to those of the uninjured contralateral knee. A repeated measure analysis of variance with the Newman–Keuls test was used for the *post hoc* test. A *p* value < 0.05 was considered to be statistically significant.

## Results

### Patient evaluation data

At 3-year follow-up after ACL reconstruction, all patients had a normal range of motion, a negative Lachman test, a negative pivot shift test, and a less than 3 mm anterior laxity compared with the contralateral uninjured knee using a KT-1000. Seven patients had excellent Lysholm scores (> 90) and three patients had fair scores (65–83). Seven patients had returned to the same pre-injury level of sports activities or one level lower in the Tegner activity level scale. There were wide variations in KOOS. Eight patients reported occasional pain in the ACL-reconstructed knees after moderate or higher level of activities (Table 2).

### T2 values

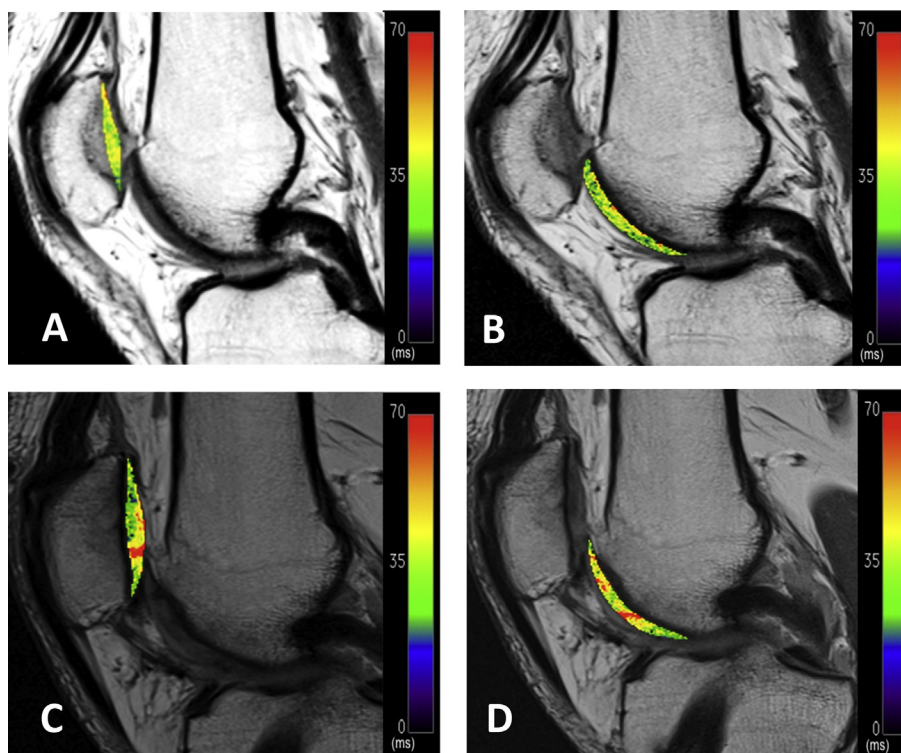
The map of the T2 time values of the trochlear and patellar cartilage are shown in Figure 2. In the medial and central trochlear regions of the ACL-reconstructed knees, the superficial layer of the cartilage had significantly higher T2 values than those of the uninjured contralateral side by  $4.23 \pm 9.09$  milliseconds (8.9%;  $p = 0.043$ ) and  $5.94 \pm 8.12$  milliseconds (10.9%;  $p = 0.019$ ), respectively (Figure 3). There were no statistically significant changes in T2 values of the lateral compartment of the superficial trochlear cartilage layer and the entire deep trochlear cartilage of the knee after ACL reconstruction. At the patella, no statistically significant changes were detected at the superficial and deep layers in the medial compartment, central compartment, and lateral compartment of the cartilage (Figure 3).

In individual patient analysis of the trochlear cartilage (Table 3), overall, 10 patients had increased T2 values in at least one area of the superficial layer and eight patients had increased T2 values in at least one area of the deep layer of the trochlear cartilage. In the patellar cartilage, five patients had increased T2 values in at least one area of the superficial layer and eight had increased T2 values in at least one area of the deep layer.

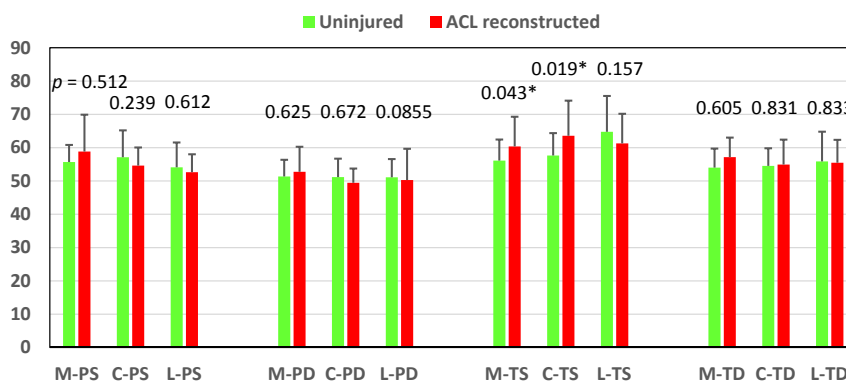
**Table 2** Clinical scores after 3 years of anterior cruciate ligament (ACL) reconstruction.

Patients	Tegner (Pre-injury)	Tegner (3 y)	Lysholm (3 y)	KOOS pain	KOOS symptoms	KOOS ADL	KOOS sport/rec	KOOS QOL
1	7	6	91	94.4	96.4	98.5	95	87.5
2	6	5	100	94.4	89.3	98.5	85	75
3	7	7	90	97.2	96.4	98.5	95	87.5
4	7	6	95	80.6	82.1	97.1	60	62
5	7	7	96	100	89.3	100	100	81.3
6	5	6	100	100	100	100	100	100
7	10	5	78	86.1	92.9	91.2	80	81.3
8	8	5	73	77.8	67.8	95.6	40	43.8
9	8	7	70	58.3	64.3	61.8	65	56.3
10	10	10	94	100	100	97.1	100	100

3 y = 3-year follow-up after ACL reconstruction; ADL = activity of daily living; KOOS = knee injury and osteoarthritis outcome score; Lysholm = Lysholm knee scoring scale; QOL = quality of life; rec = recreational sports; Tegner = Tegner activity level scale.



**Figure 2** Color-coded, sagittal plane T2 maps of the medial patellofemoral joint compartment of a typical patient. (A) Patella and (B) trochlear of the contralateral knee; (C) patella and (D) trochlear of the anterior cruciate ligament (ACL)-reconstructed knee. Note that the elevated T2 values of the ACL-reconstructed knee were compared to the contralateral side.



**Figure 3** Mean T2 values of each region of interest of the patellar and trochlear articular cartilage layers. Mean  $\pm$  error bars; 95% confidence intervals. C = central region; L = lateral region; M = medial region; PD = deep layer of patellar cartilage; PS = superficial layer of patellar cartilage; TD = deep layer of trochlear cartilage; TS = superficial layer of trochlear cartilage. (\*) indicates a significant difference of  $p < 0.05$ .

### Discussion

This study evaluated the PFJ cartilage biochemical composition changes at 3 years after ACL reconstruction surgery using T2 relaxation times. The data demonstrated that T2 value changes of the PFJ exist in all patients, although these patients were clinically asymptomatic during daily activities. More patients showed increases of T2 values at the trochlear cartilage than at the patellar cartilage. These findings proved our hypothesis that the PFJ cartilage showed increased T2 values compared to the

uninjured contralateral knees at 3-year follow-up after ACL reconstruction and the trochlear cartilage is more susceptible to T2 value changes than the patellar cartilage.

Early degeneration of the knee joint after ACL reconstruction has been extensively investigated using quantitative MRI [10,12,16,19,25,26]. There are many reports that ACL-reconstructed knees have shown increased T1 $\rho$  or T2 values at various periods of follow-up times, compared with the uninjured knee or normal population [12,16,19,26]. For example, Theologis et al. [16] reported that the medial tibia and medial femoral condyle in ACL-reconstructed

**Table 3** Increases of T2 values (ms, %) in the superficial and deep layers of different compartment of the ACL-reconstructed knees compared to the contralateral side at 3-year follow-up.

Region	Patient No.	Superficial layer			Deep layer		
		Medial compartment (ms, %)	Central compartment (ms, %)	Lateral compartment (ms, %)	Medial compartment (ms, %)	Central compartment (ms, %)	Lateral compartment (ms, %)
Trochlea	1	8.1, 14.8	11.4, 21.1	1.9, 3.1	8.8, 16.6	13.8, 30.4	12.3, 26.6
	2	11.5, 22.5	14.0, 23.1	4.3, 6.3	3.0, 6.0	-3.3, -5.9	3.4, 5.9
	3	1.8s, 3.4	-5.3, -8.5	-5.9, -9.4	3.4, 6.8	-11.6, -19.1	-3.5, -6.8
	4	-0.8, -1.2	11.8, 19.3	9.9, 17.5	3.5, 6.3	3.2, 5.5	3.4, 6.6
	5	7.0, 13.1	15.7, 29.9	24.7, 54.0	13.5, 27.4	15.7, 30.1	15.1, 32.1
	6	9.0, 17.2	-2.5, -3.4	-21.3, -27.8	1.4, 2.8	-5.4, -9.4	-5.2, -9.2
	7	3.3, 6.1	-5.1, -9.2	-17.6, -26.3	0.5, 0.9	-4.3, -7.8	-4.2, -7.2
	8	19.5, 38.3	5.1, 10.2	-19.7, -30.0	2.6, 4.5	-0.3, -0.5	-10.0, -16.8
	9	-13.9, -20.0	2.2, 3.7	5.6, 9.4	-8.4, -13.3	-1.5, -2.7	9.8, 18.3
	10	-3.2, -5.5	12.1, 22.8	-17.0, -21.7	3.1, 5.9	-2.5, -4.6	-25.0, -32.8
Patella	1	27.1, 54.2	10.3, 19.4	1.6, 3.3	8.5, 16.8	-3.4, -6.5	-2.1, -4.3
	2	5.3, 10.0	2.0, 4.0	7.6, 16.7	5.8, 12.9	0.8, 1.6	0.1, 0.3
	3	12.1, 22.7	-3.1, -5.8	5.1, 10.3	6.4, 12.7	-6.5, -12.9	-4.5, -9.4
	4	1.2, 2.1	-0.5, -0.8	-2.2, -4.0	0.2, 0.4	3.9, 7.4	-2.4, -4.7
	5	24.4, 48.6	-16.6, -22.7	-3.5, -6.2	9.5, 20.3	-8.5, -14.1	-3.6, -6.4
	6	-12.9, -21.0	-7.9, -13.4	-14.1, -23.3	-1.9, -3.9	-0.8, -1.6	-8.6, -16.2
	7	-3.4, -5.9	0.3, 0.6	-4.1, -6.7	-5.8, -10.5	3.0, 6.1	10.5, 19.0
	8	-15.4, -25.4	3.8, 8.2	0.9, 1.8	-2.5, -4.9	2.1, 4.6	3.4, 7.5
	9	1.2, 2.1	-4.9, -8.6	0.04, 0.06	-5.3, -10.1	-4.1, -7.6	5.9, 11.1
	10	-8.1, -13.4	-8.6, -13.4	-5.7, -9.8	-0.9, -1.5	-3.5, -6.8	-7.0, -13.1

knees after 12–16 months of surgery had  $T1\rho$  values that were significantly elevated compared to respective regions of contralateral knees. Bae et al. [19] reported that all patients showed a wide range of increases in T2 values (3–81%) in one or more subcompartmental areas of the tibiofemoral cartilage in the ACL-reconstructed knees when compared to the corresponding areas of the uninjured contralateral knees after 3 years of surgery. These results imply that biochemical composition changes which could be associated with early degenerative processes did occur in ACL-reconstructed knees. However, most of these studies investigated the TFJ of the knee. Fewer have looked at the degeneration of patellofemoral articulation after ACL reconstruction. The PFJ has different biomechanical features from the TFJ and could be affected by ACL reconstruction in a different manner [4,7,27,28].

In this study, the medial trochlear cartilage of the ACL-reconstructed knee showed significantly increased T2 values, compared to uninjured knees, but fewer changes in patellar cartilage were observed. In a recent MRI evaluation of cartilage degeneration of the knee after ACL reconstruction, Wang et al. [29] also reported a significant worsening of patellar cartilage in 26–48% of patients in the second-look arthroscopy at least 1 year after ACL reconstruction, although the predominance of OA sites was not reported. Culvenor et al. [30] indicated that more patients showed early OA signs at the trochlear compartment than at the tibiofemoral cartilage at 1 year follow up after ACL reconstruction, especially at the medial compartment. In a recent review paper, Culvenor et al. [4] summarized that the prevalence of PFJ OA after ACL reconstruction is between 11% and 90% at 2–15 years after surgery. These data

indicated that the PFJ is more, or at least similarly, vulnerable to degeneration after ACL reconstruction compared to the TFJ. However, the mechanisms of cartilage degeneration of the PFJ are unclear although abnormal loading has been implicated by various studies.

In our study, the quadriceps strength was not directly evaluated, but the patients showed satisfactory results using various clinical evaluation forms, including items on PFJ function and muscle strength after ACL reconstruction. There are *in vitro* biomechanical studies reporting that ACL injury caused alternations of knee joint kinematics and changes in the cartilage contact area and pressure in PFJ [27,28,31–33]. In ACL-injured knees, the cartilage peak pressure and contact area of medial and lateral patellar facet were decreased and patellar lateral tilting was increased due to an aggravated tibial external rotation, compared to normal knees [28,31,33]. Furthermore, some studies have reported that the altered kinematics of ACL-injured knees could not be restored to normal after ACL reconstruction [27,28,33] and the abnormal tibiofemoral kinematics could cause alternations in the PFJ contact pressure. However, it should be noted that there are many factors which could influence the degeneration of articular cartilage of the PFJ, such as the alignment of lower extremity, combined meniscal injury, method of treatment to the meniscal tear, daily life style that demands deep flexion of knee, and the grade of degeneration in the TFJ at the time of injury. All these factors imply an abnormal cartilage contact loading at the PFJ after ACL reconstruction. Therefore, it is imperative for future studies to determine the cartilage contact biomechanics changes after ACL reconstruction and the possible relationship between the

cartilage contact biomechanics changes and postoperative cartilage degeneration.

Our study had several limitations. This study has a small sample size. Although we used the contralateral side of the knee as a control, this limitation was not completely overcome. We recruited the patients using clear inclusion criteria, but the conditions of these patients varied as shown in [Tables 1 and 2](#). We did not perform a preoperative analysis and used the patient operation records to evaluate intraoperative cartilage status and meniscal tear. Consequently, we could not conclude if there is a deterioration or improvement of the patellofemoral articular cartilage health after 3 years of ACL reconstruction. Finally, our data were derived from patients who underwent a single bundle ACL reconstruction using a transtibial technique. Recently, various surgical techniques have been introduced in ACL reconstruction. Our data should be limited to the surgical technique that was used in this group of patients. Despite these limitations, this study presented a first view to compare T2 values of PFJ cartilage between ACL-reconstructed and uninjured contralateral knees at the 3-year follow-up. Future investigation is warranted to determine the relationship between the changes of short term T2 values and the long term OA development of the knee, as well as the effects of changing kinematics on the increases of cartilage T2 values, especially in the medial compartment of the PFJ.

## Conclusion

This study demonstrated that the articular cartilage of the PFJ of the knee at 3 years after ACL reconstruction had higher T2 values in local areas compared to the uninjured contralateral knee, even though a clinically satisfactory ACL reconstruction was achieved. The elevation of T2 values was prominent in the medial trochlear side and superficial layer of the cartilage.

## Acknowledgements/Funding Support

This work was supported by the National Institutes of Health (NIH R01 AR055612 and AR060331).

## Conflicts of interest

The authors have no conflicts of interest to declare regarding this study.

## References

- [1] Ahn JH, Kim JG, Wang JH, Jung CH, Lim HC. Long-term results of anterior cruciate ligament reconstruction using bone-patellar tendon-bone: an analysis of the factors affecting the development of osteoarthritis. *Arthroscopy* 2012;28:1114–23.
- [2] Ajuied A, Wong F, Smith C, Norris M, Earnshaw P, Back D, et al. Anterior cruciate ligament injury and radiologic progression of knee osteoarthritis: a systematic review and meta-analysis. *Am J Sports Med* 2014;42:2242–52.
- [3] Chalmers PN, Mall NA, Moric M, Sherman SL, Paletta GP, Cole BJ, et al. Does ACL reconstruction alter natural history?: A systematic literature review of long-term outcomes. *J Bone Joint Surg Am* 2014;96:292–300.
- [4] Culvenor AG, Cook JL, Collins NJ, Crossley KM. Is patellofemoral joint osteoarthritis an under-recognised outcome of anterior cruciate ligament reconstruction? A narrative literature review. *Br J Sports Med* 2013;47:66–70.
- [5] Keays SL, Newcombe PA, Bullock-Saxton JE, Bullock MI, Keays AC. Factors involved in the development of osteoarthritis after anterior cruciate ligament surgery. *Am J Sports Med* 2010;38:455–63.
- [6] Neuman P, Kostogiannis I, Friden T, Roos H, Dahlberg LE, Englund M. Patellofemoral osteoarthritis 15 years after anterior cruciate ligament injury—a prospective cohort study. *Osteoarthritis Cartilage* 2009;17:284–90.
- [7] Culvenor AG, Lai CC, Gabbe BJ, Makdissi M, Collins NJ, Vicenzino B, et al. Patellofemoral osteoarthritis is prevalent and associated with worse symptoms and function after hamstring tendon autograft ACL reconstruction. *Br J Sports Med* 2014;48:435–9.
- [8] Oiestad BE, Holm I, Engebretsen L, Aune AK, Gunderson R, Risberg MA. The prevalence of patellofemoral osteoarthritis 12 years after anterior cruciate ligament reconstruction. *Knee Surg Sports Traumatol Arthrosc* 2013;21:942–9.
- [9] Bolbos RI, Zuo J, Banerjee S, Link TM, Ma CB, Li X, et al. Relationship between trabecular bone structure and articular cartilage morphology and relaxation times in early OA of the knee joint using parallel MRI at 3 T. *Osteoarthritis Cartilage* 2008;16:1150–9.
- [10] Haugom B, Schairer W, Souza RB, Carpenter D, Ma CB, Li X. Abnormal tibiofemoral kinematics following ACL reconstruction are associated with early cartilage matrix degeneration measured by MRI T1rho. *Knee* 2012;19:482–7.
- [11] Nishioka H, Hirose J, Okamoto N, Okada T, Oka K, Taniwaki T, et al. Evaluation of the relationship between T1rho and T2 values and patella cartilage degeneration in patients of the same age group. *Eur J Radiol* 2015;84:463–8.
- [12] Potter HG, Jain SK, Ma Y, Black BR, Fung S, Lyman S. Cartilage injury after acute, isolated anterior cruciate ligament tear: immediate and longitudinal effect with clinical/MRI follow-up. *Am J Sports Med* 2012;40:276–85.
- [13] Potter HG, Koff MF. MR imaging tools to assess cartilage and joint structures. *HSS J* 2012;8:29–32.
- [14] Prasad AP, Nardo L, Schooler J, Joseph GB, Link TM. T(1)rho and T(2) relaxation times predict progression of knee osteoarthritis. *Osteoarthritis Cartilage* 2013;21:69–76.
- [15] Regatte RR, Akella SV, Lonner JH, Kneeland JB, Reddy R. T1rho relaxation mapping in human osteoarthritis (OA) cartilage: comparison of T1rho with T2. *J Magn Reson Imaging* 2006;23:547–53.
- [16] Theologis AA, Haugom B, Liang F, Zhang Y, Majumdar S, Link TM, et al. Comparison of T1rho relaxation times between ACL-reconstructed knees and contralateral uninjured knees. *Knee Surg Sports Traumatol Arthrosc* 2014;22:298–307.
- [17] Watrin-Pinzano A, Ruaud JP, Cheli Y, Gonord P, Grossin L, Gillet P, et al. T2 mapping: an efficient MR quantitative technique to evaluate spontaneous cartilage repair in rat patella. *Osteoarthritis Cartilage* 2004;12:191–200.
- [18] Wheaton AJ, Dodge GR, Elliott DM, Nicoll SB, Reddy R. Quantification of cartilage biomechanical and biochemical properties via T1rho magnetic resonance imaging. *Magn Reson Med* 2005;54:1087–93.
- [19] Bae JH, Hosseini A, Wang Y, Torriani M, Gill TJ, Grodzinsky AJ, et al. Articular cartilage of the knee 3 years after ACL reconstruction. *Acta Orthop* 2015;86:605–10.
- [20] Li X, Kuo D, Theologis A, Carballido-Gamio J, Stehling C, Link TM, et al. Cartilage in anterior cruciate ligament-

- reconstructed knees: MR imaging T1 $\rho$  and T2—initial experience with 1-year follow-up. *Radiology* 2011;258: 505–14.
- [21] Theologis AA, Kuo D, Cheng J, Bolbos RI, Carballido-Gamio J, Ma, et al. Evaluation of bone bruises and associated cartilage in anterior cruciate ligament-injured and -reconstructed knees using quantitative T1 $\rho$  magnetic resonance imaging: 1-year cohort study. *Arthroscopy* 2011;27:65–76.
- [22] Baum T, Joseph GB, Karampinos DC, Jungmann PM, Link TM, Bauer JS. Cartilage and meniscal T2 relaxation time as non-invasive biomarker for knee osteoarthritis and cartilage repair procedures. *Osteoarthritis Cartilage* 2013;21: 1474–84.
- [23] Baum T, Stehling C, Joseph GB, Carballido-Gamio J, Schwaiger BJ, Müller-Höcker C, et al. Changes in knee cartilage T2 values over 24 months in subjects with and without risk factors for knee osteoarthritis and their association with focal knee lesions at baseline: data from the osteoarthritis initiative. *J Magn Reson Imaging* 2012;35:370–8.
- [24] Li X, Benjamin Ma C, Link TM, Castillo DD, Blumenkrantz G, Lozano J, et al. In vivo T1 $\rho$  and T2 mapping of articular cartilage in osteoarthritis of the knee using 3 T MRI. *Osteoarthritis Cartilage* 2007;15:789–97.
- [25] Su F, Hilton JF, Nardo L, Wu S, Liang F, Link TM, et al. Cartilage morphology and T1 $\rho$  and T2 quantification in ACL-reconstructed knees: a 2-year follow-up. *Osteoarthritis Cartilage* 2013;21:1058–67.
- [26] Zaid M, Lansdown D, Su F, Padoia V, Tufts L, Rizzo S, et al. Abnormal tibial position is correlated to early degenerative changes one year following ACL reconstruction. *J Orthop Res* 2015;33:1079–86.
- [27] Culvenor AG, Schache AG, Vicenzino B, Pandy MG, Collins NJ, Cook JL, et al. Are knee biomechanics different in those with and without patellofemoral osteoarthritis after anterior cruciate ligament reconstruction? *Arthritis Care Res (Hoboken)* 2014;66:1566–70.
- [28] Van de Velde SK, Gill TJ, DeFrate LE, Papannagari R, Li G. The effect of anterior cruciate ligament deficiency and reconstruction on the patellofemoral joint. *Am J Sports Med* 2008; 36:1150–9.
- [29] Wang HJ, Ao YF, Jiang D, Gong X, Wang YJ, Wang J, et al. Relationship between quadriceps strength and patellofemoral joint chondral lesions after anterior cruciate ligament reconstruction. *Am J Sports Med* 2015;43:2286–92.
- [30] Culvenor AG, Collins NJ, Guermazi A, Cook JL, Vicenzino B, Khan KM, et al. Early knee osteoarthritis is evident one year following anterior cruciate ligament reconstruction: a magnetic resonance imaging evaluation. *Arthritis Rheumatol* 2015; 67:946–55.
- [31] Hsieh YF, Draganich LF, Ho SH, Reider B. The effects of removal and reconstruction of the anterior cruciate ligament on the contact characteristics of the patellofemoral joint. *Am J Sports Med* 2002;30:121–7.
- [32] Shin CS, Carpenter RD, Majumdar S, Ma CB. Three-dimensional in vivo patellofemoral kinematics and contact area of anterior cruciate ligament-deficient and -reconstructed subjects using magnetic resonance imaging. *Arthroscopy* 2009;25:1214–23.
- [33] Tajima G, Iriuchishima T, Ingham SJ, Shen W, van Houten AH, Aerts MM, et al. Anatomic double-bundle anterior cruciate ligament reconstruction restores patellofemoral contact areas and pressures more closely than nonanatomic single-bundle reconstruction. *Arthroscopy* 2010;26:1302–10.