



Research Letter: Open Science

Robot-assisted Radical Prostatectomy with the Versius Robotic Surgical System: First Description of a Clinical Case

The past decades have witnessed the spread of robotic surgery for several urological indications, with robot-assisted radical prostatectomy (RARP) being the most important one. Novel robotic competitors have recently emerged in an effort to reduce costs and improve access to robotic surgery. Versius (CMR Surgical, Cambridge, UK) is a novel surgical robotic system comprising a surgeon console, a visualization bedside unit (BSU), up to four operative BSUs, endoscopes, a camera, and instruments. Each instrument has a wristed joint that provides seven degrees of freedom at the tip for an overall 720° of rotation.

Use of the Versius system for RARP has been described in a preclinical study in which four procedures (including a single Retzius-sparing case) were successfully completed on cadavers [1,2]. In humans, the Versius system has mostly been used for renal surgery and management of benign conditions. Huddy et al. [3] described its application during the COVID-19 pandemic in 50 urological cases, including radical and partial nephrectomy, pyeloplasty, and adrenalectomy. Hussein et al. [4] reported on 100 Versius cases that included pyeloplasty, stone surgery, and radical, partial, and simple nephrectomy. Very recently, Reeves et al. [5] reported a preliminary stage 1/2a evaluation using an IDEAL (Idea, Development, Exploration, Assessment, Long-term follow-up) framework that included four RALP cases among other procedures performed with the Versius system.

However, unlike the Hugo system [6], no detailed description of a Versius RARP case in a clinical setting has been reported to date. Here we describe the first RARP case performed with the Versius system at ASST Santi Paolo e Carlo, Milan, Italy. We report on technical feasibility along with safety and possible issues, and include details on trocar placement and the surgical setup.

The RARP case was carried out by a single console surgeon (B.R.) with extensive experience with the da Vinci system (approximately 1500 RARPs); the whole surgical team had previous robotic experience and all surgeons underwent a prior 3-d cadaver laboratory session. During training, trocar positioning and the operating room setting were planned and two full cadaver procedures (partial nephrectomy and radical prostatectomy) were carried out.

The first RARP clinical case was performed in a 72-yr-old male (body mass index 25 kg/m²; height 174 cm) with a clin-

ical diagnosis of organ-confined prostate cancer. The patient had Gleason score 3 + 4 prostate cancer in two out of 11 positive systematic cores; his initial prostate-specific antigen was 6 ng/ml. The risk of nodal involvement was 3% according to the Memorial Sloan Kettering preprostatectomy nomogram, so pelvic nodal dissection was not planned.

The patient was placed in a 25° Trendelenburg position. The port configuration reflected the standard technique used by the first surgeon (Fig. 1). The BSU arms for instruments were docked first: a single BSU on the right-hand side and two BSUs on the left. The optic BSU was placed above the head on the right-hand side and docked last. Two additional ports for the assistant were located on the right-hand side (Fig. 1). Unlike the da Vinci system, a port training process is required for each Versius arm to focus instrument motion on the target area.

All the surgical steps for RARP were completed without critical surgical errors. Two high-priority alarms occurred on two different arms and required a BSU restart; the reason was an inadvertent collision between the trocar and the skin. The events had no clinical impact. The docking time was 30 min and the console time was 130 min. A video of the procedure is available at <https://drive.google.com/file/d/1kFCgr0sV5OqkBjs11-2wFU8Byny6IAAG/view?usp=drivesdk>.

The postoperative course was uneventful and the patient was discharged on the third postoperative day. Pathology revealed stage pT2c with Gleason score 3 + 4 and negative surgical margins; no leakage was evident on a cystogram. At 3 d after catheter removal the patient had recovered social continence (daytime use of a single safety pad) and full nighttime continence.

Our clinical experience demonstrates that RARP with the Versius system is a feasible procedure. However, preclinical training and accurate surgical planning are key in facing some issues that may arise during the procedure.

The Versius system has some unique features that should be considered before starting an RARP program:

- An exclusive controller handgrip (including a camera and clutch) without pedal control;
- An energy control feature on the handgrip;
- An independent BSU that requires a dedicated setup;
- A requirement for port training to focus the instruments on the target zone;
- An instrument length of 30 cm; and
- A requirement for port configuration adapted to the patient's features, the BSUs, and the instrument length.



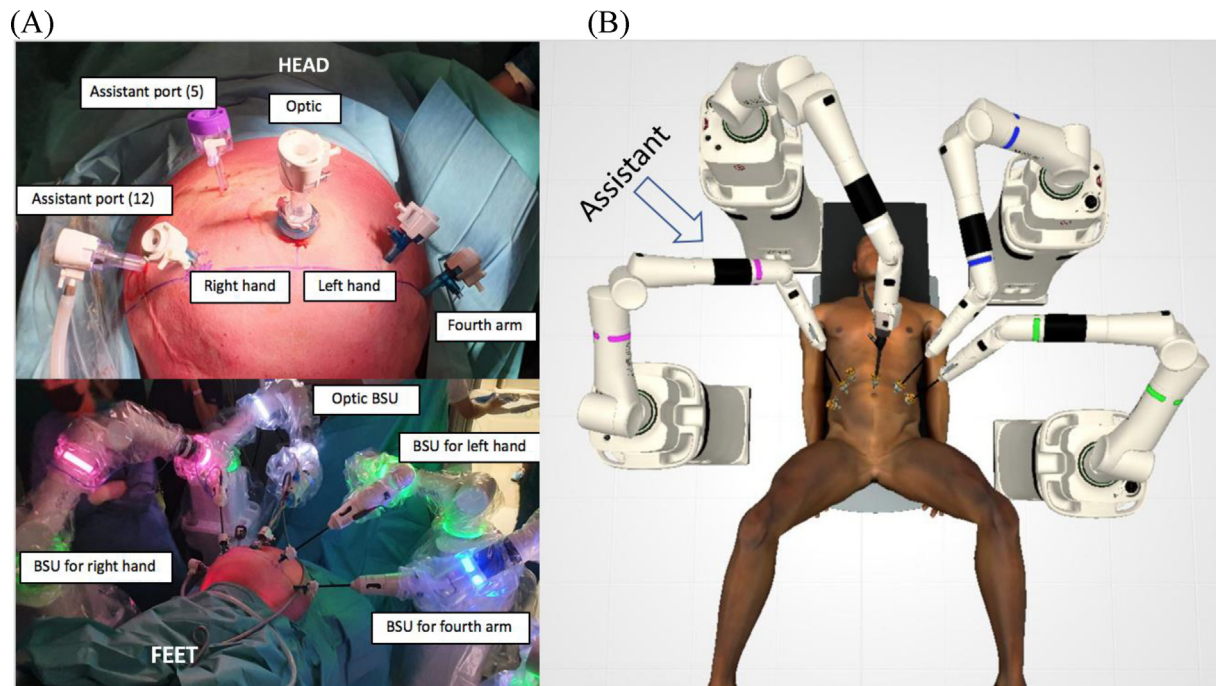


Fig. 1 – (A) Port configuration with laparoscopic trocars (Applied Medical, Rancho Santa Margarita, CA, USA). Placement of BSU arms for instruments: a single BSU was placed on the right-hand side and two BSUs on the left. The optic BSU was placed above the head on the right-hand side and docked last. Two additional ports for the assistant were located on the right-hand side. BSU = bedside unit. (B) Operating room setting for radical prostatectomy with the Versius system.

Beyond the feasibility and safety demonstrated for this first reported case, further clinical experience is required to standardize RARP with the Versius system to ensure that the procedure is reproducible and to facilitate widespread integration of the system into robotic prostate surgery programs.

Conflicts of interest: The authors have nothing to disclose.

References

- [1] Thomas BC, Slack M, Hussain M, et al. Preclinical evaluation of the Versius surgical system, a new robot-assisted surgical device for use in minimal access renal and prostate surgery. *Eur Urol Focus* 2021;7:444–52. <https://doi.org/10.1016/j.euf.2020.01.011>.
- [2] Alkatout I, Salehiniya H, Allahqoli L. Assessment of the Versius robotic surgical system in minimal access surgery: a systematic review. *J Clin Med* 2022;11:3754. <https://doi.org/10.3390/jcm11133754>.
- [3] Huddy JR, Crockett M, Nizar AS, et al. Experiences of a “COVID protected” robotic surgical centre for colorectal and urological cancer in the COVID-19 pandemic. *J Robot Surg* 2022;16:59–64. <https://doi.org/10.1007/s11701-021-01199-3>.
- [4] Hussein AA, Mohsin R, Qureshi H, et al. Transition from da Vinci to Versius robotic surgical system: initial experience and outcomes of over 100 consecutive procedures. *J Robot Surg*. In press. <https://doi.org/10.1007/s11701-022-01422-9>.
- [5] Reeves F, Challacombe B, Ribbits A, Ourselin S, Dasgupta P. Idea, Development, Exploration, Assessment, Long-term follow-up study

- (IDEAL) stage 1/2a evaluation of urological procedures with the Versius robot. *BJU Int* 2022;130:441–3. <https://doi.org/10.1111/bju.15829>.
- [6] Bravi CA, Paciotti M, Sarchi L, et al. Robot-assisted radical prostatectomy with the novel Hugo robotic system: initial experience and optimal surgical set-up at a tertiary referral robotic center. *Eur Urol* 2022;82:233–7. <https://doi.org/10.1016/j.eururo.2022.04.029>.

Bernardo Rocco^a
 Filippo Turri^a
 Mattia Sangalli^a
 Simone Assumma^a
 Igor Piacentini^a
 Angelica Grasso^a
 Paolo Dell’Orto^a
 Tommaso Calcagnile^a
 Luca Sarchi^b
 Giorgio Bozzini^c
 Maria Chiara Sighinolfi^{a,*}

^a Urology Unit, ASST Santi Paolo e Carlo, La Statale University, Milan, Italy

^b ASST Santi Paolo e Carlo, La Statale University, Milan, Italy

^c ASST Lariana, Milan, Italy

*Corresponding author. Urology Unit, ASST Santi Paolo e Carlo, Via A. Rudini 8, Milan, Italy.

E-mail address: sighinolfic@gmail.com (M.C. Sighinolfi).