

Original Article

# Reliability of treating asymptomatic traumatic type II dens fractures in patients over age 80: A retrospective series

Eric Momin, Viraat Harsh<sup>1</sup>, Jared Fridley, Lona Winnegan, Ibrahim Omeis

Department of Neurosurgery, Baylor College of Medicine, Houston, TX 77030, USA, <sup>1</sup>Department of Neurosurgery, Rajendra Institute of Medical Sciences, Ranchi, Jharkhand, India

Corresponding author: Dr. Ibrahim Omeis, Baylor College of Medicine, 7200 Cambridge St, Ste 9A, Houston, TX 77030, USA.  
E-mail: omeis@bcm.edu

Journal of Craniovertebral Junction and Spine 2015, 6:42

## Abstract

**Background:** Management of type II odontoid fractures in elderly remains controversial to whether surgical treatment is favored over conservative one. This is a study of geriatric patients with asymptomatic type II dens fractures who after sustaining a fall were initially evaluated at community hospitals. They were placed in a rigid collar and were followed up in a spine clinic. **Purpose:** To assess the reliability of treating very old patients with type II dens fracture conservatively and whether surgical intervention if needed would affect the clinical outcome. **Study Design:** Retrospective study with the literature review. **Patient Sample:** Consecutive patients above 80 years of age, who sustained a clinically asymptomatic type II dens fracture and were observed after a conservative treatment plan, was initiated. **Outcome Measures:** Outcome measures included self-reported worsening neck pain, neurological function, and radiographic measures over the follow-up period. **Materials and Methods:** A retrospective clinical analysis of 5 active geriatric patients with type II asymptomatic dens fracture. After evaluating them, treatment options were discussed with patients and their family members. The decision was to continue to follow them with a rigid collar very closely since they were reluctant to undergo any surgical procedure. **Results:** Patients were followed for an average of 29 months. They were observed for any worsening neck pain, neurological deficit, or deterioration of fracture on follow-up imaging studies. At last follow-up, 2 of 5 patients continued to be asymptomatic, the 3<sup>rd</sup> died of unrelated causes while 2 others required surgeries at least 1-year post injury. **Conclusions:** Treatment of type II dens fractures in the elderly is controversial. Independent elderly patients who are asymptomatic at presentation may be safe to be followed up very closely with a neck brace and serial X-ray. Converting to surgical treatment can be done safely when needed without affecting the overall clinical out.

**Key words:** Conservative treatment, dens fracture, geriatric, odontoid, surgical fixation

This is an open access article distributed under the terms of the Creative Commons Attribution-NonCommercial-ShareAlike 3.0 License, which allows others to remix, tweak, and build upon the work non-commercially, as long as the author is credited and the new creations are licensed under the identical terms.

**For reprints contact:** [reprints@medknow.com](mailto:reprints@medknow.com)

**How to cite this article:** Momin E, Harsh V, Fridley J, Winnegan L, Omeis I. Reliability of treating asymptomatic traumatic type II dens fractures in patients over age 80: A retrospective series. J Craniovert Jun Spine 2015;6:166-72.

Access this article online	
Quick Response Code:	Website: <a href="http://www.jcvs.com">www.jcvs.com</a>
	DOI: 10.4103/0974-8237.167859

## INTRODUCTION

Odontoid fractures are the most common isolated cervical spine injury in geriatric patients. The majority of these are type II fractures. The management of type II odontoid fractures in elderly individuals remains controversial.<sup>[1,2]</sup> Many practitioners advocate surgical stabilization due to the high nonunion rate in these patients when treated conservatively.<sup>[2]</sup> However, some of these patients for various medical or personal reasons, are reluctant to undergo surgery and will choose conservative therapy with external cervical collar immobilization over surgical intervention. The outcome of this subset of type II fracture patients is still debatable.

In this paper, we present a small retrospective observational series of geriatric patients over the age of 80 years who sustained type II odontoid fractures after a fall, who were clinically asymptomatic with no resulting neurological deficits or neck pain, and who were managed conservatively with cervical collar immobilization. The literature on this subject is subsequently reviewed and discussed.

## MATERIALS AND METHODS

A total of 17 patients with type II dens fractures were treated over a period of 5 years. Five patients over the age of 80 (mean age on presentation 84) with Nurick scale of 1–2, were followed conservatively (mean follow-up 29 months). They all presented to a nearby community hospital. Upon evaluation, imaging studies including X-ray and computed tomography scan demonstrated a type II dens fracture. Upon examination, they did not demonstrate any neurological deficit and did not complain of neck pain; thus, they were discharged in a hard collar and instructed to follow-up with a spine surgeon. Upon evaluation with the spine surgeon in the clinic, treatment

options were discussed with them and surgery was offered as the preferred treatment modality given the good functional status of the patients and their independence, as well as the relative safety of surgery. However, this subgroup of patients in this series was very reluctant to undergo surgery and 3 of them even sought a second opinion. They refused surgery due to multiple factors including their age, the minimal symptoms they acquired after the fall, and family dynamics. Thus, they were managed conservatively with a rigid neck brace for 3 months and close follow-up with serial monthly cervical spine X-ray for 3 months and magnetic resonance imaging (MRIs) at 1-year from the time of injury.

## RESULTS

The mean follow-up was 29 months (20–37 months). Early follow-up X-ray showed no deterioration of the fractures. They remained with no neck pain and no evidence of neurological deficit. At 3 months from injury, patients were taken off the neck brace.

They were allowed to return to their baseline activity including driving and baseline daily activities. Brief description of patients' clinical course outcomes are described below and in [Table 1].

### Case presentation 1

An 81-year-old female with a history of chronic lymphocytic leukemia fell from a standing position and sustained type II dens fracture [Figure 1]. Nurick scale 0. After discussion with her regarding treatment options, she opted to continue with her conservative treatment that entailed neck brace and monthly follow-up with-rays. At 3 months, X-ray was done including flexion/extension and she was weaned off her neck brace. She returned to her baseline activities including driving. She continued to follow with serial imaging. Figure 2 shows imaging

**Table 1: Patients with type II dens fracture managed conservatively**

Gender	Age	Mechanism of injury	Presence of additional spinal pathology	Presence of other spinal injuries	Length of follow-up (months)	Outcome
Male	87	Fall	Advanced degenerative cervical disc disease	None	37	X-ray showed stable fracture, no abnormal excursion. Off cervical collar, neurologically asymptomatic
Female	91	Fall	Cervical myelopathy with T2 signal on MRI in the subaxial spine	None	26	Patient deceased of causes unrelated to dens fracture. Able to function independently more than 2 months prior to last clinic appointment
Female	81	Fall	Degenerative disc disease	None	36	In treatment for breast cancer chronic lymphocytic leukemia. Asymptomatic
Male	83	Fall	Ankylosing spondylitis with degenerative changes from C2-C5	None	20	Fell since collar was discontinued. Returned with new symptoms and follow-up imaging showed the progression of the C2 fracture. Patient underwent C1 posterior arch resection, bilateral C2 neurectomies, and C1-C2 posterior fusion with instrumentation, 13 months after the first fall
Female	82	Fall	Degenerative changes at C5-6 and C6-7	None	24	Status post-C1-5 fusion 16 months after the initial injury. At baseline. Off cervical collar. Asymptomatic

MRI: Magnetic resonance imaging

at 2 years follow-up including MRI and X-ray with clinically asymptomatic fracture.

### Case presentation 2

An 83-year-old male was very active at baseline who initially sustained a fall. He was taken to the emergency room where initial imaging studies were performed [Figure 3]. Nurick scale 2. He was placed in a hard neck brace and was discharged home. Treatment options were discussed with him and surgery was recommended given the nature of the fracture. He declined surgery and sought a second opinion with another spine surgeon who recommended surgery. However, the patient opted not to have surgery and decided to follow-up in our clinic. He was weaned off his brace at 3 months and was followed up closely. He was able to carry on his baseline daily activities until he sustained a second fall 13 months after the first injury. He presented to clinic ambulating, however, with worsening neck and occipital pain. Repeat imaging of his cervical spine

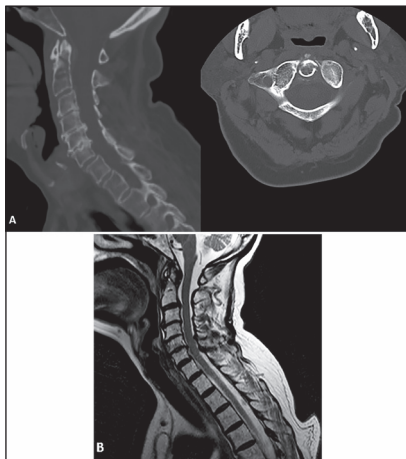


Figure 1: 81-year-old female status post fall who sustained a type II dens fracture. At time of injury: (a) Sagittal and axial computed tomography scan, and (b) Sagittal T2-weighted images demonstrating C2 fracture

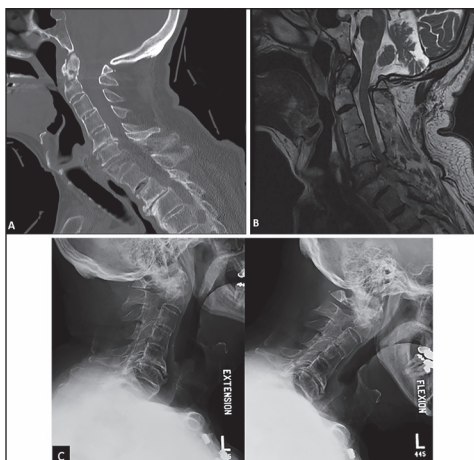


Figure 3: 83-year-old male sustaining a C2 fracture. At the time of injury: (a) Sagittal computed tomography, (b) sagittal T2-weighted images demonstrating the fracture. (c) Flexion/extension X-ray 3 months after the injury demonstrating minimal movement at C2

including an MRI showed worsening of the fracture with circumferential cord compression. He eventually agreed to surgery and underwent C1 posterior arch resection, bilateral C2 neurectomies, and C1-2 posterior instrumented fusion. The hospital course was uneventful and he was discharged home [Figure 4].

### Case presentation 3

An 82-year-old female sustained a type II dens fracture and was treated initially with a neck brace although surgery was recommended. At presentation, she was Nurick scale 2. She started having a progressive course of weakness in her upper and lower extremities, 16 months post fracture. Surgery was subsequently offered again. She agreed to cervical decompression and posterior instrumented fusion from C1 to C5. Her hospital course was uneventful and was discharged to a rehabilitation center then home. On follow-up visits, she was able to ambulate without assistance and did not complain of neck pain.

### Case presentation 4

An 87-year-old male was evaluated in the ER after a fall. He had no complaints of neck pain. Imaging studies revealed type II dens fracture. Nurick scale 1. After consultation with the

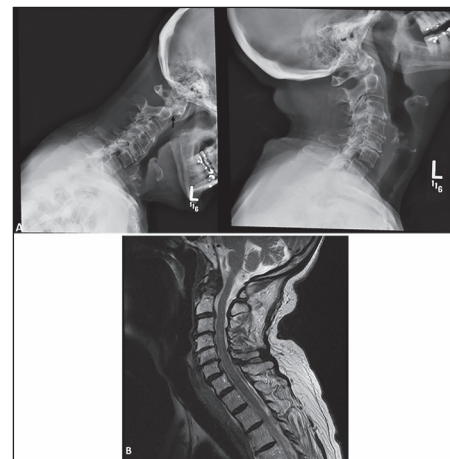


Figure 2: Two years post injury: (a) Flexion/extension X-ray demonstrating minimal movement of the fracture (arrow head). (b) Sagittal T2-weighted images demonstrating minimal reactive changes at the C1-2 complex

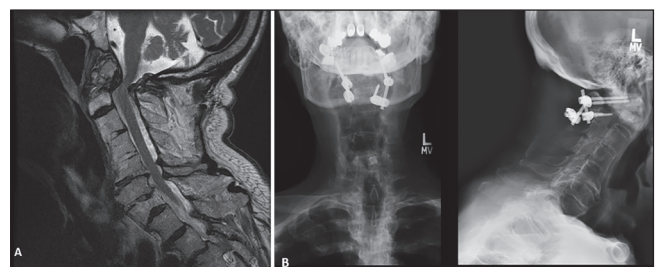


Figure 4: Patient fell a 2<sup>nd</sup> time. (a) Sagittal T2-weighted images showing circumferential cord compression. (b) The patient underwent C1 posterior arch resection, bilateral C2 neurectomies, and C1-2 posterior instrumented fusion, with the postoperative result shown in sagittal and anteroposterior X-ray

on-call surgeon, he was treated with a rigid neck brace. Upon follow-up, he continued to do well with the neck brace and X-ray of the cervical spine showed unchanged fracture. The decision was made to continue to treat him conservatively. After 3 months, X-ray was again performed and did not show any change. He was weaned off the neck brace. Follow-up (37 months post fall) imaging studies demonstrated stable fracture.

### Case presentation 5

A 91-year-old female sustained a type II dens fracture after a fall. She was independent at home. She was treated with a neck brace in the ER. Nurick scale 2. Repeat imaging studies on follow-up demonstrated stable fracture. She was doing well until 2 months after her last clinic visit. She deceased to unrelated causes.

## DISCUSSION

In the community setting, treatment patterns often differ from the urban setting: Patients with dens fractures after minor injury events frequently present to a local hospital and not a trauma center. Sometimes patients with such fractures in the setting of a clinically and subjectively asymptomatic condition, are treated with a hard collar by the physician on call, and then sent for follow-up to a spine specialist. By the time, they present to the specialist to be evaluated, a period of time has elapsed and such patients have become accustomed to the collar. It becomes difficult to convince these patients, who have been asymptomatic for some time, that surgery will add any additional benefit, and that might be rightfully so.

From our experience, refusal of surgical intervention arises from several factors:

- (1) Age is probably is the most important factor. Patients in this age group are reluctant to undergo any surgical procedure because of the considerable incidence of complication in this patient group regardless of the type of surgery. They fear that they may become more dependent on their family members.
- (2) The minimal symptoms they acquired post fall also support their inherent conviction that surgery may not be a priority. A good example is patient number 4 [Table 1]. He was so adamant not to have surgery, and his family agreed with him. However, he did well until he fell a 2<sup>nd</sup> time and his pain became so severe in his neck and suboccipital area that he started entertaining suicidal ideations. Consequently, surgery has become the sole treatment that he would accept to alleviate his symptoms. He underwent posterior arch resection to decompress the spinal cord, and bilateral C2 neurectomies to alleviate his suboccipital pain. Intraoperatively, he was found to have significant inflammatory tissue around his C2 nerve roots. Postoperatively, he did very well and his pain subsided significantly. Likewise for patient number 5, who developed progressive weakness in her extremities, surgery had become a priority to the patient and her family. She

underwent upper cervical spine decompression and fusion. Postoperatively, she improved significantly. She was able to ambulate with some assistance and her neck pain was minimal.

### (3) Family dynamics.

In 4 of the 5 patients, the family members were more opposed to any surgical treatment than the patient. This could arise from their emotional attachment to them and their fear of losing them or having their relative become more dependent.

We acknowledge that a growing evidence base favors surgical intervention in elderly patients with type II dens fractures with very good surgical outcomes<sup>[3]</sup> as it is in our experience as well: Systematic reviews showed higher osseous union rates in surgically treated patients compared to conservatively managed patients.<sup>[3]</sup> By contrast, there is a high mortality rate among elderly patients treated conservatively for type II dens fractures: A study of 58 patients treated conservatively reported a 1-year mortality rate of 14%.<sup>[4]</sup> Another series of 322 patients reported a 38% mortality rate for operative treatment, compared to 51% mortality rate for nonoperative treatment.<sup>[5]</sup> Increasing age has been shown to be associated with decreased osseous healing of type II dens fractures that are managed conservatively.<sup>[6-8]</sup> Given this evidence base in conjunction with the short operative time for odontoid screw placement (with a relatively low anesthetic burden), many surgeons prefer operative management in elderly patients with type II dens fractures as a first line treatment.<sup>[2]</sup> Both anterior and posterior surgical approaches in the elderly have been shown to have reasonable outcomes.<sup>[9]</sup> Surgery was offered and encouraged to all patients in our series in accordance with this known evidence base. However, the patients in this series all declined surgery initially. Two patients deteriorated neurologically, and once neurological symptoms arose in those patients, it was not a hard decision for both patients to agree to surgery.

There is a small evidence base indicating that conservative treatment in asymptomatic patients with a hard collar and close followed up may be permissible [Table 2]. Hart reported 5 elderly patients with chronic dens nonunion without myelopathy who were followed for 55 months in a Philadelphia collar.<sup>[10]</sup> None of these patients developed myelopathic symptoms and none had more than 1 mm in progression of atlantoaxial subluxation. Ryan and Taylor reported a series of 9 patients with nonunion who did not develop myelopathy after follow-up for 21 months.<sup>[11]</sup> Molinari *et al.* reported 34 geriatric patients followed for an average of 14.9 months and found that although 70% had mobile odontoid nonunion, their functional outcome, as assessed by pain and disability scores, did not differ from similarly aged people with no cervical disorder.<sup>[12]</sup> Smith reported 223 cases of asymptomatic type II dens fractures and found slightly higher mortality in those treated nonsurgically (halo vest or cervical collar) versus those treated surgically (15% vs. 12.5%).<sup>[13]</sup> Our case series similarly supports the tenet that asymptomatic patients with type II dens fracture can be treated conservatively as long as these patients have no neck pain, are highly functional, and agree to close follow-up. As shown in our series, 2 patients



**Table 2: Literature review of studies of geriatric patients with type II dens fracture managed conservatively**

Study author	Number of patients followed up	Mean age	Underlying spinal pathology	Follow-up (months)	Treatment	Functional outcome	Failure of conservative management	Mortality	Morbidity	Pain outcome
Butler et al. <sup>[17]</sup>	14	42	Not discussed	66	External immobilization	Advancing age associated with poorer functional outcome as assessed by scores quantifying neck pain, shoulder/arm pain, physical symptoms, functional disability, and psychiatric distress. Patients with halo had the best functional outcome, followed by custom-made cervical orthosis, and then cervical orthosis	1 required surgery	None	Patients with cervical orthosis had less psychiatric distress compared to those treated with custom-made cervical orthosis and halo device	Cervical orthosis patients had the best outcome, followed by the halo device, and then the custom-made orthosis
Chapman et al. <sup>[5]</sup>	322	82	Not discussed	21.5	Conservative versus surgery	Operative treatment group had longer hospital stays and were more likely to need a feeding tube	None reported	38% mortality rate for operative treatment, 51% mortality rate for nonoperative treatment	Operative group had a longer hospitalization compared to nonoperative group and more likely to need feeding tube	Two patients reported intermittent neck pain and occipital headache
Hart et al. <sup>[10]</sup>	5	81	All patients had radiographic evidence of multilevel cervical degenerative disease	55	C-collar	Neurologic examinations were normal in all patients. None developed myelopathic symptoms; none had more than 1 mm in progression of atlantoaxial subluxation	None reported	2 died from causes unrelated to the dens fracture	None reported	Two patients reported intermittent neck pain and occipital headache
Koeh et al. <sup>[18]</sup>	42	Median age 80	Not discussed	24	C-collar and external immobilization	97.6% with fair to excellent functional outcome. 97.6% with moderate to no disability	2 patients failed conservative management. Osseous fusion in 50% of collar patients, and in 37.5% of halo thoracic patients. Fracture stability: in 90% of collar patients and 100% of halo thoracic patients	None reported	9.5% developed complications (cervical collar-decubitus ulcers, decreased pin tension, residual neck stiffness)	90.5% with moderate pain or less

(Continued)

**Table 2: (Continued)**

Study author	Number of patients followed up	Mean age	Underlying spinal pathology	Follow-up (months)	Treatment	Functional outcome	Failure of conservative management	Mortality	Morbidity	Pain outcome
Koivikko et al. <sup>[19]</sup>	25	58	Not discussed	12.2	Conservative	Not discussed	37 of the fractures had redisplaced more than 2 mm by the time the patients were discharged from hospital. Osseous fusion in 46%. Risk factors for nonunion: fracture gap > 1 mm, posterior displacement > 5 mm, delayed start of treatment > 4 days, posterior redisplacement > 2 mm	Not discussed	Not discussed	Not discussed
Kuntz et al. <sup>[20]</sup>	20		Not discussed	13-17	Conservative versus surgery	Not discussed		10% death after surgery. 10% death after conservative management	10% morbidity after surgery. 10% morbidity after conservative management	
Molinari et al. <sup>[12]</sup>	32	84	Not discussed	15	External immobilization	No significant difference in functional outcomes compared to noninjured controls	Not reported	11.8% mortality	5.9% collar-related complications	No significant difference in pain compared to noninjured controls
Ryan and Taylor <sup>[11]</sup>	9	Not reported	Not discussed	21	Conservative management	No patients developed myelopathy				
Smith et al. <sup>[4]</sup>	223	86	Not discussed	12	Conservative versus surgery	Six surgical patients (18.8%) necessitated a feeding tube versus 2 (5%) nonsurgical patients	11/58 failure rate	15% mortality rate for nonsurgical treatment (halo vest or cervical collar); 12.5% for surgical treatment	Mean complications per patient: Nonoperative-0.625, operative-1.72	8.4-11.4% with bodily pain

required surgery due to worsening of their symptoms, and close follow-up is extremely important as myelopathy following type II dens fracture, when it develops, usually occurs more than 1-year after the injury, and in 38% of cases, more than 5 years after the injury.<sup>[14]</sup> Although a halo vest is generally more appropriate to treat type II dens fracture if this injury is elected to be treated conservatively,<sup>[15]</sup> there is high morbidity and mortality associated with halo vest placement in elderly patients.<sup>[16]</sup> For this reason, a rigid collar may be preferable.

In a very select group of patients with type II dens fractures, conservative treatment can be an option if surgery is not acceptable to the patient and their family members. However, close follow-up is of immense importance as there is a good chance (40% in our series) that surgery may be imminent. Given the relative risk with surgery and short hospital stay postoperatively, surgery was offered as the preferred option of treatment for all of our patients as surgery would offer immediate stabilization. However, nonevidence-based factors often play an important role in a patient's choice of treatment option. For those patients who are reluctant to have surgery as the first choice of treatment, close follow-up is a safe and reasonable treatment pathway to utilize as long as there is clear understanding of the possibility of neurological deterioration, an agreement for frequent visits to the office, and an acknowledgment and understanding by the patient that surgery may still be a strong possibility.

## CONCLUSIONS

Treatment options for type II dens fractures are still controversial in the elderly population. Surgical treatment of this pathology has been favored. However, in a select group of patients who are clinically asymptomatic, it is relatively safe to follow them up conservatively where there is reluctance to have surgery on the patient's part. The need to have surgery will declare itself when symptoms arise and will not affect the patients' outcome. Close follow-up can accommodate both the surgeon's and the patient's concerns.

## Financial support and sponsorship

Nil.

## Conflicts of interest

There are no conflicts of interest.

## REFERENCES

- Hsu WK, Anderson PA. Odontoid fractures: Update on management. *J Am Acad Orthop Surg* 2010;18:383-94.

- Pal D, Sell P, Grevitt M. Type II odontoid fractures in the elderly: An evidence-based narrative review of management. *Eur Spine J* 2011;20:195-204.
- Huybregts JG, Jacobs WC, Vleggeert-Lankamp CL. The optimal treatment of type II and III odontoid fractures in the elderly: A systematic review. *Eur Spine J* 2013;22:1-13.
- Smith JS, Kepler CK, Kopjar B, Harrop JS, Arnold P, Chapman JR, et al. Effect of type II odontoid fracture nonunion on outcome among elderly patients treated without surgery: Based on the AOSpine North America geriatric odontoid fracture study. *Spine (Phila Pa 1976)* 2013;38:2240-6.
- Chapman J, Smith JS, Kopjar B, Vaccaro AR, Arnold P, Shaffrey CI, et al. The AOSpine North America Geriatric Odontoid Fracture Mortality Study: A retrospective review of mortality outcomes for operative versus nonoperative treatment of 322 patients with long-term follow-up. *Spine (Phila Pa 1976)* 2013;38:1098-104.
- Polin RS, Szabo T, Bogaev CA, Replogle RE, Jane JA. Nonoperative management of Types II and III odontoid fractures: The Philadelphia collar versus the halo vest. *Neurosurgery* 1996;38:450-6.
- Ekong CE, Schwartz ML, Tator CH, Rowed DW, Edmonds VE. Odontoid fracture: Management with early mobilization using the halo device. *Neurosurgery* 1981;9:631-7.
- Fujii E, Kobayashi K, Hirabayashi K. Treatment in fractures of the odontoid process. *Spine (Phila Pa 1976)* 1988;13:604-9.
- Omeis I, Duggal N, Rubano J, Cerabona F, Abrahams J, Fink M, et al. Surgical treatment of C2 fractures in the elderly: A multicenter retrospective analysis. *J Spinal Disord Tech* 2009;22:91-5.
- Hart R, Saterbak A, Rapp T, Clark C. Nonoperative management of dens fracture nonunion in elderly patients without myelopathy. *Spine (Phila Pa 1976)* 2000;25:1339-43.
- Ryan MD, Taylor TK. Odontoid fractures in the elderly. *J Spinal Disord* 1993;6:397-401.
- Molinari RW, Khera OA, Gruhn WL, McAssey RW. Rigid cervical collar treatment for geriatric type II odontoid fractures. *Eur Spine J* 2012;21:855-62.
- Smith HE, Kerr SM, Maltenfort M, Chaudhry S, Norton R, Albert TJ, et al. Early complications of surgical versus conservative treatment of isolated type II odontoid fractures in octogenarians: A retrospective cohort study. *J Spinal Disord Tech* 2008;21:535-9.
- Crockard HA, Heilman AE, Stevens JM. Progressive myelopathy secondary to odontoid fractures: Clinical, radiological, and surgical features. *J Neurosurg* 1993;78:579-86.
- Kim SK, Shin JJ, Kim TH, Shin HS, Hwang YS, Park SK. Clinical outcomes of halo-vest immobilization and surgical fusion of odontoid fractures. *J Korean Neurosurg Soc* 2011;50:17-22.
- Tashjian RZ, Majercik S, Biffl WL, Palumbo MA, Cioffi WG. Halo-vest immobilization increases early morbidity and mortality in elderly odontoid fractures. *J Trauma* 2006;60:199-203.
- Butler JS, Dolan RT, Burbridge M, Hurson CJ, O'Byrne JM, McCormack D, et al. The long-term functional outcome of type II odontoid fractures managed non-operatively. *Eur Spine J* 2010;19:1635-42.
- Koeh F, Ackland HM, Varma DK, Williamson OD, Malham GM. Nonoperative management of type II odontoid fractures in the elderly. *Spine (Phila Pa 1976)* 2008;33:2881-6.
- Koivikko MP, Kiuru MJ, Koskinen SK, Myllynen P, Santavirta S, Kivisaari L. Factors associated with nonunion in conservatively-treated type-II fractures of the odontoid process. *J Bone Joint Surg Br* 2004;86:1146-51.
- Kuntz C 4<sup>th</sup>, Mirza SK, Jarell AD, Chapman JR, Shaffrey CI, Newell DW. Type II odontoid fractures in the elderly: Early failure of nonsurgical treatment. *Neurosurg Focus* 2000;8:e7.