

De Novo Superinfection of Hepatitis B Virus in an Anti-HBs Positive Patient with Recurrent Hepatitis C Following Liver Transplantation

Sung-Hae Ha*, Young-Min Park*, Sun-Pyo Hong[†], So-Ya Back[‡], Soo-Kyeong Shin[†], Seung-Il Ji[†], Soo-Ok Kim[†], Wang-don Yoo[†], Bo-Hyun Kim*, Sang-Jong Park*, and Zheng Hong[§]

*Hepatology Center, Bundang Jesaeng General Hospital, [†]GeneMatrix, [‡]Department of Pathology, Bundang Jesaeng General Hospital, Seongnam, Korea, and [§]Surgery of Transplantation, Tianjin First Central Hospital, Tianjin, China

A 60-year-old woman with end stage liver cirrhosis caused by genotype 2 hepatitis C virus (HCV) infection received an orthotopic liver transplantation (OLT). The patient was negative for the hepatitis B surface antigen (HBsAg) and positive for the anti-hepatitis B surface antibody (anti-HBs) prior to and one and a half months following the OLT. Due to reactivation of hepatitis C, treatment with interferon-alpha and Ribavirin started two months following the OLT and resulted in a sustained virological response. We performed a liver biopsy because a biochemical response was not achieved. Surprisingly, liver pathology showed HBsAg-positive hepatocytes with a lobular hepatitis feature, which had been negative in the liver biopsy specimen obtained one and a half months post-OLT. High titers of both HBsAg and HBeAg were detected, while anti-HBs antibodies were not found. Tests for IgM anti-hepatitis B core antibody and anti-delta virus antibodies were negative. The serum HBV DNA titer was over 1×10^7 copies/mL. A sequencing analysis showed no mutation in the "a" determinant region, but revealed a mixture of wild and mutant strains at an overlapping region of the S and P genes (S codon 213 (Leu/Ile); P codons 221 (Phe/Tyr) and 222 (Ala/Thr)). These findings suggest that *de novo* hepatitis B can develop in patients with HCV infection during the post-OLT period despite the presence of protective anti-HBs. (**Gut Liver 2011;5:248-252**)

Key Words: *De novo* hepatitis B virus infection; Occult hepatitis B virus infection; Post-orthotopic liver transplantation recurrent hepatitis C; Orthotopic liver transplantation

INTRODUCTION

Orthotopic liver transplantation (OLT) remains the only curative treatment for hepatitis C virus (HCV) induced end-stage liver cirrhosis (LC),¹ although post-OLT recurrence of HCV infection is unavoidable in most of those patients. The recurrence of hepatitis C infection and concomitant disease in the liver graft may cause substantial morbidity after OLT;¹ however, it is also possible that *de novo* infection of hepatitis B virus (HBV) from donor livers, which have had occult HBV infection, may play a role in post-OLT hepatitis.²⁻⁴

It has previously been reported that the presence of anti-hepatitis B surface antibody (anti-HBs) before OLT effectively prevents *de novo* HBV infection from an anti-hepatitis B core antibody (anti-HBc) positive donor.⁵ However, another report has suggested that, despite the presence of a high titer of anti-HBs, *de novo* HBV infection from an anti-HBc positive donor could occur long after OLT, caused by a variant with an escape mutation in the "a" determinant region of the S gene.⁶

Recently, we experienced a *de novo* infection by an HBV strain without a mutation in the "a" determinant in a case with a protective level of anti-HBs in the serum before and until one and half months after OLT; the infection occurred during the administration of interferon-alpha for the treatment of recurrent hepatitis C. There was a mixture of wild and mutant strains at overlapping regions of the S and P genes, resulting in changes in the respective frame, S codon 213 (Leu/Ile) vs. P codons 221 (Phe/Tyr) and 222 (Ala/Thr). Herein we describe the clinical course and virological data of the patient.

Correspondence to: Young-Min Park

Hepatology Center, Bundang Jesaeng General Hospital, 255-2 Seohyun-dong, Bundang-gu, Seongnam 463-774, Korea

Tel: +82-31-779-0676, Fax: +82-31-779-0164, E-mail: ymp1@hotmail.com

Received on March 16, 2010. Accepted on May 24, 2010.

pISSN 1976-2283 eISSN 2005-1212 DOI: 10.5009/gnl.2011.5.2.248

© This is an Open Access article distributed under the terms of the Creative Commons Attribution Non-Commercial License (<http://creativecommons.org/licenses/by-nc/3.0>) which permits unrestricted non-commercial use, distribution, and reproduction in any medium, provided the original work is properly cited.

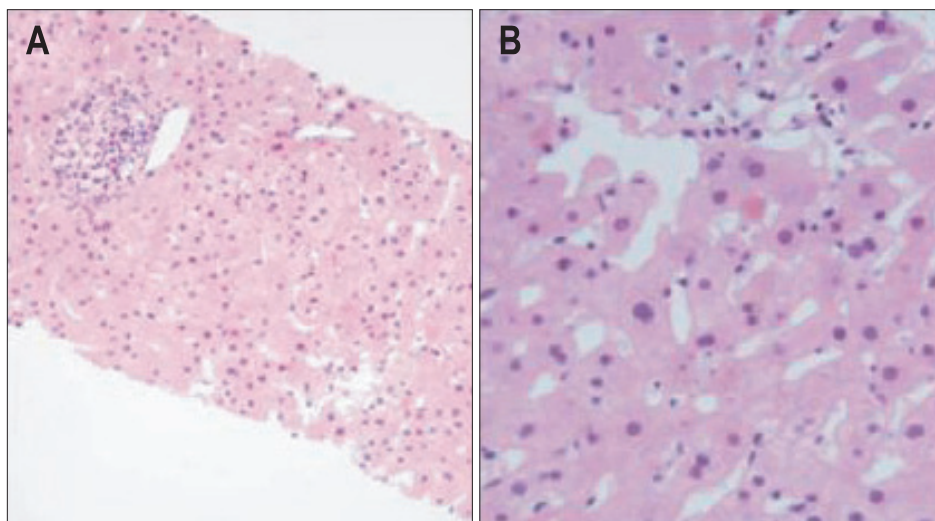


Fig. 1. Mild periportal lymphocytic inflammation with centrilobular, spotty hepatocyte necrosis is seen (A, H&E stain, $\times 100$). Note the frequent intra-acinar apoptotic bodies and focal hepatocyte necrosis (B, H&E stain, $\times 400$).

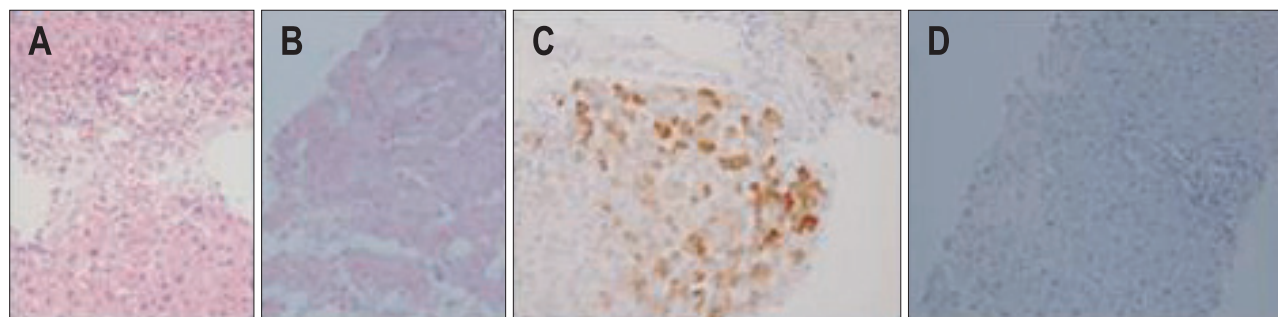


Fig. 2. Pronounced centrilobular hepatocyte damage: centrilobular confluent necrosis (A, H&E stain, $\times 200$). Note that some hepatocytes show positive cytoplasmic staining with Victoria blue solution, suggesting the presence of hepatitis B surface antigens (HBsAg) (B, Victoria blue stain, $\times 400$). Immunohistochemical stain for HBsAg shows patchy cytoplasmic staining in the liver biopsy specimen obtained 14 months post-LT (C, Envision method, $\times 200$). Comparison with negative immunohistochemical staining of the liver biopsy specimen obtained 2 months post-LT (D, Envision method, $\times 200$).

CASE REPORT

A 60-year-old Korean woman underwent OLT for end-stage liver cirrhosis caused by chronic hepatitis C. Spontaneously acquired anti-HBs was detectable and at protective titer levels before and until one and half months after OLT. HCV RNA was not detected in serum 3 weeks post OLT. Liver biopsy was performed at one and half months after OLT because the patient's serum aspartate aminotransferase (AST)/alanine aminotransferase (ALT) were elevated to 192/332 IU/L.

The first histopathologic finding did not show any evidence of acute rejection but was compatible with viral hepatitis (Fig. 1). HCV RNA became detectable in the serum at titers of 1.48×10^5 copies/mL (Roche AmplicorTM; Roche Diagnostics, Branchburg, NJ, USA). The HCV genotype 2 (single) was identified using the restriction fragment mass polymorphism (RFMP) method.⁷ Its exact subtype, however, could not be determined because of sequence variation in the subtype-determinant region.

A combination treatment of interferon-alpha 2b (IntronATM; Schering-Plough Pharmaceuticals, Kenilworth, NJ, USA), 3 million units (MU) three times a week, and ribavirin, 600 mg per

day, was started 2 months post-OLT. Soon after, however, ribavirin was withdrawn because the patient developed anemia. The time interval and dose of interferon-alpha were also adjusted to the patient's degree of leukopenia, and the duration of administration was prolonged to one year.

In spite of suboptimal adherence to antiviral therapy, HCV RNA was not detectable in the serum at one month post-treatment. Interferon-alpha injections continued for 4 months and were then stopped due to bile peritonitis, which developed 6 months post-OLT.

Though the serum aminotransferase level was normal during interferon treatment, HCV RNA was again detected in titers of 9.73×10^2 copies/mL, and the patient's AST/ALT increased to around 80 IU/mL. Both virological and biochemical responses occurred 4 months after re-treatment and persisted for 3 months. While the virological response was sustained, the serum AST/ALT re-elevated to over 60 IU/mL 8 months after re-treatment.

A liver biopsy was again performed thirteen months after the first liver biopsy. The second set of histopathological findings revealed features of lobular hepatitis with confluent necrosis

and Victoria blue staining, which strongly suggested HBsAg-positive hepatocytes (Fig. 2A and B); these findings were confirmed by immunohistochemical staining (Fig. 2C). However, such results were not seen in the first liver biopsy specimen obtained one and a half months after OLT (Fig. 2D).

Serological tests showed high titers of HBsAg (430 IU/mL, AxSYM; Abbott Laboratories, Abbott Park, IL, USA) and HBeAg (247 IU/mL, AxSYM), but the serum became negative for anti-HBs. IgM-anti-HBc and anti-delta antibody were negative. As measured by real-time PCR, HBV DNA was detectable in titers of 9.43×10^7 copies/mL. However, HBV DNA was undetectable in serum and a paraffin-embedded liver specimen collected one and a half months after OLT.

As determined by an automated sequencing method (Table 1), there were no mutations identified in the "a" determinant region of the S gene and precore/core promoter region. A mixture of

wild and mutant in the overlapping frame region of the S and P genes was found instead as follows: S codon 213 (Leu and Ile), which can be interpreted as P codons 221 (Phe and Tyr) and 222 (Ala and Thr) (Fig. 3).

The patient was started on clevudin (Levovir™; Bukwang Pharmaceutical, Seoul, Korea), 30 mg per day, soon after withdrawal of interferon-alpha. At the same time, coincidentally, gastric cancer with stage III ulcerative type was found in the patient's antrum by gastrofiberscopy 13 months post-OLT. For the treatment of gastric cancer, we performed surgical resection and

Table 1. Automated Sequencing for S and P Genes of Hepatitis B Virus (HBV) DNA

Mutation in S ORF	HBV DNA sample
sS171	Ser (TCC):Ser (TCT)=1:2
sI195M	Ile (ATA)
sP120T	Pro (CCA)
sT123N	Thr (ACC)
sK141N	Lys (AAA)
sG145R	Gly (GGA)
sV177A	Val (GTG):Ala (GCG)=3:2
sV180A	Val (GCT):Val(GTT)=1:5
sW182Stop	Trp (TGG)
sA204	Ser (AGT)
sL213I	Leu (TTA):Ile (ATG)=1:2

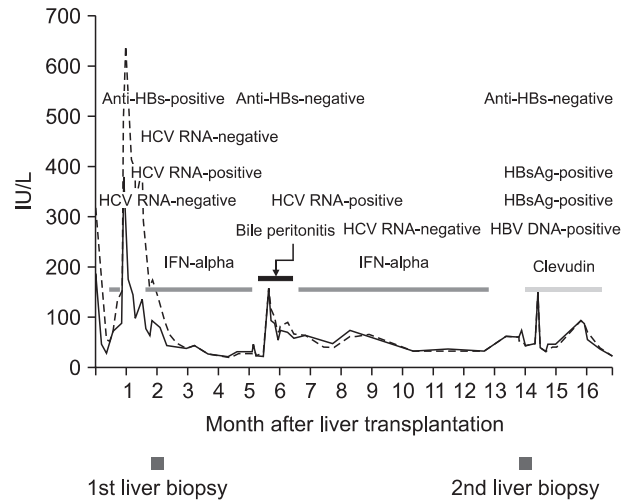


Fig. 4. Summary of the clinical course of the patient. Red and blue lines indicate alanine and aspartate aminotransferases (ALT and AST), respectively. anti-HBs, antibody to HBsAg; HCV, hepatitis C virus; HBsAg, hepatitis B surface antigen; HBV, hepatitis B virus; IFN-alpha, interferon-alpha.

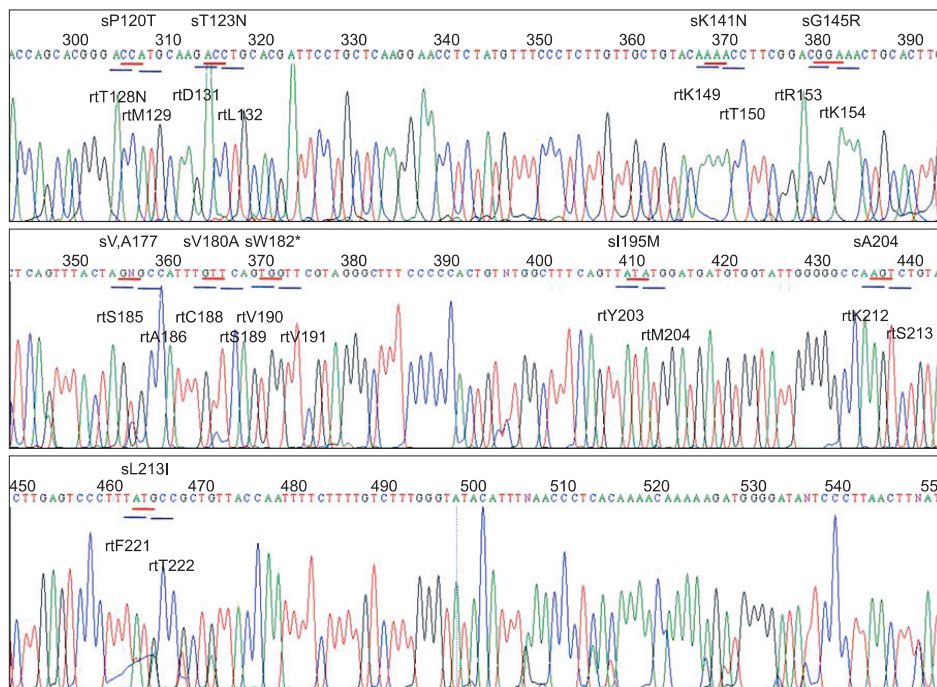


Fig. 3. No mutations were identified in the "a" determinant region of the S gene. A mixture of wild and mutant sequences in overlapping frame regions of the S and P genes was observed as follows: S codon 213 (Leu and Ile), which can be interpreted as P codons 221 (Phe and Tyr) and 222 (Ala and Thr). *sW182 stop mutation.

six cycles of adjuvant chemotherapy. Three months after clevudin treatment, HBeAg was still detected, but aminotransferase levels became normal. Fig. 4 shows a summary of the clinical course of the patient.

DISCUSSION

This case report suggests that, despite the presence of protective anti-HBs, *de novo* hepatitis B can develop in patients with recurrent hepatitis C during the post-OLT period. In this case, two possibilities are suspected regarding the source of superinfection by HBV; one is that the patient was infected by endogenous serum marker negative (silent) HBV, which was suppressed by anti-HBs; the other is that reactivation of HBV from the donor occurred, and the patient was silently infected without HBV serum markers. Both sources are so-called "occult HBV infection."

Occult HBV infection is defined as the detection of HBV DNA without HBsAg with or without the presence of HBV antibodies outside the acute phase window period.⁸ Infrequently, occult HBV may infect a patient with anti-HBs who has recovered from chronic active hepatitis, but whose HBsAg cannot be detected by usual assays for persistent, low viral replication, escape mutants.⁸

Reportedly, *de novo* HBV infection after OLT may occur in 3.5% of HBsAg-negative recipients, and it originates from donors or recipients who are anti-HBc alone or both anti-HBs and anti-HBc positive.² The use of anti-HBc-positive liver grafts makes OLT patients 2.5 times more likely to develop HBV recurrence.⁹ Therefore, recipients or donors with anti-HBc alone or who are both anti-HBs and anti-HBc positive should be carefully monitored for *de novo* HBV infection.

It is unclear how occult HBV infection is reactivated after OLT. Generally, there are two hypotheses, immune suppression and genomic mutations. As an example of the former theory, immunosuppressive chemotherapy can reactivate silent HBV infections in patients with hematological malignancies.¹⁰ The S-escape mutation clearly suggests the latter theory. In one case, *de novo* infection by an HBV variant with mutations in the "a" determinant of the S gene, Met 133 Thr (codon change ATG to ACG) and Asn 131 Thr, developed 2 years post-OLT, even though the patient had vaccine-induced anti-HBs (serum titer 256 IU/L) 1 year post-OLT.⁶

Another possibility is that HCV might promote the replication of HBV in the liver, which is frequently co-infected with the silent HBV mutant.¹¹ In this case, recurrent hepatitis C was followed by *de novo* hepatitis B. It also developed despite the presence of protective anti-HBs, but there was no mutation in the "a" determinant region of the S gene. Therefore, it is conceivable in this case that pre-activated HCV replication might have promoted the reactivation of silently infected HBV in a donor liver a short period after OLT.

A mixture of wild and mutant strains at overlapping reading frames of the S and P genes (S codon 213 (Leu/Ile), P codons 221 (Phe/Tyr) and 222 (Ala/Thr)) was detected, as shown in Fig. 3. The mutations in either the S or P gene can produce functionally significant changes in the respective overlapping gene, resulting in changed antigenicity and/or replication, but the virological and clinical significance of such overlapping mutations is unclear.¹² In this case, because HBeAg was detected and HBV DNA was still high 3 months after administration of clevudin, it should be clarified that the mutations in the overlapping frame gene regions, S codon L213I (P codons P221T and A222T), may be associated with escape mutation as well as drug resistance.

An interesting point of this case concerns the sustained HCV suppression, which occurred even with insufficient treatment of interferon-alpha. It can be partly explained by a theory that HBV superinfection in chronic HCV carriers has a severe clinical course and strongly and persistently depresses HCV.¹³ There are two hypotheses to explain the mechanism of profound suppression of chronic hepatitis C after superinfection with HBV: an anti-virus specific immune response induced by HBV infection¹⁴ and an innocent bystander mechanism induced by an HBV specific T cell response.¹⁵

In conclusion, this case report proves that post-OLT *de novo* infection of HBV without the "a" determinant mutation can develop even in patients with protective anti-HBs. In addition, *de novo* hepatitis B and recurrent hepatitis C should both be considered as etiologic factors of post-OLT hepatitis in patients with HCV infection.

ACKNOWLEDGEMENTS

Grant Support is in part by the Ministry of Commerce, Industry and Energy, Republic of Korea (Project No. 100281257).

REFERENCES

1. Willems M, Metselaar HJ, Tilanus HW, Schalm SW, de Man RA. Liver transplantation and hepatitis C. *Transpl Int* 2002;15:61-72.
2. Roche B, Samuel D, Gigou M, et al. De novo and apparent de novo hepatitis B virus infection after liver transplantation. *J Hepatol* 1997;26:517-526.
3. Dodson SF, Issa S, Araya V, et al. Infectivity of hepatic allografts with antibodies to hepatitis B virus. *Transplantation* 1997;64:1582-1584.
4. Uemoto S, Sugiyama K, Marusawa H, et al. Transmission of hepatitis B virus from hepatitis B core antibody-positive donors in living related liver transplants. *Transplantation* 1998;65:494-499.
5. Barcena R, Moraleda G, Moreno J, et al. Prevention of de novo HBV infection by the presence of anti-HBs in transplanted patients receiving core antibody-positive livers. *World J Gastroenterol* 2006;12:2070-2074.
6. Yoshida EM, Ramji A, Erb SR, et al. De novo acute hepatitis B

- infection in a previously vaccinated liver transplant recipient due to a strain of HBV with a Met 133 Thr mutation in the "a" determinant. *Liver* 2000;20:411-414.
7. Kim YJ, Kim SO, Chung HJ, et al. Population genotyping of hepatitis C virus by matrix-assisted laser desorption/ionization time-of-flight mass spectrometry analysis of short DNA fragments. *Clin Chem* 2005;51:1123-1131.
 8. Allain JP. Occult hepatitis B virus infection. *Transfus Clin Biol* 2004;11:18-25.
 9. Joya-Vazquez PP, Dodson FS, Dvorchik I, et al. Impact of anti-hepatitis Bc-positive grafts on the outcome of liver transplantation for HBV-related cirrhosis. *Transplantation* 2002;73:1598-1602.
 10. Kawatani T, Suou T, Tajima F, et al. Incidence of hepatitis virus infection and severe liver dysfunction in patients receiving chemotherapy for hematologic malignancies. *Eur J Haematol* 2001;67:45-50.
 11. Uchida T, Kaneita Y, Gotoh K, et al. Hepatitis C virus is frequently coinfecting with serum marker-negative hepatitis B virus: probable replication promotion of the former by the latter as demonstrated by in vitro cotransfection. *J Med Virol* 1997;52:399-405.
 12. Torresi J. The virological and clinical significance of mutations in the overlapping envelope and polymerase genes of hepatitis B virus. *J Clin Virol* 2002;25:97-106.
 13. Sagnelli E, Coppola N, Messina V, et al. HBV superinfection in hepatitis C virus chronic carriers, viral interaction, and clinical course. *Hepatology* 2002;36:1285-1291.
 14. Coffin CS, Mulrooney-Cousins PM, Lee SS, Michalak TI, Swain MG. Profound suppression of chronic hepatitis C following superinfection with hepatitis B virus. *Liver Int* 2007;27:722-726.
 15. Willems M, Metselaar HJ, Tilanus HW, Schalm SW, de Man RA. Liver transplantation and hepatitis C. *Transpl Int* 2002;15:61-72.