

Received: 2021.09.01
Accepted: 2021.12.07
Available online: 2021.12.16
Published: 2022.02.28

Hernioscopy Revealing Rare Abdominal Cocoon Syndrome in an Elderly Patient: A Novel Technique for Abdominal Pathology

Authors' Contribution:
Study Design A
Data Collection B
Statistical Analysis C
Data Interpretation D
Manuscript Preparation E
Literature Search F
Funds Collection G

EG 1 **Shaohan Wu***
CF 2 **Xiaofang Sun***
BC 3 **Yawei Yu**
AD 1 **Jing Wang**

1 Department of General Surgery, The Second Affiliated Hospital of Jiaxing University, Jiaxing, Zhejiang, PR China
2 Department of Dermatology, The Second Affiliated Hospital of Jiaxing University, Jiaxing, Zhejiang, PR China
3 Department of Clinical Pathology, The Second Affiliated Hospital of Jiaxing University, Jiaxing, Zhejiang, PR China

* Shaohan Wu and Xiaofang Sun contributed equally to this work

Corresponding Author:

Jing Wang, e-mail: doctoryywedu@163.com

Financial support:

This study was sponsored by the Science and Technology Program of Jiaxing (Grant number 2021AD30110)

Conflict of interest:

None declared

Patient: Male, 90-year-old
Final Diagnosis: Abdominal cocoon syndrome
Symptoms: Progressive abdominal pain, distension, and vomiting
Medication: —
Clinical Procedure: Surgical repair of bilateral hernias and hernioscopy
Specialty: Gastroenterology and Hepatology • Surgery

Objective:

Rare coexistence of disease or pathology

Background:

Incarcerated inguinal hernias (IGHs) combined with abdominal cocoons (ACs) are uncommon in adults. Abdominal cavity exploration using laparoscopy via the hernial sac (hernioscopy) has rarely been reported. Here, an elderly man with unilateral IGH complicated by a contralateral inguinal hernia and AC was found using hernioscopy. We present the surgical decision-making points in an elderly patient with IGH, enrich the diversity of AC, and propose a relatively novel hernioscopy approach.

Case Report:

A 90-year-old man presented with chronic constipation and reducible right inguinal masses. A lump in the right groin was strangulated for 2 days, accompanied with progressive abdominal pain, distension, and vomiting. The levels of inflammatory markers were elevated. Abdominal computed tomography revealed a dilated small bowel and a large mass in the right groin. Subsequently, the patient's condition quickly deteriorated. Therefore, he underwent surgical repair of bilateral hernias. Additionally, in our hospital, a total of 46 patients underwent hernioscopy because of IGH. No intraoperative or postoperative complications were observed. According to our clinical practice, hernioscopy via the bilateral hernial sacs was performed in this elderly patient. We found that almost the entire small bowel and colon were encapsulated in a fibrous and cocoon-like membrane, which postoperative pathological results revealed as AC.

Conclusions:





This is the first report to reveal that AC complicated with IGH could occur in a 90-year-old man. Hernioscopy is a relatively novel and safe surgical approach to abdominal pathology associated with incarcerated or strangulated inguinal hernias. It is rarely used in adults with IGH.

Keywords:

Case Reports • Hernia, Inguinal • Intra-Abdominal Hypertension

Full-text PDF:

<https://www.amjcaserep.com/abstract/index/idArt/934617>

 1947  —  1  24



Background

Incarcerated inguinal hernia (IGH) is a common clinical emergency in adults, usually requiring immediate surgery [1,2]. Intraoperative exploration can find IGH combined with bowel necrosis or even perforation, abdominal neoplasms, acute appendicitis, intestinal adhesion, and so on. Thus, anesthesia method, surgical procedures, and mesh materials for adult incarcerated or strangulated inguinal hernia are always individualized according to a patient's case [3,4].

An abdominal cocoon (AC) is also known as "idiopathic encapsulating peritoneal sclerosis" [5]. The small intestine and colon are either totally or partially encapsulated by a fibrocollagenous sac, which mimics a cocoon [6]. To date, several reports have revealed the clinical features, etiopathogenesis, and characteristics of pathology of AC since 1978 [7-10]. However, its etiology and pathogenesis remain unclear [8], and preoperative diagnosis remains difficult [9,11]. Therefore, most cases are accidentally discovered intraoperatively. Moreover, AC is mostly observed in young adolescent women living in tropical and subtropical regions [12]. It is rarely reported in elderly men.

Several studies have reported intestinal obstruction caused by AC [9,13]. However, few studies have reported IGH combined with AC. AC is uncommon in elderly patients. Additionally, use of hernioscopy has rarely been reported in exploring intra-abdominal conditions in adults. Interestingly, IGH combined with AC was found using hernioscopy in a 90-year-old man. We present the surgical decision-making points for a case of an elderly person with IGH, enrich the diversity of AC, and propose a relatively novel approach of hernioscopy applied to elderly patients who suffer from incarcerated or strangulated groin hernias.

Case Report

A 90-year-old man was admitted with a 2-day history of progressive abdominal pain and vomiting. He had a more than 20-year history of constipation and right reducible IGH. There was no history of surgery or tuberculosis. Physical examination of the abdomen revealed apparent abdominal distention, tympanic resonance to percussion, decreased bowel sounds, and a giant strangulated mass in the right groin. However, there were no signs of a left inguinal hernia. The skin of the scrotum was partially dark red (Figure 1A). His blood pressure was 130/66 mmHg, body temperature was 37.5°C, SpO₂ was 98%, white blood cell count was 13.85×10⁹/ml, high-sensitivity C-reactive protein (hs-CRP) level was 55.83 mg/ml, and hemoglobin concentration (Hgb) was 85 g/L. Abdominal computed tomography (CT) revealed a dilated bowel and a large mass in the right groin (Figure 1B). However, the CT scan only showed a slight broadening of the left inguinal canal and did not show a clear left hernia.

Subsequently, the patient's condition deteriorated. Therefore, he immediately underwent surgery. We made a groin incision, resulting in less trauma and a better effect. General anesthesia was administered to meet a variety of complex surgical procedures. The mass of the ischemic intestine was densely stuck, which was very difficult to rearrange (Figure 1C). The patient's small intestine could not be pulled out of the abdominal cavity. If we forcibly released the incarceration, it could increase the risk of small bowel damage and intestinal fistula. Thus, we slightly enlarged the right inguinal ring and returned these ischemic intestines after confirming that there was no necrosis after 15 min. However, to further investigate the type of hernia (ie, Maydl hernia) and any coexisting intra-abdominal pathology or further ischemia, hernioscopy was performed through the right open sac (Figure 1D). Surprisingly, all the bowel and mesenterium were almost completely encased in fibrous and cocoon-like membranes (Figure 1E, 1F). A greater omentum was absent (Figure 1F). Unfortunately, the fibrous membrane covering the intestines affected the observation and judgment of intestinal vitality and location. Overall, there was a small amount of purulent effusion in the lower abdomen, dilated bowel loops, and no signs of severe intestinal ischemia or intestinal necrosis. No definite signs of bowel obstruction were caused by AC syndrome. Moreover, a left inguinal hernia was accidentally identified (Figure 1G). There was only some fibrous tissue within the left inguinal hernia. Additionally, the protruding and stuck intestine was proved to be the terminal ileum. Therefore, right IGH is a common strangulated IGH rather than a specific type of hernia, such as a Richter hernia or a Maydl hernia. Finally, Lichtenstein hernia repair for the left inguinal hernia and Bassini hernia repair for the right IGH were performed. Drainage tubes were used to drain the inflammatory ascites and prevent infection (Figure 1H). Pathological tissue was obtained from the wall of the small intestine and from a fibrous membrane covering the surface of the ischemic intestine. Furthermore, histopathological results of the surface of the ischemic intestines revealed proliferation of fibrocytes and enrichment of collagen fibers with nonspecific inflammatory reactions (Figure 1I, 1J). The submucosa, muscular layer, serosal layer, and collagen fiber of the bowel and its fibrous membrane are clearly shown in Figure 1. These histopathological and macroscopic findings confirmed the diagnosis of AC. Inflammatory ascites were sent for bacterial culture and antibiotic drug sensitivity, but not for histological examination. This elderly patient was treated with conventional antibiotics after the operation. Moreover, the results of bacterial culture and antibiotic drug sensitivity tests were negative. A CT scan showed no evidence of leakage, recurrent hernia, or intestinal obstruction on the 5th day after the operation (Figure 1K). He was followed up for 6 months and reported a dramatic improvement in his quality of life (Figure 1L). Written informed consent was obtained from the patient for the publication of this report.

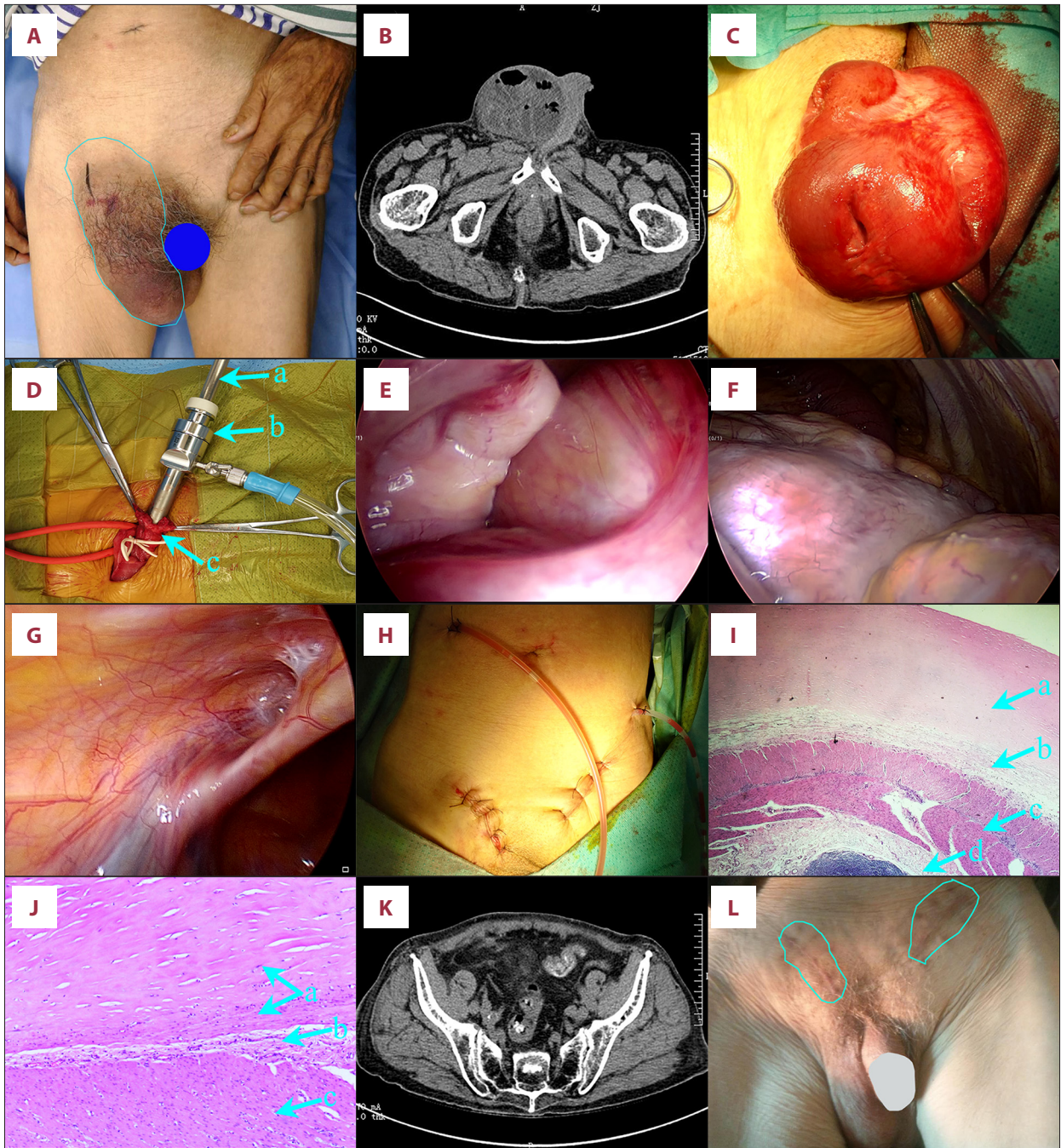


Figure 1. (A) A giant strangulated lump in the right groin within the blue line. (B) The abdominal computer tomography depicted a large lump in the right groin. (C) A mass of small intestine (the terminal ileum) was stuck together. (D) Laparoscopic exploration was performed using hernioscopy. a: lens barrel; b: 10-mm trocar; c: open hernia sac. (E, F) All the bowel and mesentery were almost totally wrapped by a fibrocollagenous and cocoon-like membrane. (G) The left inguinal hernia. (H) Drainage tubes were used to prevent infection. (I, J) Postoperative pathology of the small bowel wall and its fibrous membrane. a: fibrocyte proliferation and collagen fiber enrichment; b: serosal layer; c: muscular layer; d: the submucosa. Hematoxylin-eosin staining. (K) The abdominal computer tomography on the 5th day after operation. (L) Follow-up after 6 months. Bilateral inguinal hernia did not recur.

Discussion

When we opened the right hernia sac, a mass of the ischemic small intestine was stuck together. The surface of the small bowel was encapsulated within a thick sac (Figure 1C). We discovered that the bowel and mesenterium were almost totally wrapped by a fibrocollagenous and cocoon-like membrane. Furthermore, postoperative pathology of the small bowel wall and its fibrous membrane revealed the proliferation of fibrocytes and enrichment of collagen fibers (Figure 1I, 1J). These results are consistent with the histopathological and macroscopic manifestations of AC. Unfortunately, preoperative radiographic findings of the elderly patient were not typical AC manifestations after checking the patient's abdominal CT with the radiologists. Overall, these histopathological and macroscopic findings confirmed the diagnosis of AC.

AC is a rare peritoneal disease. The pathogenesis and mechanisms are not fully understood [14]. Many idiopathic or secondary factors can cause AC, such as abdominal tuberculosis, long-term peritoneal dialysis, history of abdominal trauma, abdominal surgery, parasite infection, bacterial infection, and intraperitoneal chemotherapy [8,15,16]. However, this patient had no such medical history. We found that the greater omentum was absent. Additionally, the intestinal tract was encapsulated by a fibrocollagenous membrane or "cocoon". Therefore, this was a typical case of idiopathic AC. With the popularization of laparoscopic techniques and advances in CT, an increasing number of AC cases are being diagnosed [11]. CT has been reported to be a valuable tool for making a definite diagnosis before surgery [14,17,18]. AC can be categorized into 3 types: type I involves part of the small bowel, type II involves the entire small bowel, and type III involves the small bowel along with the large bowel and other adjacent viscera [17]. The radiographic findings of AC patients' bowel mainly include clumped loops, inter-bowel fluid, bowel wall thickening/enhancement, and so on [18]. However, not all of these manifestations are present in a single patient [17-19]. In this case, bowel wall thickening or enhancement was not confirmed on CT. In general, clinical diagnosis is difficult without specific symptoms or radiographic findings. Therefore, a part of the AC was found during the operation and then confirmed by postoperative pathology. Surgery is the most effective method of treating AC. However, the incidence of postoperative complications and mortality are high. All symptoms in this patient were mainly caused by a strangulated hernia. Therefore, we did not deal with AC. Primary AC mainly occurs in young female patients, mostly in tropical and subtropical regions [12]. Interestingly, this 90-year-old man had strangulated groin hernias and AC, and such a case has not been reported previously.

Furthermore, a new application of hernioscopy was described to explore the abdominal cavity for contralateral groin hernias in children [20]. No large case series has been published recently. This was achieved without additional skin incisions or fascial disruptions. Unfortunately, this method is not widely used for pediatric inguinal herniorrhaphy. A small transverse abdominal incision in the inguinal area was more prevalent for pediatric inguinal hernia because of dispensing with insertion into the abdominal cavity and a shorter surgery time. Moreover, the narrow abdominal space in pediatric patients is not suitable for hernioscopy.

The abdominal cavity has rarely been explored using hernioscopy in adults. According to our clinical experience, a 10-mm trocar was inserted into the opened hernia sac to establish a pneumoperitoneum of 12 mmHg. Then, a 30° laparoscopic lens was inserted into the abdomen (Figure 1D). At the induction of anesthesia, when the hernia contents retract spontaneously into the abdomen or enterocoelia, ensuring its viability can be quite difficult. This method not only allows for a good view of the entire abdomen and avoids misdiagnosis, but also reduces tissue trauma and enables quick postoperative recovery without additional skin incision. In our medical center, hernioscopy via the open hernia sac was performed in 46 patients with IGH between August 2016 and May 2020. Furthermore, mucinous neoplasm of the appendix, acute appendicitis, and AC were found by accident. Fortunately, these patients were diagnosed and underwent treatment. Therefore, this exploration method is safe and effective for investigating the abdominal cavity and organs. However, based on our clinical practice, this technique is not suitable for pediatric patients, obese patients, or patients with abdominal adhesions. The narrow space in the abdominal cavity is not conducive to performing hernioscopy and increases the possibility of injury to the abdominal organs. Generally speaking, it is a great option, especially in adults with incarcerated or strangulated groin hernias. Unfortunately, this technique has not been detected in randomized controlled trials or prospective studies. Therefore, hernioscopy used for surgical procedures needs to be further investigated in the future.

In the past, use of mesh was considered relatively contraindicated for the repair of IGH due to the possibility of blood supply disorders, bacterial migration, and infection of the surgical area. Bassini or Shouldice is usually recommended [21]. An increasing number of studies have shown that IGH is not a contraindication for mesh repair. Mesh repair of IGH does not significantly increase the incision or mesh infection rates [22-24]. Therefore, Lichtenstein hernia repair with Prolene mesh materials was performed on the left inguinal hernia. Bassini herniorrhaphy was performed on a right strangulated hernia.

Conclusions

Here, all the findings led to a diagnosis of right IGH combined with AC in a 90-year-old man, and such a case was reported for the first time. IGH, not AC, caused small bowel obstruction. IGH and AC were not precipitating factors. Surgical decision-making for the elderly patients suffering from IGH should be made according to the actual situation of the patients. Hernioscopy used in adults is a relatively novel surgical approach, and was confirmed to be safe and effective for exploring the abdominal cavity and abdominal organs. There were no intraoperative or postoperative complications in patients who underwent hernioscopy in our medical center. Hernioscopy is a great option in clinical applications, especially in adults with incarcerated or strangulated groin hernias.

References:

1. Hassler KR, Saxena P, Baltazar-Ford KS: Open inguinal hernia repair. In: StatPearls. edn. Treasure Island FL: © 2021, StatPearls Publishing LLC; 2021. URL: <https://pubmed.ncbi.nlm.nih.gov/29083830/>
2. Pastorino A, Alshuqayfi AA: Strangulated hernia. In: StatPearls. edn. Treasure Island FL: © 2021; StatPearls Publishing LLC; 2021. URL: <https://pubmed.ncbi.nlm.nih.gov/32310432/>
3. Chen S, Tang J: [China guideline for diagnosis and treatment of adult groin hernia (2018 edition)]. *Zhonghua Wei Chang Wai Ke Za Zhi*, 2018;21(7):721-24 [in Chinese]
4. Weyhe D, Conze J, Kuthe A et al: [HerniaSurge: International guidelines on treatment of inguinal hernia in adults: Comments of the Surgical Working Group Hernia (CAH/DGAV) and the German Hernia Society (DHG) on the most important recommendations]. *Chirurg*, 2018;89(8):631-38 [in German]
5. Xia J, Xie W, Chen L et al: Abdominal cocoon with early postoperative small bowel obstruction: A case report and review of literature in China. *Medicine*, 2018;97(25):e11102
6. Karl AP, Leebmann H, Zorger N: Abdominal cocoon syndrome. *Dtsch Arztebl Int*, 2019;116(27-28):486
7. Foo KT, Ng KC, Rauff A et al: Unusual small intestinal obstruction in adolescent girls: The abdominal cocoon. *Br J Surg*, 1978;65(6):427-30
8. Li S, Wang JJ, Hu WX et al: Diagnosis and treatment of 26 cases of abdominal cocoon. *World J Surg*, 2017;41(5):1287-94
9. Ulusoy C, Nikolovski A, Öztürk NN: Difficult to diagnose the cause of intestinal obstruction due to abdominal cocoon syndrome. *Eur J Case Rep Intern Med*, 2021;8(5):002588
10. Solmaz A, Tokoçin M, Arıcı S et al: Abdominal cocoon syndrome is a rare cause of mechanical intestinal obstructions: A report of two cases. *Am J Case Rep*, 2015;16:77-80
11. Sharma V, Mandavdhare HS, Singh H et al: Significance of Bottle Gourd sign on computed tomography in patients with abdominal cocoon: A case series. *Med Pharm Rep*, 2019;92(2):192-94
12. Al-Azzawi M, Al-Alawi R: Idiopathic abdominal cocoon: A rare presentation of small bowel obstruction in a virgin abdomen. How much do we know?. *BMJ Case Rep*, 2017;2017:bcr-2017-219918
13. Karona P, Blevrakis E, Kastanaki P et al: Abdominal cocoon syndrome: An extremely rare cause of small bowel obstruction. *Cureus*, 2021;13(4):e14351
14. Singhal M, Krishna S, Lal A et al: Encapsulating peritoneal sclerosis: The abdominal cocoon. *Radiographics*, 2019; 39(1):62-77
15. Singh AU, Subedi SS, Yadav TN et al: Abdominal cocoon syndrome with military tuberculosis. *Clin J Gastroenterol*, 2021;14(2):577-80
16. Bansal P, Pal P, Ghotekar LH et al: A rare case of abdominal cocoon caused by brucellosis. *Trop Doct*, 2021 [Online ahead of print]
17. Sharma, V, Mandavdhare, HS, Singh, H et al: Significance of Bottle Gourd sign on computed tomography in patients with abdominal cocoon: A case series. *Med Pharm Rep*, 2019;92(2):192-94
18. Gorsj, U, Gupta, P, Mandavdhare, HS et al: The use of computed tomography in the diagnosis of abdominal cocoon. *Clin Imaging*, 2018;50:171-74
19. Mohakud, S, Juneja, A, Lal, H: Abdominal cocoon: Preoperative diagnosis on CT. *BMJ Case Rep*, 2019;12(5):e229983
20. Wulkan ML, Wiener ES, VanBalen N et al: Laparoscopy through the open ipsilateral sac to evaluate presence of contralateral hernia. *J Pediatr Surg*, 1996;31(8):1174-76; discussion 1176-77
21. Miserez M, Peeters E, Aufenacker T et al: Update with level 1 studies of the European Hernia Society guidelines on the treatment of inguinal hernia in adult patients. *Hernia*, 2014;18(2):151-63
22. Liu J, Chen J, Shen Y: The results of open preperitoneal prosthetic mesh repair for acutely incarcerated or strangulated inguinal hernia: A retrospective study of 146 cases. *Surg Endosc*, 2020;34(1):47-52
23. Dai W, Chen Z, Zuo J et al: Risk factors of postoperative complications after emergency repair of incarcerated groin hernia for adult patients: A retrospective cohort study. *Hernia*, 2019; 23(2):267-76
24. Majumder A, Winder JS, Wen Y et al: Comparative analysis of biologic versus synthetic mesh outcomes in contaminated hernia repairs. *Surgery*, 2016;160(4):828-38

Acknowledgements

This case was approved by the Ethics Committee of the Second Affiliated Hospital of Jiaxing University (Chairperson professor Gang Chen), 2020. Additionally, this study was conducted according to the ethics standards of the Responsible Committee on Human Experimentation (institutional and national) and complied with the Helsinki Declaration.

Declaration of Figures' Authenticity

All figures submitted have been created by the authors who confirm that the images are original with no duplication and have not been previously published in whole or in part.