

This sometimes requires prosthetic hip replacement. Renal transplant patients are now being examined with a view to the earlier diagnosis of this condition. Three such cases, one bilateral, have so far come to light (Figure 12). Conventional radiographs, computerised tomography and isotope studies have been normal on these patients.

The investigation of the hips of these patients has enabled us to study in addition the transplanted kidneys which are well shown on the coronal images of the hips. The healthy transplant shows a clear differentiation of renal cortex and medulla on the T₁ sequences (Figure 13), a feature which is lost in the kidney undergoing rejection.

COMMENT

Our experience at Southmead Hospital has confirmed the recognised value of MR in the investigation of the central nervous system, including the spinal canal where its use excludes the necessity of intrathecal injection of contrast medium. In addition, however, we recognise that the method has widespread applications outside the central nervous system, notably in the genito-urinary tract, the musculo-skeletal system and in the investigation of the renal transplant patient. It is a rapidly developing imaging modality and signs indicate that it might

well become the investigation of choice in the study of the circulatory system with all that implies.

Acknowledgements

It is a pleasure to record our thanks for the technical expertise of our radiographers, Ann Case and Joanne Waring and of Allen Wood of Picker International.

REFERENCES

1. PRANT-ZAWADSKI, M. (1988) Magnetic Resonance: state of the art. MR imaging of the brain. *Radiology* **166**, 1-10.
2. BYDDER, G. M. (1984) Magnetic resonance imaging of the brain. *Radiologic Clinics of North America* **22**, No. 4.
3. BRYAN, P. J. BUTLER, H. E. NELSON, A. D. LIPOMA, J. P. KOPIWODA, S. Y. RESNICK, M. I. COHEN, A. M. HAAGAN, J. R. (1986) Magnetic resonance imaging of the prostate. *AJR* **146**, 543-548.
4. HEIKEN, J. P. LEE, J. K. T. (1988) MR imaging of the pelvis. *Radiology* **166**, 11-16.
5. AMENDOLA, M. A. GLAZER, G. M. GROSSMAN, H. B. AISEN, A. M. FRANCIS, I. R. (1986) Staging of bladder carcinoma: MRI-CT-surgical correlation. *AJR* **146**, 1179-1183.
6. SARTORIS, D. J. RESNICK, D. (1987) MR imaging of the musculo-skeletal system. *AJR* **149**, 457-467.
7. BELTRAN, J. NOTO, A. M. MOSURE, J. C. WEISS, K. L. ZOELZER, W. CHRISTOFONDIS, A. J. (1986) The Knee. Surface coil MR imaging at 1.5T. *Radiology* **159**, 747-751.

MRI in Pregnancy: The Diagnosis of Vasa Previa by Magnetic Resonance Imaging

M. J. Nimmo, MB ChB; D Kinsella, MRCP; H. S. Andrews, FRCR

Case Report

A 24-year-old woman was admitted at 32 weeks gestation for investigation of painless antepartum haemorrhage. The pregnancy had been uneventful with a normal routine ultrasound at 16 weeks. Ultra-sound following admission demonstrated a posterior placenta within 5cm of the internal os, and a succenturiate lobe anteriorly, also within 5cm of the internal os. The exact relationship of these structures was difficult to determine.

Following two further episodes of antepartum haemorrhage, magnetic resonance imaging was carried out at 34 weeks gestation. Sagittal and coronal sections were obtained on a Picker MRI system using T1 weighted pulse sequences (sagittal TR 300 ms, TE 30 ms, coronal TR 500 ms, TE 26 ms). Figure 1 demonstrates the normal placenta on the posterior uterine wall, terminating just over 1 cm from the internal os. A succenturiate lobe lies on the anterior wall terminating 3.5cm from the os. Blood vessels are clearly seen between these, lying between the foetal head and the os.

After several further minor episodes of bleeding, an ultrasound study at 36 weeks confirmed the finding of fluid filled structures (blood vessels) between the foetal head and the os. Detailed visualisation of the placental relationship to the internal os again proved difficult.

At 36.4 weeks, a healthy boy of 2.5 kg was delivered by emergency lower section Caesarian Section. The MRI findings were confirmed at operation.

Discussion

The value of MRI in placenta praevia has previously been demonstrated by Powell et al (1), but no reports of vasa previa have appeared in the literature. We confirm the finding that MRI has a complementary role with ultrasound in patients where ultrasonic visualisation of the internal os and placenta is equivocal.

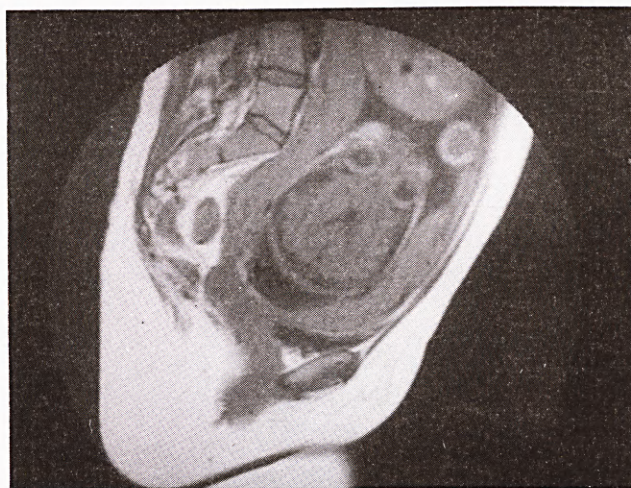


Figure 1

Cephalic presentation with vasa previa
Sagittal T₁ Weighted MRI Scan.

The high cost of MRI and its limited availability contrast with ultrasound, but ultrasound examination of patients presenting with antepartum haemorrhage will select a smaller group in which MRI will clarify equivocal appearances. In this situation its cost-effectiveness can be maximised.

REFERENCES

1. Magnetic Resonance Imaging and Placenta Previa, Powell, M. C. Buckley, J. Price, H. Worthington, B. S. Symonds, E. M. *Am J Obstet Gynecol* 1986; **154**, 565-569.