

Relationship Between the Computed Tomographic Volumetry of the Eyeballs and Lacrimal Glands in a Nigerian Population

Abstract

Aim: The aim of this article was to obtain measurements of the eyeballs/globes and lacrimal glands in normal subjects using cranial computed tomography (CT) scan. Understanding the normative approximations of these measurements could help in diagnosing and evaluating orbito-ocular pathologies. **Materials and Methods:** This retrospective study examined 220 globes/eyeballs and 220 lacrimal glands of 110 consecutive participants. The eyeball volume was calculated using both the ellipsoid and spherical formulas, whereas lacrimal gland volume was approximated using the ellipsoid formula only. **Results:** The mean age of the subjects was 51.18 ± 14.85 years and ranged from 22 to 85 years. The study population was 53.6% male ($n = 59$) and 46.3% female ($n = 51$). The mean volumes of all globes in this study were 5.82 ± 0.77 and 5.98 ± 0.75 cm³ using the ellipsoid and spherical formulae, respectively. The mean volume of all lacrimal glands was 0.42 ± 0.14 cm³ using the ellipsoid formula. The mean globe volumes using the ellipsoid and spherical formulae (6.02 ± 0.84 and 6.02 ± 0.84 cm³) in males were significantly larger than the corresponding mean globe volumes in females (5.59 ± 0.62 and 5.80 ± 0.65 cm³) ($P < 0.0001$ and $P = 0.001$, respectively). There was no significant difference between the lacrimal gland volumes of males (0.42 ± 0.14 cm³) and females (0.42 ± 0.14 cm³) ($P = 0.84$). **Conclusion:** Males have larger eyeball/globe volumes than females. Eyeball and lacrimal gland volumes did not correlate significantly. Eyeball volume showed an inverse relationship with age. Age did not affect lacrimal gland volume.

Keywords: Computed tomography, globe, lacrimal gland, Nigeria, normative dimensions

Introduction

The lacrimal gland is an eccrine gland that secretes tears and is located proximal to the superior and lateral rectus muscles.^[1] The lacrimal gland is vital for ocular surface health, comfort, and maintenance of the optical quality of the cornea and by extension of the eye.^[2] Globe and lacrimal gland measurements are important in the overall understanding of various pathologies in the orbit, particularly in the fields of ophthalmology and craniofacial surgery.^[3,4] Various imaging modalities have been used in managing and monitoring various orbito-ocular pathologies. Magnetic resonance imaging (MRI) provides better soft tissue resolution, whereas computed tomography (CT) allows for better visualization of calcifications and bony changes.^[1,5] Normative measurements of the globes and lacrimal glands of various ethnicities around the world have been documented.^[6-12]

There is paucity of data on the globe and lacrimal gland CT measurements of Nigerians

and other sub-Saharan Africans. There are few Nigerian studies that described globe volumes on cross-sectional imaging,^[1,13-16] but only one on CT dimensions of the lacrimal gland. We could find no study in the English language literature that assessed the relationship between eyeball dimensions and lacrimal gland dimensions on CT. Therefore, the aim of this study was to evaluate the relationships between CT dimensions of the globes and lacrimal glands in a cosmopolitan Black African population.

Materials and Methods

This was a retrospective study of 110 consecutive cranial computed tomography (CT) scans (220 globes; 220 lacrimal glands) acquired at a radiodiagnostic centre in Lagos, Nigeria. The study protocol conformed to the ethical guidelines of the 1964 Declaration of Helsinki and its latest revisions in 2013.

The electronic records of the patients were explored to extract their demographic characteristics, nationality, indications for

Bukunmi Michael Idowu¹,
Stephen Olaoluwa Onigbinde²,
Allen Li Chen³,
Jordan B. Hughes³,
Oluwaseun Olaniyi Awe^{4,5},
Joseph Adetola Adedigba³

¹Union Diagnostics and Clinical Services, Yaba, Lagos, Nigeria, ²Department of Anatomical Sciences, School of Medicine, St George's University, Grenada, West Indies,

³Tulane University School of Medicine, New Orleans, LA, USA, ⁴Department of Ophthalmology, Obafemi Awolowo University, Ile-Ife, Nigeria, ⁵Department of Ophthalmology, Obafemi Awolowo University Teaching Hospital Complex, Ile-Ife, Nigeria

Received: 23-Mar-2022

Accepted: 26-Apr-2022

Published: 23-Aug-2022

Address for correspondence:

Dr. Bukunmi Michael Idowu,
 Union Diagnostics and Clinical Services, Yaba, Lagos, Nigeria.
 E-mail: ibmcontacts@gmail.com

Access this article online

Website:

www.jwacs-jcoac.com

DOI: 10.4103/jwas.jwas_66_22

Quick Response Code:



How to cite this article: Idowu BM, Onigbinde SO, Chen AL, Hughes JB, Awe OO, Adedigba JA. Relationship between the computed tomographic volumetry of the eyeballs and lacrimal glands in a Nigerian population. *J West Afr Coll Surg* 2022;12:34-40.

This is an open access journal, and articles are distributed under the terms of the Creative Commons Attribution-NonCommercial-ShareAlike 4.0 License, which allows others to remix, tweak, and build upon the work non-commercially, as long as appropriate credit is given and the new creations are licensed under the identical terms.

For reprints contact: reprints@medknow.com

imaging, and other relevant medical information. Craniofacial CT scans of patients aged 18 years and above with non-orbito-ocular indications for imaging were enrolled into the study. Scans were excluded if the patient was non-Nigerian, had poor image quality or had obvious structural variation(s), or abnormality in the anatomy of the globe such as aphakia or presence of an intraocular implant and other evident ocular, orbital, or lacrimal pathologies on CT. A Siemens 16-slice Somatom AR.T CT scanner (Siemens Healthineers AG, Erlangen, Germany) was used. The cranial CT scans were performed in an axial plane from the skull base to the vertex, with a slice thickness of 2.5 mm.

The measurements were obtained directly on the computer control console of the CT scanner. We measured the anteroposterior (AP) and transverse (TS) diameters of the lacrimal glands on axial images [Figure 1], whereas the craniocaudal (CC) diameter was obtained on reformatted coronal images [Figure 2]. On the axial images, AP diameter of the lacrimal gland was measured from the most posterior edge of the gland to its most anterior edge. The TS diameter was measured perpendicular to the AP diameter, from the medial edge to the lateral edge of the gland at its widest location.^[10] On the coronal images, the CC diameter was measured from the superior edge to the inferior edge of the lacrimal gland. The TS diameter of the lacrimal gland on coronal view was also determined in this image. All the measurements were obtained on any slice that demonstrated the maximal extent of the lacrimal gland.^[10] The lacrimal gland volume was calculated using the ellipsoid formula as craniocaudal diameter (cm) × anteroposterior diameter (cm) × axial transverse diameter (cm) × 0.523 (mL). The lacrimal TS diameter on the coronal view was not included in the volume calculation, but was statistically compared to the axial TS diameter to determine any differences.

The globe measurements (inner margin to inner margin) were obtained from the axial scans taken at the level of the maximal thickness of the lens showing the optic nerve (mid-ocular axial section) [Figure 3]. The AP and TS diameters of the globes

were measured on a mid-ocular axial section in which the axial size of the globes and lenses is maximal.^[16] The AP diameter (axial length) of the globe was measured with the measuring calipers positioned at the level of the posterior (inner) corneal surface to the inner choroid interface. Images were magnified sufficiently enough to improve precision of placement of the digital measuring caliper without compromising image sharpness. The TS diameter (width) was the maximal distance from the nasal to the temporal ends of the globe. The ocular CC diameter was the maximum distance between the cranial and caudal ends of the globe on a reformatted mid-coronal image [Figure 4]. The TS diameter of the globe on coronal view was also determined in this image using an average of three measurements. The ocular TS diameter on the coronal view was not included in the volume calculation but was statistically compared with the axial TS diameter to determine any differences. One consultant radiologist performed all the CT measurements in the soft tissue window.

Statistical analysis

Descriptive statistics were utilized to describe the demographics of the sample populations. Paired sample *t*-test was used to compare related groups means, and unpaired *t*-test was used

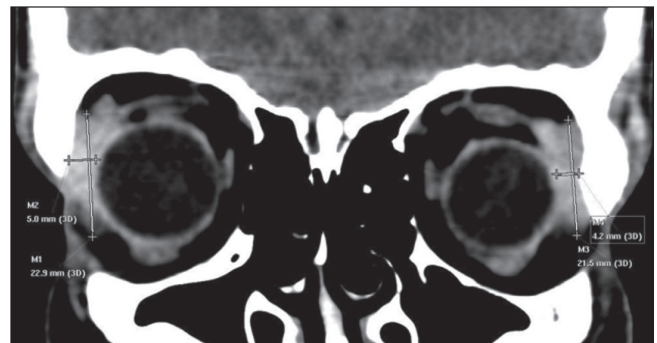


Figure 2: Coronal CT reformat of the lacrimal glands showing the craniocaudal diameters (lines M1 and M3) and coronal plane transverse diameters (lines M2 and M4)

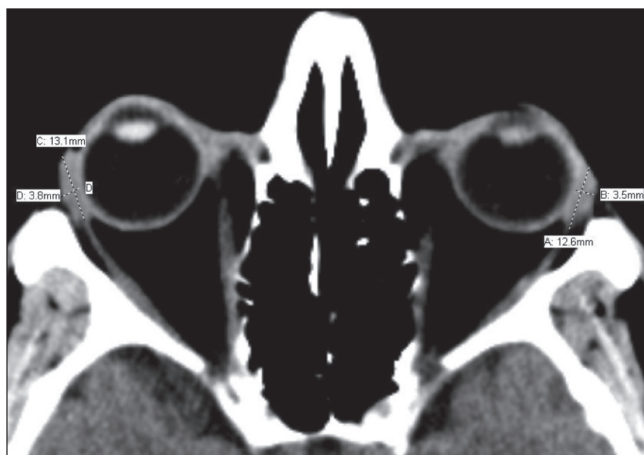


Figure 1: Axial CT of the lacrimal glands showing the anteroposterior diameters (lines A and C) and transverse diameters (lines B and D)

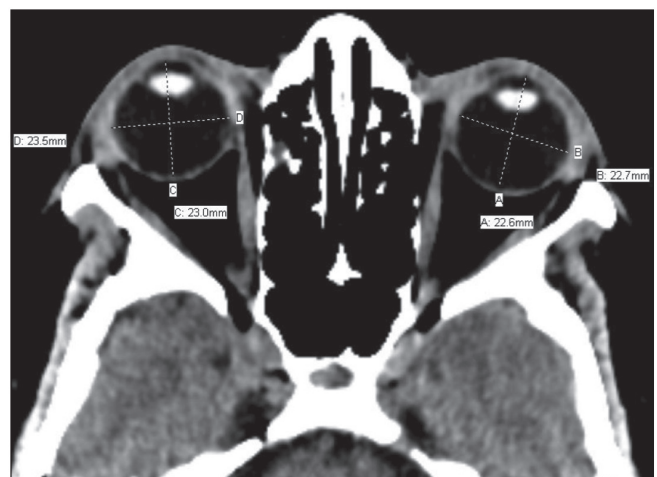

Figure 3: Axial CT of the eyeballs/globes at the level of the lens showing the anteroposterior diameters (lines A and C) and transverse diameters (lines B and D) of the eyeballs

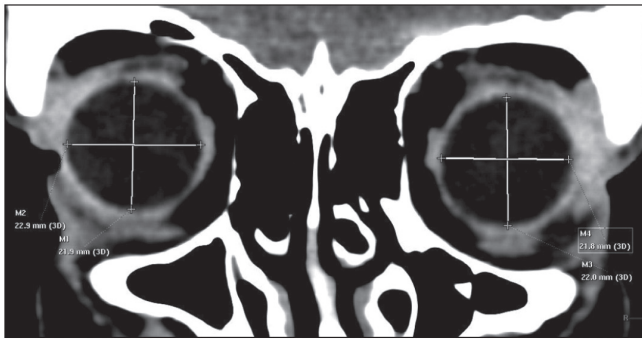


Figure 4: Coronal CT reformat of the eyeballs/globes showing the craniocaudal diameters (lines M1 and M3) and coronal plane transverse diameters (lines M2 and M4) of the eyeballs

to compare independent group means. One-way analysis of variance (ANOVA) with a Bonferroni *post hoc* test was used to analyse multiple groups. Pearson’s correlation was used to evaluate linear relationships between groups. Normality was always checked using the Shapiro–Wilk test; otherwise, the Mann–Whitney test and non-parametric methods were used to evaluate differences between groups. The globe volume was calculated using the two formulas:

The ellipsoid formula^[16] (cm³) is:

$$\text{Craniocaudal diameter (cm)} \times \text{Anteroposterior diameter (cm)} \times \text{Axial transverse diameter (cm)} \times 0.523.$$

The spherical formula^[14] (cm³) is $\frac{4}{3}\pi r^3$,

where

$$r = \frac{(\text{anteroposterior diameter} + \text{axial transverse diameter})}{4}$$

Lacrimal gland volume approximations were calculated using the following formula: Ellipsoid volume = Craniocaudal diameter (cm) × Anteroposterior axial diameter (cm) × Transverse axial diameter (cm) × 0.523.^[16]

Differences in volumes and linear dimensions between groups were considered statistically significant at a *P*-value of less than 0.05. The data were analysed using GraphPad Prism version 8.0 (GraphPad Software Inc., San Diego, CA, USA).

Results

The mean age of the enrolled subjects was 51.18 ± 14.85 years and ranged from 22 to 85 years. The study population consisted of 53.64% male (*n* = 59, mean age 50.34 ± 15.07 years) and 46.36% female (*n* = 51, mean age 52.16 ± 14.69 years).

Both ellipsoid and spherical volume approximations were made for globes, whereas only ellipsoid volume was applied to the lacrimal glands. The mean ellipsoid volume of globes in this study was 5.82 ± 0.77 cm³, while the mean spherical volume was 5.98 ± 0.75 cm³. There was a significant difference between the ellipsoid volume and spherical volume approximations for globes (*P* < 0.0001). For all patients, mean right globe ellipsoid

volume was 5.86 ± 0.82 cm³ and mean left globe volume was 5.79 ± 0.73 cm³; no significant difference existed between the left and right globes (*P* = 0.46). For the spherical formula, the mean right globe volume was 5.99 ± 0.73 cm³ and left globe volume was 5.97 ± 0.78 cm³, with no significant difference (*P* = 0.87).

The mean globe ellipsoid volume for males (6.02 ± 0.84 cm³) was significantly larger than the mean globe ellipsoid volume for females (5.59 ± 0.62 cm³) (*P* < 0.0001). Likewise, the mean globe spherical volume for males (6.13 ± 0.80 cm³) was significantly larger than the mean globe spherical volume for females (5.80 ± 0.65 cm³) (*P* = 0.0012). These relationships are both depicted in Table 1. The average male globe ellipsoid volume was 7.69% larger than the volume of the average female globe, whereas the male globe was 5.69% larger using the sphere approximation.

The volumes of the left and right globes were compared within sexes. For both the ellipsoid and spherical globe approximations, there was no significant difference between the left and right globes for both males and females, as depicted in Table 1.

The mean ellipsoid volume of all lacrimal glands in this study was 0.42 ± 0.14 cm³. For all subjects, the mean volume of right lacrimal glands was 0.43 ± 0.14 cm³ and of left lacrimal glands was 0.41 ± 0.14 cm³ with no significant difference in volume (*P* = 0.33). There was no significant difference between the lacrimal gland volumes of males (0.42 ± 0.14 cm³) and females (0.42 ± 0.14 cm³) (*P* = 0.84). There was also no significant difference when comparing left and right lacrimal gland volumes for both males and females, as shown in Table 1.

Next, we evaluated the linear diameters: AP, CC, and TS for globes and the lacrimal glands’ AP and CC diameters. The mean male globe CC diameter (2.23 ± 0.18 cm) was significantly larger than that for females (2.16 ± 0.13 cm) (*P* = 0.0006). The mean male globe TS diameters (2.33 ± 0.13 cm) were significantly larger than those for females (2.27 ± 0.11 cm) (*P* = 0.0005). The mean male globe AP diameters (2.20 ± 0.10 cm) were not significantly different from those for females (2.18 ± 0.09 cm) (*P* = 0.084).

For the lacrimal gland linear parameters, mean male AP diameter (1.31 ± 0.16 cm) was not significantly different from the mean diameter for females (1.30 ± 0.16 cm) (*P* = 0.85). The mean male CC diameter (1.40 ± 0.17 cm) was also not significantly different from the mean female CC diameter (1.37 ± 0.19 cm) (*P* = 0.24). Our analysis showed no significant difference between male lacrimal gland mean TS axial diameter (0.43 ± 0.08 cm) and male lacrimal gland mean TS coronal diameter (0.43 ± 0.07 cm) (*P* = 0.80). However, there was a significant difference between female lacrimal gland mean TS axial diameters (0.44 ± 0.08 cm) and female lacrimal gland mean TS coronal diameters (0.41 ± 0.07 cm) (*P* = 0.0027). There was no significant difference found when all lacrimal gland mean TS axial diameters (0.43 ± 0.08 cm)

Table 1: Lacrimal gland volume and eyeball volume by sex

Sex	CEEV (cm ³)	CSEV (cm ³)	EREV (cm ³)	ELEV (cm ³)	P-value	SREV (cm ³)	SLEV (cm ³)	P-value	RLGV (cm ³)	LLGV (cm ³)	P-value
Males (n=59)	6.02±0.84	6.13±0.80	6.02±0.88	5.96±0.80	0.20	6.13±0.73	6.13±0.87	0.97	0.43±0.13	0.41±0.15	0.14
Females (n=51)	5.59±0.62	5.80±0.65	5.62±0.67	5.58±0.59	0.42	5.82±0.69	5.78±0.61	0.41	0.42±0.15	0.41±0.14	0.38
P-value	<0.0001	0.0012									

CEEV: combined (both eyes) ellipsoid eyeball volume, CSEV: combined (both eyes) spherical eyeball volume, EREV: ellipsoid right eyeball volume, ELEV: ellipsoid left eyeball volume, SREV: spherical right eyeball volume, SLEV: spherical left eyeball volume, RLGv: right lacrimal gland volume, LLGv: left lacrimal gland volume

were compared with all lacrimal gland mean TS coronal diameters (0.42±0.07 cm).

We divided the cohort into age groups and mean globe/lacrimal gland volumes associated with each group in Table 2. One-way ANOVA yielded significant differences among the age groups regarding globe volumes for both the ellipsoid and spherical approximations. There were no differences between age groups for lacrimal gland volumes. Table 3 compares the lacrimal gland dimensions in this study with those of some previous studies.

We evaluated the correlation of all globe volumes (ellipsoid/spherical approximations). Globe ellipsoid volume approximation demonstrated a weak but significant negative correlation ($r = -0.23, P = 0.01$). However, when the spherical volume approximation was used, the correlation became non-significant ($r = -0.18, P = 0.06$).

Lacrimal gland volumes and age were correlated and yielded Pearson's correlation $r = -0.01658, P = 0.8635$; hence, there was no significant correlation between lacrimal gland volumes and age. There was no statistically significant correlation between globe volumes and lacrimal gland volumes in this study.

We correlated the globes' AP, CC, TS diameters with age and lacrimal glands' AP, CC diameters with age. Only the globes' CC diameter showed a significant weak negative correlation with age ($r = -0.21, P = 0.02$).

Discussion

Globe volume is a crucial parameter in understanding the pathophysiology of many orbito-ocular diseases such as macrophthalmus, buphthalmus, and microphthalmus.^[17] Quantifying the globe volume in a cohort of subjects with normal physiology can help in both medical and surgical management of orbito-ocular diseases.^[16] Previous studies have used either the ellipsoid or spherical formula to calculate globe volume.^[14,16] The mean spherical globe volume in our study (5.98±0.75 cm³) is marginally larger than the spherical globe volume of 5.28 cm³ reported by Igbiniedion and Ogbeide,^[14] but smaller than the spherical globe volume of 6.75 cm³ of Ibinaiye *et al.*^[16] It is noteworthy that while the former used CT scan, the latter study used MRI.

This study used both formulae to quantify globe volume to check how the two resulting volumes varied among male and female subjects. We found that the volume of male globes is significantly larger than the volume of female globes using both formulae. On average, the volume of male globes was larger than the volume of female globes by 7.69% and 5.69% using the ellipsoidal and spherical formulas, respectively. This appears consistent with a previous study that demonstrated that Iranian males had a larger globe volume than those of Iranian females.^[3] However, there was no significant side-to-side difference between the right and left globe volumes in males and females using both formulae. Similar studies measuring globe volume of Nigerian eyes reported a larger volume of

Table 2: Lacrimal gland and eyeball volume by age group

Age group (years)	Number of subjects	Eyeball ellipsoid volume (cm ³)	Eyeball sphere volume (cm ³)	Lacrimal gland volume (cm ³)
20–29	20	5.53	5.62	0.44
30–39	20	6.38	6.30	0.39
40–49	20	5.95	6.11	0.42
50–59	20	5.92	6.24	0.42
60+	30	5.53	5.64	0.42
<i>P</i> -value		0.0022	0.0007	0.90

Table 3: Comparison of right and left lacrimal gland dimensions in different ethnicities

	Index study	Nawaz et al. ^[11]	Bulbul ^[7]	Danjem and Salaam ^[1]	Lee et al. ^[23]	Tamboli et al. ^[10]
Right lacrimal						
AL (mm)	14.41	13.53	16.2	14.6	14.9	14.7
AW (mm)	4.31	4.20	4.1	4.1	4.1	5.1
CL (mm)	13.80	15.46	18.3	20.7	20.9	16.9
CW (mm)	4.30	3.99	4.1	2.9	3.6	5.2
Left lacrimal						
AL (mm)	13.90	13.35	16.0	14.5	14.7	14.5
AW (mm)	4.30	4.05	4.0	4.1	4.3	4.8
CL (mm)	13.80	15.26	18.3	20.8	20.7	16.9
CW (mm)	4.20	3.86	4.1	3.0	3.8	5.2

AL: axial length (anteroposterior diameter on axial view), AW: axial width (transverse diameter on axial view), CL: coronal length (craniocaudal diameter on coronal view), CW: coronal width (transverse diameter on coronal view)

male eyes compared with female eyes, although the difference was not statistically significant.^[14,16] Male CC diameter being significantly longer than female CC diameter is another possible explanation for the larger globe volume found in males as any increased diameter of a three-dimensional structure will lead to increased volume. Male globe volumes being larger than female globe volumes could be due to males having a bigger body habitus than females, and this leads to male organs being bigger than the corresponding female organs.^[18,19]

As the relationships of globe volume in inter-sex and intra-sex groups remain consistent using either the ellipsoid or spherical formula, this could mean that the two formulae are interchangeable when used to approximate globe volume. It is also noteworthy that while both formulas showed consistent relationships with age and gender, the spherical formula approximated a volume significantly larger than the ellipsoid volume. Igbiniedion and Ogbeide^[14] preferred the spherical formula because they believed that it reduced the likely margin of error associated with the ellipsoid formula. It is also known that the globe is not a perfect sphere. As there is a paucity of literature comparing these two formulas in the same study, further studies using globe models of known volumes will help to determine which of the two formulas approximates globe volume better.

Interestingly, Pearson's linear regression analysis comparing globe volume with age showed a weak negative, albeit significant, correlation. Igbiniedion and Ogbeide^[14] and Hahn and Chu^[20] both reported decline in globe volume from 50 and 30 years, respectively. A possible explanation for this finding could be that the structural proteins in the globe lose their

integrity with age, thus resulting in a mild reduction in globe volume over time.^[20] Ageing, through multiple mechanisms, leads to enhanced degradation of extracellular matrix proteins such as elastin and collagen, thus resulting in decreased structural integrity of these proteins.^[21] Furthermore, choroidal volume which includes vasculature, stroma, and connective tissue has been shown to decrease with age.^[22] The cumulative physiological effects of ageing may contribute to the overall loss of globe size over time.

The CC diameter was longer in males compared with females and decreased with increasing age. The globe axial TS diameter was longer in males than in females. This finding is congruent with a study by Bulbul^[7] who found statistically significant differences among males and females regarding globe axial length. While Bulbul^[7] found a significant correlation between age and globe axial diameter, this study found no correlation between age and globe axial diameter. This difference could be due to the higher statistical power of our sample population. The globes' AP diameter was not significantly correlated with age or gender.

Lacrimal gland volumes reported by prior studies have been generated using tracings and not mathematical formulas, which might provide a more exact approximation.^[8,19] This is the first study, to the best of our knowledge, to quantify lacrimal gland volumes using the ellipsoid formula. Studies using the freehand pencil tracing method found a right lacrimal gland volume of 0.696 ± 0.261 cm³ and left lacrimal gland volume of 0.649 ± 0.231 cm³ in a Caucasian population in the USA and 0.617 ± 0.210 cm³ (right lacrimal) and 0.597 ± 0.197 cm³ (left lacrimal) in Turkey.^[7,9] These values are higher than the

mean lacrimal gland volume ($0.42 \pm 0.14 \text{ cm}^3$) of all subjects in this study using the ellipsoid formula. Unlike globe volume, sex had no correlation with lacrimal gland volume as our analysis showed that there is no difference between the lacrimal volumes of males and females. This finding is also supported by the results in a study describing the CT-measured lacrimal gland volumes using freehand pencil tracing in a Caucasian population in USA.^[9] We also found that age had no correlation with lacrimal gland volume.

Studies among Caucasian and Korean populations using freehand pencil tracing have shown that an increase in age correlated with a decrease in lacrimal gland volume.^[9,10,23] Obata *et al.*^[24] speculated that the decreased lacrimal gland size with age is probably due to periductal fibrosis resulting from decreased tear outflow as people age. Our study did not agree with this finding in the other studies. We suspect that the discrepancy could be due to different methods used to approximate the lacrimal gland volumes. Comparing the approximation formula with the tracing method, there is a possibility that these two methods are interchangeable among males and females but yield different approximations between age groups. The statistical power of our cohort could have affected our finding on the relationship between age and lacrimal gland volume. Also, the lacrimal gland linear variables (AP and CC diameter) were not significant with age and gender, which also explain the similar pattern seen with lacrimal volume mentioned earlier. Regarding the two methods of lacrimal volume approximations, there need to be more studies that explore if the formula method is more accurate, considering that the formula method might eliminate the potential human error associated with the freehand pencil tracing method.

Although we found no statistically significant correlation between globe volume and lacrimal gland volume, we could not compare this observation to previous studies because the relationship between globe volume and lacrimal gland volume is currently understudied in the literature. Further exploration of this relationship would be needed to properly ascertain the relationship between globe volumes and lacrimal gland volumes. However, Tenzel *et al.*,^[25] using MRI, reported that lacrimal gland volume (generated using OsiriX software) correlated with orbital volume, though the correlation coefficient was not stated.

The lacrimal gland TS axial diameter and lacrimal gland TS coronal diameter are the same measurements from two viewpoints (axial and coronal). When controlling for sex, there was no significant difference between the male lacrimal gland TS axial diameters and lacrimal gland TS coronal diameters, but there was a significant difference between these dimensions among female subjects. This difference disappears when all TS axial diameters were compared with all TS coronal diameters in this patient population. This lack of significant difference among all subjects in this cohort could mean that either axial TS diameter or coronal TS diameter would suffice for lacrimal

gland volume calculations using the ellipsoid formula. Since this is probably the first study to explore the interchangeability of these two measurements in the ellipsoid formula, more studies with higher statistical power are needed to ascertain if both measurements are statistically similar.

Comparing our linear dimensions with other populations around the world, the reported lacrimal gland axial diameter in Caucasians (0.48 cm on the left and 0.51 cm on the right)^[9] is higher than the axial diameter in this study ($0.43 \pm 0.082 \text{ cm}$), whereas the reported Korean (right = 0.41 cm, left = 0.43 cm)^[23] and Pakistani (right = 0.42 cm, left = 0.41 cm)^[11] axial diameters are similar to ours. The coronal diameter of the lacrimal gland in our study ($0.42 \pm 0.068 \text{ cm}$) was lower than that reported in a similar study of Caucasians (0.52 cm bilaterally)^[9] but higher than that of Korean (right = 0.36 cm; left = 0.38 cm)^[23] and Pakistani (right = 0.399 cm; left = 0.386 cm)^[11] studies. These findings suggest that lacrimal gland axial and coronal diameters may be different among various ethnicities and geographical locations around the world.

Limitations

The limitations of this study include the following: first, prior clinical examination of the eyes (refractive errors causing posterior staphyloma can affect ocular dimensions) was impossible in a retrospective study. Secondly, the lacrimal gland has a density similar to the surrounding orbital structures which sometimes made it challenging to measure it on CT—such images were excluded. Thirdly, a 16-slice CT scanner was used for this study; a much higher slice spiral scanner might perhaps provide more detail for better assessment.

Conclusion

This study generated normative data that can be a reference for ophthalmologists, craniofacial surgeons, and other physicians. There was no significant correlation between globe volume and lacrimal gland volume. Male globes were larger than female globes. While age correlated inversely with globe volume, there was no correlation between age and lacrimal gland volume.

Acknowledgement

None.

Financial support and sponsorship

Nil.

Conflicts of interest

There are no conflicts of interest.

Authors' contribution

BMI: Conception, design, literature search, data acquisition, data analysis, statistical analysis, manuscript preparation, manuscript editing, manuscript review, approval of final draft, guarantor.

SOO: Statistical analysis, manuscript review, approval of final draft, guarantor.

ALC: Manuscript editing, manuscript review, approval of final draft.

JBH: Manuscript editing, manuscript review, approval of final draft.

OOA: Manuscript editing, manuscript review, approval of final draft.

JAA: Design, literature search, manuscript preparation, manuscript editing, manuscript review, approval of final draft.

References

1. Danjem S, Salaam A. Computed tomographic dimensions of the lacrimal gland in normal Nigerian orbits. *Int J Sci Res Publ* 2016;6:151-5.
2. Lorber M. Gross characteristics of normal human lacrimal glands. *Ocul Surf* 2007;5:13-22.
3. Khademi Z, Bayat P. Computed tomographic measurements of orbital entrance dimensions in relation to age and gender in a sample of healthy Iranian population. *J Curr Ophthalmol* 2016;28:81-4.
4. Huh HD, Kim JH, Kim SJ, Yoo JM, Seo SW. The change of lacrimal gland volume in Korean patients with thyroid-associated ophthalmopathy. *Korean J Ophthalmol* 2016;30:319-25.
5. Min SG, Ha MS. Calculated CT volumes of lacrimal glands in normal Korean orbits. *J Korean Ophthalmol Soc* 2015;56:1-5.
6. Gao Y, Moonis G, Cunnane ME, Eisenberg RL. Lacrimal gland masses. *Am J Roentgenol* 2013;201:W371-81.
7. Bulbul E. Evaluation of lacrimal gland dimensions and volume in Turkish population with computed tomography. *J Clin Diagn Res* 2016;10:TC06-8.
8. Lorber M, Vidić B. Measurements of lacrimal glands from cadavers, with descriptions of typical glands and three gross variants. *Orbit* 2009;28:137-46.
9. Bingham CM, Castro A, Realini T, Nguyen J, Hogg JP, Sivak-Callcott JA. Calculated CT volumes of lacrimal glands in normal Caucasian orbits. *Ophthalmic Plast Reconstr Surg* 2013;29:157-9.
10. Tamboli DA, Harris MA, Hogg JP, Realini T, Sivak-Callcott JA. Computed tomography dimensions of the lacrimal gland in normal Caucasian orbits. *Ophthalmic Plast Reconstr Surg* 2011;27:453-6.
11. Nawaz S, Lal S, Butt R, Ali M, Shahani B, Dadlani A. Computed tomography evaluation of normal lacrimal gland dimensions in the adult Pakistani population. *Cureus* 2020;12:e7393.
12. Güngör G, Urfalioğlu S. Assessment of lacrimal gland volume with computed tomography in a Turkish population. *BSJ Health Sci* 2019;2:5-8.
13. Annongu IT, Mohammad H, Chia M, Chaha K, Magaji GO. Baseline eyeball biometrics on computed tomography in Makurdi, North Central Nigeria. *J BioMed Res Clin Pract* 2018;1:17-21.
14. Igbinedion BO, Ogbeye OU. Measurement of normal ocular volume by the use of computed tomography. *Niger J Clin Pract* 2013;16:315-9.
15. Salaam A, Aboje O, Danjem S, Tawe G, Salaam A. Ocular biometry using computed tomography in Jos, North Central Nigeria. *Ophthalmol Res* 2016;5:1-6.
16. Ibinaiye PO, Maduforo CO, Chinda D. Estimation of the eyeball volume on magnetic resonance images in Zaria, Nigeria. *Sub-Saharan Afr J Med* 2014;1:82-85.
17. Osborne DR, Foulks GN. Computed tomographic analysis of deformity and dimensional changes in the eyeball. *Radiology* 1984;153:669-74.
18. Nieves JW, Formica C, Ruffing J, Zion M, Garrett P, Lindsay R, *et al.* Males have larger skeletal size and bone mass than females, despite comparable body size. *J Bone Miner Res* 2005;20:529-35.
19. Gray J, Wolfe L. A cross-cultural investigation into the sexual dimorphism of stature. In: Hall R, editor. *Sexual Dimorphism in Homo Sapiens: A Question of Size*. New York: Praeger Scient; 1982. p. 197-230.
20. Hahn FJ, Chu WK. Ocular volume measured by CT scans. *Neuroradiology* 1984;26:419-20.
21. Phillip JM, Aifuwa I, Walston J, Wirtz D. The mechanobiology of aging. *Annu Rev Biomed Eng* 2015;17:113-41.
22. Zhou H, Dai Y, Shi Y, Russell JF, Lyu C, Noorikolouri J, *et al.* Age-related changes in choroidal thickness and the volume of vessels and stroma using swept-source OCT and fully automated algorithms. *Ophthalmol Retina* 2020;4:204-15.
23. Lee JS, Lee H, Kim JW, Chang M, Park M, Baek S. Computed tomographic dimensions of the lacrimal gland in healthy orbits. *J Craniofac Surg* 2013;24:712-5.
24. Obata H, Yamamoto S, Horiuchi H, Machinami R. Histopathologic study of human lacrimal gland. Statistical analysis with special reference to aging. *Ophthalmology* 1995;102:678-86.
25. Tenzel PA, Moffa D, Decilveo AP, Reddy HS. Normal lacrimal gland volumes by magnetic resonance imaging and the relationship of lacrimal gland volume to orbital size. *J Craniofac Surg* 2019;30:e741-3.