

Rare case of gemination of mandibular third molar—A case report

Sandeep S¹, Jeevan Kumar G², Suraj Potdar³, Rishabh Bhanot⁴,
Amit S. Vathare⁵, Rahul V. C. Tiwari⁶, Harshitha B⁷

¹Department of Oral and Maxillofacial Surgery, C.K.S. Theja Institute of Dental Sciences and Research, Tirupati, Andhra Pradesh, ²Consultant Oral and Maxillofacial Surgeon, Tirupati, Andhra Pradesh, ³Department of Orthodontics and Dentofacial Orthopedics, Vasantdada Patil Dental College and Hospital, Kavalapur, Maharashtra, ⁴Consultant Oral and Maxillofacial Surgeon, Jyoti Kendra General Hospital, Ludhiana, Punjab, ⁵Prosthodontist and Implantologist, Jaysingpur, Shirol, Kolhapur, Maharashtra, ⁶Consultant Oral and Maxillofacial Surgeon, CLOVE Dental and OMNI Hospitals, Visakhapatnam, Andhra Pradesh, ⁷Department of Periodontics, Sri Sai college of dental surgery, Vikarabad, Telangana, India

ABSTRACT

Fusion and germination are the anomalies that occur due to some developmental eccentricity during the time of morpho-differentiation of the tooth bud and have a close resemblance to each other. The gemination is an attempt of the division of a single tooth into two and, hence, appears as an enlarged single tooth while the tooth count is normal when the affected tooth is counted as one. Its exact pathogenesis is ambiguous. This anomaly has been observed mostly in deciduous dentition as compared to that in permanent dentition. Gemination is rarely associated with the third molar and, hence, the terminology is arguable when this condition is seen in relation to the third molar. In the present article, a case of germination of mandibular third molar has been reported.

Keywords: Double teeth, fusion, gemination

Introduction

Germination and fusion are rare but important as these anomalies are potentially influencing any other teeth.^[1] Fusion is defined as a union of two separate tooth buds during the tooth development stage and the amount of fusion of dentin, pulp canal, and pulp chambers are in confluence with the stage at which union occurs.^[2] As a result of fusion, the counting will be one tooth less than the normal count. On contrary, the germination is an attempt of a single tooth germ to divide and hence it results in the appearance of a large single tooth

usually with bifid crown and a common root and the root canal.^[2,3] This results in a tooth with a bifid crown, while the total number of teeth is normal.^[4] In the present article, a case of germination in mandibular third molar has been reported; it is a rare entity by itself, showing the atypical coronal and radicular morphology.

Case Report

A 30-year-old female reported with a complaint of pain in her right lower back tooth region since 1 month. There was no contributory medical and dental history. The intraoral examination revealed partial eruption of the mesial cusp of the crown of 48 with swelling and redness of the pericoronal flap. The provisional diagnosis of pericoronitis with impacted 48 was made and differential diagnosis of periodontitis and odontogenic cyst was made. On radiographic examination, orthopantomography (OPG) revealed the presence of

Address for correspondence: Dr. Sandeep S,
Department of Oral and Maxillofacial Surgery, C.K.S.
Theja Institute of Dental Sciences and Research, Tirupati,
Andhra Pradesh, India.
E-mail: sansim9999@gmail.com

Received: 19-01-2020

Revised: 12-03-2020

Accepted: 15-03-2020

Published: 31-05-2020

Access this article online

Quick Response Code:



Website:
www.jfmipc.com

DOI:
10.4103/jfmipc.jfmipc_117_20

This is an open access journal, and articles are distributed under the terms of the Creative Commons Attribution-NonCommercial-ShareAlike 4.0 License, which allows others to remix, tweak, and build upon the work non-commercially, as long as appropriate credit is given and the new creations are licensed under the identical terms.

For reprints contact: WKHLRPMedknow_reprints@wolterskluwer.com

How to cite this article: Sandeep S, Kumar GJ, Potdar S, Bhanot R, Vathare AS, Tiwari RV, *et al.* Rare case of gemination of mandibular third molar—A case report. J Family Med Prim Care 2020;9:2577-9.

a partially erupted atypical tooth in the third molar region [Figure 1]. The morphology of the tooth appeared like two crown structures were fused with single bulbous radicular portion. The pulp chamber was large and shared by both the crowns and, thereby, appeared to be continuous in both the crowns while two root canals were visible in the radicular portion extending mesially and distally from the large pulp chamber. A radiographic diagnosis of gemination was made and radiographic differential diagnosis of fusion with supernumerary tooth was made. The patient was subjected to surgical extraction of 48 under local anesthesia [Figure 2]. The extracted tooth was examined in detail in order to differentiate it from fusion [Figure 3]. The examination of the extracted tooth revealed the continuation

of the tooth except they appeared separated by a marked groove on the buccal and lingual surface of the tooth appeared [Figures 4]. The tooth was having a single root and thereby looked like an incomplete division of the tooth. The extracted tooth was sectioned and it was confirmed which again confirmed gemination [Figure 5]. Follow up OPG revealed healing socket [Figure 6].

Discussion

Gemination and fusion are the developmental anomalies with unusual anatomy. Gemination of the tooth is the developmental

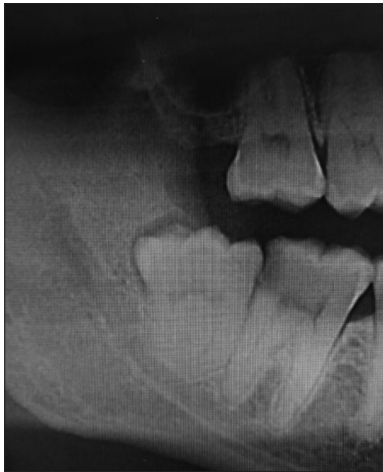

Figure 1: Orthopantomography (OPG) (cropped) showing partially erupted anomalous mandibular right 3rd molar

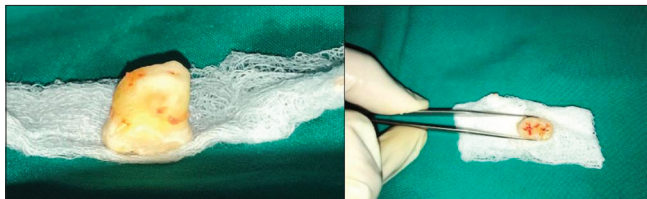


Figure 3: Showing morphology of the extracted 48

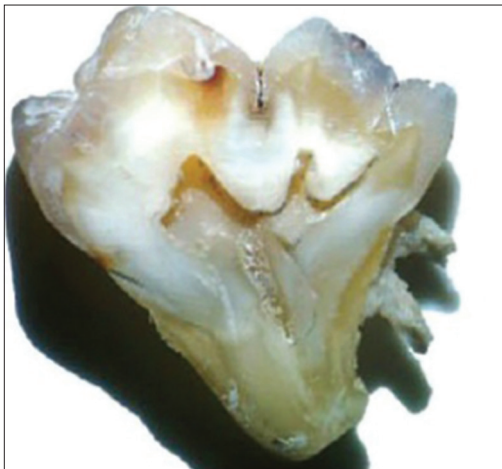

Figure 5: Showing sectioned extracted tooth

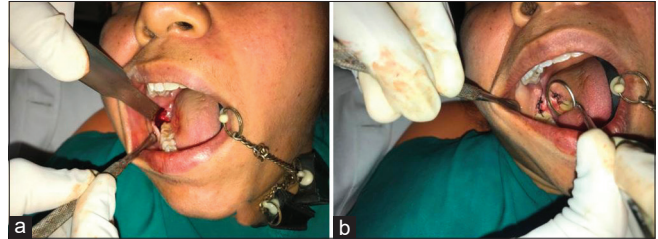


Figure 2: Showing intraoperative (a) and postoperative (b) picture

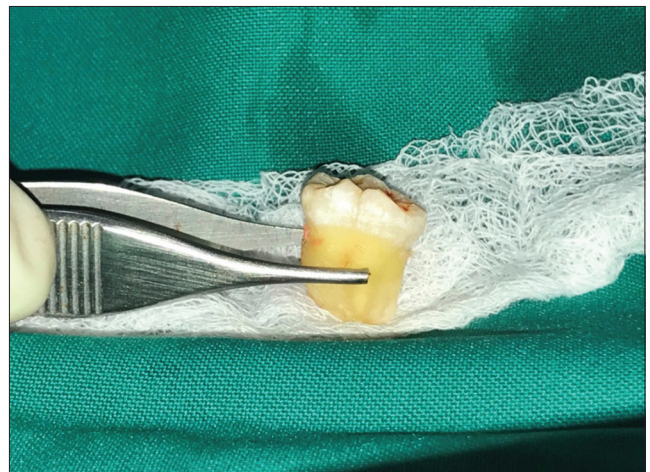


Figure 4: Morphology of the extracted 48 showing marked groove on the buccal surface

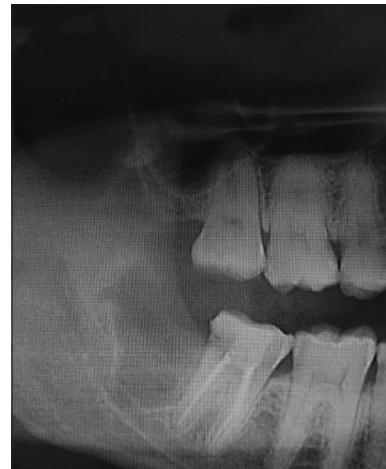

Figure 6: OPG (cropped) showing healing of the extraction socket

anomaly occurring in the morpho-differentiation stage of tooth development and it arise as a result of the failed attempt by the single tooth bud to divide and hence thereby appear as a double tooth or bifid crown resulting in a bifid crown.^[1,5] It is very difficult, if not impossible to differentiate between germination and fusion clinically, especially if supernumerary tooth is involved.^[6] Higher prevalence of such anomalies has been seen in the deciduous dentition although it occurs in both primary and permanent dentition with anterior region being the most common site.^[7] It is generally found with a higher incidence in the lower jaw and with equal sex predilection. The prevalence rate of unilateral gemination in primary and permanent dentition is 0.5% and 0.1%, respectively. The prevalence rate of bilateral cases in primary and permanent dentition is 0.01% to 0.04% and 0.02% to 0.05%, respectively. However, in our reported case, the anomaly is unilaterally present in the mandibular arch which is relatively rare.^[8] In 1970, Brook and Winter proposed that these anomalies can be referred to by an unbiased term like “double teeth.” Moreover, in 1979, Mader (1979) highlighted the similarity of the clinical appearance of geminated and fused teeth and recommended the term “fused teeth” in order to refer to the teeth joined together by dentin. It is usually very difficult to differentiate between germination and fusion clinically. Thereby, several clinical and radiographic criteria have been used in order to differentiate between these entities. Fusion is an incomplete union of two tooth buds, while gemination is the incomplete or failed attempt of one tooth bud to divide into two. Without the involvement of the supernumerary tooth and presence of full complement of teeth indicate the phenomenon of germination while one toothless in the full complement of teeth indicates fusion. Radiographically, in case of fused teeth, there will be evidence of two distinct pulp chambers while in case of germination, there is only one pulp chamber.^[9] In the present case report, it was difficult to diagnose the case clinically as fusion with supernumerary teeth or geminated teeth. In the present case scenario, there was no reduction in the full complement of teeth; moreover, because of the presence of a large pulp chamber, we arrived at the diagnosis of gemination of 48. The gemination in posterior permanent dentition is usually an uncommon condition. It is an extremely rare situation and thereby it is an important to primarily diagnose this dental anomaly that could affect any other tooth in the mouth. The present case report suggests that more delayed the treatment can be associated with more severe position of the impacted teeth. Since, the severity of tooth impaction could follow different patterns while taking into consideration various investigated factors, thereby it is mandatory to include such factors while diagnosing the dental impaction in primary settings and henceforth planning the preliminary or preventive and interceptive interventions for the patients. Such case compulsory needs primary care and intervention. Moreover, the identification of this anomalous condition and its radiographic evaluation is definitely required

for any primary treatment involving these variations of teeth for their successful outcome.

Conclusion

Gemination and fusion of teeth are rare but at the same time clinically important because of their potential side effects and implications on the other teeth. The post-surgical complications of such cases can be prevented and clinical management can be facilitated by carefully making pertinent and appropriate diagnosis.

Declaration of patient consent

The authors certify that they have obtained all appropriate patient consent forms. In the form the patient(s) has/have given his/her/their consent for his/her/their images and other clinical information to be reported in the journal. The patients understand that their names and initials will not be published and due efforts will be made to conceal their identity, but anonymity cannot be guaranteed.

Financial support and sponsorship

Nil.

Conflicts of interest

There are no conflicts of interest.

References

1. Rajendran R, Sivapathasundaram B. Shafer's Textbook of Oral Pathology. 7th ed. New Delhi: Elsevier; 2012.
2. Nelson SJ, Ash MM Jr. Wheeler's Dental Anatomy, Physiology and Occlusion. 9th ed. St. Louis: Saunders; 2012.
3. Krishnamurthy M, Kumar VN, Leburu A, Jeddy N. Fusion of maxillary central incisors with mesiodens. J Oral Maxillofac Pathol 2018;22:131-4.
4. Goutham B, Bhuyan L, Chinnannavar SN, Kundu M, Jha K, Behura SS. Prevalence of dental anomalies in Odisha population: A panoramic radiographic study. J Contemp Dent Pract 2017;18:549-53.
5. Bilge NH, Yeşiltepe S, Törenek Ağırman K, Çağlayan F, Bilge OM. Investigation of prevalence of dental anomalies by using digital panoramic radiographs. Folia Morphol (Warsz) 2018;77:323-8.
6. Dang HQ, Constantine S, Anderson PJ. The prevalence of dental anomalies in an Australian population. Aust Dent J 2017;62:161-4.
7. Fekonja A. Prevalence of dental developmental anomalies of permanent teeth in children and their influence on esthetics. J Esthet Restor Dent 2017;29:276-83.
8. Gurbuz O, Ersen A, Dikmen B, Gumustas B, Gundogar M. The prevalence and distribution of the dental anomalies in the Turkish population. J Anat Soc India 2019;68:46-51.
9. Venkatesh A, Mitthra S, Prakash V, Prasad TS. Gemination or Fusion? - A case report. Biomed Pharmacol J 2016;9: 1225-8.