

Research Article



Benefits of mineralized bone cortical allograft for immediate implant placement in extraction sites: an *in vivo* study in dogs

Valérie Orti,^{1,2,*} Philippe Bousquet,^{1,2} Paul Tramini,² Cesar Gaitan,³
Brenda Mertens,¹ Frédéric Cuisinier^{1,2}

¹Department of Periodontology, Montpellier University Hospital, Montpellier, France

²Laboratory of Bioengineering and Nanoscience, University of Montpellier, Montpellier, France

³Department of Stomatology, Centro Ciencias de la Salud, Universidad Autónoma, Aguascalientes, Mexico



Received: Mar 9, 2016

Accepted: Jul 13, 2016

*Correspondence to

Valérie Orti

Laboratory of Bioengineering and Nanoscience, EA4203, University of Montpellier, 545 Avenue du Professeur Jean-Louis Viala, Montpellier Cedex 34193, France.
E-mail: orti.valerie.30@gmail.com
Tel: +33-6-0976-6015
Fax: +33-4-1175-9201

Copyright © 2016 Korean Academy of Periodontology

This is an Open Access article distributed under the terms of the Creative Commons Attribution Non-Commercial License (<http://creativecommons.org/licenses/by-nc/3.0/>).

ORCID

Valérie Orti
<http://orcid.org/0000-0002-7901-9227>
Philippe Bousquet
<http://orcid.org/0000-0002-4444-2703>
Paul Tramini
<http://orcid.org/0000-0002-8227-9150>
Cesar Gaitan
<http://orcid.org/0000-0001-6452-2578>
Brenda Mertens
<http://orcid.org/0000-0002-3649-4351>
Frédéric Cuisinier
<http://orcid.org/0000-0001-6870-0490>

Conflict of Interest

No potential conflict of interest relevant to this article was reported.

ABSTRACT

Purpose: The aim of the present study was to evaluate the effectiveness of using a mineralized bone cortical allograft (MBCA), with or without a resorbable collagenous membrane derived from bovine pericardium, on alveolar bone remodeling after immediate implant placement in a dog model.

Methods: Six mongrel dogs were included. The test and control sites were randomly selected. Four biradicular premolars were extracted from the mandible. In control sites, implants without an allograft or membrane were placed immediately in the fresh extraction sockets. In the test sites, an MBCA was placed to fill the gap between the bone socket wall and implant, with or without a resorbable collagenous membrane. Specimens were collected after 1 and 3 months. The amount of residual particles and new bone quality were evaluated by histomorphometry.

Results: Few residual graft particles were observed to be closely embedded in the new bone without any contact with the implant surface. The allograft combined with a resorbable collagen membrane limited the resorption of the buccal wall in height and width. The histological quality of the new bone was equivalent to that of the original bone. The MBCA improved the quality of new bone formation, with few residual particles observed at 3 months.

Conclusions: The preliminary results of this animal study indicate a real benefit in obtaining new bone as well as in enhancing osseointegration due to the high resorbability of cortical allograft particles, in comparison to the results of xenografts or other biomaterials (mineralized or demineralized cancellous allografts) that have been presented in the literature. Furthermore, the use of an MBCA combined with a collagen membrane in extraction and immediate implant placement limited the extent of post-extraction resorption.

Keywords: Allografts; Alveolar bone loss; Bone regeneration; Dental implants; Tooth extraction

INTRODUCTION

Studies have described the placement of implants immediately after tooth extraction. The advantages of this technique include a higher implant survival rate, better aesthetic results, the preservation of alveolar hard and soft tissue volume, and better patient satisfaction due to a shortened treatment period [1-5].

Several studies have demonstrated that this protocol cannot reliably preserve the alveolar bone or avoid resorption [6-9]. The height of the buccal alveolar bone wall was found to have significantly decreased (2.6 mm loss) 12 weeks after tooth extraction. The residual heights of the buccal and lingual alveolar bone were found to be similar 3 months after simple extraction to those observed after extraction followed by immediate implant placement. The authors of that study observed more bone loss at the buccal wall in both cases [8].

A range of biomaterials, primarily bone xenografts and allografts, have been found to improve osseous volume [10]. In a 30-patient clinical study, the use of biomaterials reduced horizontal loss, but not vertical loss, of the buccal wall [11]. Other studies have demonstrated that vertical bone loss was limited using an allograft covered with a resorbable collagen membrane [10,12-18]. Clearly, biomaterials delay osseointegration during the time of reossification during new bone-implant contact. The low resorbability of the graft can be clinically considered as an advantage, as it leads to primary stability and limited socket resorption. Allografts that are only osteoconductive have shown comparable results to those of autogenous bone and better results than xenografts, which are mainly used in operations to fill sockets. They have the benefit of avoiding intraoral or extraoral bone harvesting. The reduction of the number of residual cortical particles resulting from the higher rate of resorption of cortical particles compared to xenografts (or bone cancellous allografts) allows the regenerated bone structure to be closer to that of the original bone. Pure cortical allograft particles provide the density and strength of an autograft of cortical bone without the cost or invasiveness of that method. Therefore, the renewed interest of clinicians in allografts, with or without a collagenous membrane, justifies new in-depth studies of this material [13,15,18]. Our study focused on cortical bone chips, which have not been previously studied. The aim of this study was to investigate the benefit of using a mineralized bone cortical allograft, with or without a resorbable membrane, on alveolar bone remodeling after immediate implant placement in a dog model.

MATERIALS AND METHODS

This research protocol was approved by the ethical committee for animal studies of Universidad Autónoma de San Luis Potosí, Mexico. The study was conducted according to the National or Institutional Guidelines for the Care and Use of Laboratory Animals. Six mongrel dogs, approximately 18 months old and weighing approximately 20 kg, were included in this study. During surgical procedures, the dogs were anesthetized with 1 mL/10 kg of intravenously administered tiletamine chlorhydrate and zolazepam chlorhydrate (50/50) (Zoletil 50[®], Virbac, Carros, France). Mucoperiosteal full-thickness flaps were elevated to visualize the buccal and lingual hard bone ridge. The teeth were hemisected with the use of a fissure bur and were carefully removed using forceps. Four biradicular premolars (right and left P3 and P4) were extracted from the mandible of each dog, for a total of 48 socket sites (Table 1). Mineralized bone cortical allograft particles treated with Tutoplast[®]

Table 1. Distribution of operations (48 sites, 144 measures)

Groups	Implant alone (control sites)		Implant+MBCA		Implant+MBCA+collagenous membrane	
	S50%	S100%	S50%	S100%	S50%	S100%
1 month	1 site (3 measures)	1 site (3 measures)	1 site (3 measures)	1 site (3 measures)	2 sites (6 measures)	2 sites (6 measures)
3 months	3 sites (9 measures)	7 sites (21 measures)	3 sites (9 measures)	7 sites (21 measures)	6 sites (18 measures)	14 sites (42 measures)

S50%, socket with buccal wall height reduced by 50%; S100%, intact socket; MBCA, mineralized bone cortical allograft.

(Puros[®] cortical, Zimmerdental, Carlsbad, CA, USA) were used for grafting, and collagenous membranes derived from bovine pericardium (Copios[®], Zimmerdental) were placed as a barrier to isolate the socket. The control sites were the sockets containing only an implant. The buccal-lingual dimension of the sockets was measured using a sliding caliper after extraction. The following 3 surgical protocols were tested: allograft alone (12 sites), allograft with membrane (24 sites), and control site with implant alone (12 sites). Two types of sockets were evaluated, including intact sockets (S100%; 32 sites; Figure 1A) and sockets with their buccal wall height reduced by 50% (S50%; 16 sites). For the S50% group, the buccal bone wall was reduced with a bur (Figure 1B) and the distance between the buccal alveolar wall and the top of the implant was measured after implantation with a sliding caliper to quantify osseous resorption at the test and control sites, which were randomly selected. Eight implants were placed in each dog in each freshly extracted socket with a marginal level of buccal bone crest. Sockets were prepared for implant installation according to the guidelines provided by the manufacturer. The implants were tapered screw-vent models (Zimmerdental), measuring 3.7 mm wide and 10 mm or 11.5 mm long. Mineralized bone cortical allograft particles were placed to fill the gap around the implant, with or without a collagen resorbable membrane, in order to establish which surgical protocol led to the best results in terms of osseous preservation.

The buccal and lingual flaps were managed and secured to allow for submerged healing in the experimental sites. The dogs received 51 mg/10 kg of amoxicillin twice daily (Penamox[®], Invekra, Mexico City, Mexico) over 8 days. Dogs were euthanized by an overdose of pentobarbital 1 month after the procedure for 1 dog and 3 months after the procedure for the remaining 5 dogs.

Radiographic analysis

A cone-beam scan (VGi, NewTom, Verona, Italy) was performed for each sample in order to visualize bone resorption and osseointegration and to determine both the direction and position of the implant edges before embedding.

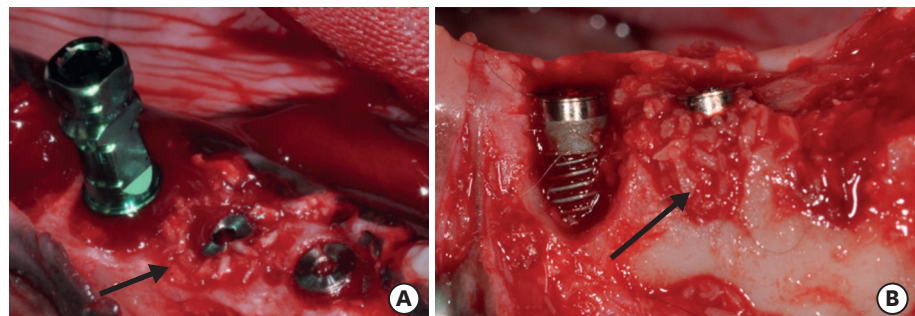


Figure 1. The 2 types of sockets. (A) Intact sockets (S100%) with 3 implants. The middle implant was placed with cortical Puros[®] chips (black arrow) in the socket. (B) Sockets with the buccal wall height reduced to 50% (S50%). The implant on the right was cover with mineralized bone cortical allograft (black arrow).

Histomorphometric analysis

The specimens were immediately fixed in 2% glutaraldehyde and 2% formaldehyde in a 0.1M solution of sodium cacodylate buffer at pH 7.4 before dehydration in a graded series of alcohols. The specimens were then embedded in epoxy resin. Undecalcified sections were prepared using an automated ISOMET 2000 (Buehler, Düsseldorf, Germany) precision saw. After polishing, the sections were mounted on glass microscope slides and stained with Goldner trichrome. A Leitz DM-RBE Microscope (Leica, Wetzlar, Germany), associated with a camera D90 (Nikon, Tokyo, Japan), was used for analysis. For each site, 3 histologic sections per site were used for measurements (Table 1).

Histomorphometric measurements

Histomorphometric measurements were completed using Image J (National Institutes of Health, Bethesda, MD, USA). To evaluate osseointegration, bone-implant contact (BIC) was measured on histologic sections (enlargement of $\times 25$). The total length of bone in contact with the implant was measured, and the percentage of the threaded portion of the implant in contact with the bone was calculated. The bone height was calculated by measuring the distance between the buccal or alveolar wall crest and the marginal level of the implant using Image J software on histology sections compared with the measures obtained before the operations.

Statistical analysis

The Shapiro-Wilk normality test showed that the outcome variables (bone height and BIC) were normally distributed. The influence of various surgical parameters on BIC and bone height was analyzed using 4-way analysis of variance with the option of partial sum of squares used for unbalanced data (time, 1 month or 3 months; type of socket, 50% or 100%; allograft, yes or no; and membrane, yes or no). Pairwise comparisons between groups were made using the *t*-test with Bonferroni correction. Statistical analyses were performed with Stata version 14.1 (Stata Corp., College Station, TX, USA), and the level of statistical significance was set at 0.05.

RESULTS

Histomorphometric analysis

At 3 months, we observed full osseointegration, which would not interfere with grafting and guided bone regeneration operations (Figure 2). The mineralized bone cortical allograft particles were completely embedded in the newly formed bone, which covered almost the entire implant surface (Figure 2). The visualization of residual particles was more difficult at that time. Indeed, the majority of these particles disappeared into the newly formed bone. The particles were sparse and difficult to observe on 25% of the histology sections for all surgical protocols. The observed particles were surrounded with newly formed bone, confirming their capacity for osseointegration. The internal structure of the particles showed the presence of empty osteocyte lacunae (Figure 3).

The use of allograft particles significantly reduced buccal wall bone resorption (1.80 ± 2.46 vs. 3.80 ± 1.51 mm) as well as lingual cortical resorption (1.20 ± 1.04 vs. 2.30 ± 0.39 mm). This reduction in bone resorption was higher for the buccal wall than for the lingual wall (Table 2). Finally, the use of a membrane with an allograft significantly reduced buccal wall bone resorption (1.20 ± 2.57 vs. 2.90 ± 2.28 mm). The limited resorption was further reduced to a significant extent when allograft particles were combined with a collagen membrane in comparison to when they were used alone (1.20 ± 2.57 vs. 2.90 ± 2.28 mm for the buccal wall and 1.00 ± 0.78 vs. 1.80 ± 1.07 mm for the lingual wall) (Table 3).

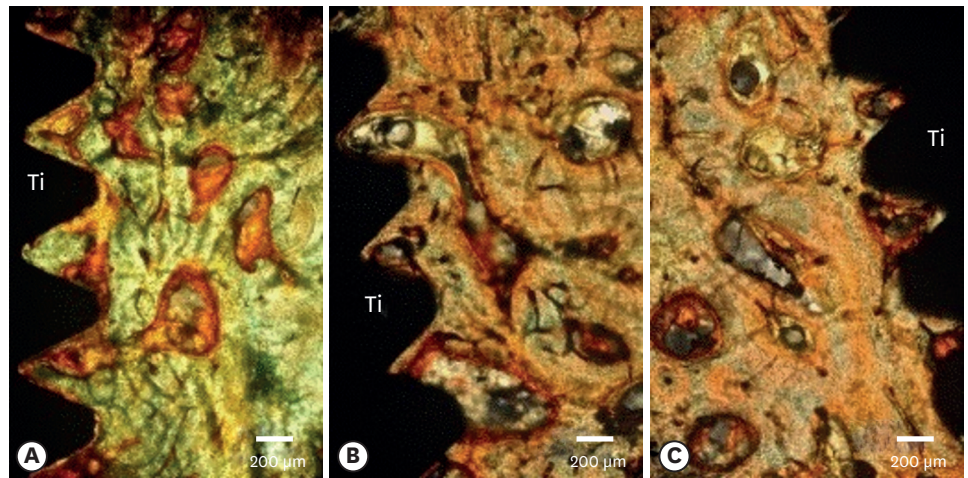


Figure 2. The interface between bone and the implant surface. (A) An implant alone placed into the fresh extraction socket (Goldner trichrome stain). (B) An implant with mineralized bone cortical allograft (Goldner trichrome stain). (C) An implant with a mineralized bone cortical allograft combined with a collagen membrane (Goldner trichrome stain).




Figure 3. Interface bone-implant surface with mineralized bone cortical allograft particles without a membrane 3 months after implantation. (A) Mineralized bone cortical allograft (A) and new bone (NB) (Goldner trichrome stain). (B) The black arrow indicates a layer of newly formed bone (B) between the dental implant (Ti) and mineralized bone cortical allograft particles (Goldner trichrome stain).

Table 2. Marginal buccal and lingual bone loss with or without allograft particles (cortical Puros®) at 3 months

Parameter	Bone loss (mm) without MBCA (n=30)	Bone loss (mm) with MBCA (n=30)	P value
BW	3.80±1.51	1.80±2.46	0.002 ^{a)}
LW	2.30±0.39	1.20±1.04	0.020 ^{a)}

Values are presented as mean±standard deviation.

MBCA, mineralized bone cortical allograft; n, number of samples; BW, buccal wall; LW, lingual wall.

^{a)}Statistically significant difference compared to baseline.

Table 3. Marginal buccal and lingual bone resorption with mineralized bone cortical allograft particles with or without a collagenous resorbable membrane (Copios®) at 3 months

Parameter	Bone loss (mm) without membrane (n=40)	Bone loss (mm) with membrane (n=40)	P value
BW	2.90±2.28	1.20±2.57	0.030 ^{a)}
LW	1.80±1.07	1.00±0.78	0.010 ^{a)}

Values are presented as mean±standard deviation.

BW, buccal wall; LW, lingual wall; n, number of samples.

^{a)}Statistically significant difference compared to baseline.

Table 4. Comparison of buccal and lingual bone resorption measured in histological sections for the S50% and S100% sockets after 1 and 3 months in the control sites

Parameter	Bone loss (mm) at month 1			Bone loss (mm) at month 3		
	S50% (n=3)	S100% (n=3)	P value	S50% (n=9)	S100% (n=21)	P value
BW	0.20±0.30	2.10±0.03	0.120	1.60±0.02	4.40±1.06	0.030 ^{a)}
LW	1.20±0.20	0.40±0.01	0.900	2.10±0.14	2.90±0.73	0.030 ^{a)}

Values are presented as mean±standard deviation.

BW, buccal wall; LW, lingual wall; n, number of sites; S50%, socket with buccal wall height reduced by 50%; S100%, intact socket.

^{a)}Statistically significant difference compared to baseline.

Table 5. Comparison of BIC at 1 and 3 months after surgery

Parameter	BIC at month 1 (%)				BIC at month 3 (%)			
	S50%	S100%	P value	n	S50%	S100%	P value	n
Implant	40.16	48.20	0.020 ^{a)}	6	30.62	50.02	0.01 ^{a)}	20
Implant+MBCA	36.76	55.97	0.040 ^{a)}	6	66.29	60.49	0.53	20
Implant+MBCA+membrane	45.10	56.91	0.862	12	64.27	66.28	0.85	20

Values are presented as percentages.

BIC, bone-implant contact; n, number of samples; S50%, socket with buccal wall height reduced by 50%; S100%, intact socket; MBCA, mineralized bone cortical allograft.

^{a)}Statistically significant difference compared to baseline.

At 1 month, we observed that the buccal and lingual crests were located at 2.10±0.03 mm on the buccal side and 0.40±0.01 mm on the lingual side, apical to the marginal level of the implant, in the S100% sockets. The bone resorption was higher for the buccal and lingual walls at 3 months than at 1 month. This resorption was significantly lower for the buccal wall in the S50% group than in the S100% group, and buccal wall resorption was significantly more extensive (Table 4).

Osseointegration was incomplete at 1 month for all protocols.

At 1 and 3 months, mineralized bone cortical allograft with or without a collagen membrane did not disturb osseointegration in comparison with the control site (Table 5, Figure 2). The mineralized bone cortical allograft was observed 1 month (Figure 4) and 3 months after implantation (Figures 3 and 5). At 1 month, while osseointegration was incomplete, the allograft particles were surrounded by a thin layer of newly formed bone and were therefore never directly in contact with the implant surface. Active resorption areas of allograft particles were visible (Figure 4).

Indeed, the Tutoplast[®] processing performed on this material, with the aim of eliminating the risk of contamination through various treatments, allows protection of the collagenic mineral weft and the architecture of the donor. Observation with strong magnification (×400) allows visualization of these residual particles and shows the presence of empty gaps of osteocytes. Furthermore, the Goldner trichrome staining of these particles is different from that of the newly formed bone, due to the chemical modification of the organic matrix during Tutoplast[®] processing.

X-ray tomography

X-ray tomography scans showed that buccal wall resorption was observed for all surgical protocols and that less resorption was observed in the lingual walls (Figures 6, 7, 8, and 9). Osseointegration was incomplete at 1 month for all protocols (Figure 6). At 3 months, mineralized bone cortical allografts alone or combined with a membrane limited the resorption of the buccal wall and preserved the bone volume. In these situations, the resorption of the buccal wall was limited in height, but losses in bone volume were still observed (Figures 7 and 8). Full osseointegration was observed, which would not interfere with grafting and guided bone regeneration operations (Figures 6, 7, 8, and 9).

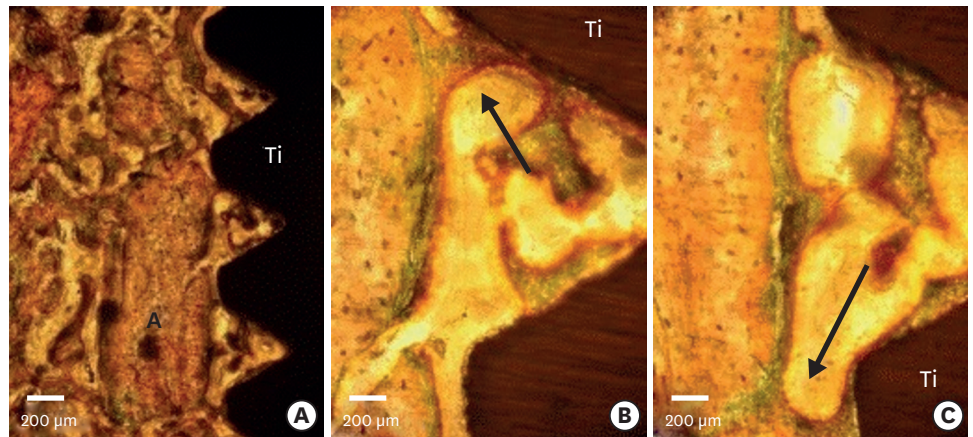


Figure 4. Histological view of a titanium implant 1 month after of implantation. The space between the implant and the alveolar socket was filled with mineralized bone cortical allograft and a membrane was placed in the buccal side. (A) Mineralized bone cortical allograft particles (Goldner trichrome stain). (B, C) Enlarged views of mineralized bone cortical allograft particles. The green layer surrounding the mineralized bone cortical allograft corresponds to newly formed bone. In both cases, contact between newly formed bone and the implant surface was established (black arrows). The newly formed bone layer is continuous around the mineralized bone cortical allograft particles in contrast to the titanium (Goldner trichrome stain).

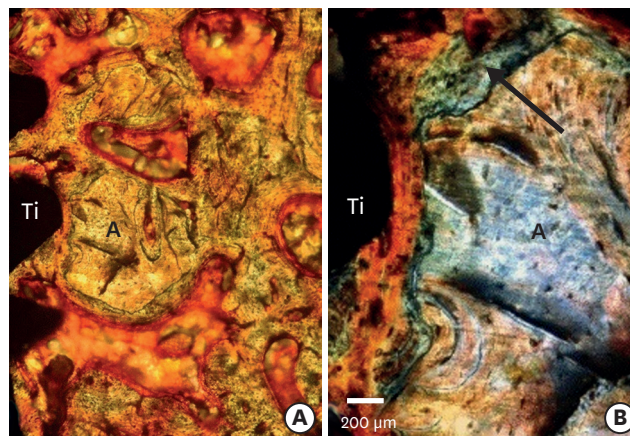


Figure 5. Bone-implant interface with mineralized bone cortical allograft particles and a membrane 3 months after implantation. (A) General view with mineralized bone cortical allograft particles (Goldner trichrome stain). (B) The black arrow indicates a layer of newly formed bone between the dental implant (Ti) and particles of mineralized bone cortical allograft (A) (Goldner trichrome stain).

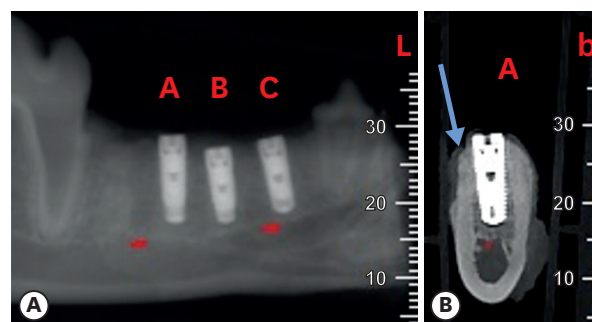


Figure 6. X-ray tomography at 1 month (S100%, intact socket). (A) Mesio-distal view of 3 implants. (B) Linguo-vestibular view of an implant with mineralized bone cortical allograft particles and a membrane. The blue arrow indicates the buccal wall with limited height and widthwise bone resorption.

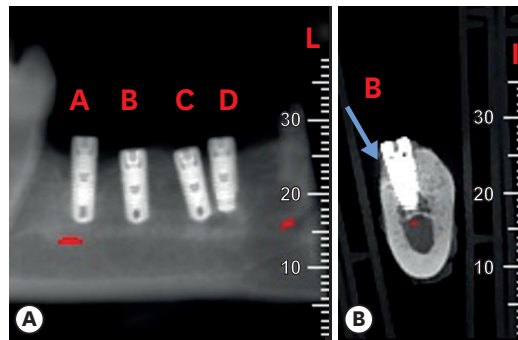


Figure 7. X-ray tomography at 3 months (S100%, intact socket). (A) Mesio-distal view of 4 implants. (B) Linguo-vestibular view of implant B with mineralized bone cortical allograft particles and a membrane. The blue arrow indicates the buccal wall with limited resorption.

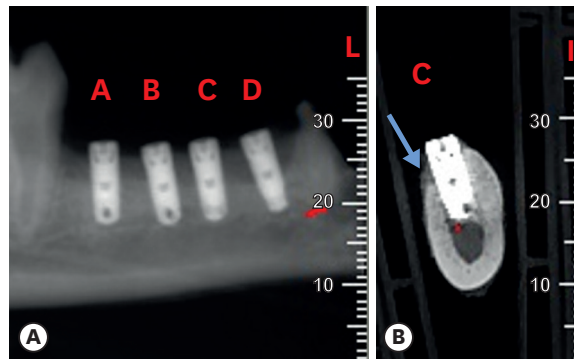


Figure 8. X-ray tomography at 3 months (S100%, intact socket). (A) Longitudinal view of 4 implants. (B) Coronal view of implant C with mineralized bone cortical allograft particles. The blue arrow indicates the buccal wall with post-extraction resorption.

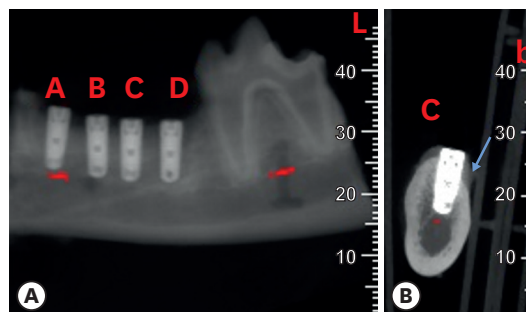


Figure 9. X-ray tomography at 3 months with 50% of the buccal wall (BW) removed (S50%, buccal wall socket height reduced by 50%). (A) Longitudinal view of 4 implants. (B) Coronal view of implant C with mineralized bone cortical allograft particles and a membrane. The blue arrow indicates the BW with limited resorption.

DISCUSSION

The technique of immediately placing implants after tooth extraction does not protect from bone reduction along the buccal-lingual or vertical axes. Alveolar post-extraction resorption varies from 2 to 4 mm in the vertical and horizontal axes, with an average of 3 mm [19].

Certain criteria, including the position of the implant with respect to the crest, the distance that separates the implant from the alveolar buccal wall, and the diameter of the implant, influence bone reshaping during the post-implant healing phase [20]. A study showed that the buccal wall must have an original width of 2 mm to avoid loss of bone height. In addition to the importance of the thickness of the alveolar buccal wall, the space between the implant and socket is also involved in the phenomenon of bone reduction [21]. Indeed, the diameter of a dental root is often larger than the implant. Animal and clinical studies have shown that a space between 1 to 2.25 mm was easily filled after 4 months using rough surface implants with an additional vertical ridge reduction [22,23]. A gap between the implant and the socket wall smaller than 1.5 mm will be completely filled independently from the loss in the height of the buccal bone [24].

These data are not significantly different from well-established findings regarding physiological osseous post-extraction resorption.

Our investigation evaluated the dimensional changes (from 1 month to 3 months) of the buccal and lingual alveolar bone wall after placing an implant into fresh extraction sockets (control sites). Post-extraction resorption of the buccal wall was recognized as inevitable in cases of the immediate placement of implants [6-8,25,26]. Our results confirmed, in control sites, that immediate implant placement did not avoid post-extraction resorption, regardless of the alveolar bone height, which is in agreement with the current literature [6-8,20,21]. At 3 months, dimensional changes of the socket were most pronounced on the buccal side, and greater in magnitude than has been reported in other studies. This tendency was probably related to differences in diet.

Many authors have studied the contribution of regenerative techniques in limiting bone resorption [10,12,14,16,17,19,26-36]. Few studies have assessed mineralized bone cortical allografts in comparison with mineralized or demineralized cancellous allografts or xenografts for the preservation of bone volume and quantity of newly-formed bone. They also showed fewer residual particles in allografts than in xenografts, which contributed to the use of allograft particles in this study [29,31,37,38]. Furthermore, we analyzed whether the regenerative procedures associated with these particles influenced bone remodeling around implants.

We observed that dimensional changes in the alveolar ridge occurred following implant placement in fresh extraction sockets, regardless of the application of regenerative procedures, and that buccal wall resorption was more pronounced, both in the control and the test sites.

The findings of this study confirm the positive contribution of these regenerative techniques in terms of osseous volume preservation during implant surgery for both cortical allograft particles (cortical Puros®) and cortical allograft particles combined with a resorbable collagenic membrane (Copios®), with better osseous volume preservation observed when mineralized bone cortical allograft was combined with a collagenous membrane.

This could be explained by the fact that the graft was placed between the implant and buccal wall. When peri-implant gaps were filled with mineralized bone cortical allograft, post-extraction bone resorption was reduced, not prevented completely. Therefore, regenerative procedures (i.e., a mineralized bone cortical allograft combined with a resorbable collagenous membrane) improved bone remodeling and osseointegration around the implants.

Additionally, at 1 month, we observed a significant increase in the BIC when the mineralized bone cortical allograft was used in comparison with the control sites, demonstrating that osseointegration was not perturbed and may instead have been accelerated. Mineralized bone cortical allograft particles did not perturb osseointegration because they were never in direct contact with the implant surface.

In the early period of healing, allograft particles were surrounded by newly formed bone, confirming their capacity for osseosynthesis, but they did not form a real continuity with the socket bone. They had a high degree of biocompatibility with the surrounding tissue and were mainly replaced by newly formed bone at 3 months. These observations for residual cortical Puros® chips are similar to those made in studies of other allografts [29,36-38].

Considerable interest has emerged in bone cortical allograft particles in the immediate extraction-implantation technique. The smaller number of residual particles due to higher resorbability than xenografts or other biomaterials described in the literature allows the regenerated bone structure to be more similar to the original bone. A mineralized bone cortical allograft combined with a collagen membrane allows a significant reduction in buccal and lingual bone resorption, which was higher than observed using mineralized bone cortical allograft alone. The membrane is used as a barrier to hold the mineralized bone cortical allograft in place during the entire healing time. Therefore, the real benefit of using a mineralized bone cortical allograft and membranes in implant surgery is preserving bone volume and enhancing osseointegration, which are the key factors for clinical success.

In conclusion, within the limits of this study, we demonstrated that the regenerative technique after immediate implant placement in a fresh extraction socket with bone cortical allografts combined with a membrane significantly limited buccal wall bone resorption. Furthermore, we showed that when this technique was used, the regenerated bone was similar to the original bone in terms of histological structure.

REFERENCES

1. Wheeler SL, Vogel RE, Casellini R. Tissue preservation and maintenance of optimum esthetics: a clinical report. *Int J Oral Maxillofac Implants* 2000;15:265-71.
[PUBMED](#)
2. Paolantonio M, Dolci M, Scarano A, d'Archivio D, di Placido G, Tumini V, et al. Immediate implantation in fresh extraction sockets. A controlled clinical and histological study in man. *J Periodontol* 2001;72:1560-71.
[PUBMED](#) | [CROSSREF](#)
3. Chen ST, Wilson TG Jr, Hämmerle CH. Immediate or early placement of implants following tooth extraction: review of biologic basis, clinical procedures, and outcomes. *Int J Oral Maxillofac Implants* 2004;19 Suppl:12-25.
[PUBMED](#)
4. Lindeboom JA, Tjiook Y, Kroon FH. Immediate placement of implants in periapical infected sites: a prospective randomized study in 50 patients. *Oral Surg Oral Med Oral Pathol Oral Radiol Endod* 2006;101:705-10.
[PUBMED](#) | [CROSSREF](#)
5. Schropp L, Isidor F, Kostopoulos L, Wenzel A. Patient experience of, and satisfaction with, delayed-immediate vs. delayed single-tooth implant placement. *Clin Oral Implants Res* 2004;15:498-503.
[PUBMED](#) | [CROSSREF](#)
6. Araújo MG, Lindhe J. Dimensional ridge alterations following tooth extraction. An experimental study in the dog. *J Clin Periodontol* 2005;32:212-8.
[PUBMED](#) | [CROSSREF](#)

7. Araújo MG, Sukekava F, Wennström JL, Lindhe J. Tissue modeling following implant placement in fresh extraction sockets. *Clin Oral Implants Res* 2006;17:615-24.
[PUBMED](#) | [CROSSREF](#)
8. Araújo MG, Wennström JL, Lindhe J. Modeling of the buccal and lingual bone walls of fresh extraction sites following implant installation. *Clin Oral Implants Res* 2006;17:606-14.
[PUBMED](#) | [CROSSREF](#)
9. Tan WL, Wong TL, Wong MC, Lang NP. A systematic review of post-extraction alveolar hard and soft tissue dimensional changes in humans. *Clin Oral Implants Res* 2012;23 Suppl 5:1-21.
[PUBMED](#) | [CROSSREF](#)
10. Simion M, Dahlin C, Trisi P, Piattelli A. Qualitative and quantitative comparative study on different filling materials used in bone tissue regeneration: a controlled clinical study. *Int J Periodontics Restorative Dent* 1994;14:198-215.
[PUBMED](#)
11. Chen ST, Darby IB, Adams GG, Reynolds EC. A prospective clinical study of bone augmentation techniques at immediate implants. *Clin Oral Implants Res* 2005;16:176-84.
[PUBMED](#) | [CROSSREF](#)
12. Barone A, Ricci M, Calvo-Guirado JL, Covani U. Bone remodelling after regenerative procedures around implants placed in fresh extraction sockets: an experimental study in Beagle dogs. *Clin Oral Implants Res* 2011;22:1131-7.
[PUBMED](#) | [CROSSREF](#)
13. Dimova C. Socket preservation procedure after tooth extraction. *Key Eng Mater* 2014;587:325-30.
[CROSSREF](#)
14. Evans CD, Chen ST. Esthetic outcomes of immediate implant placements. *Clin Oral Implants Res* 2008;19:73-80.
[PUBMED](#)
15. Han JY, Shin SI, Herr Y, Kwon YH, Chung JH. The effects of bone grafting material and a collagen membrane in the ridge splitting technique: an experimental study in dogs. *Clin Oral Implants Res* 2011;22:1391-8.
[PUBMED](#) | [CROSSREF](#)
16. Iasella JM, Greenwell H, Miller RL, Hill M, Drisko C, Bohra AA, et al. Ridge preservation with freeze-dried bone allograft and a collagen membrane compared to extraction alone for implant site development: a clinical and histologic study in humans. *J Periodontol* 2003;74:990-9.
[PUBMED](#) | [CROSSREF](#)
17. Simon BI, Von Hagen S, Deasy MJ, Faldu M, Resnansky D. Changes in alveolar bone height and width following ridge augmentation using bone graft and membranes. *J Periodontol* 2000;71:1774-91.
[PUBMED](#) | [CROSSREF](#)
18. Vignoletti F, Sanz M. Immediate implants at fresh extraction sockets: from myth to reality. *Periodontol* 2000 2014;66:132-52.
[PUBMED](#) | [CROSSREF](#)
19. Feuille F, Knapp CI, Brunsvold MA, Mellonig JT. Clinical and histologic evaluation of bone-replacement grafts in the treatment of localized alveolar ridge defects. Part 1: mineralized freeze-dried bone allograft. *Int J Periodontics Restorative Dent* 2003;23:29-35.
[PUBMED](#)
20. Tomasi C, Sanz M, Cecchinato D, Pjetursson B, Ferrus J, Lang NP, et al. Bone dimensional variations at implants placed in fresh extraction sockets: a multilevel multivariate analysis. *Clin Oral Implants Res* 2010;21:30-6.
[PUBMED](#) | [CROSSREF](#)
21. Qahash M, Susin C, Polimeni G, Hall J, Wikesjö UM. Bone healing dynamics at buccal peri-implant sites. *Clin Oral Implants Res* 2008;19:166-72.
[PUBMED](#) | [CROSSREF](#)
22. Botticelli D, Berglundh T, Buser D, Lindhe J. The jumping distance revisited: an experimental study in the dog. *Clin Oral Implants Res* 2003;14:35-42.
[PUBMED](#) | [CROSSREF](#)
23. Botticelli D, Renzi A, Lindhe J, Berglundh T. Implants in fresh extraction sockets: a prospective 5-year follow-up clinical study. *Clin Oral Implants Res* 2008;19:1226-32.
[PUBMED](#) | [CROSSREF](#)
24. Wilson TG Jr, Schenk R, Buser D, Cochran D. Implants placed in immediate extraction sites: a report of histologic and histometric analyses of human biopsies. *Int J Oral Maxillofac Implants* 1998;13:333-41.
[PUBMED](#)

25. Botticelli D, Berglundh T, Lindhe J. Hard-tissue alterations following immediate implant placement in extraction sites. *J Clin Periodontol* 2004;31:820-8.
[PUBMED](#) | [CROSSREF](#)
26. Klinge B, Alberius P, Isaksson S, Jönsson J. Osseous response to implanted natural bone mineral and synthetic hydroxylapatite ceramic in the repair of experimental skull bone defects. *J Oral Maxillofac Surg* 1992;50:241-9.
[PUBMED](#) | [CROSSREF](#)
27. Araújo M, Linder E, Wennström J, Lindhe J. The influence of Bio-Oss Collagen on healing of an extraction socket: an experimental study in the dog. *Int J Periodontics Restorative Dent* 2008;28:123-35.
[PUBMED](#)
28. Becker W. Treatment of small defects adjacent to oral implants with various biomaterials. *Periodontol* 2000 2003;33:26-35.
[PUBMED](#) | [CROSSREF](#)
29. Block MS, Finger I, Lytle R. Human mineralized bone in extraction sites before implant placement: preliminary results. *J Am Dent Assoc* 2002;133:1631-8.
[PUBMED](#) | [CROSSREF](#)
30. Brugnami F, Then PR, Moroi H, Leone CW. Histologic evaluation of human extraction sockets treated with demineralized freeze-dried bone allograft (DFDBA) and cell occlusive membrane. *J Periodontol* 1996;67:821-5.
[PUBMED](#) | [CROSSREF](#)
31. Keith JD Jr, Petrungaro P, Leonetti JA, Elwell CW, Zeren KJ, Caputo C, et al. Clinical and histologic evaluation of a mineralized block allograft: results from the developmental period (2001–2004). *Int J Periodontics Restorative Dent* 2006;26:321-7.
[PUBMED](#)
32. Lee DW, Pi SH, Lee SK, Kim EC. Comparative histomorphometric analysis of extraction sockets healing implanted with bovine xenografts, irradiated cancellous allografts, and solvent-dehydrated allografts in humans. *Int J Oral Maxillofac Implants* 2009;24:609-15.
[PUBMED](#)
33. Schropp L, Kostopoulos L, Wenzel A. Bone healing following immediate versus delayed placement of titanium implants into extraction sockets: a prospective clinical study. *Int J Oral Maxillofac Implants* 2003;18:189-99.
[PUBMED](#)
34. Simion M, Trisi P, Piattelli A. GBR with an e-PTFE membrane associated with DFDBA: histologic and histochemical analysis in a human implant retrieved after 4 years of loading. *Int J Periodontics Restorative Dent* 1996;16:338-47.
[PUBMED](#)
35. Wang HL, Tsao YP. Histologic evaluation of socket augmentation with mineralized human allograft. *Int J Periodontics Restorative Dent* 2008;28:231-7.
[PUBMED](#)
36. Wood RA, Mealey BL. Histologic comparison of healing after tooth extraction with ridge preservation using mineralized versus demineralized freeze-dried bone allograft. *J Periodontol* 2012;83:329-36.
[PUBMED](#) | [CROSSREF](#)
37. Wang HL, Boyapati L. “PASS” principles for predictable bone regeneration. *Implant Dent* 2006;15:8-17.
[PUBMED](#) | [CROSSREF](#)
38. Hämmerle CH, Jung RE, Yaman D, Lang NP. Ridge augmentation by applying bioresorbable membranes and deproteinized bovine bone mineral: a report of twelve consecutive cases. *Clin Oral Implants Res* 2008;19:19-25.
[PUBMED](#)