



Unruptured pregnancy in a noncommunicating rudimentary horn at 37 weeks with a live fetus: a case report

Chen Cheng, Weiwei Tang, Lei Zhang, Mei Luo, Meihua Huang, Xiuling Wu, Guiping Wan [✉]

Laboratory of Gynecological Oncology, Jiangsu Province Hospital on Integration of Chinese and Western Medicine Affiliated to Nanjing University of Traditional Chinese Medicine, Nanjing, Jiangsu 210028, China.

Abstract

We report an extremely rare case of an unruptured non-communicating rudimentary horn full-term pregnancy. A woman who had a uterine malformation was misdiagnosed as uterus didelphys and gave birth to a live, healthy fetus. The correct diagnosis was not made until cesarean section at 37 4/7 weeks. The case suggests that women who are pregnant in a rudimentary horn could obtain a full-term delivery and give birth to a live and healthy baby.

Keywords: unruptured, non-communicating rudimentary horn, full-term delivery

Introduction

Unicornuate uterus with a rudimentary horn is a rare müllerian anomaly which has a high incidence of obstetric complications including ectopic pregnancy in the rudimentary horn. The true prevalence of müllerian duct abnormalities is not well established because the majority of patients are asymptomatic and it is approximately 1:200–1:600 in fertile women. However, rudimentary horn pregnancy occurs in approximately 1 of every 76,000 pregnancies and commonly presents with first- or second-trimester uterine rupture. The unicornuate uterus with a non-communicating uterine horn is one of these conditions. In such cases, only 50% to 55% are symptomatic, and only 8% of rudimentary horn pregnancies are diagnosed before the symptoms appear. Term pregnancies with delivery of a live fetus have been rarely reported in such unusual and life-threatening condition. We report an extremely rare case of a pregnancy in a

non-communicating rudimentary uterine horn which reached a full-term delivery, without rupture, to a healthy neonate.

Case report

A 25-year-old woman, gravida 1 para 0, presented at our hospital. According to her reliable dates, she was at a 37 2/7-week that pregnancy. A review of her menstrual history revealed her menarche was achieved at thirteen. The patient had a regular menstrual cycle of 30 days and her menstruation was consistently about 7 days duration. A previous ultrasound at early pregnancy revealed a single fetus intrauterine pregnancy with congenital uterine malformation, diagnosed as didelphys. During her pregnancy, the patient was not on regular follow-up. A single, meticulous examination was performed at the 7th month, revealing a single live intrauterine fetus which conformed to her gestational weeks. Threatened premature delivery did not

[✉] Corresponding author: Guiping Wan, MD, Laboratory of Gynecological Oncology, Jiangsu Province Hospital on Integration of Chinese and Western Medicine Affiliated with Nanjing University of Traditional Chinese Medicine, 100 Hongshan Road, Nanjing, Jiangsu 210029, China.

Tel/fax: +86-25-85608658/+86-25-85637817, E-mail: wgplab@163.com. Received 04 July 2013, Revised 15 August 2013, Accepted 04 December 2013, Epub 28 February 2014

The authors reported no conflict of interests.

emerge until 34 5/7 weeks. She then received tocolysis upon admission into another hospital. Magnesium sulfate was used to inhibit uterine contractions in order to delay delivery until the gestational age of 37 weeks. Two weeks later, her condition stabilized and she was discharged. In follow-up examinations, her pulse rate and blood pressure were both normal and the fundus of the uterus corresponded to the date of her pregnancy.

Upon admission to our hospital, she was required to complete the related auxiliary examination. Laboratory examinations and fetal monitoring were normal except that the latest ultrasound showed that the amniotic fluid index was only 7.3 cm and the patient was diagnosed with borderline oligohydramnios and breech presentation. No slight lower abdominal pain, no vaginal bleeding, or no uterine contractions was detected. In order to raise her amniotic fluid levels, fluid replacement therapy was performed immediately. The next day, the results of her examinations showed that her cholic acid was 6.741 $\mu\text{g/mL}$, highly suggestive of

intrahepatic cholestasis of pregnancy. The amniotic fluid index returned to normal. Regular contractions were detected in fetal monitoring. Because her pregnancy was primigravida with breech presentation with suspected intra-hepatic cholestasis of pregnancy and her uterine malformation, vaginal delivery was not feasible. The patient and her family consented to cesarean section delivery.

The next day, cesarean section was performed and, intraoperatively, a large intact right-sided uterine horn was observed to be the size of a full-term pregnancy, while the left sided uterine horn increased to the size of two months' pregnancy. The uterine surface was coarse and full of congestive blood vessels. The right-side uterine horn was incised to deliver a fetus of 37 4/7 weeks gestation. The neonate was a live girl weighting 2,550 g, and the Apgar score was normal. The placenta could not be easily stripped, so artificial stripping of the placenta was performed. Uterine massage was performed in order to promote uterine contractions;

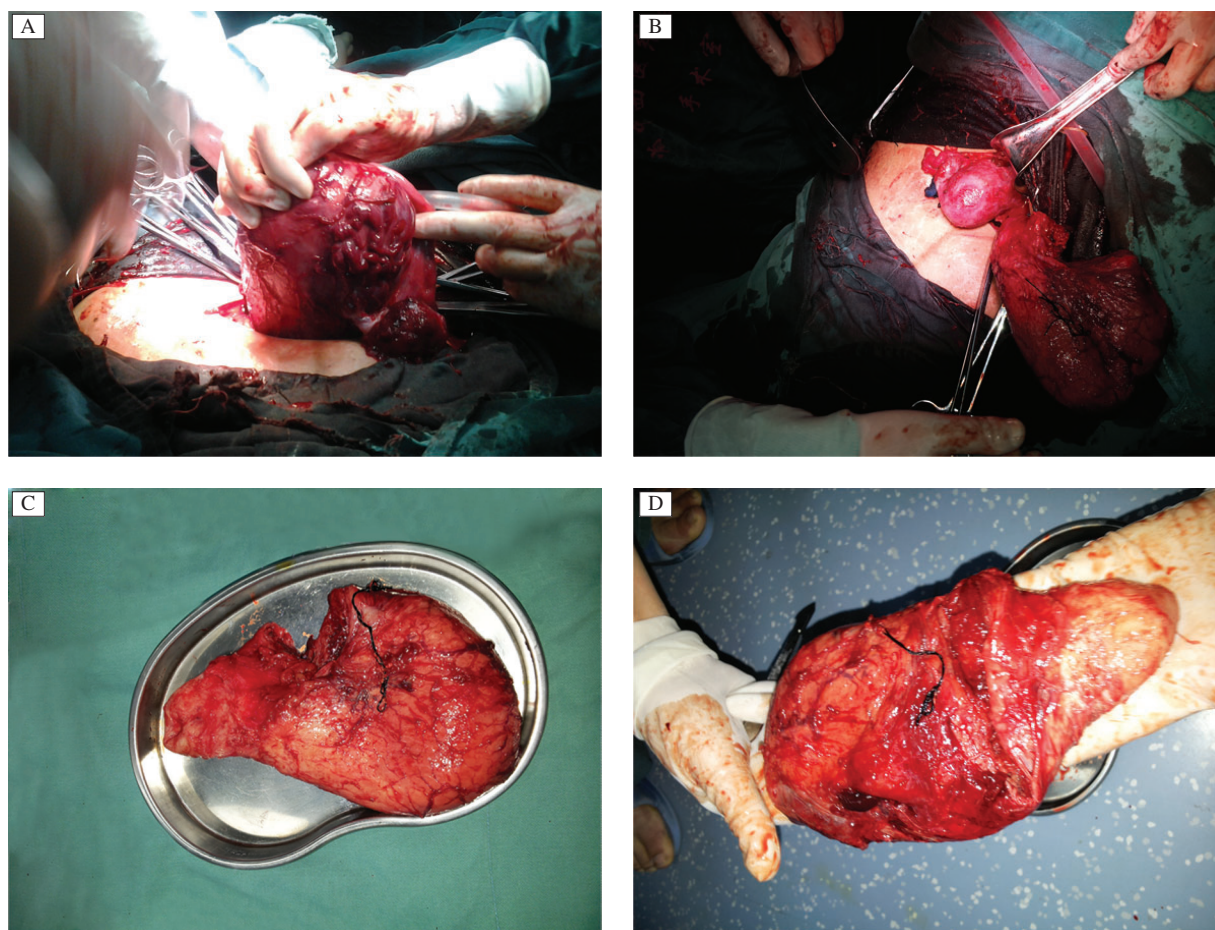


Fig. 1 The rudimentary horn of a patient with an unruptured non-communicating rudimentary horn who reached full-term pregnancy and delivered a healthy baby. A: View of the right sided rudimentary horn intra-uterine pack with sterilized gauze before excision. B: Intra-operative photograph showing the normal uterus with the rudimentary horn attached to its right. C: Sectioned rudimentary horn. D: Inner view of the non-communicating rudimentary horn with the cavity.

however, intractable bleeding from the placenta bed was uncontrollable and an intra-uterine pack with sterilized gauze was applied (**Fig. 1A**). During this process, the rudimentary horn was identified and excised from the uterus to control bleeding. There was no communication between the rudimentary horn and the main uterine cavity. The stump was then sutured (**Fig. 1B**). A peritoneal lavage was done and the abdomen was closed. Resection of the rudimentary horn was completed successfully (**Fig. 1C**). Total blood loss was about 1,500 mL and 200 mL fresh frozen blood plasma and 4 units of red blood cell were transfused followed by 1,200 mL crystalloid and 1,300 mL colloid.

A pregnancy in a non-communicating rudimentary horn was confirmed after the operation (**Fig. 1D**). Pathological and histological findings confirmed a right-sided non-communicating rudimentary horn with cavity. Her postoperative course was uneventful. Her temperature, pulse and blood pressure were all normal the next day except that her hemoglobin was 82.0 g/L. An anti-infection treatment and a blood-tonifying drug were used until she was discharged. As a result of blood loss, she was still anemic when discharged, with the hemoglobin showing 74.0 g/L, and she required further treatment for anemia during follow-up.

Discussion

The unicornuate uterus with a non-communicating rudimentary horn results from the normal development and maturation of one of the müllerian ducts with concomitant hypoplasia of the contralateral müllerian duct^[1]. According to the American Fertility Society (AFS), “unicornuate” uterus müllerian duct anomalies are classified as follows: “class a” is with cavity, communicating with the uterus; “class b” is with cavity, not communicating with the uterine; “class c” is without cavity; and “class d” is without horn.

Pregnancy in a non-communicating rudimentary horn is considered to be the result of transperitoneal migration of either the ovum or the zygote from the contralateral side. Previous reports demonstrated that uterine rupture occurred in 80% of rudimentary horn pregnancies and most pregnancies in these cases ruptured in the second trimester before the 20th week of gestation^[2]. Despite early ultrasonography, it is still difficult to make a clear diagnosis of pre-rupture rudimentary horn pregnancy. The preoperative diagnosis is provided in only 22% gynecologic and 29% obstetric cases, so most diagnoses are confirmed only after laparotomy. Few cases are diagnosed in the first trimester and most of them are asymptomatic or have a uterine abnormality as described previously. Magnetic reso-

nance imaging has proven to be a very effective, noninvasive tool for the diagnosis of müllerian abnormalities, but this modality is expensive for routine use, except when rudimentary horn pregnancy is suspected either by history or by early suspicious ultrasound examinations. As a result, late or wrong diagnosis resulting in uterine rupture is frequent.

For a precise diagnosis and protect maternal health, routine ultrasonographic diagnosis in the first trimester is important^[3-5]. However, the overall sensitivity of ultrasonography for diagnosing a rudimentary horn or rudimentary horn pregnancy is actually low at early pregnancy, especially when it is used for the differential diagnosis of ectopic pregnancy with other uterine malformations, such as uterus biconis, uterus duplex and mediastinum uterus, suggesting that clinicians should pay more attention to pregnancy combined with uterine malformation during routine obstetric examinations, especially, when there is a possibility of an ectopic pregnancy in a rudimentary horn which is characterized by malpresentation or other complications. When these circumstances occur, some necessary measures must be implemented immediately according to symptoms. Termination of pregnancy should also be performed, if necessary, once a rudimentary horn pregnancy is confirmed and the horn excised^[6].

The case of rudimentary horn pregnancy presented in this report was misdiagnosed as uterus didelphys prior to the cesarean section. However, several worthy points should be focused on. Firstly, cases of pregnancy in the rudimentary horn with a full-term delivery have seldom been reported, so far, especially a patient who gave birth to a healthy baby^[7]. Secondly, during routine obstetric examination, our patient had none of the typical manifestations usually found in rudimentary horn pregnancies. Borderline oligohydramnios and intrahepatic cholestasis of pregnancy should not be due to rudimentary horn, while malpresentation might be attributed to rudimentary horn because there was less space available for favorable adaptation of the fetal head in the uterus. Thirdly, although such cases are rare, clinician should be aware of this life-threatening condition and, once it is identified, mandatory life saving procedures such as timely laparotomy and immediate removal of the horn should be performed as was done in our case^[8-10]. Laparoscopic resection is limited to pre-rupture first trimester cases and it was reported to be successful in some cases. Last but not least, this case may shed light on correct diagnosis and differential diagnosis of rudimentary horn pregnancy when this circumstance occurs in the future, in order to effectively reduce the rate of missed diagnosis and misdiagnosis of this condition.

References

- [1] Junqueira B, Allen L, Spitzer R, et al. Müllerian duct anomalies and mimics in children and adolescents: correlative intraoperative assessment with clinical imaging. *Radiographics* 2009;29(4):1085–1103.
- [2] Goel P, Saha PK, Mehra R, et al. Unruptured postdated pregnancy with a live fetus in a noncommunicating rudimentary horn. *Indian J Med Sci* 2007;61(4):23–27.
- [3] Arslan T, Bilgiç E, Sentürk MB, et al. Rudimentary uterine horn pregnancy: a mystery diagnosis. *Fertil Steril* 2009; 92(6):203.e1–3.
- [4] D Reichman, MR Laufer, BK Robinson. Pregnancy outcomes in unicornuate uteri: a review. *Fertil Steril* 2009; 91(5):1886–1894.
- [5] S Chopra, A Keepanasseri, M Rohilla, et al. Obstetric morbidity and the diagnostic dilemma in pregnancy in rudimentary horn: retrospective analysis. *Arch Gynecol Obstet* 2009;280(6):907–910.
- [6] Lennox G, Pantazi S, Keunen J, et al. Minimally invasive surgical management of a second trimester pregnancy in a rudimentary uterine horn. *J Obstet Gynaecol Can* 2013; 35(5):468–472.
- [7] Patra S, Puri M, Trivedi SS, et al. Unruptured term pregnancy with a live fetus with placenta percreta in a noncommunicating rudimentary horn. *Congenit Anom (Kyoto)* 2007;47(4):156–157.
- [8] Thakur S, Sood A, Sharma C. Ruptures noncommunicating rudimentary horn pregnancy at 19 weeks with previous cesarean delivery: a case report. *Case Rep Obstet Gynecol* 2012;2012:308476.
- [9] Kanagal DV, Hanumanalu LC. Ruptured rudimentary horn pregnancy at 25 weeks with previous vaginal delivery: a case report. *Case Rep Obstet Gynecol* 2012;2012: 985076.
- [10] Singh N, Singh U, Verma ML. Ruptured bicornuate uterus mimicking ectopic pregnancy: A case report. *J Obstet Gynaecol Res* 2013;39(1):364–366.

CLINICAL TRIAL REGISTRATION

The *Journal* requires investigators to register their clinical trials in a public trials registry for publication of reports of clinical trials in the *Journal*. Information on requirements and acceptable registries is available at www.icmje.org/faq_clinical.html.