

# Direct oral anticoagulants compared to vitamin K antagonist for the management of left ventricular thrombus

Hansa Iqbal<sup>1</sup>, Sam Straw<sup>2</sup>, Thomas P. Craven<sup>2</sup>, Katherine Stirling<sup>3</sup>, Stephen B. Wheatcroft<sup>2</sup> and Klaus K. Witte<sup>2\*</sup>

<sup>1</sup>School of Medicine, University of Leeds, Leeds, UK; <sup>2</sup>Leeds Institute of Cardiovascular and Metabolic Medicine, University of Leeds, Leeds, UK; <sup>3</sup>Medicines Management and Pharmacy Service, Leeds Teaching Hospitals NHS Trust, Leeds, UK

## Abstract

**Aims** Left ventricular (LV) thrombus is increasingly detected in patients with and without ischaemic heart disease due to the increased availability of cardiac magnetic resonance imaging. Risk factors include anterior ST elevation myocardial infarction, delayed reperfusion therapy, and non-ischaemic cardiomyopathy with severe LV systolic dysfunction. We aimed to report the characteristics and outcomes of patients with LV thrombus treated with either vitamin K antagonist (VKA) or direct oral anticoagulants (DOAC) with a view to describing differences in efficacy, specifically, subsequent thromboembolic events, thrombus resolution, and also side effects of therapy including clinically significant bleeding.

**Methods and results** We conducted a retrospective, observational cohort study of patients diagnosed with LV thrombus between 1 December 2012 and 30 June 2018 and treated with either DOAC or VKA. We recorded patient demographics, past medical history, prescribed medications, and baseline investigations. The primary outcomes were rates of thromboembolism and clinically significant bleeding, with secondary outcomes of thrombus resolution on repeat cardiac imaging, repeat hospitalization, and all-cause mortality. During the study period, 84 patients were diagnosed with and managed for LV thrombus. Of these, 62 received VKA and 22 DOAC including 13 prescribed rivaroxaban, eight apixaban, and one dabigatran. Most patients 75 (89%) were male with an average age of  $62 \pm 14$  years. Ischaemic heart disease was the cause of LV impairment in 73 (87%) patients. Baseline characteristics were similar between groups at baseline. Most  $n = 55$  (65%) were co-prescribed a single antiplatelet agent and 32 (38%) received dual-antiplatelet therapy. During an average follow-up of  $3.0 \pm 1.4$  years, there were no statistically significant differences between VKA and DOAC in rates of stroke (2% vs. 0%,  $P = 0.55$ ), other thromboemboli (2% vs. 0%,  $P = 0.55$ ), or clinically significant bleeding (10% vs. 0%,  $P = 0.13$ ). The average interval to cardiac imaging follow-up was  $233 \pm 251$  days and was not different between groups ( $P = 0.83$ ), and there was no difference in the rate of resolution of thrombus (76% vs. 65%  $P = 0.33$ ). Rehospitalization (50% vs. 45%;  $P = 0.53$ ) and all-cause mortality (10% vs. 14%;  $P = 0.61$ ) were also similar.

**Conclusions** Our data suggest that DOACs are likely to be at least as effective and safe as VKA for stroke prevention in patients with LV thrombus and, despite their lack of a licence for this indication, are therefore likely to represent a reasonable and more convenient option for this setting. The optimal timing and type of anticoagulation for LV thrombus, as well as the role of screening for high-risk patients, should be tested in prospective, randomized trials.

**Keywords** Left ventricular thrombus; Direct oral anticoagulant; Vitamin K antagonist

Received: 13 November 2019; Revised: 18 February 2020; Accepted: 31 March 2020

\*Correspondence to: Dr Klaus K Witte, Leeds Institute of Cardiovascular and Metabolic Medicine, University of Leeds, LIGHT Building, Clarendon Way, Leeds LS2 9JT, UK.

Tel: (+44) 113 3926108. Email: k.k.witte@leeds.ac.uk

Hansa Iqbal and Sam Straw denote joint first authorship.

In patients receiving DOAC compared to vitamin K antagonist for left ventricular thrombus, there were no differences in the rates of thromboembolism, resolution of thrombus, or clinically significant bleeding. Our study supports the use of DOAC in this patient group; further prospective studies are needed to determine the optimal treatment strategy for LV thrombus.

## Introduction

Left ventricular (LV) thrombus is frequently identified in patients presenting with anterior ST elevation myocardial infarction (STEMI) despite primary percutaneous coronary intervention (PCI). It is detectable by echocardiography in 4–8% of those undergoing reperfusion therapy<sup>1,2</sup> but is often found incidentally by cardiovascular magnetic resonance imaging (CMR) which has greater sensitivity.<sup>3</sup> LV thrombus is more common in those with large, anterior infarcts<sup>4</sup> and in those who do not receive prompt reperfusion but can also occur in non-ischaemic cardiomyopathies with severe LV systolic dysfunction.<sup>5</sup>

The presence of LV thrombus presents an increased risk of systemic thromboembolism including stroke in around 10–15% of patients in the absence of anticoagulation.<sup>6</sup> In patients with LV thrombus after acute myocardial infarction, most thromboembolic events occur within the first 4 months,<sup>7</sup> whilst in most cases, thrombus is no longer visible within 3–6 months.<sup>4</sup> Observational studies have demonstrated a reduced risk of thromboembolism with administration of vitamin K antagonist (VKA), which until recently have been the only available treatment option.<sup>7</sup>

Direct oral anticoagulants (DOAC) are now first-line protection against thromboembolic events in patients with non-valvular atrial fibrillation (AF) due to their greater safety, clinical effectiveness, and more predictable pharmacokinetics compared to VKA, prompting the inference that DOAC might perform similarly in reducing the risk of thromboembolism due to LV thrombus. There have been no prospective trials comparing the use of DOAC with VKA for LV thrombus, and international guidelines do not make specific recommendations about the optimal type of anticoagulant,<sup>8</sup> yet anecdotally their use for this indication is increasing.<sup>9</sup>

## Objectives

We aimed to report the characteristics and outcomes of patients with LV thrombus treated with either VKA or DOAC with a view to describing differences in efficacy, specifically, in terms of subsequent thromboembolic events, thrombus resolution and also side effects of therapy including clinically significant bleeding.

## Methods

### Study design

This was a retrospective, observational cohort study, designed and reported according to the Strengthening the Reporting of Observational Studies in Epidemiology (STROBE) statement.<sup>10</sup>

## Setting

The study was undertaken at the Leeds Teaching Hospitals NHS Trust (LTHT) which is a tertiary referral centre for cardiology. LTHT provides primary PCI for the West Yorkshire region, which has a population of approximately 3.5 million and has routine access to transthoracic echocardiography (TTE), contrast TTE, and CMR.

## Participants

Patients aged over 18 years cared for at our institution and diagnosed with LV thrombus between 1 December 2012 and 30 June 2018 were eligible for inclusion. Patients were excluded if they were treated with low-molecular weight heparin (LMWH) or were not anticoagulated because of either chronic organized thrombus or patient preference. Patients bridged with LMWH until the international normalized ratio (INR) was therapeutic and subsequently treated with VKA were not excluded. We also excluded patients receiving anticoagulation prior to diagnosis for other indications, those anticoagulated for LV aneurysm without evidence of thrombus, and those treated at other institutions. Patients who died within 30 days of diagnosis in whom data on anticoagulation and follow-up imaging were not available were excluded from our analysis. Patients were allocated to receive either DOAC or VKA based on patient preference, following discussion with their physician and anticoagulation counselling by clinical pharmacist. According to our institutional protocol, patients who received DOAC were made aware that this was an off-licence use of a licensed medication.

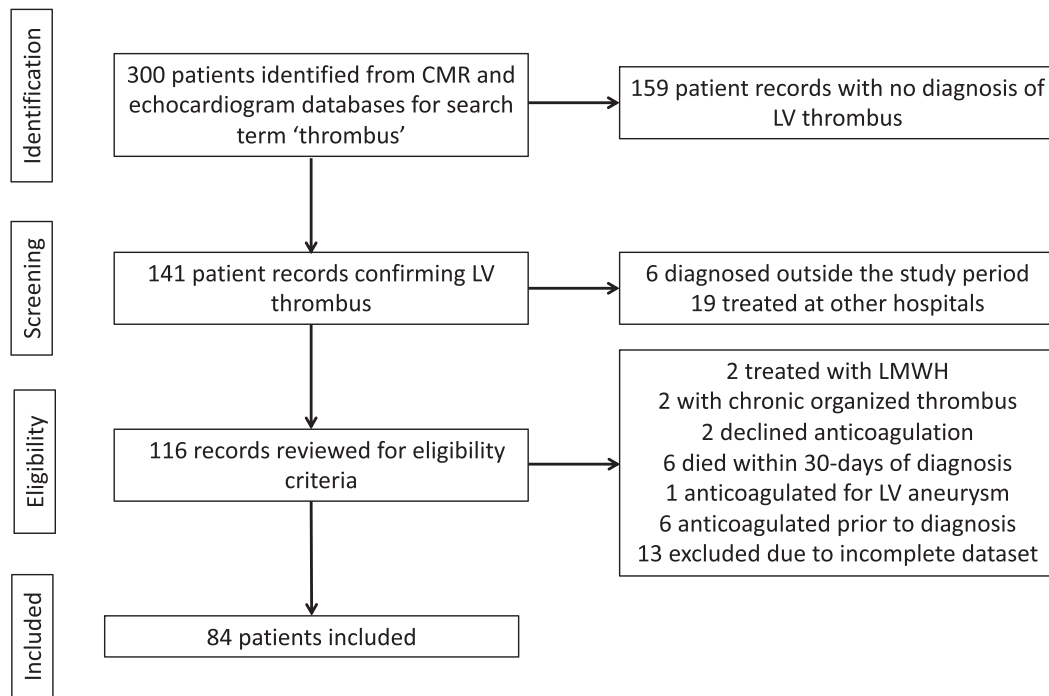
## Data sources

Patients were identified by searches of TTE, transoesophageal echocardiography (TOE), contrast TTE, and CMR databases for the term 'thrombus'. Patient records with datasets including the word 'thrombus' were manually evaluated for evidence of LV thrombus and scrutinized for inclusion criteria (*Figure 1*). The data for each patient were confirmed with reference to local electronic data systems and the written medical record.

## Variables

Demographic variables collected included patient age, sex, and ethnicity. Aetiology of LV impairment was classified as ischaemic cardiomyopathy (ICM), dilated cardiomyopathy (DCM), hypertrophic cardiomyopathy (HCM), acute myocarditis, or unknown. Recorded predisposing medical history included diabetes mellitus, hypertension, heart failure,

**Figure 1** Flow chart to show patient identification and exclusion criteria; 275 patients were treated for LV thrombus during the study period, of whom 84 were included in our analysis.



smoking history, atrial fibrillation (AF), history of thromboembolism, peripheral arterial disease (PAD), previous stroke or transient ischaemic attack (TIA), immobility, hospitalization within the past 12 months, inflammatory disease, active cancer, and CHA<sub>2</sub>DS<sub>2</sub>VASc score. We also collected data on laboratory investigations including haemoglobin, platelets, creatinine, and N-terminal pro-B-type natriuretic peptide (NT-pro-BNP) and cardiac imaging data including left ventricular ejection fraction (LVEF), LV volume, LV internal diameter in diastole (LVIDd), degree of mitral regurgitation (MR), and the presence of regional wall motion abnormality (RWMA).

## Outcomes

The primary outcomes were thromboembolic events during the study period and clinically relevant bleeding. Secondary outcomes were resolution of thrombus on subsequent imaging, all-cause mortality, and repeat hospitalization.

## Statistics

Normally distributed continuous variables are expressed as mean  $\pm$  standard deviation, non-normally distributed continuous variables by median and range in parentheses. Discrete variables are presented as number and percentages in parentheses. Comparisons between categorical variables were

compared using  $\chi^2$  and continuous variables by Student's *t*-test. In all analyses, a *P*-value of  $<0.05$  was regarded as statistically significant.

## Definitions

Patient ethnicity was classified according to the 2011 Census for England, Northern Ireland and Wales. Ischaemic cardiomyopathy was defined as either a myocardial infarction at index presentation, previous coronary artery bypass grafting, previous PCI, evidence of inducible ischaemia on non-invasive imaging or scar suggesting infarction on CMR. Inflammatory disease was defined as any systemic inflammatory process, including but not limited to rheumatoid arthritis, systemic lupus erythematosus, and vasculitis. LVEF was determined by CMR where possible, or from TTE by Simpson's biplane where endocardial border definition allowed. Mitral regurgitation was regarded as categorical as either moderate or severe. Repeat imaging was any cardiac imaging undertaken during follow-up following diagnosis of LV thrombus, regardless of the documented indication. Rehospitalization was any admission to hospital following the index episode, and cardiac admissions were those in which the primary diagnosis was due to the cardiology complaint. Clinically relevant bleeding was any episode of bleeding documented on the hospital medical record including hospitalization, attendance at the emergency department, or described in subsequent correspondence

during the period of anticoagulation. Resolution of LV thrombus on repeat imaging was defined as either no evidence of thrombus or organization of thrombus.

## Ethical considerations

The study protocol was approved by local governance processes at LHT as a retrospective service evaluation (audit) and therefore did not require specific ethical approval or patient consent, providing that usual data protection was in place. Only members of the clinical team had access to routinely collected data, which were anonymized at the point of analysis.

## Results

### Patients

Between 1 December 2012 and 30 June 2018, 84 patients were diagnosed with and managed for LV thrombus in LHT (*Figure 1*). The average length of follow-up was  $3.0 \pm 1.4$  years. Anticoagulation was ceased in 46 (55%) patients prior to censorship. The average duration of anticoagulation was  $677 \pm 568$  days and not different between DOAC ( $545 \pm 368$  days) and VKA ( $724 \pm 619$  days) ( $P = 0.21$ ). Of the patients included in our analysis, 75 (89%) were male with an average age of  $62 \pm 14$  years. Most were White European ( $n = 73$ ), and the group included South Asians ( $n = 5$ ), East Asians ( $n = 2$ ), Black-Africans ( $n = 2$ ), and two patients who classed themselves as other ethnicities.

Most ( $n = 73$ , 87%) had ischaemic heart disease as the cause of LV impairment leading to thrombus, of whom 29 (35%) patients were diagnosed following myocardial infarction, following an interval of  $5 \pm 7$  days. Four (5%) had DCM, three (4%) had HCM, two (2%) developed LV thrombus following an episode of acute myocarditis, and in two (2%), the aetiology of LV impairment was unknown. In six patients, LV thrombus was diagnosed following an initial presentation of stroke. In one patient, the presentation was acute myocardial infarction due to embolism of LV thrombus into the circumflex artery. For the remaining patients, LV thrombus was diagnosed incidentally on routine cardiac imaging.

### Treatment of left ventricular thrombus

There was a preference for VKA during the study period, which was prescribed for 62 (74%) patients, all of whom received warfarin which was given at a variable dosage to achieve INR between two and three. Of the 22 (26%) who received DOAC, 13 were prescribed rivaroxaban (20 mg once daily), eight prescribed apixaban (5 mg twice daily), and one dabigatran (150 mg twice daily). The clinical characteristics

of patients allocated to receive DOACs compared to VKA were similar at baseline, with the exception of lower platelet count, higher rate of PAD, and greater proportion of patients of ethnic minorities in the DOAC group (*Tables 1 and 2*). Fifty-five patients (65%) were co-administered an antiplatelet agent, which was aspirin in 48, clopidogrel in 33, and ticagrelor in 6. Thirty-two (38%) were co-administered dual antiplatelet therapy (DAPT) alongside anticoagulation.

### Thromboembolic events

During anticoagulation, there was one episode of stroke; this occurred 6 days following diagnosis of LV thrombus in a patient taking VKA. A second patient who was initially prescribed VKA developed a stroke following cessation of anticoagulation (with VKA) following resolution of thrombus on CMR. There were no significant differences between VKA and DOAC in rates of stroke (rate 2% vs. 0%,  $P = 0.55$ ). Other thromboemboli occurred in one patient taking VKA (rate 2% vs. 0%,  $P = 0.55$ ).

### Clinically significant bleeding

During follow-up, there were six documented cases of clinically significant bleeding, all occurring in patients taking VKA (rate 10% vs. 0%,  $P = 0.13$ ) (*Table 3*). There were three episodes of gastrointestinal bleeding: one requiring hospitalization and blood transfusion and two which were managed conservatively. There were no instances of intracranial bleeding. Three patients developed epistaxis, none of which required hospitalization or blood transfusion.

### Repeat imaging and resolution of thrombus

Repeat imaging datasets were available for 75 (89%) patients, 20 of whom received DOACs and 55 who received VKA (*Figure 2*). The mean duration between diagnosis and repeat imaging was  $233 \pm 251$  days with no difference between groups ( $P = 0.83$ ). There was no evidence of residual thrombus in 55 (73%) patients who underwent repeat imaging, 42 of whom receiving VKA and 13 received DOAC (rate 76% vs. 65%,  $P = 0.33$ ). The imaging modality was the same in 41 (55%), of the 34 patients who underwent a different imaging modality in 26 instances, the initial diagnosis was made by CMR, and the subsequent imaging was TTE.

### Hospitalization and all-cause mortality

During follow-up, 41 patients were hospitalized. In 16, this was determined to be cardiovascular, and in 34, the hospitalization was non-cardiovascular. There were no significant differences in rates of hospitalization between those receiving DOAC or

**Table 1** Baseline characteristics of patients receiving either DOAC or VKA

	All patients (n = 84)	DOAC (n = 22)	VKA (n = 62)	P-value
<b>Demographics</b>				
Age	62 ± 14	62 ± 13	62 ± 14	1.0
Male sex	75 (89)	20 (91)	55 (89)	0.77
<b>Ethnicity</b>				
White European	73 (87)	16 (73)	57 (92)	0.03
South Asian	5 (6)	3 (14)	2 (3)	
East Asian	2 (2)	0 (0)	2 (3)	
Black-African	2 (2)	1 (5)	1 (2)	
Other ethnicity	2 (2)	2 (9)	0 (0)	
<b>Past medical history</b>				
Hypertension	27 (32)	9 (41)	18 (29)	0.31
Diabetes mellitus	22 (26)	19 (86)	19 (31)	0.12
Smoking history	38 (49)	10 (45)	28 (50)	0.73
Active cancer	4 (5)	0 (0)	4 (6)	0.22
Heart failure	81 (96)	21 (95)	60 (94)	0.77
Hypercholesterolaemia	13 (15)	4 (18)	9 (15)	0.68
AF	6 (7)	3 (14)	3 (5)	0.17
Peripheral arterial disease	6 (7)	4 (18)	2 (3)	0.02
Stroke/TIA	10 (12)	1 (5)	9 (15)	0.21
Thromboembolism	3 (4)	1 (5)	2 (3)	0.77
Immobility	1 (1)	0 (0)	1 (2)	0.55
Admission in previous 12 months	10 (12)	1 (5)	9 (15)	0.21
Inflammatory disease	0 (0)	0 (0)	0 (0)	—
CHA <sub>2</sub> DS <sub>2</sub> VASc score	3 (1–8)	3 (1–5)	3 (1–8)	0.49
<b>Medications</b>				
Aspirin	48 (59)	9 (41)	39 (65)	0.05
Ticagrelor	6 (7)	0 (0)	7 (10)	0.12
Clopidogrel	33 (39)	11 (50)	22 (35)	0.28
Bisoprolol equivalent dose (mg)	4.6 ± 3.2	4.6 ± 2.9	4.6 ± 3.3	0.98
Ramipril equivalent dose (mg)	4.0 ± 2.9	3.8 ± 2.8	4.1 ± 2.9	0.66
Furosemide equivalent dose (mg)	31 ± 48	43 ± 46	26 ± 48	0.17
<b>Aetiology of heart failure</b>				
ICM	73 (87)	18 (82)	55 (89)	0.27
DCM	4 (5)	2 (9)	2 (3)	
HCM	3 (4)	2 (9)	1 (2)	
Myocarditis	2 (2)	0 (0)	2 (3)	
Unknown	2 (2)	0 (0)	2 (3)	

Continuous variables are expressed as mean ± standard deviation; categorical variables are presented as number and percentages in parentheses.

AF, atrial fibrillation; DCM, dilated cardiomyopathy; DOAC, direct acting oral anticoagulant; HCM, hypertrophic cardiomyopathy; ICM, ischaemic cardiomyopathy; TIA, transient ischaemic attack; VKA, vitamin K antagonist.

VKA (rate 50% vs. 45%,  $P = 0.53$ ) (Table 3). Excluding patients who died within 30 days of diagnosis, there were nine deaths during longer-term follow-up (Figure 1), with no difference between treatment groups and death caused by thromboembolism or bleeding (rate 10% vs. 14%,  $P = 0.61$ ).

## Discussion

### Key findings

In this single centre retrospective analysis of outcomes following anticoagulation for LV thrombus, there were no significant differences in the rates of systemic thromboembolism, resolution of thrombus, or bleeding between patients receiving DOAC or VKA. Of note, all episodes of clinically significant bleeding and systemic thromboembolism occurred in the group receiving VKA.

### Treatment duration and repeat imaging

The major risk of LV thrombus is systemic embolization of clot with distal ischaemia or infarction. Rates of thromboembolism appear to be higher in those with large or mobile thrombi and those that protrude into the LV cavity.<sup>6,11–13</sup> Based upon observational data, it is likely that formal anticoagulation reduces the risk of embolization, but it is unclear whether it affects the rate of thrombus resolution.<sup>14</sup>

The optimal duration of anticoagulation for LV thrombus is unknown, and although international guidelines suggest 3–6 months, there are no prospective data to support this recommendation.<sup>8</sup> Repeat imaging following a period of anticoagulation is recommended to assess for resolution with the suggestion that organized thrombus is associated with a lower rate of embolization allowing safe withdrawal of anticoagulation. In the present study, the interval between diagnosis and repeat imaging and the duration of

**Table 2** Cardiac imaging variables

Outcome	All patients (n = 84)	DOAC (n = 22)	VA (n = 62)	P-value
LVEF (%)	34 ± 13	31 ± 13	35 ± 13	0.31
LVIDd (mm)	54 ± 8	56 ± 8	53 ± 8	0.21
LV volume (mL)	232 ± 85	252 ± 80	221 ± 87	0.23
MR	14 (17)	3 (14)	11 (18)	0.66
RWMA	67 (81)	20 (91)	47 (76)	0.14
<i>Location</i>				
Apex	76 (95)	19 (90)	57 (97)	0.27
Anterior	4 (5)	2 (10)	2 (3)	
Haemoglobin (g/L)	142 ± 21	145 ± 18	141 ± 22	0.48
Platelets (×10 <sup>9</sup> per litre)	241 ± 79	211 ± 70	252 ± 79	0.03
Creatinine (μmol/L)	93 ± 29	100 ± 20	91 ± 31	0.23
BNP (ng/L)	5197 ± 6038	6105 ± 4714	4663 ± 6777	0.56

Continuous variables expressed as mean ± standard deviation, categorical variables as number and percentages in parentheses. DOAC, direct acting oral anticoagulant; BNP, brain natriuretic peptide; LVEF, left ventricular ejection fraction; LVIDd, left ventricular internal diameter in diastole; MR, mitral regurgitation; RWMA, regional wall motion abnormality; VKA, vitamin K antagonist.

**Table 3** Outcomes in patients with LV thrombus

Outcome	All patients (n = 84)	DOAC (n = 22)	VKA (n = 62)	P-value
Stroke	1 (1)	0 (0)	1 (2)	0.55
Other systemic emboli	1 (1)	0 (0)	1 (2)	0.55
Gastrointestinal bleeding	3 (4)	0 (0)	3 (5)	0.29
Intracranial bleeding	0 (0)	0 (0)	0 (0)	—
Other bleeding	3 (4)	0 (0)	3 (5)	0.29
Internal to repeat imaging	233 ± 251	244 ± 245	230 ± 255	0.83
Resolution of thrombus	55 (73)	13 (65)	42 (76)	0.33
Hospitalization (all)	41 (49)	10 (45)	31 (50)	0.53
Hospitalization (cardiac)	16 (19)	7 (32)	9 (15)	0.08
Hospitalization (non-cardiac)	34 (40)	6 (27)	28 (45)	0.14
All-cause mortality	9 (11)	3 (14)	6 (10)	0.61

Continuous variables expressed as mean ± standard deviation, categorical variables are presented as numbers and percentages in parentheses.

anticoagulation were longer than is recommended. Overall, 89% underwent repeat imaging, with resolution of thrombus in 73%. However, follow-up imaging modality was the same as that undertaken at baseline in only 45% of cases, and the lower use of CMR at follow-up might have overestimated the rate of thrombus resolution.<sup>3</sup>

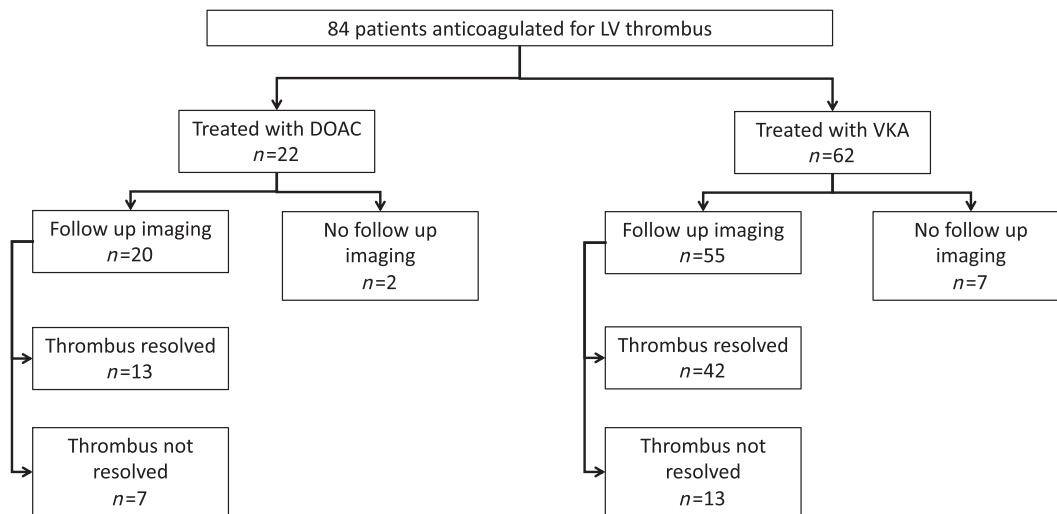
### Screening of high-risk individuals

Most patients in our cohort were identified incidentally on routine imaging. Screening for individuals with anterior STEMI with apical wall akinesis has been suggested.<sup>4</sup> On balance, CMR or contrast TTE would be the imaging of choice due to their greater sensitivity than standard TTE for the detection of LV thrombus.<sup>3</sup> However, given the proposed relationship between thromboembolic risk and thrombus burden, it is

not known whether the risk of thromboembolism from thrombi too small to be seen on TTE outweighs the risk of bleeding. This is especially true in those patients who undergo PCI for anterior STEMI who will usually require longer-term antiplatelet agents alongside anticoagulation.

In our analysis, we identified six patients whose initial presentation was a stroke. Three of these patients had a history of previous anterior STEMI, of whom two had undergone TTE showing no evidence of LV thrombus. In the other STEMI patient, LV thrombus had been correctly diagnosed, but subsequent resolution on CMR led to a decision to stop anticoagulation, and they subsequently developed a stroke, and a second LV thrombus was diagnosed at this time. For the three patients without a clear history of STEMI, two had evidence of previous (silent) anterior infarction on CMR and one was found to have previously undiagnosed DCM.

**Figure 2** Flow chart to show repeat imaging and rates of thrombus resolution in patients treated with VKA compared to DOAC. The majority of patients had some form of follow-up imaging, and there was resolution of thrombus in the majority of cases.



### Direct oral anticoagulant for the prevention of stroke in non-valvular atrial fibrillation

Landmark clinical trials assessing DOAC compared to VKA for the management of non-valvular AF have demonstrated overall greater safety and at least similar efficacy at reducing rates of thromboembolism.<sup>15–18</sup> Real world studies have confirmed these findings; in a large registry study, the rates of bleeding were significantly lower (hazard ratio: 0.89; 95% confidence interval: 0.68–0.92) despite a time-in-therapeutic range of around 70%, higher than in most clinical trials.<sup>19</sup> There are also data to support the use of DOAC to prevent thromboembolism in those with left atrial thrombus.<sup>20,21</sup>

### Anticoagulation for the prevention of vascular events in heart failure

Patients with heart failure and reduced ejection fraction (HFrEF) are at greater risk of thromboembolism in sinus rhythm and atrial fibrillation, and although VKA reduce this risk, the benefits are outweighed by bleeding rates.<sup>22–25</sup> Despite their increased safety, in severe HFrEF, the risk of bleeding with DOAC combined with the competing risks of death from heart failure means there is no clinical benefit.<sup>26</sup> However, in stable heart failure and vascular disease, there is a net clinical benefit from low dose DOAC.<sup>27</sup> On the whole, if the thromboembolic rate is less than 3%, then formal anticoagulation is of questionable benefit.<sup>22</sup> In this study, the rate of reimaging was low, with ongoing anticoagulation likely providing little benefit in the absence of another indication.

### Direct oral anticoagulant prescribed alongside dual antiplatelet therapy

For patients with LV thrombus as a consequence of STEMI, most will require the co-administration of two antiplatelet agents. In this study, 65% were co-administered an antiplatelet agent, and 38% were receiving DAPT. Whilst there is little evidence to guide the use of triple therapy for LV thrombus, DAPT is commonly co-administered in those undergoing PCI who also have non-valvular AF.<sup>28</sup> Data from clinical trials<sup>29–31</sup> and observational studies<sup>32,33</sup> have shown improved safety when using DOAC compared to VKA, with lower rates of bleeding. In our study, three (50%) of those with significant bleeding were receiving DAPT; overall, the bleeding rate was low and not significantly different between groups.

### Direct oral anticoagulant for the treatment of left ventricular thrombus

There are few data supporting the use of DOAC for LV thrombus, yet the increased safety and efficacy of these agents in other settings especially where the thromboembolic risk is around 3% or greater make their use for thromboprophylaxis in these high-risk patients a logical consideration. A single-centre retrospective study including 49 patients with LV thrombus due to anterior ST-elevation myocardial infarction found no significant difference in rates of thromboembolism, major bleeding, or thrombus resolution between VKA and DOACs concluding that DOAC appeared to be safe for such patients.<sup>34</sup> In another retrospective analysis of 98 patients with LV thrombus, 36% of which were treated with

DOAC; there were no differences in rates of stroke or systemic embolization, but this study did not report rates of bleeding or thrombus resolution.<sup>35</sup> Meta-summaries of case reports of patients with LV thrombus receiving non-vitamin K antagonists with varying numbers of patients (12–41) reported similar findings. One reported no embolic events and one episode of non-fatal bleeding event, whilst two others reported one episode of stroke and one episode of non-fatal bleeding.<sup>9,36,37</sup>

Our data are broadly in line with these studies. For the 22 patients receiving DOAC, there were no differences in efficacy and no adverse safety signal associated in this setting. During the study period, there were two episodes of stroke, one episode occurred during a period of anticoagulation with VKA. This patient developed a left middle cerebral artery embolus, having been commenced on VKA 6 days previously following an incidental finding of LV thrombus on CMR. At the time of stroke, the dosage of VKA was not therapeutic, with an international normalized ratio of 1.6. It is possible that DOACs might provide additional protection immediately after initiation compared to VKA whose onset time is longer; however, in this case, LMWH was co-administered during this time. A second patient, initially treated with VKA, had resolution of thrombus on CMR performed at 95 days after anticoagulation was ceased. This patient subsequently developed a stroke 139 days after stopping anticoagulation and a second LV thrombus was diagnosed at this time.

## Limitations

This study is limited by its retrospective, non-randomized approach, small sample size, and single centre setting, and our data should be considered in light of these features. Patients were allocated to receive DOAC or VKA based on patient preference following discussion with their physician, and although groups were similar at baseline, it is feasible that non-random allocation resulted in unmeasured differences between groups.

Whilst all patients presenting with a myocardial infarction at our centre undergo routine screening with TTE, not all undergo CMR screening for this complication. Those patients diagnosed with LV thrombus on CMR imaging underwent the scan as part of their routine care or to confirm the presence of LV thrombus suspected on TTE. It is well recognized that CMR is a more sensitive test for LV thrombus and that TTE will have missed smaller thrombi. Furthermore, imaging performed soon after STEMI might have preceded the development of LV thrombus. Nevertheless, we feel that our data represent the results of a cohort that represents standard clinical care.

Repeat imaging was performed at the discretion of the treating cardiologist, and the lack of a standardized approach is an additional limitation which may have influenced the rate

of thrombus resolution. Furthermore, the time to repeat imaging was longer than is recommended to assess for thrombus resolution. However, although we report thrombus resolution, our primary outcomes were clinical event rates.

The lack of experience with the use of DOAC in patients with reduced renal function or high body mass may limit the generalizability of these findings for such patients in whom VKA with a measurable effect might be the preferred therapy. Finally, in those with non-ischaemic cardiomyopathies, whose natural history does not include an acute trigger, it may be difficult to comment on the resolution of thrombus or optimal duration of anticoagulation.

## Conclusions

Our data suggest that DOACs are likely to be at least as effective and safe as VKA for stroke prevention in patients with LV thrombus and, despite their lack of a licence for this indication, are therefore likely to represent a reasonable and more convenient option for this setting. The optimal timing and type of anticoagulation, as well as the role of screening for patients at elevated risk of LV thrombus, should be explored in prospective, randomized trials.

## Acknowledgements

No specific funding was used for the completion of this project. S. S. is supported by an unconditional research grant from Medtronic to the University of Leeds for a PhD fellowship program. The research took place at the Leeds General Infirmary and the National Institute for Health Research Leeds Cardiovascular Research Facility at Leeds Teaching Hospitals NHS Trust.

## Conflict of interest

None declared.

## Author Contribution

H. I., T. C., and K. K. W. researched the topic and devised the study. S. W., K. S., and K. K. W. conceived, wrote, and implanted guidance for anticoagulation therapy, including DOAC for LV thrombus at LHT. H. I. and S. S. collected data and undertook statistical analysis. S. S. and K. K. W. produced the first draft of the manuscript. All other co-authors contributed equally to manuscript preparation.



## References

- Rehan A, Kanwar M, Rosman H, Ahmed S, Ali A, Gardin J, Cohen G. Incidence of post myocardial infarction left ventricular thrombus formation in the era of primary percutaneous intervention and glycoprotein IIb/IIIa inhibitors. A prospective observational study. *Cardiovasc Ultrasound* 2006; **4**: 20.
- Gianstefani S, Douiri A, Delithanasis I, Rogers T, Sen A, Kalra S, Charangwa L, Reiken J, Monaghan M, MacCarthy P. Incidence and predictors of early left ventricular thrombus after ST-elevation myocardial infarction in the contemporary era of primary percutaneous coronary intervention. *Am J Cardiol* 2014; **113**: 1111–1116.
- Weinsaft JW, Kim J, Medicherla CB, Ma CL, Codella NC, Kukar N, Alaref S, Kim RJ, Devereux RB. Echocardiographic algorithm for post-myocardial infarction LV thrombus: a gatekeeper for thrombus evaluation by delayed enhancement CMR. *JACC Cardiovasc Imaging* 2016; **9**: 505–515.
- Bulluck H, Chan MHH, Paradies V, Yellon RL, Ho HH, Chan MY, Chin CWL, Tan JW, Hausenloy DJ. Incidence and predictors of left ventricular thrombus by cardiovascular magnetic resonance in acute ST-segment elevation myocardial infarction treated by primary percutaneous coronary intervention: a meta-analysis. *J Cardiovasc Magn Reson* 2018; **20**: 72.
- Habash F, Vallurupalli S. Challenges in management of left ventricular thrombus. *Ther Adv Cardiovasc Dis* 2017; **11**: 203–213.
- Stratton JR, Resnick AD. Increased embolic risk in patients with left ventricular thrombi. *Circulation* 1987; **75**: 1004–1011.
- Vaitkus PT, Barnathan ES. Embolic potential, prevention and management of mural thrombus complicating anterior myocardial infarction: a meta-analysis. *J Am Coll Cardiol* 1993; **22**: 1004–1009.
- Ibanez B, James S, Agewall S, Antunes MJ, Bucciarelli-Ducci C, Bueno H, Caforio ALP, Crea F, Goudevenos JA, Halvorsen S, Hindricks G, Kastrati A, Lenzen MJ, Prescott E, Roffi M, Valgimigli M, Varenhorst C, Vranckx P, Widimský P, ESC Scientific Document Group. 2017 ESC Guidelines for the management of acute myocardial infarction in patients presenting with ST-segment elevation: the task force for the management of acute myocardial infarction in patients presenting with ST-segment elevation of the European Society of Cardiology (ESC). *Eur Heart J* 2018; **39**: 119–177.
- Leow AS, Sia CH, Tan BY, Loh JP. A meta-summary of case reports of non-vitamin K antagonist oral anticoagulant use in patients with left ventricular thrombus. *J Thromb Thrombolysis* 2018; **46**: 68–73.
- von Elm E, Altman DG, Egger M, Pocock SJ, Gøtzsche PC, Vandenbroucke JP, STROBE Initiative. Strengthening the reporting of observational studies in epidemiology (STROBE) statement: guidelines for reporting observational studies. *BMJ* 2007; **335**: 806–808.
- Visser CA, Kan G, Meltzer RS, Dunning AJ, Roelandt J. Embolic potential of left ventricular thrombus after myocardial infarction: a two-dimensional echocardiographic study of 119 patients. *J Am Coll Cardiol* 1985; **5**: 1276–1280.
- Keren A, Goldberg S, Gottlieb S, Klein J, Schuger C, Medina A, Tzivoni D, Stern S. Natural history of left ventricular thrombi: their appearance and resolution in the posthospitalization period of acute myocardial infarction. *J Am Coll Cardiol* 1990; **15**: 790–800.
- Meltzer RS, Visser CA, Fuster V. Intracardiac thrombi and systemic embolization. *Ann Intern Med* 1986; **104**: 689–698.
- Weinreich DJ, Burke JF, Pauletto FJ. Left ventricular mural thrombi complicating acute myocardial infarction. Long-term follow-up with serial echocardiography. *Ann Intern Med* 1984; **100**: 789–794.
- Patel MR, Mahaffey KW, Garg J, Pan G, Singer DE, Hacke W, Breithardt G, Halperin JL, Hankey GJ, Piccini JP, Becker RC, Nessel CC, Paolini JF, Berkowitz SD, Fox KA, Califf RM, ROCKET AF Investigators. Rivaroxaban versus warfarin in nonvalvular atrial fibrillation. *N Engl J Med* 2011; **365**: 883–891.
- Giugliano RP, Ruff CT, Braunwald E, Murphy SA, Wiviott SD, Halperin JL, Waldo AL, Ezekowitz MD, Weitz JI, Špinar J, Ruzyllo W, Ruda M, Koretsune Y, Betcher J, Shi M, Grip LT, Patel SP, Patel I, Hanyok JJ, Mercuri M, Antman EM, ENGAGE AF-TIMI 48 Investigators. Edoxaban versus warfarin in patients with atrial fibrillation. *N Engl J Med* 2013; **369**: 2093–2104.
- Connolly SJ, Ezekowitz MD, Yusuf S, Eikelboom J, Oldgren J, Parekh A, Pogue J, Reilly PA, Themeles E, Varrone J, Wang S, Alings M, Xavier D, Zhu J, Diaz R, Lewis BS, Darius H, Diener HC, Joyner CD, Wallentin L, RE-LY Steering Committee and Investigators. Dabigatran versus warfarin in patients with atrial fibrillation. *N Engl J Med* 2009; **361**: 1139–1151.
- Granger CB, Alexander JH, McMurray J, Lopes RD, Hylek EM, Hanna M, al-Khalidi HR, Ansell J, Atar D, Avezum A, Bahit MC, Diaz R, Easton JD, Ezekowitz JA, Flaker G, Garcia D, Geraldes M, Gersh BJ, Golitsyn S, Goto S, Hermosillo AG, Hohnloser SH, Horowitz J, Mohan P, Jansky P, Lewis BS, Lopez-Sendon JL, Pais P, Parkhomenko A, Verheugt FW, Zhu J, Wallentin L, ARISTOTLE Committees and Investigators. Apixaban versus warfarin in patients with atrial fibrillation. *N Engl J Med* 2011; **365**: 981–992.
- Sjogren V, Byström B, Renlund H, Svensson PJ, Oldgren J, Norrving B, Själander A. Non-vitamin K oral anticoagulants are non-inferior for stroke prevention but cause fewer major bleedings than well-managed warfarin: a retrospective register study. *PLoS ONE* 2017; **12**: e0181000.
- Lip GY, Hammerstingl C, Marin F, Cappato R, Meng IL, Kirsch B, van Eickels M, Cohen A, X-TRA study and CLOT-AF registry investigators. Left atrial thrombus resolution in atrial fibrillation or flutter: results of a prospective study with rivaroxaban (X-TRA) and a retrospective observational registry providing baseline data (CLOT-AF). *Am Heart J* 2016; **178**: 126–134.
- Fleddermann A, Eckert R, Muskala P, Hayes C, Magalski A, Main ML. Efficacy of direct acting oral anticoagulant drugs in treatment of left atrial appendage thrombus in patients with atrial fibrillation. *Am J Cardiol* 2019; **123**: 57–62.
- Witte KK, Jamil HA. Thromboprophylaxis in heart failure patients with sinus rhythm: aspirin and warfarin lead to similar cardiovascular outcomes. *Evid Based Med* 2013; **18**: 69–70.
- Homma S, Thompson JL, Pullicino PM, Levin B, Freudenberg RS, Teerlink JR, Ammon SE, Graham S, Sacco RL, Mann DL, Mohr JP, Massie BM, Labovitz AJ, Anker SD, Lok DJ, Ponikowski P, Estol CJ, Lip GY, di Tullio MR, Sanford AR, Mejia V, Gabriel AP, del Valle M, Buchsbaum R, WARCEF Investigators. Warfarin and aspirin in patients with heart failure and sinus rhythm. *N Engl J Med* 2012; **366**: 1859–1869.
- Massie BM, Collins JF, Ammon SE, Armstrong PW, Cleland JG, Ezekowitz M, Jafri SM, Krol WF, O'Connor CM, Schulman KA, Teo K, Warren SR, WATCH Trial Investigators. Randomized trial of warfarin, aspirin, and clopidogrel in patients with chronic heart failure: the warfarin and antiplatelet therapy in chronic heart failure (WATCH) trial. *Circulation* 2009; **119**: 1616–1624.
- Cleland JG, Daubert JC, Erdmann E, Freemantle N, Gras D, Kappenberger L, Tavazzi L, Cardiac Resynchronization-Heart Failure (CARE-HF) Study Investigators. The effect of cardiac resynchronization on morbidity and mortality in heart failure. *N Engl J Med* 2005; **352**: 1539–1549.

26. Zannad F, Anker SD, Byra WM, Cleland JGF, Fu M, Gheorghide M, Lam CSP, Mehra MR, Neaton JD, Nessel CC, Spiro TE, van Veldhuisen D, Greenberg B, COMMANDER HF Investigators. Rivaroxaban in patients with heart failure, sinus rhythm, and coronary disease. *N Engl J Med* 2018; **379**: 1332–1342.
27. Eikelboom JW, Connolly SJ, Bosch J, Dagenais GR, Hart RG, Shestakovska O, Diaz R, Alings M, Lonn EM, Anand SS, Widimsky P, Hori M, Avezum A, Piegas LS, Branch KRH, Probstfield J, Bhatt DL, Zhu J, Liang Y, Maggioni AP, Lopez-Jaramillo P, O'Donnell M, Kakkar AK, Fox KAA, Parkhomenko AN, Ertl G, Störk S, Keltai M, Ryden L, Pogosova N, Dans AL, Lanas F, Commerford PJ, Torp-Pedersen C, Guzik TJ, Verhamme PB, Vinereanu D, Kim JH, Tonkin AM, Lewis BS, Felix C, Yusuf K, Steg PG, Metsarinne KP, Cook Bruns N, Misselwitz F, Chen E, Leong D, Yusuf S, COMPASS Investigators. Rivaroxaban with or without aspirin in stable cardiovascular disease. *N Engl J Med* 2017; **377**: 1319–1330.
28. Gibson CM, Mehran R, Bode C, Halperin J, Verheugt FW, Wildgoose P, Birmingham M, Ianus J, Burton P, van Eickels M, Korjian S, Daaboul Y, Lip GY, Cohen M, Husted S, Peterson ED, Fox KA. Prevention of bleeding in patients with atrial fibrillation undergoing PCI. *N Engl J Med* 2016; **375**: 2423–2434.
29. Lopes RD, Heizer G, Aronson R, Vora AN, Massaro T, Mehran R, Goodman SG, Windecker S, Darius H, Li J, Averkov O, Bahit MC, Berwanger O, Budaj A, Hijazi Z, Parkhomenko A, Sinnaeve P, Storey RF, Thiele H, Vinereanu D, Granger CB, Alexander JH, AUGUSTUS Investigators. Antithrombotic therapy after acute coronary syndrome or PCI in atrial fibrillation. *N Engl J Med* 2019; **380**: 1509–1524.
30. Cannon CP, Bhatt DL, Oldgren J, Lip GYH, Ellis SG, Kimura T, Maeng M, Merkely B, Zeymer U, Gropper S, Nordaby M, Kleine E, Harper R, Manassie J, Januzzi JL, ten Berg J, Steg PG, Hohnloser SH, RE-DUAL PCI Steering Committee and Investigators. Dual antithrombotic therapy with dabigatran after PCI in atrial fibrillation. *N Engl J Med* 2017; **377**: 1513–1524.
31. Vranckx P, Valgimigli M, Eckardt L, Tijssen J, Lewalter T, Gargiulo G, Batushkin V, Campo G, Lysak Z, Vakaliuk I, Milewski K, Laeis P, Reimitz PE, Smolnik R, Zierhut W, Goette A. Edoxaban-based versus vitamin K antagonist-based antithrombotic regimen after successful coronary stenting in patients with atrial fibrillation (EN-TRUST-AF PCI): a randomised, open-label, phase 3b trial. *Lancet* 2019; **394**: 1335–1343.
32. Amin R, McWilliams N, Lee D, Altaf F, Virani F, Dickinson K, Walker D, Sharp A, Gerber R. 36 Triple therapy anticoagulation following percutaneous coronary intervention (PCI) with novel oral anticoagulants (NOAC) is safe and has no adverse effects on bleeding post procedure when compared to triple therapy with vitamin K antagonist (VKA). *Heart* 2016; **102**: A25–A26.
33. Sindet-Pedersen C, Lamberts M, Staerk L, Nissen Bonde A, Berger JS, Pallisgaard JL, Lock Hansen M, Torp-Pedersen C, Gislason GH, Olesen JB. Combining oral anticoagulants with platelet inhibitors in patients with atrial fibrillation and coronary disease. *J Am Coll Cardiol* 2018; **72**: 1790–1800.
34. Jaidka A, Zhu T, Lavi S, Johri A. Treatment of left ventricular thrombus using warfarin versus direct oral anticoagulants following anterior myocardial infarction. *Can J Cardiol* 2018; **34**: S143.
35. Robinson A, Ruth B, Dent J. Direct oral anticoagulants compared to warfarin for left ventricular thrombi: a single center experience. *J Am Coll Cardiol* 2018; **71**: A981.
36. Turgay Yildirim O, Akşit E, Aydin F, Hüseyinoğlu Aydin A. Efficacy of direct oral anticoagulants on left ventricular thrombus. *Blood Coagul Fibrinolysis* 2019; **30**: 96–103.
37. Kaji M, Shokr M, Ramappa P. Use of direct oral anticoagulants in the treatment of left ventricular thrombus: systematic review of current literature. *Am J Ther* 2019: 1.