

CASE REPORT

Ancient schwannoma in the sublingual space masquerading as a plunging ranula

Nimisha Vallabh^{1,*}, Venkat Srinivasan¹, David Hughes², and David Agbamu³

¹Ear, Nose and Throat Department, Wirral Teaching Hospitals NHS Trust, Arrowe Park Hospital, Wirral CH49 5PE, UK, ²Radiology Department, Wirral Teaching Hospitals NHS Trust, Arrowe Park Hospital, Wirral CH49 5PE, UK, and ³Histopathology Department, Wirral Teaching Hospitals NHS Trust, Arrowe Park Hospital, Wirral CH49 5PE, UK

*Correspondence address. Ear, Nose and Throat Department, Wirral University Teaching Hospitals Trust, Arrowe Park Hospital, Arrowe Park Road, Upton, Wirral, Merseyside CH49 5PE, UK. Tel: 07976205669; Fax: 0151 604 8070; E-mail: nimishavallabh@doctors.org.uk

Abstract

Ancient schwannomas are benign, slow-growing tumours derived from the neural sheath. They are characterized by degenerative changes which are not seen in the common schwannoma. An unusual case of ancient schwannoma of the sublingual space is reported to highlight the diagnostic challenge that this tumour presents. A 49-year-old male patient presented with an 8-month history of a right-sided neck swelling, palpable in the anterior part of the submandibular triangle. Pre-operative imaging showed a non-enhancing mass in the sublingual space spilling into the submandibular triangle, consistent with a plunging ranula. Fine needle aspiration cytology was inconclusive. However, histopathology of the lesion confirmed the diagnosis of an ancient schwannoma, which is seldom found in the sublingual space.

INTRODUCTION

Ancient schwannomas are benign, slow-growing tumours derived from the neural sheath. They were first described by Ackerman and Taylor in 1951 [1] and can occur in a variety of regions of the head and neck but rarely in the sublingual space [2]. Swellings of the anterior triangle of the neck are common; imaging and fine needle aspiration cytology (FNAC) are often used to aid diagnosis. However, schwannomas remain difficult to diagnose and can be mistaken for other more common conditions. As these tumours often arise from major nerves, surgical management can lead to significant lifelong morbidity. Therefore, pre-operative diagnosis is important to allow the patient to make a fully informed decision regarding management of the tumour.

CASE REPORT

A 49-year-old male patient presented with an 8-month history of a right-sided neck swelling. The patient reported an intermittent dull ache associated with the mass but denied any association with eating. The patient's medical history was unremarkable and he was a non-smoker. Clinical examination demonstrated a soft, 2 cm swelling palpable in the anterior part of the right submandibular triangle. There was no swelling seen or palpable in the floor of the mouth. The submandibular duct was clinically normal with no obvious calculi and examination of the neck was unremarkable.

Several investigations were requested to characterize the mass further. Mandibular occlusal views were normal, ruling out stones. The patient had a standard magnetic resonance

Received: February 26, 2017. Accepted: March 17, 2017

Published by Oxford University Press and JSCR Publishing Ltd. All rights reserved. © The Author 2017.

This is an Open Access article distributed under the terms of the Creative Commons Attribution Non-Commercial License (<http://creativecommons.org/licenses/by-nc/4.0/>), which permits non-commercial re-use, distribution, and reproduction in any medium, provided the original work is properly cited. For commercial re-use, please contact journals.permissions@oup.com

imaging (MRI) of neck with pre and post contrast images taken. There was a $2.8 \times 1.2 \times 1.5$ cm lobulated lesion in the right sublingual space, extending anterior to submandibular gland, medial and posterior to mylohyoid muscle and lateral to genioglossus muscle (Figs 1 and 2). It was immediately adjacent to Wharton's duct which was slightly displaced but not obstructed. It had intense T_2 signal, isointense to hypointense T_1 signal and showed no enhancement post contrast. Both submandibular glands were normal and there was no cervical lymphadenopathy. The radiological findings were consistent

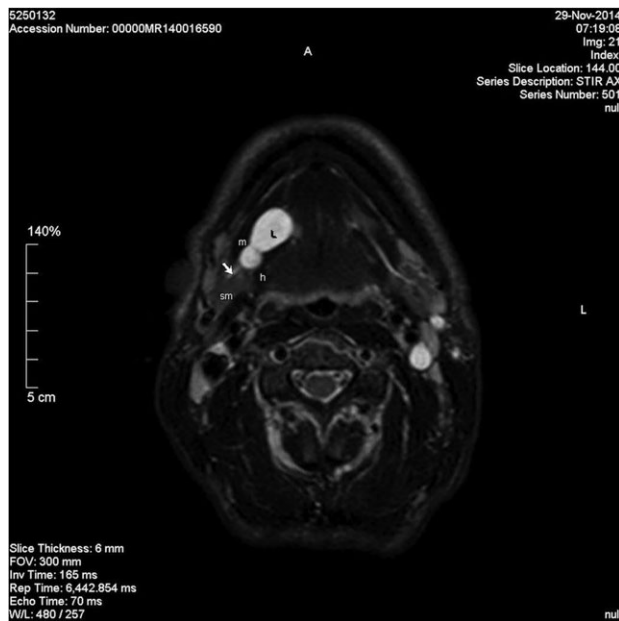


Figure 1: Axial STIR image showing a lobulated homogenous hyperintense lesion in the right floor of mouth. L, lesion; m, mylohyoid muscle; sm, submandibular gland; h, hyoglossus; short arrow, Wharton's duct.

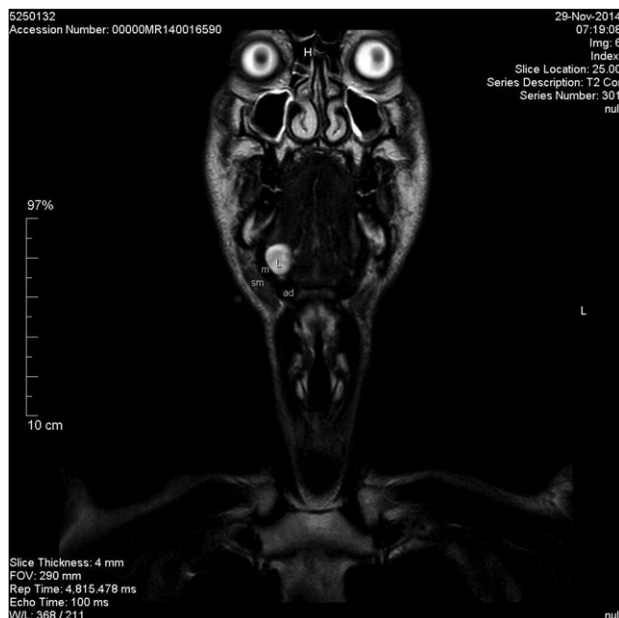

Figure 2: Coronal T_2 -weighted image. L, lesion; m, mylohyoid muscle; sm, submandibular gland; ad, anterior belly of digastric muscle.

with a plunging ranula. Fine needle aspiration yielded a few clusters of blood stained, cytologically bland epithelioid cells and no specific diagnosis could be made. Given the clinical features and results of the pre-operative investigations, the most likely diagnosis was a plunging ranula from the sublingual space, extending into the submandibular triangle.

The patient elected to have the mass removed under a general anaesthetic. A solid, bilobed swelling was found anterior to the right submandibular gland extending superiorly. It was completely excised with preservation of the submandibular gland and hypoglossal nerve. Histopathology of the excised mass showed a grey nodule with a glistening surface. The mass was well circumscribed with verocay bodies and degenerative nuclear atypia. The findings were diagnostic of an ancient schwannoma (Figs 3 and 4). The patient's recovery was complicated by the development of a haematoma which required a temporary tracheostomy and evacuation in theatre. The patient subsequently developed a right-sided hypoglossal nerve palsy. The patient's progress has been monitored in the outpatient department with no evidence of recurrence at 12 months.

DISCUSSION

Schwannomas are benign, slow-growing tumours of the neural sheath. They arise from Schwann cells which produce the myelin sheath covering of cranial, peripheral and autonomic nerves. It is reported that 25–45% of extracranial schwannomas are located in the head and neck regions [3], the most common site being the parapharyngeal space [2]. They are relatively rare and are often mistaken for metastatic disease or other

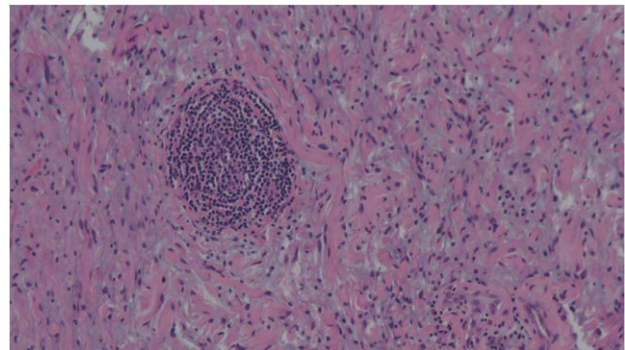


Figure 3: Spindle cells set in a myxoid stroma characteristic of schwannoma. Haematoxylin and eosin (H&E).

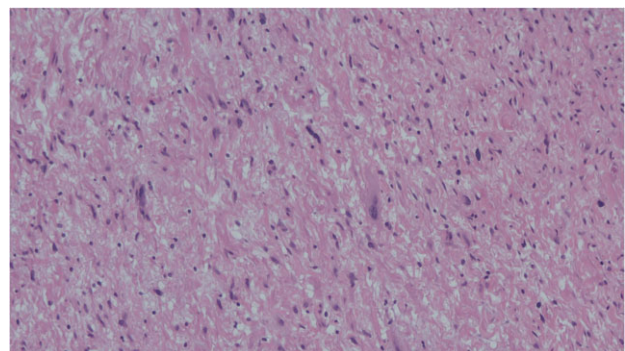


Figure 4: Cells with enlarged hyperchromatic nuclei seen in ancient schwannoma. Haematoxylin and eosin (H&E).

non-neurogenic tumours. Once a diagnosis has been made, management may consist of observation, complete surgical excision or intracapsular enucleation.

Schwannoma is difficult to diagnose clinically but, a long-standing history and a firm mass are suggestive [4]. Radiological diagnosis can also be challenging with sensitivity estimated at 20% for computed tomography (CT) and up to 80% for MRI [5]. Ultrasonography is often used in the investigation of neck lumps. However, the appearance of a schwannoma can mimic a pleomorphic adenoma. The literature does not support the use of CT for the diagnosis of schwannoma and MRI is often preferred for better soft tissue delineation. This may aid in diagnosis and identification of the nerve of origin. Schwannomas appear hypointense on T₁-weighted images and heterogeneously hyperintense on T₂-weighted images [4, 6]. They demonstrate intense enhancement with gadolinium-based contrast. As demonstrated in our case, MRI can still fail to be diagnostic.

FNAC remains a valuable tool to characterize neck masses but its accuracy in schwannoma is only reported to be 20–25% [4, 6]. Macroscopically, schwannomas are smooth and uniform and often attached to their nerve of origin which may help intra-operative diagnosis. Histologically, schwannomas are encapsulated and consist of alternating Antoni-A and Antoni-B regions [7]. Ancient schwannomas can be recognized by their additional degenerative features such as fibrosis, cystic necrosis and degenerative nuclei [7]. They can often be mistaken for malignant tumours due to nuclear atypia and hyperchromasia [7].

The differential diagnosis of a right-sided neck swelling is varied and includes: submandibular gland neoplasm, lymphadenopathy, plunging ranula, haemangioma and lipoma. A ranula is a retention cyst of the sublingual gland which usually occurs secondary to trauma or duct obstruction. It often presents as a bluish swelling in the floor of the mouth. The swelling can extend behind or through the mylohyoid muscle and into the submandibular space forming a plunging ranula [5]. A plunging ranula is usually associated with an intra-oral component but rarely it can present as an isolated neck swelling [5]. The pre-operative imaging of our patient demonstrated a homogenous, non-enhancing lesion involving the sublingual gland and extending into the submandibular space. The lesion did not show enhancement with contrast which is unusual for a schwannoma [8], and may be interpreted as being consistent with a cystic lesion. Both schwannomas and ranulas appear hypointense on T₁-weighted images and hyperintense on

T₂-weighted images. As FNAC was inconclusive, a differential diagnosis of several pathologies was considered based on clinical assessment and radiological investigations. Given the characteristic MRI appearances and the failure to enhance with contrast, a pre-operative diagnosis of plunging ranula was made.

ACKNOWLEDGEMENT

None.

CONFLICT OF INTEREST STATEMENT

None declared.

REFERENCES

1. Ackerman LV, Taylor FH. Neurogenous tumors within the thorax; a clinicopathological evaluation of forty-eight cases. *Cancer* 1951;4:669–91.
2. Kang GCW, Soo K-C, Lim DTH. Extracranial non-vestibular head and neck schwannomas: a ten-year experience. *Ann Acad Med Singapore* 2007;36:233–8.
3. Colreavy MP, Lacy PD, Hughes J, Bouchier-Hayes D, Brennan P, O'Dwyer AJ, et al. Head and neck schwannomas: a 10 year review. *J Laryngol Otol* 2000;114:119–24.
4. Liu H-L, Yu S-Y, Li GK-H, Wei WI. Extracranial head and neck Schwannomas: a study of the nerve of origin. *Eur Arch Otorhinolaryngol* 2011;268:1343–7.
5. Nilesh K, Malik NA, Patil P, Chapi MD. Large plunging ranula presenting as isolated neck swelling: steps in diagnosis and surgical steps in management. *J Clin Diagn Res JCDR* 2015;9:MD01–03.
6. Yasumatsu R, Nakashima T, Miyazaki R, Segawa Y, Komune S. Diagnosis and management of extracranial head and neck schwannomas: a review of 27 cases. *Int J Otolaryngol* 2013;2013: 973045.
7. Choudry HA, Nikfarjam M, Liang JJ, Kimchi ET, Conter R, Gusani NJ, et al. Diagnosis and management of retroperitoneal ancient schwannomas. *World J Surg Oncol* 2009;7:12.
8. Skolnik AD, Loevner LA, Sampathu DM, Newman JG, Lee JY, Bagley LJ, et al. Cranial nerve schwannomas: diagnostic imaging approach. *Radiogr Rev Publ Radiol Soc N Am Inc* 2016; 36:1463–77.