

Prevention and Treatment of Burn Scar Contracture: A Practical Review

Layne N. Raborn, MD*
Jeffrey E. Janis, MD, FACS†

Summary: Burn contracture affects close to one-third of all burn patients, leading to significant functional impairment and costs. Effective prevention and treatment strategies are necessary to decrease morbidity and unnecessary costs. This scoping review aimed to summarize prevention and treatment strategies used for management of burn scar contractures published in the literature since 2000. A comprehensive PubMed review was performed in October 2022 to identify methods of burn contracture prevention and treatments. Non-English, duplicate, and unavailable articles were excluded. Data were extracted including publication year, techniques, and outcomes. A total of 327 publications met criteria for inclusion. Most articles were published in 2011 (n = 22). Treatment strategies were discussed in 82.9% of studies, prevention in 16.5%, and both in 0.6%. The most common areas discussed included the upper extremity (n = 127) and neck (n = 102). Flaps were the most frequently used method (n = 208), followed by autografts (n = 89). Most preventative therapies were still in early stages of development. Burn contracture management requires a highly individualized approach with many available reconstructive techniques available. Further research is needed to improve prevention techniques and decrease morbidity and cost to patients. (*Plast Reconstr Surg Glob Open* 2024; 12:e5333; doi: [10.1097/GOX.0000000000005333](https://doi.org/10.1097/GOX.0000000000005333); Published online 19 January 2024.)

INTRODUCTION

Although modern medicine has led to increased survival following burn injury, burn contracture remains a major cause of subsequent morbidity, leading to functional deficits and cosmetic complaints. Contractures can greatly affect patients' quality of life, physical function, pain, and vitality.¹ The rate of contracture following a burn according to an analysis of the National Institute on Disability and Rehabilitation Research burn model system database has been reported to be as high as 33% at the time of hospital discharge.² As expected, a higher total body surface area burn is predictive of the number of contractures patients will develop.^{2,3} Thus, patients with a limited amount of healthy tissue available for reconstructive techniques are also more likely

to need major surgical corrections. The use of techniques which prevent the development of contracture and effectively use available tissue to correct contracture is crucial to improve patient outcomes and cost to the system.

This review sought to identify techniques used for prevention and correction of burn contractures published in the literature since 2000 and to effectively summarize these topics in a way that clinicians could easily reference when developing effective treatment strategies for burned patients.

METHODS

A review of the literature was performed in October 2022 according to guidelines.^{4,5} Peer-reviewed articles were identified by a single author (L.N.R.) using PubMed. The search terms for burn scar contracture were utilized to identify articles related to burn scar contractures (Table 1). Inclusion and exclusion criteria were set before the study, and articles that discussed prevention and treatment methods for burn scar

From the *Division of Plastic Surgery, University of Rochester Medical Center, Rochester, N.Y.; and †Department of Plastic and Reconstructive Surgery, Ohio State University, Wexner Medical Center Columbus, Ohio.

Received for publication August 16, 2023; accepted August 31, 2023.

Copyright © 2024 The Authors. Published by Wolters Kluwer Health, Inc. on behalf of The American Society of Plastic Surgeons. This is an open-access article distributed under the terms of the [Creative Commons Attribution-Non Commercial-No Derivatives License 4.0 \(CCBY-NC-ND\)](https://creativecommons.org/licenses/by-nc-nd/4.0/), where it is permissible to download and share the work provided it is properly cited. The work cannot be changed in any way or used commercially without permission from the journal.

DOI: [10.1097/GOX.0000000000005333](https://doi.org/10.1097/GOX.0000000000005333)

Disclosure statements are at the end of this article, following the correspondence information.

Related Digital Media are available in the full-text version of the article on www.PRSGlobalOpen.com.

Table 1. Search Terms Used in PubMed to Identify Articles Relevant to Burn Contracture and Number of Results

Term	Search Phrase	No. of Publications
Burn contractures	Search: burn scar contracture (“burns” [MeSH Terms] OR “burns” [All Fields] OR “burn” [All Fields]) AND (“cicatrix” [MeSH Terms] OR “cicatrix” [All Fields] OR “scar” [All Fields]) AND (“contractural” [All Fields] OR “contracture” [MeSH Terms] OR “contracture” [All Fields] OR “contractures” [All Fields] OR “contractured” [All Fields]) Translations burn: “burns” [MeSH Terms] OR “burns” [All Fields] OR “burn” [All Fields] scar: “cicatrix” [MeSH Terms] OR “cicatrix” [All Fields] OR “scar” [All Fields] contracture: “contractural” [All Fields] OR “contracture” [MeSH Terms] OR “contracture” [All Fields] OR “contractures” [All Fields] OR “contractured” [All Fields]	1244

Table 2. Inclusion and Exclusion Criteria for Articles Selected to Examine Burn Contractures

Inclusion criteria
Addresses, proposes, discusses, or exemplifies the prevention or management of burn contractures
Exclusion criteria
Not about burn contracture
Year before 2000
On demographics
On garments
Language not English
On metric or model
On outcomes
On patient positioning
Review article
Speech article
On splints or devices
On therapy management
On pathology
Abstract unavailable
Article unavailable
Duplicate article

contractures were included (Table 2). Qualitative articles were included to identify common themes, whereas reviews were excluded to limit repeated data. Data were manually extracted, as available, and stored using a standardized spreadsheet. The categories of extracted data are reported in Table 3.

Takeaways

Question: What is the evidence behind optimal burn scar contracture management?

Findings: Across 327 publications in our PubMed review of the literature, the majority of burn scar contractures were managed with flaps and grafts. The types and success rates varied by area of the body requiring reconstruction. Evidence on preventative techniques was sparse.

Meaning: Individual treatment plans of burn patients should be customized to the patient. Evidence-based management can lead to improved outcomes.

Table 3. Data Extracted from Included Publications

Year
Title
Journal
Author
Language
Techniques used
Preventative or treatment method
Area of body
Outcome of study

RESULTS

Selection of Studies

PubMed search yielded 1244 publications which were screened by title and abstract (Fig. 1). After initial screening, 378 articles were further screened with article review. Of these, 327 met inclusion and exclusion criteria and were included in the study. (See table, Supplemental Digital Content 1, which displays a full list of all publications included, <http://links.lww.com/PRSGO/C978>.)

Study Characteristics

An average of 14 articles were published a year between 2000 and 2022, with the highest number published in 2011 (n = 22, 6.7%) and the fewest published in 2001 (n = 5, 1.5%). (See table, Supplemental Digital Content 2, which displays the number of publications on burn scar contracture per year from 2000 to 2022, <http://links.lww.com/PRSGO/C979>.) Articles were primarily focused on treatment strategies (n = 271, 82.9%), followed by prevention strategies (n = 54, 16.5%), and two articles focused on both (0.6%) (Fig. 2).

Contracture of the Head and Neck

We identified 57 articles which discussed contractures of the head and 102 which discussed contractures of the neck (Fig. 3). (See table, Supplemental Digital Content 3, which displays a table summarizing articles which discussed preventative and reconstructive options for burn contractures of the head, <http://links.lww.com/PRSGO/C980>.) (See table, Supplemental Digital Content 4, which displays a table summarizing articles which discussed preventative and reconstructive options

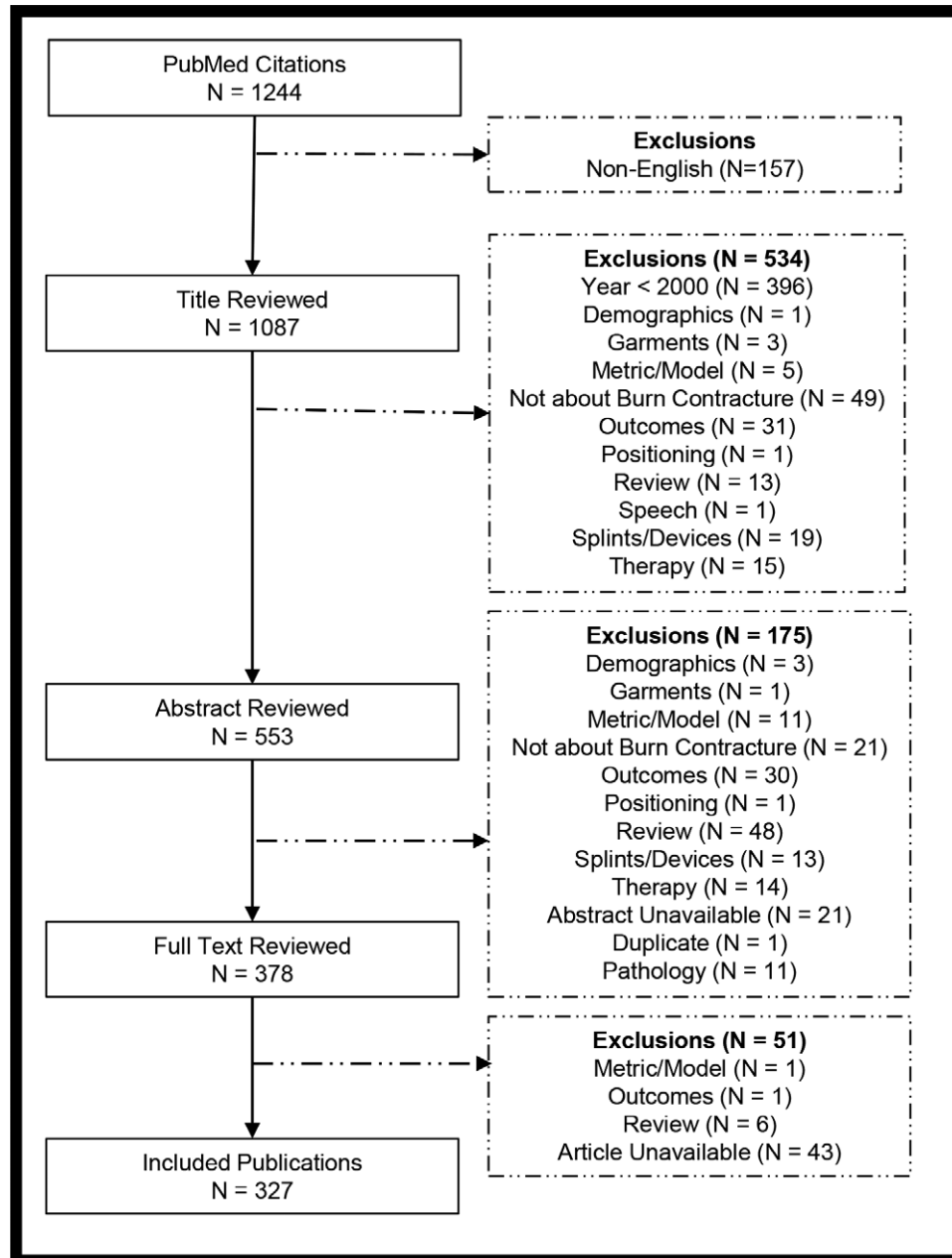


Fig. 1. PRISMA (Preferred Reporting Items for Systematic Reviews and Meta-Analyses) flowchart.

for burn contractures of the neck, <http://links.lww.com/PRSGO/C981>.) Contractures in this area lead to issues such as feeding difficulties, airway obstructions, visual deficits, poor cosmetic appearance, and psychosocial issues. Reconstructive options are specific to each of the areas affected and are outlined in detail in **Supplemental Digital Contents 3–4** (<http://links.lww.com/PRSGO/C980>; <http://links.lww.com/PRSGO/C981>). In general, flaps were most commonly used for reconstruction, which provided low rates of recurrent contracture while offering color match and functional improvement (Table 4). Neck contracture management sought to correct motion limitations, micrognathia, mandibular retrusion, and lip ectropion. Skin grafts were utilized in a few

articles, but the use of dermal regenerative templates as an intermediate step before grafting was encouraged to improve rates of recurrence. Flaps were overall preferred for better outcomes.⁶ Flap options for the neck are represented in Table 5. Two algorithmic approaches for choosing local tissue arrangements or flaps were published^{7,8}; local tissue was preferred for smaller contractures and flaps for mild to moderate size.^{7–11} Cervicoplasty,^{12,13} platysmaplasty,¹⁴ and platysmotomies¹⁵ were also performed during reconstructions. Specific surgical techniques such as the use of three rows of suture to restore the cervicomandibular angle¹⁶ and methods of graft fixation were discussed.¹⁷ Overall, the complexity of head and neck burn reconstruction is owed to its functional and

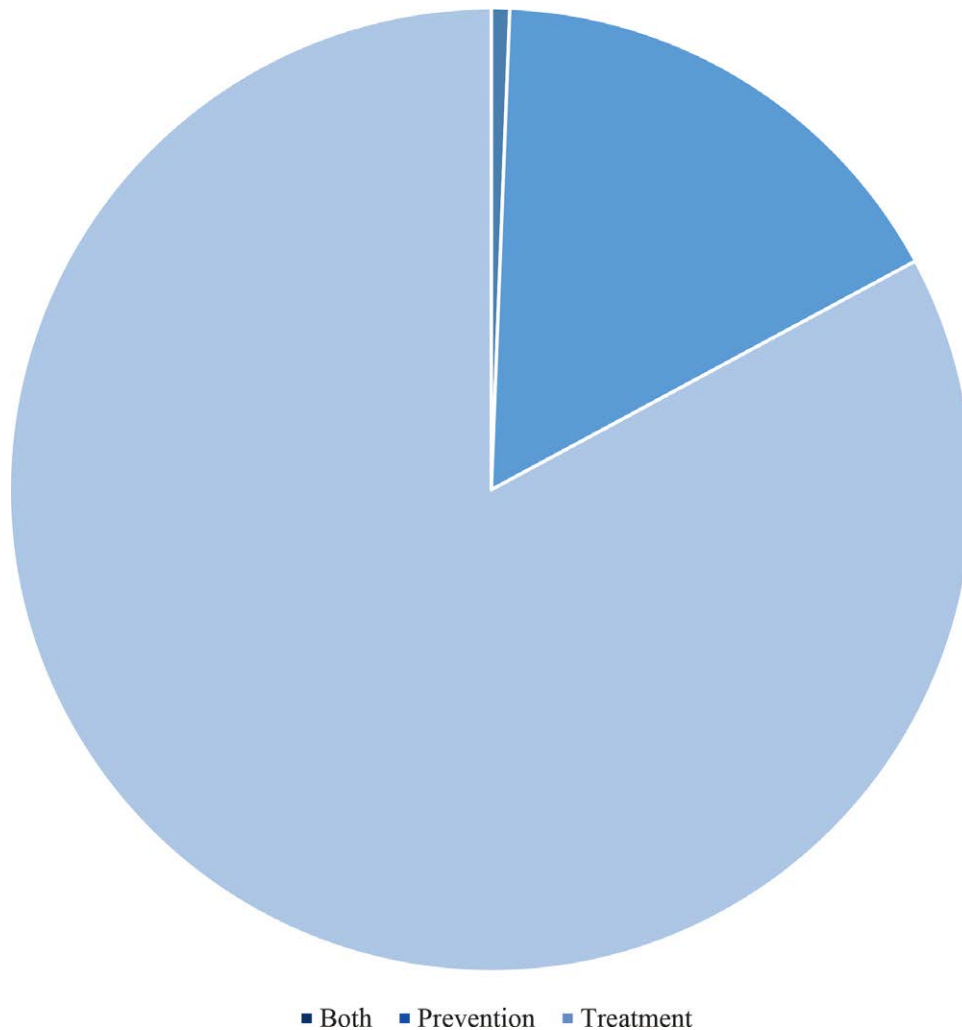


Fig. 2. Number of publications focused on burn contracture prevention (n = 54, 16.5%), treatment (n = 271, 82.9%), and those that focused on both (n = 2, 0.6%).

aesthetic demands, and thus, the scope of discussion in the literature was wide.

Contracture of the Upper Extremity

There were 127 articles which discussed burn contracture reconstruction of the upper extremities, including the shoulder and axilla, elbow, wrist, and hand. (See table, **Supplemental Digital Content 5**, which displays a table summarizing articles which discussed preventative and reconstructive options for burn contractures of the upper extremity, <http://links.lww.com/PRSGO/C982>.) Upper extremity burn contractures hinder patients' normal daily activities and ability to care for themselves; thus, reconstructive options aimed to improve range of motion and function, maintain circulation, and obtain wound closure.¹⁸ For the axilla, two guidelines specific for the area and contracture degree have been published.^{19,20} Karki et al recommended variations of Z-plasties and advancement flaps for mild to moderate contractures and for severe contractures, either a parascapular flap/scapular flap or skin grafting if surrounding tissue was involved.¹⁹ Asuku et al recommended local flaps

for contracture involving either anterior or posterior axillary fold (type I), and the use of skin grafts and fasciocutaneous flaps for contractures either involving both anterior and posterior axillary fold but sparing axillary dome (type II) or also involving axillary dome/pan-axillary (type III).²⁰ For the elbow, flaps were compared with grafts and shown to be the superior option, largely due to the mobility required at this area and risk for recurrent contracture with grafts.²¹ If grafting was used in the upper extremity, full-thickness skin grafts were preferred,²²⁻²⁴ but dermal regeneration templates and substitutes showed comparable results in terms of decreasing recurrent contracture rates when used as intermediate steps before grafting.²⁵⁻³⁴ Additional techniques used to improve contracture appearance included the use of fat grafting for hand reconstruction,^{35,36} tumescence to improve the surgeon's visual field in initial burn debridements,³⁷ and the use of basic-fibroblast growth factor^{38,39} or silicone.⁴⁰

Management of Lower Extremity Contractures

There were 43 articles that discussed management of lower extremity contractures, including the foot and

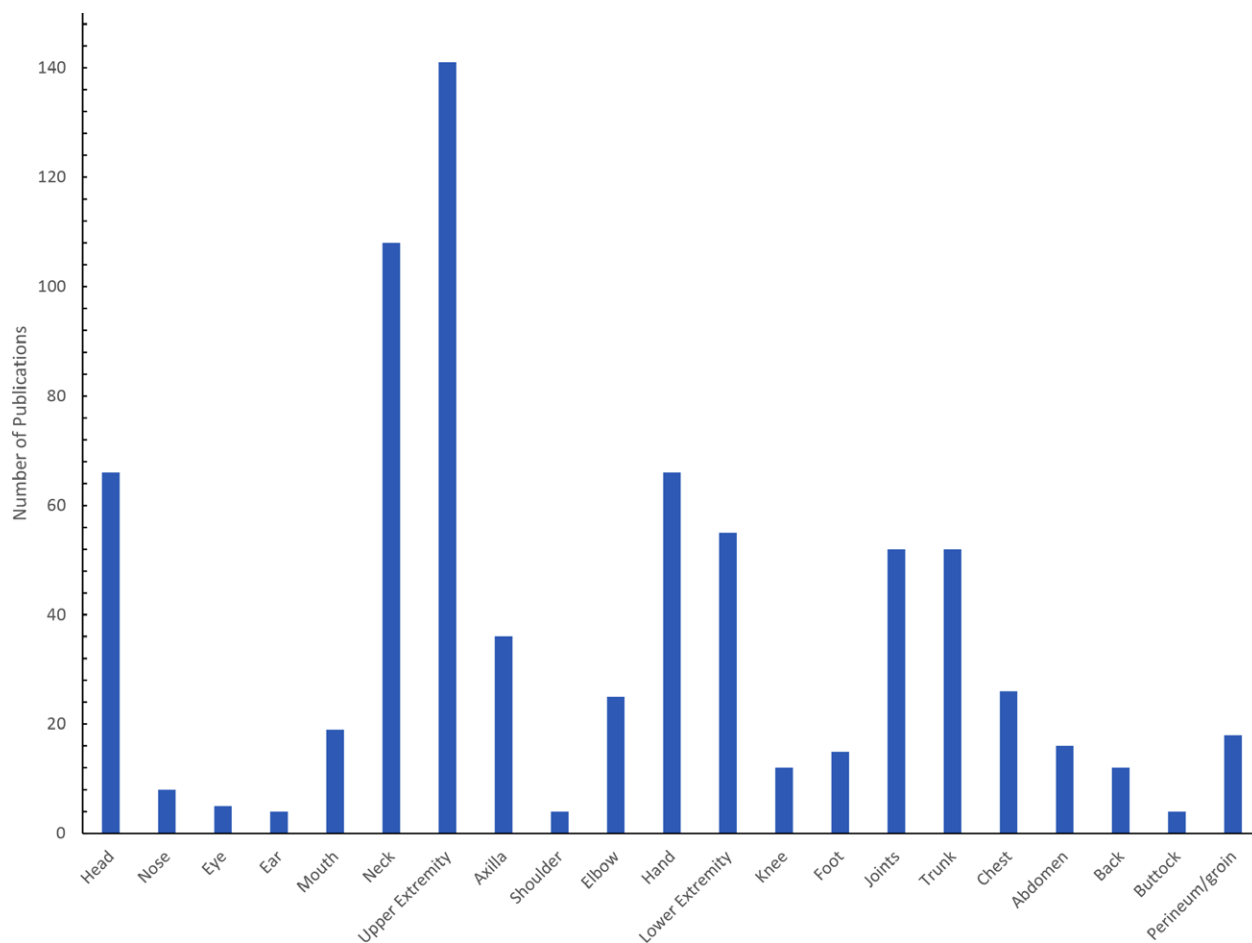


Fig. 3. Number of publications focused on each anatomic area, with the highest number focusing on the upper extremity ($n = 127$) and neck ($n = 102$).

ankle which can prevent successful ambulation if not addressed. (See table, **Supplemental Digital Content 6**, which displays a table summarizing articles which discussed preventative and reconstructive options for burn contractures of the lower extremity, <http://links.lww.com/PRSGO/C983>.) Grishkevich offered an algorithmic approach to the ankle based on the location of the contracture, recommending trapeze-flap plasty for the edge and medial contractures, and skin grafting for circumferential contractures.⁴¹ Equinus contracture was addressed with Achilles lengthening and multiple Z-plasties.⁴² Split-thickness skin grafts were used for feet, and a study on timing showed they could be done in unison with no change in outcomes.⁴³ Fat grafting was used to improve contracture of tendons.³⁶ Knee reconstruction included the successful use of flaps such as popliteal keystone island, free latissimus, and anterolateral thigh (ALT) flaps, as well as the use of allografting, and dermal regeneration templates.

Management of Joint Contractures

Particular attention was paid to mitigating the risk of recurrent burn contracture in areas that involved joints. Because of the high risk of functional issues with recurrent

contracture, flaps were preferred and showed better outcomes to skin grafts.⁴⁴ Grafts were sometimes combined with advancement flaps⁴⁵ or Alloderm (LifeCell Corp., Branchburg, N.J.).⁴⁶

Management of Trunk Contractures

Management of trunk contractures was discussed in 37 articles, which included the chest, abdomen, back, and buttock. (See table, **Supplemental Digital Content 7**, which displays a table summarizing articles which discussed preventative and reconstructive options for burn contractures of the trunk, <http://links.lww.com/PRSGO/C984>.) Chest contractures can be particularly devastating cosmetically for women and in some cases were shown to decrease lung capacity. For general coverage, flaps utilized included the dorsal scapular island, internal mammary artery perforator, ALT, superficial inferior epigastric artery, and deep inferior epigastric perforator flaps.⁴⁷ Recommendations to restore breast contour included skin grafting, preferably full-thickness, with mammoplasty.⁴⁸⁻⁵¹ Haik et al proposed using a reverse abdominoplasty if the inframammary fold was involved.⁵² Dermal regeneration templates were recommended if split-thickness skin grafting was considered.⁴⁸ Abdominal contractures can be particularly

Table 4. Flap Techniques for Head Reconstruction

Flaps	Publications, N	Additional Specified Modifications	Area Specifications
Deltpectoral flap	2		
Trapezius flap	4	Myocutaneous or fasciocutaneous, expanded	
Thoracodorsal artery perforator	1	Super-thin	
Thoracoacromial artery perforator	1	Expanded	
Supraclavicular island flap, transverse cervical artery flap, infraclavicular artery flap	3	Expanded	
Cervical artery flap	2	Occipitocervical, cervicopectoral, super-thin, supercharged	
Arterialized venous flap	2	Expanded, free	
Temporalis fascia/temporal flap	2	Free	
Scapular flap/parascapular	3	Expanded, free	
Lateral arm flap	2	Free	
Lateral forearm flap	6	Expanded, free	Various including lip
Tensor fascia lata flap	2	Free	
Forehead flap	4	Expanded, island, foreheadplasty	
Groin flap	1	Expanded, free	
Anterolateral thigh flap	4	Expanded, free	Various including mouth
Intercostal perforator flap	1		
Deep inferior epigastric perforator flap	2	Free	
Buccal mucosal flap	2	Advancement	For mouth
Submental artery flap	1		For aerodigestive tract
Jejunal flap	1	Free	For aerodigestive tract
Nasolabial flap	1		For mouth
Frontonasal flap	1		For nose and lip
Trapeze-flap	2		For nose and mouth
Rhomboid flap	3		
Z-plasty, multi-z-plasty	3		
V-Y flap	1		
Triangular flap	1		For ear
Expanded local flap	1		For lip
Unspecified	5	Super-thin, expanded, island perforator-based	

problematic for young childbearing women due to the lack of laxity⁵³; however, a modified abdominoplasty was proposed as a method for correction.^{52,54} An expanded ALT also provided effective coverage.⁵⁵ For contractures of the back, correction of kyphosis was the target goal and reconstruction usually incorporated flaps like expanded local flaps, ALT, or trapezius myocutaneous flap, in combination with thoracoplasty and Texas Scottish Rite Hospital spinal system.^{56–59}

Management of Perineum and Groin Contractures

Contractures of the perineum and groin, which can inhibit sexual function and voiding abilities, were discussed in 15 articles. (See table, Supplemental Digital Content 8, which displays a table summarizing articles which discussed preventative and reconstructive options for burn contractures of the perineum and groin, <http://links.lww.com/PRSGO/C985>.) Initial debridement with hydro-surgery showed improved scar results for penile burns.⁶⁰ Integra (Integra LifeScience Corporation, Plainsboro, N. J.) was also used for penile reconstruction.⁶¹ Scrotal burns can lead to cryptorchidism, and thus, orchidopexy, skin graft, and Z-plasty were utilized for correction.⁶² Flaps were often used for the perineum, including trapezoid, or pudendal thigh, groin, and thinned deep inferior epigastric perforator flaps.^{63–66}

Overview of Techniques

A variety of techniques were discussed for reconstruction of contractures and various preventative measures. (See table, Supplemental Digital Content 9, which displays a table summarizing articles which discussed novel preventative and reconstructive materials, <http://links.lww.com/PRSGO/C986>.) In the initial stages, adequate debridement using hydrosurgical debridement was shown to improve healing time and minimize contracture.^{60,67} Extracorporeal shock wave therapy also showed promising effects on scar pliability.⁶⁸ The use of honey dressings and moist exposed burn ointments over silver sulfadiazine demonstrated improved scar outcomes.^{69–71} The timing of reconstructive surgery had mixed results in terms of affecting the rate of burn contracture.^{72–75}

Lasers were utilized in 17 studies with overall good results. (See table, Supplemental Digital Content 10, which displays a table summarizing articles which discussed preventative and reconstructive options using laser therapy for burn contractures, <http://links.lww.com/PRSGO/C987>.) Guidelines for use of ablative fractional CO₂ lasers were reported to enhance successful incorporation into practice.⁷⁶ Various studies reported improvements of scar atrophy, contracture, texture, and color, as well as joint range of motion. The 400 mW 670 nm Softlaser also showed a small but present

Table 5. Flap Techniques for Neck Reconstruction

Technique	Publications, N	Additional Specified Modifications
Anterolateral thigh flap	9	Expanded, free, butterfly design
Scapular flap, parascapular flap, circumflex scapular flap	9	Expanded, island, free, bilobed
Transverse cervical artery flap, supraclavicular island flap, infraclavicular artery flap	15	Expanded
Cervical artery, cervicopectoral, occipitocervical, and cervicothoracic flap	8	Super-thin, expanded
Deltpectoral flap	3	Expanded
Trapezius flap	5	Fasciocutaneous, musculocutaneous, expanded, extended
Thoracodorsal artery perforator	4	Super-thin, expanded, free
Forehead flap	2	Island, expanded
Deep inferior epigastric perforator flap	1	Bipedicle, free
Lateral forearm flap	3	Free
Platysma flap	1	
Latissimus dorsi flap	4	Expanded, Free
Long-skin pedicled flap	2	
Groin flap	4	Free, expanded, bipedicle
Arterialized venous flap	3	Expanded
Tensor fascia lata flap	2	Free
Rectus femoris flap	1	Free
Medial thigh flap	1	Expanded, free
Anteromedial thigh flap	1	Free
Lateral leg perforator flap	1	Free
Chest flap	1	
V-Y flap	2	Reverse
Z-plasty, multi-z-plasty	7	Expanded, extended
Rhomboid flap	1	
Trapeze-flap	3	
Unspecified	9	Supercharged transpositional flap, fasciocutaneous flap, expanded, island, super-thin

improvement on the visual analog scale compared with nontreated burns.⁷⁷ Combined laser studies that utilized a pulsed dye laser for pruritis and erythema and CO₂ laser for stiffness and texture demonstrated improvements on the Vancouver Scar Scale and UNC Scar Scale.^{78–80} The use of the combined erbium:yttrium aluminum garnet/CO₂ laser also improved scar ratings.^{81,82} One institutional study showed decreased surgical reconstructions after laser therapy became available.⁸³ Steroid injections were often paired with laser therapy to enhance its affects.^{84–86}

Flaps were the most common reconstructive technique discussed (n = 208), and a wide variety of options were presented. (See table, Supplemental Digital Content 11, which displays a list of articles using flaps for reconstruction, <http://links.lww.com/PRSGO/C988>.) Expanders were frequently utilized to thin flaps and increase available tissue. There was one report of “reverse expansion” preformed via liposuction.⁸⁷

Skin autografts were the second most frequently mentioned technique after flaps (n = 89). (See table, Supplemental Digital Content 12, which displays a list of articles using grafts for reconstruction, <http://links.lww.com/PRSGO/C989>.) As previously discussed, grafts were subject to higher rates of contracture and, thus, not preferred over highly mobile areas. However, split-thickness grafts were utilized when available tissue was sparse and often used in conjunction with flaps. The Meek micrograph technique was developed to gain the most coverage

from a small amount of available skin, using small full-thickness skin grafts, and demonstrated promising results in terms of contracture rate.^{88,89} Fat grafting was utilized to restore volume and counteract skin tethering as well as for its therapeutic effects.^{35,90–96}

Engineered substances provided excellent options for coverage and improved contracture rates, especially in the setting of extensive burns (Supplemental Digital Content 9, <http://links.lww.com/PRSGO/C986>). Dermal matrices were frequently used (n = 29). A biodegradable temporizing matrix was used to provide temporizing coverage before autologous grafting. Cultured auto and allografts were shown to improve contracture rates but noted to be costly. Nexobrid (MediWound, Israel), an enzymatic debridement agent, was reported to decreased the need for scar contracture release when used in acute burns but is a novel method still in clinical studies.⁹⁷ Other additives and drugs currently in development have shown promising results. (See table, Supplemental Digital Content 13, which displays a table summarizing studies which focused on drugs used to treat and prevent burn contractures and their outcomes, <http://links.lww.com/PRSGO/C990>.) With the exception of mitomycin C, which showed negative effects on scarring, preliminary studies have shown that dehydrated human amnion chorion membrane, basic-fibroblast growth factor, platelet-rich plasma, pullulan-collagen biomimetic hydrogel scaffold enhanced with adipose-derived stem cells, small molecule focal adhesion kinase inhibitor, recombinant nematode anticoagulant

protein, pirfenidone, tamoxifen, TGF-beta antagonists/ decorin, activin-like kinase 5 inhibitor, A-83-0, botulinum toxin, Rho kinase inhibitor, Y-27632, pentoxifylline, interleukin 10, and imiquimod may each positively affect burn contractures.

Published Evidence

We identified 54 articles that reported statistically significant results. (See table, Supplemental Digital Content 14, which displays a summary of evidence in the literature on burn contracture reconstruction, <http://links.lww.com/PRSGO/C991>.) Eight of these were randomized control studies. These articles covered topics including the use of new drugs and additives, the most effective surgical techniques, optimal operative timing, the best choice for graft thickness, outcomes for graft reconstruction compared with flap reconstruction, the use of expanders, outcomes of laser therapy, and the use of reconstructive methods using engineered products. Although these findings are important for reconstructive and preventative treatment plans, the literature lacked strong evidence that could be used to develop an algorithmic anatomically based approach to burn contracture management. For each anatomic site, there are many reconstructive options but few direct comparisons of these options. There was, however, evidence for nonanatomically specific concepts as follows: flaps generally have better outcomes and lower risk of recontracture than grafts, acellular dermal matrices can be used as intermediates to decrease the risk of graft contracture, laser therapy has a mildly positive effect on burn contractures, and various drugs have shown promising results by inhibiting contracture formation in preliminary studies.

DISCUSSION

Burn contractures can have a significant impact on patient function and ability to return to daily activities. There is a wide variety of treatment options which must be decided based on the individual patient's needs and extent of burn contracture, as well as the area of contracture. This review summarizes the available literature over the past two decades, including 327 articles in total, and is currently the largest summation of current literature on burn contracture available. It can be utilized by providers as a consolidated reference when developing a treatment approach for burn patients.

There were many treatment methods discussed which ranged from grafts and flaps to engineered material and various modification techniques. The most commonly treated areas included the neck (n = 102) and upper extremity (n = 127), which is understandable, considering these anatomic areas can be challenging to reconstruct and can lead to significant functional morbidity if not adequately addressed. Flap reconstruction (n = 208) and autograft reconstructions (n = 89) were the most commonly used treatment modalities. Although skin graft reconstruction has low morbidity and is useful in patients with extensive burns due to limited tissue requirement, the rate of recurrent contracture is much higher

than flap reconstruction. Much of the literature sought to find a balance between the recurrent contracture rate of grafts and morbidity of flaps. Engineered materials such as dermal matrices were often utilized in conjunction with grafts to decrease the rate of recontracture (n = 29). Fasciocutaneous flaps, such as the ALT flap, were frequently used as low-morbidity options and paired with modification techniques such as super-thinning, expansion, and conversion to free flap to widen the scope of anatomic applicability.

Notably, despite the rate of burn contracture being high in the burn population, the number of prevention-focused articles was sparse (n = 54, 16.5%), and drug studies were mostly in preliminary stages. Available data have shown that scar contractures significantly increase the cost of healthcare for patients up to 5.6 times more than burn patients without contractures.⁹⁸ This is largely due to the number of surgical interventions that are required.⁹⁸ Although an individualized approach can improve the rate of recurrent correctional surgery, cost efficiency starts with prevention. Our study revealed that a clear emphasis should be placed on developing antiscar treatment modalities and accelerating the current research to identify prevention methods.

Our study had several limitations due to its structure. Our information was limited to available, reported, published data in the current literature. Some publications were not available and thus excluded, which may have led to selection bias, although the number of included publications was large to diminish this effect. Although the large number of publications included allowed us to present a comprehensive review, we were limited in the amount of detail presented from each. Our previous publications, however, have shown that inclusion of a large number of studies can be an incredibly useful reference for providers.⁹⁹⁻¹⁰³

CONCLUSIONS

An individualized approach to burn scar contracture management is essential to minimize the cost and morbidity to burn patients. Further research is necessary to increase preventative treatment strategies.

Jeffrey E. Janis, MD, FACS

Department of Plastic and Reconstructive Surgery
Ohio State University, Wexner Medical Center
915 Olentangy River Road, Suite 2100, Room 2114
Columbus, OH 43212

E-mail: jeffrey.janis@osumc.edu

Twitter: @jjanismd

Instagram: JeffreyJanisMD

DISCLOSURES

Dr. Janis received royalties from Thieme and Springer Publishing. Dr. Raborn has no financial interest to declare.

REFERENCES

1. Leblebici B, Adam M, Bağış S, et al. Quality of life after burn injury: the impact of joint contracture. *J Burn Care Res.* 2006;27:864-868.

2. Goverman J, Mathews K, Goldstein R, et al. Adult contractures in burn injury: a burn model system national database study. *J Burn Care Res* 2017;38:e328–e336.
3. Goverman J, Mathews K, Goldstein R, et al. Pediatric contractures in burn injury: a burn model system national database study. *J Burn Care Res* 2017;38:e192–e199.
4. Tricco AC, Lillie E, Zarin W, et al. PRISMA extension for scoping reviews (PRISMA-ScR): checklist and explanation. *Ann Intern Med*. 2018;169:467–473.
5. Munn Z, Peters MD, Stern C, et al. Systematic review or scoping review? Guidance for authors when choosing between a systematic or scoping review approach. *BMC Med Res Methodol*. 2018;18:1–7.
6. Saaiq M. Supraclavicular artery flap versus skin graft: which is a better reconstructive tool for managing post-burn contractures in the neck. *World J Plast Surg*. 2021;10:15–21.
7. Gao Y, Li H, Gu B, et al. Postburn neck contracture: principles of reconstruction and a treatment algorithm. *J Reconstr Microsurg*. 2018;34:514–521.
8. Tsai FC, Mardini S, Chen DJ, et al. The classification and treatment algorithm for post-burn cervical contractures reconstructed with free flaps. *Burns*. 2006;32:626–633.
9. Grishkevich VM. Trapeze-flap plasty: effective method for postburn neck contracture elimination. *Burns*. 2010;36:383–388.
10. Grishkevich VM, Grishkevich M, Menzul V. Postburn neck anterior contracture treatment in children with scar-fascial local trapezoid flaps: a new approach. *J Burn Care Res*. 2015;36:e112–e119.
11. Grishkevich VM, Grishkevich M. Postburn neck lateral contracture anatomy and treatment: a new approach. *J Burn Care Res*. 2015;36:e294–e299.
12. Yang JY, Tsai FC, Chana JS, et al. Use of free thin anterolateral thigh flaps combined with cervicoplasty for reconstruction of postburn anterior cervical contractures. *Plast Reconstr Surg*. 2002;110:39–46.
13. Tsai FC, Yang JY, Chuang SS, et al. Combined method of free lateral leg perforator flap with cervicoplasty for reconstruction of anterior cervical scar contractures: a new flap. *J Reconstr Microsurg*. 2002;18:185–190.
14. Zhang YX, Wang D, Follmar KE, et al. A treatment strategy for postburn neck reconstruction: emphasizing the functional and aesthetic importance of the cervicomenal angle. *Ann Plast Surg*. 2010;65:528–534.
15. Haik J, Prat D, Kornhaber R, et al. Treatment of cervical contractures utilising a closed platysmotomy like approach: case report and review of the literature. *Burns*. 2016;42:e93–e97.
16. Motamed S, Mousavizadeh SM, Niazi F, et al. Lateral lower face and neck contouring following burn injury. *Acta Med Iran*. 2015;53:225–230.
17. Samal CC, Dash S, Agrawal K, et al. Comparative evaluation of three methods of skin graft fixation for split thickness skin graft after release of post burn contracture of the neck. *Burns*. 2019;45:691–698.
18. Chou TD, Chen SL, Lee TW, et al. Reconstruction of burn scar of the upper extremities with artificial skin. *Plast Reconstr Surg*. 2001;108:378–384.
19. Karki D, Mehta N, Narayan RP. Post-burn axillary contracture: a therapeutic challenge! *Indian J Plast Surg*. 2014;47:375–380.
20. Asuku ME, Ibrahim A, Ijekeye FO. Post-burn axillary contractures in pediatric patients: a retrospective survey of management and outcome. *Burns*. 2008;34:1190–1195.
21. Issa M, Badawi M, Bisheet G, et al. Skin graft versus local flaps in management of post-burn elbow contracture. *Cureus*. 2021;13:e20768.
22. Chan QE, Barzi F, Harvey JG, et al. Functional and cosmetic outcome of full- versus split-thickness skin grafts in pediatric palmar surface burns: a prospective, independent evaluation. *J Burn Care Res*. 2013;34:232–236.
23. Chandrasegaram MD, Harvey J. Full-thickness vs split-skin grafting in pediatric hand burns—a 10-year review of 174 cases. *J Burn Care Res*. 2009;30:867–871.
24. Weeks D, Kasdan ML, Wilhelmi BJ. Forty-year follow-up of full-thickness skin graft after thermal burn injury to the volar hand. *Eplasty*. 2016;16:e21.
25. Bassetto F, Staffieri A, Reho F, et al. Management of complex pediatric burn scars in a humanitarian collaboration. *Ann Burns Fire Disasters*. 2015;28:46–49.
26. Hop MJ, Langenberg LC, Hiddingh J, et al. Reconstructive surgery after burns: a 10-year follow-up study. *Burns*. 2014;40:1544–1551.
27. Pan Y, Liang Z, Yuan S, et al. A long-term follow-up study of acellular dermal matrix with thin autograft in burns patients. *Ann Plast Surg*. 2011;67:346–351.
28. Gurbuz K, Demir M, Das K. The use of dermal substitute in deep burns of functional/mobile anatomic areas at acute phase after early excision and subsequent skin autografting: dermal substitute prevents functional limitations. *J Burn Care Res*. 2020;41:1079–1083.
29. Haslik W, Kamolz LP, Manna F, et al. Management of full-thickness skin defects in the hand and wrist region: first long-term experiences with the dermal matrix Matriderm. *J Plast Reconstr Aesthet Surg*. 2010;63:360–364.
30. Ou KL, Tzeng YS, Liu HH, et al. Negative pressure wound therapy in conjunction with artificial dermis for burned hand reconstruction. *Ann Plast Surg*. 2021;86:S13–S17.
31. Burn JS, Oh SJ. Fist position for skin grafting on the dorsal hand: II clinical use in deep burns and burn scar contractures. *Plast Reconstr Surg*. 2000;105:581–588.
32. Jiang Y, Guo R, Zhou S, et al. Functional and aesthetic reconstruction of digital flexion contractures with full-thickness planar skin grafts in children. *Dermatol Ther*. 2020;33:e14466.
33. Morandi EM, Schwabegger E, Tasch C, et al. Skin grafting after paediatric palmar burns: an analysis of 82 patients. *J Hand Surg Eur Vol*. 2019;44:1031–1035.
34. Greyson MA, Wilkens SC, Sood RF, et al. Five essential principles for first web space reconstruction in the burned hand. *Plast Reconstr Surg*. 2020;146:578e–587e.
35. Byrne M, O'Donnell M, Fitzgerald L, et al. Early experience with fat grafting as an adjunct for secondary burn reconstruction in the hand: technique, hand function assessment and aesthetic outcomes. *Burns*. 2016;42:356–365.
36. Colonna MR, Scarcella MC, Stagno d'Alcontres F, et al. Should fat graft be recommended in tendon scar treatment? Considerations on three cases (two feet and a severe burned hand). *Eur Rev Med Pharmacol Sci*. 2014;18:753–759.
37. Prasetyono TO, Koswara AF. Retrospective analysis of the one-per-million tumescent technique in post-burn hand deformity surgeries. *Arch Plast Surg*. 2015;42:164–172.
38. Hayashida K, Fujioka M, Morooka S, et al. Effectiveness of basic fibroblast growth factor for pediatric hand burns. *J Tissue Viability*. 2016;25:220–224.
39. Matsumine H, Fujimaki H, Takagi M, et al. Full-thickness skin reconstruction with basic fibroblast growth factor-impregnated collagen-gelatin sponge. *Regen Ther*. 2019;11:81–87.
40. Pruksapong C, Burusapat C, Hongkarnjanakul N. Efficacy of silicone gel versus silicone gel sheet in hypertrophic scar prevention of deep hand burn patients with skin graft: a prospective randomized controlled trial and systematic review. *Plast Reconstr Surg Glob Open*. 2020;8:e3190.
41. Grishkevich VM. Ankle dorsiflexion postburn scar contractures: anatomy and reconstructive techniques. *Burns*. 2012;38:882–888.

42. Boffeli TJ, Gorman CM. Achilles lengthening and multiple Z-plasty in parallel for correction of toe walking associated with burn scar equinus contracture. *J Foot Ankle Surg.* 2019;58:1025–1029.
43. Dhanraj P, Wiesey F, Phillips LG, et al. Burn scar contractures of the feet: efficacy of bilateral simultaneous surgical correction. *Burns.* 2002;28:814–819.
44. Ma Z, Mo R, Chen C, et al. Surgical treatment of joint burn scar contracture: a 10-year single-center experience with long-term outcome evaluation. *Ann Transl Med.* 2021;9:303.
45. Motamed S, Hasanpoor SE, Moosavizadeh SM, et al. Treatment of flexion contractures following burns in extremities. *Burns.* 2006;32:1017–1021.
46. Yim H, Cho YS, Seo CH, et al. The use of AlloDerm on major burn patients: AlloDerm prevents post-burn joint contracture. *Burns.* 2010;36:322–328.
47. Angrigiani C, Artero G, Castro G, et al. Reconstruction of thoracic burn sequelae by scar release and flap resurfacing. *Burns.* 2015;41:1877–1882.
48. Palao R, Gómez P, Huguet P. Burned breast reconstructive surgery with Integra dermal regeneration template. *Br J Plast Surg.* 2003;56:252–259.
49. Mueller M, Boorman JG. Post-burn breast resurfacing using an abdominal full-thickness skin graft. *Br J Plast Surg.* 2002;55:148–150.
50. Hsiao YC, Yang JY, Chuang SS, et al. Are augmentation mammoplasty and reconstruction of the burned breast collateral lines? Experience in performing simultaneous reconstructive and aesthetic surgery. *Burns.* 2009;35:130–136.
51. Grishkevich VM. Restoration of the shape, location and skin of the severe burn-damaged breast. *Burns.* 2009;35:1026–1035.
52. Haik J, Grabov-Nardini G, Goldan O, et al. Expanded reverse abdominoplasty for reconstruction of burns in the epigastric region and the inframammary fold in female patients. *J Burn Care Res.* 2007;28:849–853.
53. Takeda K, Sowa Y, Numajiri T, et al. Expansion abdominoplasty for a pregnant woman with severe abdominal wall contracture due to a major burn during childhood: a case report. *Ann Plast Surg.* 2013;70:643–646.
54. Ergün SS. Release of the postburn contractures on the lower abdomen and inguinal regions using modified abdominoplasty. *J Burn Care Res.* 2012;33:e247–e250.
55. Acarturk TO, Bengur FB. Total aesthetic subunit reconstruction of the burned anterior abdomen using pre-expanded pedicled anterolateral thigh flap—a case report. *Microsurgery.* 2019;39:753–757.
56. Wu L, Qiu Y, Wang B. Adolescent scar contracture scoliosis caused by back scalding during the infantile period. *Stud Health Technol Inform.* 2006;123:135–140.
57. Qiu Y, Wang SF, Wang B, et al. Adolescent scar contracture scoliosis caused by back scalding during the infantile period. *Eur Spine J.* 2007;16:1557–1562.
58. Tao HR, Hui H, Guo SZ, et al. Staged corrective surgery for complex adolescent kyphoscoliosis caused by back scalding during the childhood period. *Eur Spine J.* 2013;22:305–309.
59. Can A, Orgill DP, Dietmar Ulrich JO, et al. The myocutaneous trapezius flap revisited: a treatment algorithm for optimal surgical outcomes based on 43 flap reconstructions. *J Plast Reconstr Aesthet Surg.* 2014;67:1669–1679.
60. Yeh CC, Lin YS, Huang KF. Resurfacing of total penile full-thickness burn managed with the Versajet hydrosurgery system. *J Burn Care Res.* 2010;31:361–364.
61. Jaskille AD, Shupp JW, Jeng JC, et al. Use of Integra in the treatment of third degree burns to the penile shaft: a case series with 6-month follow-up. *J Burn Care Res.* 2009;30:524–528.
62. Öksüz M, Deliağa H, Topkara A, et al. An unexpected long-term complication of genital burn in a child: secondary cryptorchidism. *Ulus Travma Acil Cerrahi Derg.* 2018;24:85–87.
63. Grishkevich VM. Postburn perineal obliteration: elimination of perineal, inguinal, and perianal contractures with the groin flap. *J Burn Care Res.* 2010;31:786–790.
64. Benito P, De Juan A, Cano M. The pudendal thigh flap as YV advanced flap for the release of perineum burns contractures. *J Plast Reconstr Aesthet Surg.* 2012;65:681–683.
65. Grishkevich VM. Burned perineum reconstruction: a new approach. *J Burn Care Res.* 2009;30:620–624.
66. Eo S, Kim D, Jones NF. Microdissection thinning of a pedicled deep inferior epigastric perforator flap for burn scar contracture of the groin: case report. *J Reconstr Microsurg.* 2005;21:447–450.
67. Hirokawa E, Sato T, Fujino T, et al. Hydrosurgical debridement as an approach to wound healing: an animal thermal burn model. *J Wound Care.* 2019;28:304–311.
68. Fioramonti P, Cigna E, Onesti MG, et al. Extracorporeal shock wave therapy for the management of burn scars. *Dermatol Surg.* 2012;38:778–782.
69. El Kahi CG, Atiyeh BS, Abdallah Hajj Hussein I, et al. Modulation of wound contracture alpha-smooth muscle actin and multispecific vitronectin receptor integrin alphavbeta3 in the rabbit's experimental model. *Int Wound J.* 2009;6:214–224.
70. Gupta SS, Singh O, Bhagel PS, et al. Honey dressing versus silver sulfadiazene dressing for wound healing in burn patients: a retrospective study. *J Cutan Aesthet Surg.* 2011;4:183–187.
71. Ziegler T, Cakl T, Schauer J, et al. Treatment of second to third-degree burns in a 2-day-old infant: a case report. *Int J Surg Case Rep.* 2019;61:195–198.
72. Ayaz M, Karami MY, Deilami I, et al. Effects of early versus delayed excision and grafting on restoring the functionality of deep burn-injured hands: a double-blind, randomized parallel clinical trial. *J Burn Care Res.* 2019;40:451–456.
73. Mohammadi AA, Bakhshaeekia AR, Marzban S, et al. Early excision and skin grafting versus delayed skin grafting in deep hand burns (a randomised clinical controlled trial). *Burns.* 2011;37:36–41.
74. Murphy KE, McCue SW, McElwain DL. Clinical strategies for the alleviation of contractures from a predictive mathematical model of dermal repair. *Wound Repair Regen.* 2012;20:194–202.
75. Zhou R, Qiu L, Xiao J, et al. Early wound repair versus later scar repair in children with treadmill hand friction burns. *J Burn Care Res.* 2022;43:269–276.
76. Seago M, Shumaker PR, Spring LK, et al. Laser treatment of traumatic scars and contractures: 2020 International Consensus Recommendations. *Lasers Surg Med.* 2020;52:96–116.
77. Gaida K, Koller R, Isler C, et al. Low level laser therapy—a conservative approach to the burn scar? *Burns.* 2004;30:362–367.
78. Hultman CS, Friedstat JS, Edkins RE, et al. Laser resurfacing and remodeling of hypertrophic burn scars: the results of a large, prospective, before-after cohort study, with long-term follow-up. *Ann Surg.* 2014;260:519–29; discussion 529–32.
79. Hultman CS, Edkins RE, Wu C, et al. Prospective, before-after cohort study to assess the efficacy of laser therapy on hypertrophic burn scars. *Ann Plast Surg.* 2013;70:521–526.
80. Staubach R, Glosse H, Fennell S, et al. A single-institution experience about 10 years with children undergoing fractional ablative carbon dioxide laser treatment after burns: measurement of air pressure-induced skin elevation and retraction time (Dermalab) including standardized subjective and objective scar evaluation. *J Burn Care Res.* 2023;44:655–669.
81. Kawecki M, Bernad-Wiśniewska T, Sakiel S, et al. Laser in the treatment of hypertrophic burn scars. *Int Wound J.* 2008;5:87–97.

82. Rodriguez-Menocal L, Davis SS, Becerra S, et al. Assessment of ablative fractional CO₂ laser and Er:YAG laser to treat hypertrophic scars in a red duroc pig model. *J Burn Care Res.* 2018;39:954–962.
83. Issler-Fisher AC, Fisher OM, Clayton NA, et al. Ablative fractional resurfacing for burn scar management affects the number and type of elective surgical reconstructive procedures, hospital admission patterns as well as length of stay. *Burns.* 2020;46:65–74.
84. Tennyson H, Helling ER, Wiseman J, et al. The effect of topical mitomycin C on full-thickness burns. *Plast Reconstr Surg.* 2007;120:879–886.
85. Uebelhoer NS, Ross EV, Shumaker PR. Ablative fractional resurfacing for the treatment of traumatic scars and contractures. *Semin Cutan Med Surg.* 2012;31:110–120.
86. Waibel JS, Wulkan AJ, Shumaker PR. Treatment of hypertrophic scars using laser and laser assisted corticosteroid delivery. *Lasers Surg Med.* 2013;45:135–140.
87. Ibrahim AE, Debbas CC, Dibo SA, et al. Reverse tissue expansion by liposuction deflation adopted for harvest of large sheet of full-thickness skin graft. *Ann Burns Fire Disasters.* 2012;25:98–101.
88. Lee SZ, Halim AS, Wan Sulaiman WA, et al. Outcome of the modified meek technique in the management of major pediatric burns. *Ann Plast Surg.* 2018;81:295–301.
89. Rettinger CL, Fletcher JL, Carlsson AH, et al. Accelerated epithelialization and improved wound healing metrics in porcine full-thickness wounds transplanted with full-thickness skin micrografts. *Wound Repair Regen.* 2017;25:816–827.
90. Al-Hayder S, Gramkow C, Trojahn Kølbe SF. Use of autologous fat grafting for the correction of burn scar contracture in the hand: a case report. *Case Reports Plast Surg Hand Surg.* 2017;4:81–83.
91. Gargano F, Schmidt S, Evangelista P, et al. Burn scar regeneration with the “SUFA” (Subcision and Fat Grafting) technique. A prospective clinical study. *JPRAS Open.* 2018;17:5–8.
92. Karakol P, Bozkurt M. Recent strategic approach in post-burn extremity scars and contractures. *J Plast Surg Hand Surg.* 2021;55:153–161.
93. Klinger M, Caviglioli F, Klinger FM, et al. Autologous fat graft in scar treatment. *J Craniofac Surg.* 2013;24:1610–1615.
94. Le JM, Bosworth JW, Honeywell B, et al. Adipose grafting for volume and scar release. *Ann Plast Surg.* 2021;86:S487–S490.
95. Luo X, Liu F, Wang X, et al. Region-oriented and staged treatment strategy in reconstruction of severe cervical contracture. *PLoS One.* 2015;10:e0122669.
96. Xu X, Lai L, Zhang X, et al. Autologous chyle fat grafting for the treatment of hypertrophic scars and scar-related conditions. *Stem Cell Res Ther.* 2018;9:64.
97. Korzeniowski T, Grywalska E, Strużyna J, et al. Preliminary single-center experience of bromelain-based eschar removal in children with mixed deep dermal and full thickness burns. *J Clin Med.* 2022;11:4800.
98. Mirastschijski U, Sander JT, Zier U, et al. The cost of post-burn scarring. *Ann Burns Fire Disasters.* 2015;28:215–222.
99. ElHawary H, Hintermayer MA, Alam P, et al. Decreasing surgical site infections in plastic surgery: a systematic review and meta-analysis of level 1 evidence. *Aesthet Surg J.* 2021;41:NP948–NP958.
100. Saeg F, Schoenbrunner AR, Janis JE. Evidence-based wound irrigation: separating fact from fiction. *Plast Reconstr Surg.* 2021;148:601e–614e.
101. Saeg F, Orazi R, Bowers GM, et al. Evidence-based nutritional interventions in wound care. *Plast Reconstr Surg.* 2021;148:226–238.
102. Raborn LN, Janis JE. Overcoming the impact of COVID-19 on surgical mentorship: a scoping review of long-distance mentorship in surgery. *J Surg Educ.* 2021;78:1948–1964.
103. Raborn LN, Janis JE. Current views on the new United States medical licensing examination step 1 pass/fail format: a review of the literature. *J Surg Res.* 2022;274:31–45.