



Medial Meniscotibial Ligament of the Knee: A Step by-Step Dissection

Ligamento meniscotibial medial do joelho: Uma dissecação passo a passo

Jonatas Brito de Alencar Neto¹ Alexia Barros Cardoso¹ Gerônimo de Souza Munhoz¹
Luiz Holanda Pinto Neto¹ Renata Clazzer² Diego Ariel de Lima^{2,3}

¹ Physician, orthopedic and traumatologist, Department of Orthopedics and Traumatology, Doctor José Frota Institute, Fortaleza, CE, Brazil

² Physician, Orthopedist and traumatologist, Department of Orthopedics and Traumatology, Otávio de Freitas Hospital, Recife, PE, Brazil

³ Professor, Department of Health Sciences, Federal Rural University of the Semi-Arid, Mossoró, RN, Brazil

Address for correspondence Diego Ariel de Lima, MD, PhD, Universidade Federal Rural do Semi-Árido, Rua Francisco Mota, 572, Pres. Costa e Silva, Mossoró, RN, 59625-900, Brazil (e-mail: arieldelima.diego@gmail.com).

Rev Bras Ortop 2023;58(5):e755–e759.

Abstract

Objective Considerable attention has been paid to meniscotibial ligaments (MTLs), also known as coronary ligaments, especially after the “Save the Meniscus” initiative gained importance among knee surgeons. Technically challenging, the diagnosis and treatment of ramp lesion show the importance of MTLs. These ligaments were discovered long ago, but their contribution to knee stability has only recently been studied and still lacks information. Thus, the aim of the present study was to describe step-by-step an dissection technique of the medial MTL, efficient, reproducible and that may lead to further research.

Method Twenty fresh cadaver knees were used, with no preference for sex or age. The knees were dissected using the same technique standardized by our team. Each dissection step was recorded digitally.

Results The medial MTL was found in all 20 knees studied using the aforementioned technique. In our sample, the medial MTL exhibited an average length of 70.0 ± 13.4 mm and width of 32.25 ± 3.09 mm, thickness of 35.3 ± 2.7 mm and weight of 0.672 ± 0.134 g. In all the cases, the medial MTL originated proximally and deeply to the deep MTL in the tibia.

Conclusion We describe a simple effective and reproducible medial MTL dissection technique that makes it possible to identify the ligament over the entire medial extension of the knee.

Keywords

- ligaments
- menisci, tibial
- dissection

Work developed at the José Frota Institute, Fortaleza, CE, Brazil.

received
July 25, 2022
accepted
November 23, 2022

DOI <https://doi.org/10.1055/s-0043-1776137>.
ISSN 0102-3616.

© 2023. Sociedade Brasileira de Ortopedia e Traumatologia. All rights reserved.

This is an open access article published by Thieme under the terms of the Creative Commons Attribution-NonDerivative-NonCommercial-License, permitting copying and reproduction so long as the original work is given appropriate credit. Contents may not be used for commercial purposes, or adapted, remixed, transformed or built upon. (<https://creativecommons.org/licenses/by-nc-nd/4.0/>)

Thieme Revinter Publicações Ltda., Rua do Matoso 170, Rio de Janeiro, RJ, CEP 20270-135, Brazil

Resumo

Objetivo Considerável atenção tem sido dada aos ligamentos meniscotibiais (LMT), também conhecidos como ligamentos coronários, especialmente depois que a iniciativa “Salve o Menisco” ganhou importância entre os cirurgiões de joelho. Tecnicamente desafiadores, o diagnóstico e o tratamento da lesão em rampa são importantes nos LMTs. Esses ligamentos foram descobertos há muito tempo, mas sua contribuição para a estabilidade do joelho foi recentemente estudada e ainda carece de informações. Assim, o objetivo deste estudo foi descrever passo a passo uma técnica de dissecação medial do LMT que é eficiente, reproduzível e que possa levar a novas pesquisas.

Métodos Foram utilizados 20 joelhos de cadáveres frescos, sem preferência por sexo ou idade. Os joelhos foram dissecados com a mesma técnica padronizada por nossa equipe. Cada etapa da dissecação foi gravada digitalmente.

Resultados O LMT medial foi encontrado em todos os 20 joelhos estudados com a técnica supracitada. Em nossa amostra, o LMT medial apresentou comprimento médio de $70,0 \pm 13,4$ mm e largura de $32,25 \pm 3,09$ mm, além de espessura de $35,3 \pm 2,7$ mm e peso de $0,672 \pm 0,134$ g. Em todos os casos, a origem do LMT medial era proximal e profunda em relação ao LMT profundo na tíbia.

Conclusão Descrevemos uma técnica de dissecação simples do LMT medial que é eficaz, reproduzível e permite a identificação do ligamento em toda a extensão medial do joelho.

Palavras-chaves

- ▶ ligamentos
- ▶ meniscos tibiais
- ▶ dissecação

Introduction

The menisci are fibrocartilaginous structures that provide important functionalities to the biomechanical complex of the knee, such as axial and tension forces, cushioning, synovial fluid distribution and an increase in articular surface area between the tibia and femur.¹⁻⁴ These structures are attached to the knee by meniscocapsular ligaments, which contain meniscofemoral and meniscotibial (MTL) components.^{1,5,6}

Peltier et al.⁷ described the importance of MTLs for knee stability, especially for posteromedial rotation stability. MTL lesion is a common cause of knee pain in middle-aged athletes.⁸ In addition, MTLs, particularly the medial meniscotibial ligament, exhibit synergic action with the anterior cruciate ligament (ACL), primarily for rotation stability, anterior translation and internal and external rotations, clinically confirmed by the rotational test during physical examination.⁷

Considerable attention has been paid to MTLs, also known as coronary ligaments, especially after the “Save the Meniscus” initiative gained importance among knee surgeons. Technically challenging, the diagnosis and treatment of ramp lesion show the importance of MTLs.¹ These ligaments were discovered long ago, but their contribution to knee stability has only recently been studied and still lacks information.¹

Thus, the aim of the present study was to describe step-by-step an dissection technique of the medial LMT, efficient, reproducible and that may lead to further research.

Methods

The present study was approved by the Research Ethics Committee (protocol number: 27128619.6.0000.5047).

Twenty fresh cadaver knees were used, with no preference for sex or age. The corpses were selected by the Intrahospital Commission on Organ and Tissue Donation for Transplants.

Exclusion criteria were cadavers with traumatic signs or degenerative lesion around the knee that would hinder medial MTL dissection. However, none of the selected cadavers were excluded.

All the knees were dissected using the same technique to determine the incidence of medial MTLs, thereby maintaining standards important to the study conclusions.

Results

The cutaneous incision starts in the topography proximal to the medial epicondyle toward the posterior edge of the tibia (▶ **Fig. 1A**). After diuresis of the skin and subcutaneous cell tissue, the crural fascia was identified inferiorly to the sartorius fascia (▶ **Fig. 1B**).

After the longitudinal incision on the crural fascia is made, it is possible to observe the superficial medial collateral ligament (MCL) and articular line (AL) (▶ **Fig. 2**). After distally releasing the superficial MCL, we can identify the capsule of the knee joint (known as the third layer, according to Warren and Marshall⁹), which becomes thicker and forms a vertically oriented band of short fibers known as the deep MCL. This, in turn, extends from the femur to the medial portion of the peripheral margin of the meniscus and tibia.

Anteriorly, the deep MCL is clearly separated from the superficial MCL by an interposed pouch. Posteriorly, however, the layers join because the meniscofemoral portion of the deep MCL tends to merge with the overlying superficial MCL in the region near cephalic fixation. The meniscotibial portion of the deep MCL, however, is immediately separated from the

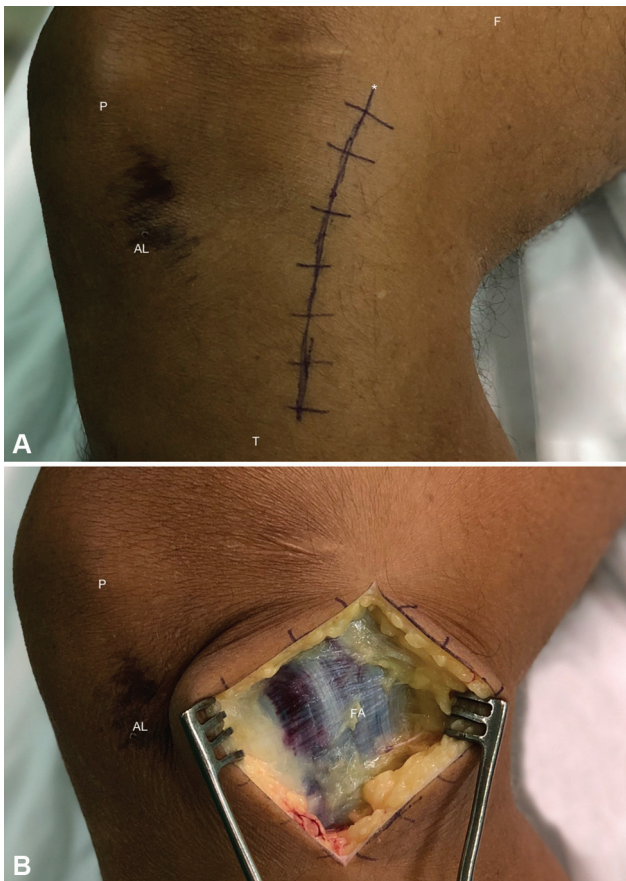


Fig. 1 Access for exeresis of the medial MTLs. (A) The cutaneous incision starts in the topography proximal to the medial epicondyle toward the posterior edge of the tibia. (B) First medial layer of the knee. (P: Patella; AL: Articular Line; F: Femur; T: Tibia; FA: Sartorius Fascia; *: Cutaneous Incision).

overlying superficial MCL and is referred to as the coronary ligament, that is, part of the medial MTL itself. Thus, identifying the deep MCL is an excellent reference to identify the medial MTL and its meniscal and tibial insertions (→ Fig. 3).

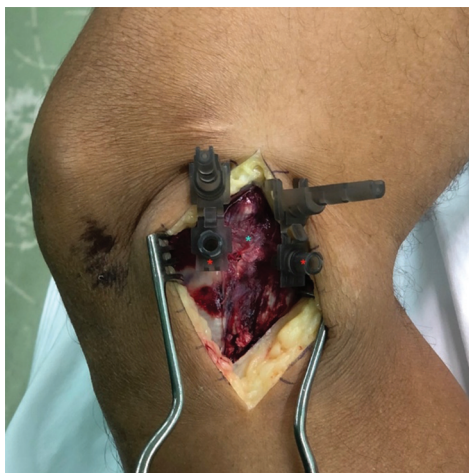

Fig. 2 Access for exeresis of the medial MTLs. Second medial layer of the knee. Needles demonstrate the exact position of the articular line. Medial collateral ligament between the needles (Red asterisk: 25 × 7mm needles; Blue asterisk: medial collateral ligament).

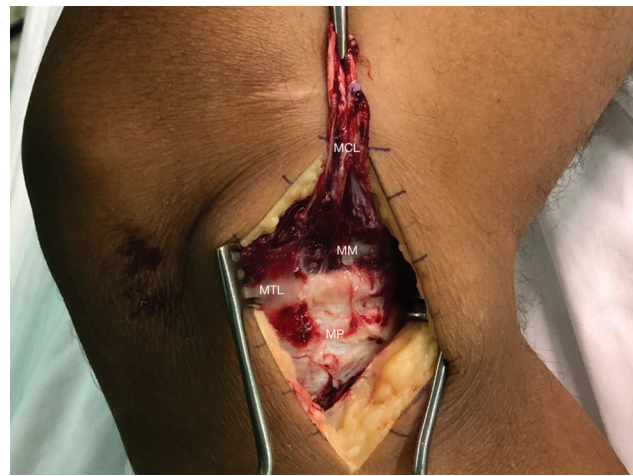


Fig. 3 Access for exeresis of the medial MTLs. Third medial layer of the knee. Medial collateral ligament displaced proximally, to enable visualization of the medial meniscus and medial MTL (inserted). (MCL: Medial collateral ligament; MTL: Meniscotibial ligament; MP: Medial plateau; MM: Medial meniscus).

The tibial insertion of the MTL is released and the meniscus proximally displaced, revealing the entire extension and length of the medial MTL (→ Fig. 4).

In all the cadavers, we observed that this ligament exhibits vast meniscal and tibial interdigitation.

A transverse incision is made in the meniscal and tibial insertions, highlighting the entire medial MTL (→ Fig. 5)

The medial MTL was found in all 20 knees studies using the aforementioned technique. In our sample, the medial MTL exhibited an average length of 70.0 ± 13.4 mm and width of 32.25 ± 3.09 mm, thickness of 35.3 ± 2.7 mm and weight of 0.672 ± 0.134 g. In all the cases, the origin of the medial MCL was proximal and deep in relation to the deep MTL in the tibia.

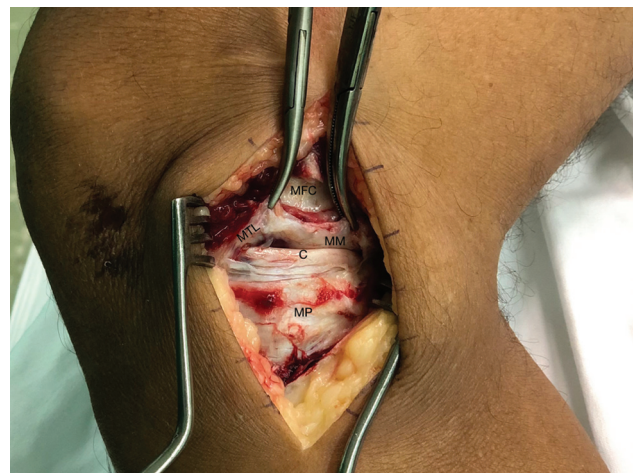


Fig. 4 Access for exeresis of the medial MTLs. Third medial layer of the knee. Medial MTL insertion (displaced proximally). (MTL: Medial tibial meniscus ligament; MM: Medial meniscus; MFC: Medial femoral condyle; MP: Medial plateau; C: Cartilage).

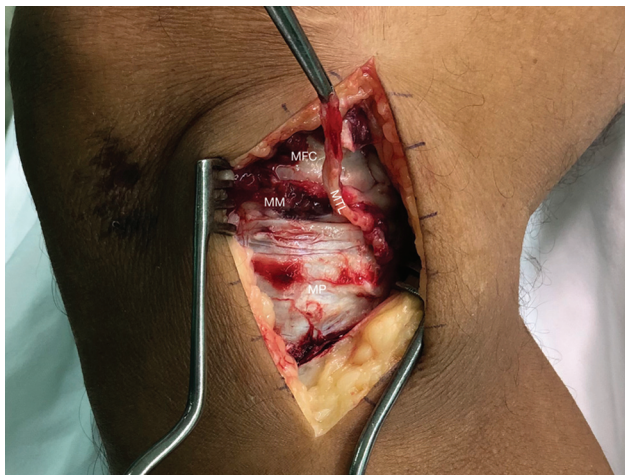


Fig. 5 Access for exeresis of the medial MTLs. Disinsertion of the medial MTL of the medial meniscus and its tibial insertion (MTL: Medial tibial meniscus ligament; MM: Medial meniscus; MFC: Medial femoral condyle; MP: Medial plateau).

Discussion

Clinical and anatomical studies of the MTL have increased significantly in recent years. However, a thorough understanding of the anatomy via well performed or standardized dissections is essential to manage surgeries and conduct additional research. However, information on medial MTLs is limited, primarily with respect to anatomical dissection.

In 2010, Fang et al.¹⁰ dissected 10 cadavers, initially identifying the superficial MCL and the deep MCL from their femoral and tibial insertions. The anatomy of the deep MCL was analyzed in two parts: meniscofemoral and meniscotibial ligaments, with a description of the length, insertion site and relationship with the meniscus. Cavaignac et al.¹¹ studied 14 cadavers and described a dissection with disinsertion of goose foot tendons, sectioning the medial gastrocnemius tendon up to its femoral insertion to release the posterior capsula and disinsert the femur from the vastus medialis muscle. A single anatomical part was collected from each cadaver, including the medial condyle, medial tibial plateau, medial meniscus, cruciate ligaments, articular capsule and distal insertion of the semimembranosus. In all the cases, macroscopic examination revealed a structure corresponding to the meniscotibial ligament, inserted into the inferior part of the medial meniscus, specifically at the posterior-inferior border.

In a study on the anatomy of the posterior medial meniscus, DePhillipo et al.¹² described a dissection in which all the soft tissues were removed 10 cm distal and proximal to the articular line, and whole structures of the posteromedial corner were left intact. Analysis revealed a common attachment between the insertion of the medial meniscus ligament and meniscocapsular insertion in the posterior horn of the medial meniscus.

Griffith et al.¹³ dissected 24 cadaver knees, highlighting the semitendinosus, gracilis and sartorius muscles and tendons, and isolating, in a deeper dissection, the proximal and

distal divisions of the superficial MCL, posterior oblique ligament and the meniscofemoral and meniscotibial divisions of the deep MCL. DePhillipo et al.¹⁴ described a posterior longitudinal approach with the dissection made between the heads of the gastrocnemius muscles, locating the MTL medial to the tibial facet of the posterior cruciate ligament, 1.5 cm distal to the articular line. A 2007 study² dissected 85 knees, finding MTLs in only 23.5%, and two different insertions in each.

Di Francia et al.¹⁵ recently described a direct posterior approach via the popliteal fossa, identifying, isolating and sectioning the ischiotibial and gastrocnemius muscles, revealing the posterior capsula of the knee, which was opened at its most proximal part, allowing access to the posterior segment of the medial meniscus. Histological analysis found no ligament structure corresponding to the MTL.

The present study presented a large number of patients studied when compared with others on the same topic. LaPrade et al.¹⁶ dissected 8 cadaver knees to study the anatomy of the medial part of the knee. El-Khoury et al.¹⁷ dissected 10 knees, 4 from adult cadavers and 6 from dead fetuses, to study ruptures of the MTL. Liu et al.¹⁰ studied the knees of 10 cadavers to describe the morphology of the medial collateral ligament. Griffith et al.¹³ dissected 24 cadavers to assess the biomechanical correlation of the medial knee structures. Few studies, however, provide a detailed description of the anatomical dissection procedure.

Conclusion

We describe a simple effective and reproducible medial MTL dissection technique that makes it possible to identify the ligament over the entire medial extension of the knee.

Financial Support

The present study received no financial support from public, commercial, or notfor-profit sources.

Conflict of Interests

The authors have no conflict of interests to declare.

References

- 1 de Alencar Neto JB, dos Santos AP, Lopes MBG, de Lima LL, Clazzer R, de Lima DA. Anatomia do ligamento meniscotibial medial do joelho: Uma revisão sistemática. [Publicação online: 2022-06-10]. Rev Bras Ortop. Disponível em: <https://www.thieme-connect.com/products/ejournals/html/10.1055/s-0042-1749199>
- 2 Bezerra FS, Alves JN, Silva MAS, et al. Quantitative and descriptive analysis of the meniscotibial ligament in human corpses. Journal of Morphological Sciences 2007;24(04):211-213
- 3 Seitz A, Kasisari R, Claes L, Ignatius A, Dürselen L. Forces acting on the anterior meniscotibial ligaments. Knee Surg Sports Traumatol Arthrosc 2012;20(08):1488-1495
- 4 Arnoczky SP, Warren RF. Microvasculature of the human meniscus. Am J Sports Med 1982;10(02):90-95
- 5 Aman ZS, DePhillipo NN, Storaci HW, et al. Quantitative and qualitative assessment of posterolateral meniscal anatomy: defining the popliteal hiatus, popliteomeniscal fascicles, and the lateral meniscotibial ligament. Am J Sports Med 2019;47(08):1797-1803

- 6 Day B, Mackenzie WG, Shim SS, Leung G. The vascular and nerve supply of the human meniscus. *Arthroscopy* 1985;1(01):58–62
- 7 Peltier A, Lording T, Maubisson L, Ballis R, Neyret P, Lustig S. The role of the meniscotibial ligament in posteromedial rotational knee stability. *Knee Surg Sports Traumatol Arthrosc* 2015;23(10):2967–2973
- 8 Millar AP. Meniscotibial ligament strains: a prospective survey. *Br J Sports Med* 1991;25(02):94–95
- 9 Wan AC, Felle P. The menisco-femoral ligaments. *Clin Anat* 1995;8(05):323–326
- 10 Liu F, Yue B, Gadikota HR, et al. Morphology of the medial collateral ligament of the knee. *J Orthop Surg Res* 2010;5(01):69
- 11 Cavaignac E, Sylvie R, Teulières M, et al. What is the relationship between the distal semimembranosus tendon and the medial meniscus? A gross and microscopic analysis from the SANTI study group. *Am J Sports Med* 2021;49(02):459–466
- 12 DePhillipo NN, Moatshe G, Chahla J, et al. Quantitative and qualitative assessment of the posterior medial meniscus anatomy: defining meniscal ramp lesions. *Am J Sports Med* 2019;47(02):372–378
- 13 Griffith CJ, LaPrade RF, Johansen S, Armitage B, Wijdicks C, Engebretsen L. Medial knee injury: Part 1, static function of the individual components of the main medial knee structures. *Am J Sports Med* 2009;37(09):1762–1770
- 14 DePhillipo NN, Moatshe G, Brady A, et al. Effect of Meniscocapsular and Meniscotibial Lesions in ACL-Deficient and ACL-Reconstructed Knees: A Biomechanical Study. *Am J Sports Med* 2018;46(10):2422–2431
- 15 Di Francia R, Nicolas Q, Quintin-Roué I, Le Henaff G, Gunepin FX, Dubrana F. Ramp lesions of the posterior segment of the medial meniscus: what is repaired? A qualitative histological study of the meniscocapsular and meniscotibial attachments. *Clin Orthop Relat Res* 2020;478(12):2912–2918
- 16 LaPrade RF, Engebretsen AH, Ly TV, Johansen S, Wentorf FA, Engebretsen L. The anatomy of the medial part of the knee. *J Bone Joint Surg Am* 2007;89(09):2000–2010
- 17 El-Khoury GY, Usta HY, Berger RA. Meniscotibial (coronary) ligament tears. *Skeletal Radiol* 1984;11(03):191–196