

Congenital Esophageal Atresia Associated with a Tracheobronchial Remnant

Yuhao Wu, M.D.^{1,2,3,4}, Chun Wu, M.D.^{1,2,3,4}

¹Department of Cardiothoracic Surgery, Children's Hospital of Chongqing Medical University;

²Ministry of Education Key Laboratory of Child Development and Disorders; ³China International Science and Technology Cooperation Base of Child Development and Critical Disorders; ⁴Chongqing Key Laboratory of Pediatrics, Chongqing, China

A rare case of esophageal atresia/tracheo-esophageal fistula (EA-TEF) with an associated tracheobronchial remnant (TBR) is reported and discussed herein. A 13-month-old patient was seen with a complaint of vomiting of solid food 1 year after EA-TEF repair. An esophagogram showed a tapered narrowing in the lower segment of the esophagus. A re-operation was carried out and a pathologic examination of the resected stenotic segment revealed the presence of a TBR.

Key words: 1. Esophageal atresia
2. Esophageal stenosis
3. Tracheobronchial remnant

Case report

Esophageal atresia (EA) is a congenital malformation with a frequency of 1 per 3,000 to 3,500 live births [1]. The surgical treatment for EA is reliable; however, complications such as anastomotic stricture, gastro-esophageal reflux disease (GERD), and anastomotic leak are often observed after surgery. Congenital esophageal stenosis (CES) has been reported as a rare comorbidity in patients with EA [2]. CES causes symptoms such as vomiting and dysphagia, which are easily misunderstood as symptoms of anastomotic stricture after EA is repaired. Therefore, inappropriate treatment is often carried out before the correct diagnosis is established. CES has various causes, among which stenosis due to a tracheobronchial remnant (TBR) is particularly rare [3]. Herein, we report a case of EA/tracheo-esophageal fistula (EA-TEF) with an associated TBR.

A 2,700 g female, 4 days of age, was hospitalized due to vomiting milk. A physical examination showed abundant saliva and a non-distended abdomen. It was not possible to insert a nasogastric tube, and the diagnosis of EA was then considered. An esophagogram and reconstructed computed tomography (CT) scan showed EA without TEF (Fig. 1A). The upper pouch of the esophagus was at the T3 level. At the age of 7 days, a right-side posterolateral thoracotomy was performed through the fourth intercostal space, and an end-to-end anastomosis for the esophagus was created. Furthermore, a TEF was found during the operation and it was properly resected. A nasogastric tube was then successfully inserted into the stomach. At the age of 16 days, a postoperative esophagogram was conducted, and no signs of anastomotic stricture or anastomotic leak were observed. The patient was discharged, and symptoms such as vomiting and dysphagia were not present at follow-up.

Received: September 6, 2018, Revised: November 14, 2018, Accepted: November 21, 2018, Published online: June 5, 2019

Corresponding author: Chun Wu, Department of Cardiothoracic Surgery, Children's Hospital of Chongqing Medical University, No.136 Zhongshan Second Road, Yuzhong District, Chongqing 400014, China
(Tel) 86-18883883009 (Fax) 86-18883883009 (E-mail) wuchun007@sina.com

© The Korean Society for Thoracic and Cardiovascular Surgery. 2019. All right reserved.

© This is an open access article distributed under the terms of the Creative Commons Attribution Non-Commercial License (<http://creativecommons.org/licenses/by-nc/4.0>) which permits unrestricted non-commercial use, distribution, and reproduction in any medium, provided the original work is properly cited.

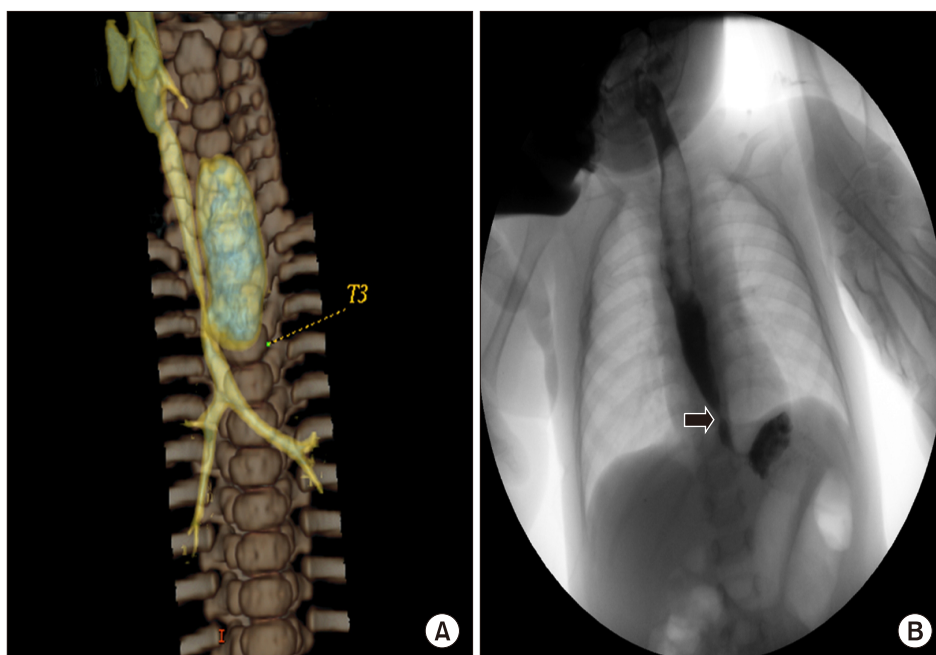


Fig. 1. (A) Reconstructed computed tomography before the first end-to-end anastomosis for esophageal atresia. (B) The esophagogram showed a tapered narrowing 2-3 cm above the cardia (an arrow indicates the narrowing lesion).

At the age of 13 months, the patient was readmitted due to vomiting after being fed solid food. An esophagogram showed esophageal stenosis 2-3 cm above the cardia and a tapered narrowing in the lower segment (Fig. 1B). Since the distance between the stenotic region and cardia was shorter than 5 cm according to the esophagogram, a left subcostal laparotomy was performed and the stenotic part of the esophagus was identified at 2 cm above the cardia, with a width of 5 mm. Manual palpation suggested that the stenotic part was rigid and formed a semi-loop. The combination of preoperative esophagography and intraoperative findings led us to strongly suspect TBR in this case. The stenotic part of the esophagus was resected, as we described in a previous study [4]. The anterior wall of the esophagus was opened longitudinally and the posterior wall was preserved intact. The stenotic part was then excised and the anterior wall of the esophagus was sutured horizontally (Fig. 2). Fundoplication was not necessary since the cardia was not involved. The operative time was 65 minutes and no complications after surgery were observed. An esophagogram performed 7 days after surgery showed that the anastomosis was mildly stenotic and that barium contrast passed through smoothly. No sign of GERD or anastomotic leak was observed. The pathologic examination of the resected specimens revealed the presence

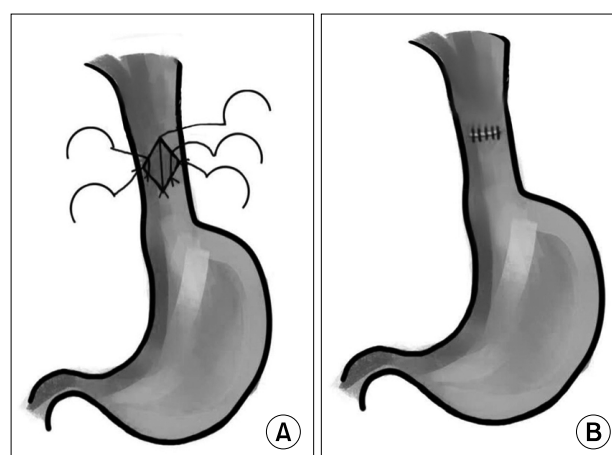


Fig. 2. Surgical procedure of our approach. (A) The anterior wall of the esophagus was cut longitudinally and the posterior wall was preserved intact. (B) The stenotic part was excised and the anterior wall of the esophagus was sutured horizontally.

of a TBR. Islands of cartilage and seromucous glands were found in the submucosal and muscular layers (Fig. 3). The patient was discharged 9 days after the second operation, and esophageal dilation was performed 1 month and 3 months after discharge due to anastomotic stricture. No further vomiting of solid food has been observed in this patient, and she is still receiving close follow-up.

The written informed consents were obtained.

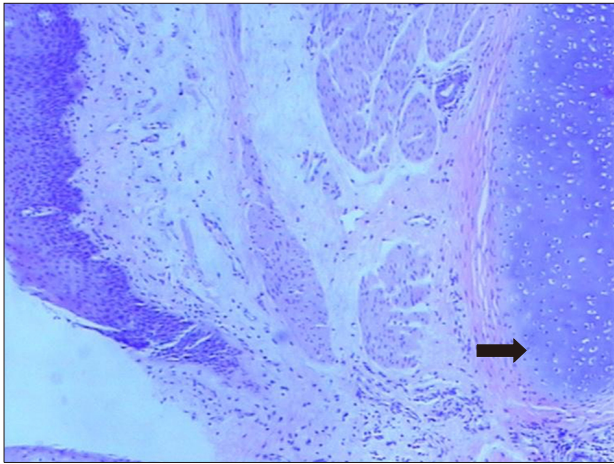


Fig. 3. Pathologic presence of tracheobronchial remnant (H&E, ×40). An arrow indicates the cartilage tissue.

Discussion

EA associated with CES is extremely rare. Holder et al. [2] reported that CES was found in only 3 of 1,058 EA-TEF patients. As an uncommon cause of CES, EA associated with TBR has rarely been reported in the literature. Yoo et al. [5] reported 7 cases of EA associated with TBR, which is the largest sample size to date. Traditionally, TBR patients undergo resection and end-to-end anastomosis. However, unlike the traditional surgical approach, we performed a new surgical approach for this patient with suspected TBR. In our case, the anterior wall of the esophagus was cut longitudinally and the posterior wall was preserved intact. The stenotic part was excised and the anterior wall of the esophagus was sutured horizontally. With this technique, the blood supply of the anastomosis can be preserved as much as possible to reduce the incidence of anastomotic leakage after operation. Moreover, the cardia is not involved and GERD can be avoided when the stenotic segment is close to the cardia. In our opinion, resection with end-to-end anastomosis is not necessary if the stenotic part is a semi-loop of cartilage. We previously reported a case series of 34 TBR patients [4], all of whom presented with a semi-loop of cartilage. The surgical approach described above was performed in 33 cases with satisfactory outcomes. Although anastomotic stenosis was found in 8 patients after surgery, they recovered after esophageal dilation was performed 1–3 times. In this patient,

stenosis was relieved by performing esophageal dilation twice. In our previous study, all patients were diagnosed with isolated TBR, and none of those cases were associated with EA. Therefore, this is the first case of EA associated with a TBR that we have encountered.

It is difficult to diagnose EA and CES simultaneously before initial surgery for EA. In our case, we did not identify the esophageal stenosis on the esophagogram and reconstructed CT scan before EA repair. Furthermore, at the end of the surgery for EA, a nasogastric tube was successfully inserted into the stomach. Therefore, insertion of a nasogastric tube into the stomach does not necessarily exclude CES.

An esophagogram is the most crucial examination for diagnosing TBR, and stenosis in the lower third of the esophagus is often observed. The pendulum sign or mouse-tail sign indicates TBR, along with a tapered narrowing on the esophagogram [4]. However, Suzuhigashi et al. [6] reported that a tapered narrowing was not necessarily related to TBR. The type of CES is important for determining the treatment strategy, and inappropriate treatment can lead to severe complications. For instance, esophageal dilation can cause perforation in patients with TBR. Therefore, endoscopic ultrasonography (EUS) should be considered when the type of CES is difficult to clarify, since it has been reported to be an effective tool for determining the type of CES [7]. Although EUS is not a common diagnostic examination in pediatric patients, it should be considered as a way to classify CES before treatment. Other methods have also been reported to assist in the diagnosis of EA associated with CES. Ibrahim et al. [8] reported that histologic examination of the lower esophageal pouch during repair of EA was a novel technique that helped diagnose EA associated with CES.

In summary, early diagnosis of EA associated with TBR is difficult. It is important to identify whether symptoms such as vomiting and dysphagia after EA repair are caused by an anastomotic stricture or concomitant TBR. Esophagography plays a crucial role in the diagnosis of TBR. The new surgical approach that we have reported should be considered in TBR patients when the stenotic part is a semi-loop of cartilage.

Conflict of interest

No potential conflict of interest relevant to this article was reported.

ORCID

Yuhao Wu: <https://orcid.org/0000-0003-2475-8820>

Chun Wu: <https://orcid.org/0000-0001-9263-7938>

References

1. Rothenberg S. *Thoracoscopic repair of esophageal atresia and tracheo-esophageal fistula in neonates: the current state of the art*. *Pediatr Surg Int* 2014;30:979-85.
2. Holder TM, Cloud DT, Lewis JE Jr, Pilling GP 4th. *Esophageal atresia and tracheoesophageal fistula: a survey of its members by the surgical section of the American Academy of Pediatrics*. *Pediatrics* 1964;34:542-9.
3. Yeung CK, Spitz L, Brereton RJ, Kiely EM, Leake J. *Congenital esophageal stenosis due to tracheobronchial remnants: a rare but important association with esophageal atresia*. *J Pediatr Surg* 1992;27:852-5.
4. Wang Y, Wu C, Pan Z, et al. *Diagnosis and treatment of 34 cases of congenital tracheobronchial cartilage remnants of esophagus*. *J Pediatr Surg* 2018;53:2136-9.
5. Yoo HJ, Kim WS, Cheon JE, et al. *Congenital esophageal stenosis associated with esophageal atresia/tracheoesophageal fistula: clinical and radiologic features*. *Pediatr Radiol* 2010;40:1353-9.
6. Suzuhigashi M, Kaji T, Noguchi H, et al. *Current characteristics and management of congenital esophageal stenosis: 40 consecutive cases from a multicenter study in the Kyushu area of Japan*. *Pediatr Surg Int* 2017;33:1035-40.
7. Terui K, Saito T, Mitsunaga T, Nakata M, Yoshida H. *Endoscopic management for congenital esophageal stenosis: a systematic review*. *World J Gastrointest Endosc* 2015;7:183-91.
8. Ibrahim AH, Al Malki TA, Hamza AF, Bahnassy AF. *Congenital esophageal stenosis associated with esophageal atresia: new concepts*. *Pediatr Surg Int* 2007;23:533-7.