

Safety and efficacy of sodium cromoglycate-fluorometholone fixed combination eye drops in allergic conjunctivitis

Saeed Alwadani

Access this article online
Quick Response Code:

Website: www.saudijophthalmol.org
DOI: 10.4103/sjopt.sjopt_208_21

Abstract:

PURPOSE: This study aimed to assess the efficacy and safety of sodium cromoglycate with fluorometholone in patients with allergic conjunctivitis.

METHODS: We conducted a single-arm phase IV open-label trial where fifty patients who received the eye drops were followed for 4 weeks. Treatment efficacy was assessed using the ocular itching score, conjunctival assessment score, total symptom and sign (TSS) score, and Visual Analog Scale (VAS).

RESULTS: Patients who received sodium cromoglycate-fluorometholone eye drops experienced significant improvements in their ocular itching score (mean difference [MD]: 1.14, $P < 0.001$) and conjunctival redness score (MD: 1.18, $P < 0.001$). Statistically significant improvements in TSS and VAS were achieved in 78% of the patients reporting no conjunctivitis by the end of the study. The overall therapeutic response to the drug was as follows: 16% improved and 84% much improved. No serious adverse events were reported.

CONCLUSION: Sodium cromoglycate with fluorometholone eye drops achieved 100% therapeutic response among patients with allergic conjunctivitis. The eye drops improve the ocular itching, and conjunctival irritation without serious adverse events. This combination appears effective and tolerable for treatment of allergic conjunctivitis.

Keywords:

Allergic conjunctivitis, fluorometholone, sodium cromoglycate

INTRODUCTION

Allergic conjunctivitis affects about one-fifth of the Western population. It is caused by the exposure to seasonal or perennial allergens. The most common symptom of allergic conjunctivitis is ocular itching.^[1,2] Allergic conjunctivitis is strongly associated with allergic rhinitis which is also called hay fever. Almost 90% of allergic conjunctivitis patients suffer from frequent episodes of ocular problems at least 1 day a week.^[3] Therefore, the cornerstone of the management of ocular hypersensitivity is the use of anti-allergic drugs as mast cell stabilizers, antihistamines, and corticosteroids.^[4,5] These drugs are currently used for the treatment of allergic conjunctivitis and hay fever. However, it is suggested that the

combination of two therapeutic agents might have an additional therapeutic benefit.

Sodium cromoglycate is a mast cell stabilizer that prevents type I allergic reactions, and therefore, it might alleviate the ocular signs and symptoms of hay fever, acute and chronic, and vernal keratoconjunctivitis. Moreover, it is suggested to decrease the need for supplementary oral antihistamines.^[6] Sodium cromoglycate eye drops are widely prescribed for the treatment of allergic eye diseases and allergic rhinitis.^[6-8] Fluorometholone is a steroid used to treat the eye inflammation. In a clinical study, the combination of fluorometholone and bromfenac sodium achieved an improvement in the ocular signs and symptoms and the global evaluation scale of patients with allergic conjunctivitis.^[9] In 2013, fluorometholone (0.1%) was compared with topical pranoprofen (0.1%) in patients with

This is an open access journal, and articles are distributed under the terms of the Creative Commons Attribution-NonCommercial-ShareAlike 4.0 License, which allows others to remix, tweak, and build upon the work non-commercially, as long as appropriate credit is given and the new creations are licensed under the identical terms.

For reprints contact: WKHLRPMedknow_reprints@wolterskluwer.com

How to cite this article: Alwadani S. Safety and efficacy of sodium cromoglycate-fluorometholone fixed combination eye drops in allergic conjunctivitis. Saudi J Ophthalmol 2022;36:107-12.

Department of Ophthalmology,
College of Medicine, King
Saud University, Riyadh,
Saudi Arabia

Address for correspondence:
Dr. Saeed Alwadani,
Department of Ophthalmology,
College of Medicine, King
Saud University, Riyadh,
Saudi Arabia.

E-mail: alwsaeed@ksu.edu.sa

Submitted: 07-Sep-2021

Revised: 17-Oct-2021

Accepted: 28-Nov-2021

Published: 11-Jul-2022

chronic allergic conjunctivitis; fluorometholone provided quicker reliefs compared to topical pranopfen. Furthermore, the effect of fluorometholone was more pronounced in younger patients.^[10]

We performed this open-label study to assess the safety and efficacy of combination sodium cromoglycate and fluorometholone eye drops in patients with allergic conjunctivitis.

METHODS

We followed the Transparent Reporting of Evaluations with Nonrandomized Designs statement guidelines when reporting this manuscript.^[11] This study was approved by the Ethics Committee of King Saud University College of Medicine. The trial was performed in compliance with the recommendations of the 18th World Health Congress (Helsinki, 1964) and all applicable amendments.^[12] All patients gave written informed consent prior to the enrollment.

We conducted a single-arm, phase 4 open-label clinical trial within the period from March to October 2016. Patients who met the following inclusion criteria were recruited: age 12–65 years; ≥ 4 episodes of chronic allergic conjunctivitis, defined as ≥ 4 episodes of severe itching, conjunctiva hyperemia, and increased lacrimation lasting ≥ 3 days/year; ocular itching assessment Grade ≥ 2 and the conjunctival redness assessment Grade ≥ 2 ; no contact lenses; and ability to instill eye drops independently. Patients who met any of the following criteria were excluded: pregnancy or breastfeeding; use of other anti-allergic medications during or 3 days prior to study entry; symptoms and signs or risk factors for glaucoma; history of hypersensitivity to any of the components of the study medication; bacterial, viral, or fungal infection of either eye; significant cardiovascular, hepatic, or renal comorbidity; and ocular surgery within 6 months that preceded study enrollment.

Study process, follow-up, and evaluations

Following a screening period of 3 days, eligible patients self-administered a single drop of sodium cromoglycate-fluorometholone (trade name: Fluca) into the conjunctival sac of the eye(s) four times daily over a 14-day study period. Each milliliter contains 20 mg of sodium cromoglycate and 1 mg of fluorometholone, corresponding to 1 mg of sodium cromoglycate and 0.05 mg of fluorometholone per eye drop. Patients were evaluated for the ocular itching score, conjunctival assessment score, Visual Analog Scale (VAS), and total symptom and sign score (TSSS). The TSSS was based on subjective evaluation of the severity of itching and lacrimation, and examiner evaluation of redness and swelling – 0 = absent, 1 = mild, 2 = moderate, and 3 = severe.

At the baseline (day 0), the physician evaluated the symptoms and signs of allergic conjunctivitis. This assessment was repeated in each visit during the treatment period. Treatment

compliance was monitored by reviewing patients' diaries. Furthermore, the total number of doses and instillations administered or missed was recorded by the study coordinator on the patient's case report form.

At the end of the study, patients' diaries were kept at the study center as part of the source documentation records. Rescue medication consumption was also monitored by reviewing the patients' diaries.

Efficacy assessment

On baseline (day 0) and at follow-up visits, the physician evaluated allergic conjunctivitis symptoms (itching, tearing, burning, and redness) and signs (conjunctival erythema, conjunctival edema, and eyelid edema).

The primary efficacy endpoints were a reduction of $>25\%$ in ocular itching score from baseline to the first follow-up visit.

Ocular itching score

At least 25% reduction (1 Grade decrease) in the ocular itching score from baseline to the first follow-up visit was calculated using the ocular itching assessment grades as follows:

- Grade 0: None or itching in one canthus or corner of the eye
- Grade 1: An intermittent tickle sensation involving more than just the corner of the eye
- Grade 2: Moderate, diffuse continuous itch with the desire to rub which can be controlled voluntarily
- Grade 3: A severe itch with the desire to rub which cannot be controlled voluntarily
- Grade 4: Incapacitating itch with an irresistible urge to rub which interferes with the routine lifestyle of the subject.

Conjunctival redness scores

At least 25% decrease (1 Grade decrease) in the mean conjunctival redness score from baseline to the first follow-up visit was calculated using conjunctival redness assessment grades which are interpreted as follows:

- Grade 0: None
- Grade 1: Mild – Slightly dilated blood vessels; the color of vessels is typically pink
- Grade 2: Moderate – More apparent dilation of blood vessels; vessel color is more intense (redder); redness involves most of the vessel bed
- Grade 3: Severe – Numerous and obvious dilated blood vessels; in the absence of chemosis, the color is deep red, maybe less red or pink in the presence of chemosis.

Secondary efficacy endpoint

1. The change in the VAS (0 to 100 mm) for assessment of symptom tolerance where “0” implies no symptoms and “100” implies severe, intolerable symptoms, and it was calculated with the help of VAS
2. The overall therapeutic response assessed, from the investigator's point of view, using a scale of 0–2 where 0 = no improvement, 1 = improved, and 2 = much improved

3. The overall reduction in the TSSS from baseline to the end of our study based on the following scores: 0 = absent, 1 = mild, 2 = moderate and 3 = severe.

Safety assessment

All patients were monitored for any adverse events (AEs). Safety was expressed as the incidence and severity of AEs either reported by the subject or discovered by investigator questioning, physical examination, or clinical laboratory evaluations during follow-up visits.

Sample size and power calculation

The sample size was calculated to detect 25% reduction in the mean ocular itching score from baseline to day 14. To detect this reduction with 80% statistical power and 5% margin of error in a population with a standard deviation of 1.2% from the baseline, fifty subjects were required.

Statistical analysis

Categorical variables were summarized as frequencies and percentages. Data normality was tested by the Kolmogorov–Smirnov test. Continuous variables were summarized as mean and standard deviation in the case of normally distributed data or median and interquartile range for nonnormally distributed data.

The frequency and percentage of patients with AEs were tabulated by treatment group, body system, severity, and relationship to the study medication. Data of the primary and secondary outcomes were summarized using appropriate summary statistics, i.e., the number of patients, mean, standard deviation, median, and range of the TSSS. The changes from baseline in the efficacy measures and the overall therapeutic responses were calculated. An alpha level below 0.05 was considered for statistical significance.

RESULTS

Characteristics of the study population

Fifty patients were enrolled in this study. Most of them were males (64%) with a mean age of 31.87 (\pm 9.6) years. The mean body mass index of the patients was 26.47 \pm 4.7 kg/m². The characteristics of the study population are shown in Table 1.

Ocular itching score

There was a statistically significant reduction in the mean ocular itching scores. The mean ocular itching score was 2.3 \pm 0.5 at visit one. By the end of the study, patients scored 0.2 \pm 0.5. All in all, 98% of the participants have achieved at least one grade reduction in ocular itching score, and the mean difference (MD) between the first and last visits was 1.1 (95% confidence interval: 1.0–1.3).

Conjunctival redness score

There was a statistically significant reduction in the mean conjunctival assessment score from the baseline till the last follow-up visit (MD = 1.2, P < 0.001). Change in conjunctival redness scores from baseline to each visit is shown in Figure 1.

Table 1: Characteristics of study participants

Characteristic	Value
Male, <i>n</i> (%)	32 (64)
Age (year) \pm SD	31.9 \pm 9.6
Weight (kg) \pm SD	71.5 \pm 13.3
Height (m) \pm SD	164.3 \pm 7.4
BMI (kg/m ²) \pm SD	26.5 \pm 4.7
Ocular itching assessment score, <i>n</i> (%)	2.340(48)
Grade 2	33 (66)
Grade 3	17 (34)
Conjunctival redness assessment score, <i>n</i> (%)	2.36 (0.49)
Grade 2	32 (64)
Grade 3	18 (36)
VAS score, <i>n</i> (%)	3.3 (0.54)
Mild conjunctivitis	1 (2)
Moderate conjunctivitis	41 (82)
Severe conjunctivitis	8 (16)

Categorical variables are summarized as frequencies and percentages (*n*,%) while continuous variables are presented as mean \pm SD. BMI: Body mass index, VAS: Visual Analog Scale, SD: Standard deviation

Visual Analog Scale score

There was a significant reduction in VAS scores from the second visit to the last follow-up visit. By the end of the study, 78% of the patients reported no conjunctivitis, as shown in Figure 2.

Therapeutic response

The overall therapeutic response at the end of the study was 100%, with 84% of the patients reporting significant improvement in symptoms and 16% reporting mild-moderate improvement [Figure 3].

Total symptom and sign score

By the end of the study, there were statistically significant improvements from visit 2 in the symptoms of chronic conjunctivitis (0.17 vs. 2.2), and signs of chronic allergic conjunctivitis (0.09 vs. 1.5). The mean TSSS scores are shown in Figure 4.

Treatment compliance

Patients receiving the study drug showed a high percentage of compliance. Compliance was 100% in all participants.

Adverse events

There were no serious adverse events or deaths reported by any of the participants.

DISCUSSION

Our study evaluated the efficacy and safety of the sodium cromoglycate-fluorometholone eye drops, a combination of sodium cromoglycate (20 mg/ml) and fluorometholone (1 mg/ml), for patients with allergic conjunctivitis. In terms of the ocular itching score, conjunctival redness score, VAS, TSSS, and the overall therapeutic response, sodium cromoglycate-fluorometholone eye drops were effective in relieving the symptoms and signs of allergic conjunctivitis fever, with no serious adverse events indicating that the drug was safe in the population. Ninety-eight percent

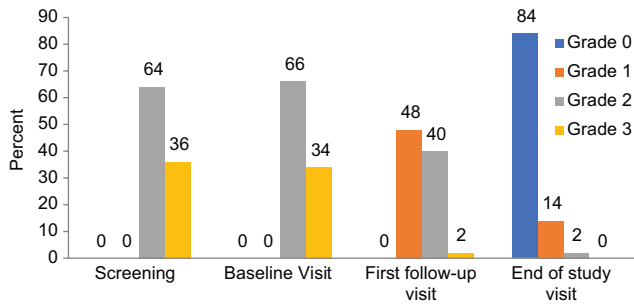


Figure 1: Conjunctival redness score in patients with allergic conjunctivitis who received sodium cromoglycate-fluorometholone fixed combination eye drops

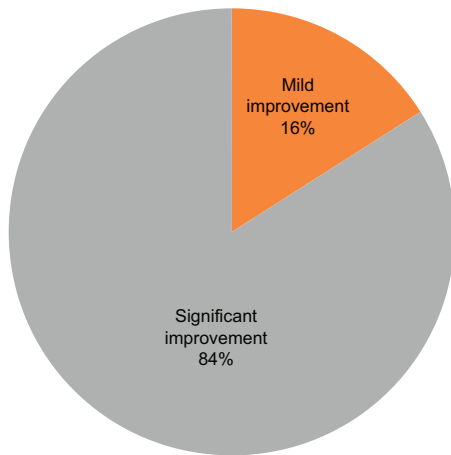


Figure 3: Overall therapeutic response for sodium cromoglycate-fluorometholone fixed combination eye drops in allergic conjunctivitis

of the subjects achieved at least one grade reduction in terms of the ocular itching score and conjunctival redness assessment score. The overall therapeutic response was recorded at the end of the study, with a percentage of 84% of the patients achieving a therapeutic response of “much improved.” The TSSS of allergic conjunctivitis (itching, lacrimation, redness, and swelling) was significantly alleviated by the end of the study. At the last visit, 78% of the patients reported no conjunctivitis.

The efficacy achieved by the sodium cromoglycate-fluorometholone eye drops can be explained by the mechanism of actions of the two agents: sodium cromoglycate and fluorometholone. Sodium cromoglycate is a mast cell stabilizer that prevents type I allergic reactions, and therefore, it might alleviate the ocular signs and symptoms of acute and chronic allergic conjunctivitis, and vernal keratoconjunctivitis.^[6-8,13] While fluorometholone is a steroid used to treat inflammation of the allergic and papillary conjunctivitis.^[10,14-16] Sodium cromoglycate-fluorometholone eye drops are a combination of sodium cromoglycate (20 mg/ml) and fluorometholone (1 mg/ml) for the treatment of chronic allergic conjunctivitis and vernal keratoconjunctivitis.

In 1992, a multicenter study evaluated the efficacy and short-term safety of lodoxamide 0.1% eye drops with sodium cromoglycate

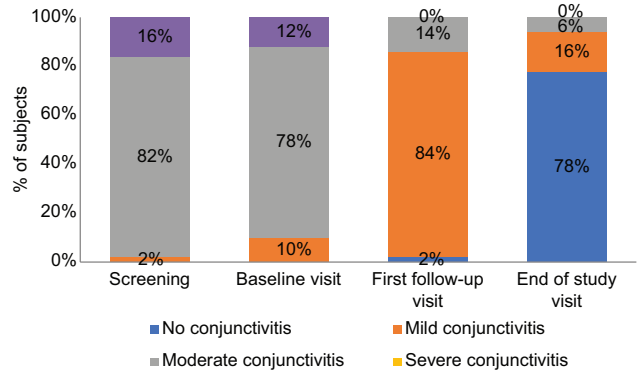


Figure 2: Visual Analog Scale score per visit in patients with allergic conjunctivitis who received sodium cromoglycate-fluorometholone fixed combination eye drops

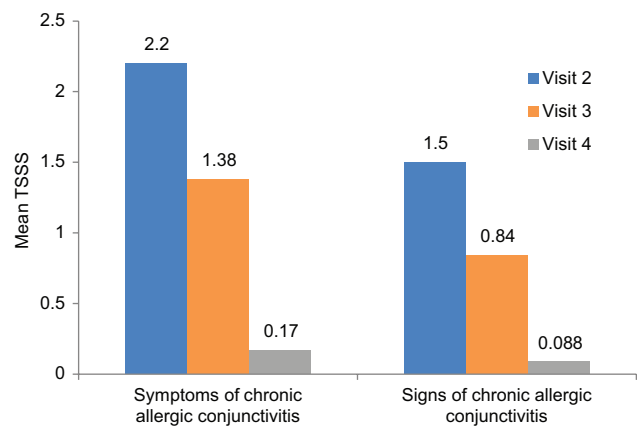


Figure 4: Mean total symptom and sign score in patients with allergic conjunctivitis who received sodium cromoglycate-fluorometholone fixed combination eye drops

2% eye drops, and it showed a significantly more rapid and greater improvement in symptoms and signs of allergic conjunctivitis than patients given sodium cromoglycate 2%.^[17] Furthermore, in 1997, Leonarda *et al.* investigated the efficacy of lodoxamide and disodium cromoglycate in patients with keratoconjunctivitis, and they declared that lodoxamide significantly reduced eosinophil cationic protein tear levels, and it was more effective than sodium cromoglycate in reducing clinical signs and symptoms.^[18] Similarly, in 1998, Akman *et al.* showed that disodium cromoglycate 2% and fluorometholone 0.1% were effective in reducing the leukotriene B4 and leukotriene C4 levels in thirty patients with vernal keratoconjunctivitis.^[19] In a prospective study, bromfenac sodium 0.1% and fluorometholone 0.02% were compared when concomitantly used with disodium cromoglycate 2.0% for the treatment of 86 patients with allergic conjunctivitis.^[9] In this study, all subjective symptom scores were decreased in both concomitant treatment groups compared with baseline ($P < 0.05$). In addition, more patients preferred the fluorometholone 0.02% as a concomitant medication than bromfenac sodium 0.1%.^[9] It is worth noting that compared to other steroids, fluorometholone has a lower tendency to raise intraocular pressure.^[20]

Another multicenter randomized controlled trial of 240 allergic conjunctivitis patients showed that fluorometholone could improve signs and symptoms of allergic conjunctivitis and was comparable to other treatments as epinastine, ketotifen, and olopatadine.^[21] A German study compared the combination of antazoline/tetryzoline eye drops with levocabastine eye drops in acute allergic conjunctivitis. Antazoline/tetryzoline had a more rapid onset of action (about 30 minutes) and more reductions in subjective and objective ocular symptoms compared to the levocabastine eye drops.^[22]

Our study has several strength points. First, the relatively larger sample size of our study compared to previous reports. Secondly, the prospective nature of the study design allowed observing the disease symptoms on multiple efficacy measures. Finally, participants were not randomized, and they had to self-administer the study drug. However, the study also has limitations. We did not assess corneal signs such as punctate erosions, and grading was not performed for conjunctival or lid edema. Finally, we did not measure intraocular pressure during the period when fluorometholone was being used. Prolonged use of fluorometholone is associated with increased intraocular pressure, and practitioners should inform their patients about this risk.

CONCLUSION

Sodium cromoglycate-fluorometholone eye drops achieved 100% therapeutic response among patients with allergic conjunctivitis. Sodium cromoglycate-fluorometholone eye drops could improve the ocular itching score, conjunctival redness assessment score, VAS pain score, and TSSS without any serious adverse events highlighting that this combination is tolerable and effective for the treatment of allergic conjunctivitis.

Ethical conduct of the study

The protocol complied with the recommendations of the 18th World Health Congress (Helsinki, 1964) and all applicable amendments. The protocol also complied with the laws and regulations, as well as any applicable guidelines, of the Kingdom of Saudi Arabia where the study was conducted.

Patient information and consent

Written informed consent forms (ICFs) for the study participation were obtained from all patients before any protocol-specific procedures were carried out. The ICF was approved by the Independent Ethics Committee and was acceptable to the sponsor. The investigator explained the nature of the study and the action of the study medication. The patients/legally accepted representatives (LARs) were informed that the participation is voluntary and that they can withdraw from the study at any time. The patients/LARs were provided with sufficient time to read and understand the ICF to make informed decisions to participate in the study. In accordance with the Saudi Food and Drug Authority guidelines and applicable regulations, the informed consent was documented and approved by the Ethics Committee and was signed by the patient/LAR prior to performing

any protocol-specific procedures. Furthermore, if new information became available that may be relevant to the patient's willingness to continue participation in the study, this was communicated in a timely manner to the patient/LAR. The communication of this information was provided and documented via a revised consent form or addendum to the original consent form. If the patient/LAR was unable to read and sign the ICF, then the form was signed and dated by an impartial witness who is independent of the investigator. The patient was given a signed copy of the consent form, and the original was maintained with the patient's records.

Acknowledgments

The author would like to acknowledge King Saud University Medical City, King Saud University administrators, and staff for providing a much-needed assistance throughout the course of this research. Thanks are also extended to the colleagues from the Ophthalmology Department who provided insights and expertise that greatly assisted the research and for their comments on an earlier version of the manuscript.

Financial support and sponsorship

Nil.

Conflicts of interest

There are no conflicts of interest.

REFERENCES

- Abelson MB, Shetty S, Korchak M, Butrus SI, Smith LM. Advances in pharmacotherapy for allergic conjunctivitis. *Expert Opin Pharmacother* 2015;16:1219-31.
- Bielory L. Ocular allergy overview. *Immunol Allergy Clin North Am* 2008;28:1-23, v.
- Torkildsen GL, Gomes P, Welch D, Gopalan G, Srinivasan S. Evaluation of desloratadine on conjunctival allergen challenge-induced ocular symptoms. *Clin Exp Allergy* 2009;39:1052-9.
- Carr WW, Nayak AS, Ratner PH, Gow JA, McNamara TR, Williams JI. Bepotastine Besilate Ophthalmic Solution 1.5% (Bepreve) Study Group. Efficacy of bepotastine besilate ophthalmic solution 1.5% for seasonal allergic conjunctivitis: A randomized, placebo-controlled, natural exposure, clinical trial. *Allergy Asthma Proc* 2013;34:247-54.
- Bielory L, Katelaris CH, Lightman S, Naclerio RM. Treating the ocular component of allergic rhinoconjunctivitis and related eye disorders. *MedGenMed* 2007;9:35.
- Sorkin EM, Ward A. Ocular sodium cromoglycate. An overview of its therapeutic efficacy in allergic eye disease. *Drugs* 1986;31:131-48.
- Collum LM, Fitzsimon S, Hillery M, Collum A, Power WJ, Pelikan Z, *et al.* Twice daily 4% Sodium Cromoglycate vs. 2% Sodium Cromoglycate used four times daily in seasonal (grass pollen) allergic conjunctivitis. *Doc Ophthalmol* 1992;82:267-77.
- Lejeune M, Lefebvre PP, Delvenne P, El-Shazly AE. Nasal sodium cromoglycate (Lomusol) modulates the early phase reaction of mild to moderate persistent allergic rhinitis in patients mono-sensitized to house dust mite: A preliminary study. *Int Immunopharmacol* 2015;26:272-6.
- Fujishima H, Fukagawa K, Takano Y, Tanaka M, Okamoto S, Miyazaki D, *et al.* Comparison of efficacy of bromfenac sodium 0.1% ophthalmic solution and fluorometholone 0.02% ophthalmic suspension for the treatment of allergic conjunctivitis. *J Ocul Pharmacol Ther* 2009;25:265-70.
- Li Z, Mu G, Chen W, Gao L, Jhanji V, Wang L. Comparative evaluation of topical pranoprofen and fluorometholone in cases with chronic allergic conjunctivitis. *Cornea* 2013;32:579-82.
- Des Jarlais DC, Lyles C, Crepaz N; TREND Group. Improving the reporting quality of nonrandomized evaluations of behavioral and

- public health interventions: The TREND statement. *Am J Public Health* 2004;94:361-6.
12. Rickham PP. Human experimentation. code of ethics of the world medical association. declaration of helsinki. *Br Med J* 1964;2:177.
 13. Bielory BP, O'Brien TP, Bielory L. Management of seasonal allergic conjunctivitis: Guide to therapy. *Acta Ophthalmol* 2012;90:399-407.
 14. Diao H, She Z, Cao D, Wang Z, Lin Z. Comparison of tacrolimus, fluorometholone, and saline in mild-to-moderate contact lens-induced papillary conjunctivitis. *Adv Ther* 2012;29:645-53.
 15. Celik T, Turkoglu EB. Comparative evaluation of olopatadine 0.01% combined fluorometholone 0.1% treatment versus olopatadine 0.01% combined ketorolac 0.4% treatment in patients with acute seasonal allergic conjunctivitis. *Curr Eye Res* 2014;39:42-6.
 16. Li Z, Chen W, Zhang Y, Jhanji V, Fan Z, Mu G. Topical fluorometholone versus diclofenac sodium in cases with perennial allergic conjunctivitis. *Eye Contact Lens* 2015;41:310-3.
 17. Fahy GT, Easty DL, Collum LM, Benedict-Smith A, Hillery M, Parsons DG. Randomised double-masked trial of lodoxamide and sodium cromoglycate in allergic eye disease. A multicentre study. *Eur J Ophthalmol* 1992;2:144-9.
 18. Leonardi A, Borghesan F, Avarello A, Plebani M, Secchi AG. Effect of lodoxamide and disodium cromoglycate on tear eosinophil cationic protein in vernal keratoconjunctivitis. *Br J Ophthalmol* 1997;81:23-6.
 19. Akman A, Irkeç M, Orhan M. Effects of lodoxamide, disodium cromoglycate and fluorometholone on tear leukotriene levels in vernal keratoconjunctivitis. *Eye (Lond)* 1998;12:291-5.
 20. Pleyer U, Ursell PG, Rama P. Intraocular pressure effects of common topical steroids for post-cataract inflammation: Are they all the same? *Ophthalmol Ther* 2013;2:55-72.
 21. Figus M, Fogagnolo P, Lazzeri S, Capizzi F, Romagnoli M, Canovetti A, *et al.* Treatment of allergic conjunctivitis: Results of a 1-month, single-masked randomized study. *Eur J Ophthalmol* 2010;20:811-8.
 22. Wertheimer R, Blessmann G. Antazoline/tetryzoline eyedrops in comparison with levocabastine eyedrops in acute allergic conjunctivitis. *Klin Monbl Augenheilkd* 1997;210:93-6.