

Received: 2016.05.29  
Accepted: 2016.08.10  
Published: 2016.11.07

ISSN 1941-5923  
© Am J Case Rep, 2016; 17: 830-833  
DOI: 10.12659/AJCR.899791

## Richter's Type of Incarcerated Obturator Hernia that Presented with a Deep Femoral Abscess: An Autopsy Case Report

Authors' Contribution:  
Study Design A  
Data Collection B  
Statistical Analysis C  
Data Interpretation D  
Manuscript Preparation E  
Literature Search F  
Funds Collection G

CDEF 1 **Satoru Yonekura**  
B 2 **Masaaki Kodama**  
A 1 **Shunichi Murano**  
B 3 **Hirohisa Kishi**  
ABCDE 4 **Akihiro Toyoda**

1 Department of Endocrinology, Tochigi Medical Center Shimotsuga, Tochigi City, Tochigi, Japan  
2 Department of Surgery, Tochigi Medical Center Shimotsuga, Tochigi City, Tochigi, Japan  
3 Department of Surgical Pathology, Douai Kinen Hospital, Tokyo, Japan  
4 Department of Surgical Pathology, JA Kouseiren Kamitsuga General Hospital, Kanuma, Tochigi, Japan

**Corresponding Author:** Satoru Yonekura, e-mail: [yonechian+md@gmail.com](mailto:yonechian+md@gmail.com)  
**Conflict of interest:** None declared

**Patient:** Female, 89  
**Final Diagnosis:** Obturator hernia  
**Symptoms:** Coxalgia • femoral abscess • gait disorder  
**Medication:** —  
**Clinical Procedure:** —  
**Specialty:** Surgery

**Objective:** Unusual clinical course  
**Background:** Richter's obturator hernia is a rare abdominal hernia that is difficult to diagnose. The purpose of this case report is to show an unusual presentation of a fatal Richter's obturator hernia that was accompanied by a femoral abscess.





**Case Report:** An 89-year-old woman complained of sudden left coxalgia and a gait disorder but no abdominal symptoms. She had no history of trauma or surgery in the inguinal area. Twenty-three days after her first complaint of coxalgia, the patient was admitted in a coma with necrotizing fasciitis in the left inguinal area. The patient died of asystole due to hyperkalemia. During surveillance for the cause of death, a Richter's type of incarcerated obturator hernia was identified at autopsy. The incarcerated small intestine had penetrated into the left obturator foramen to form an abscess that extended into the deep femoral region.

**Conclusions:** Obturator hernia accompanied by femoral abscess is extremely rare, but it should be suspected when a patient with no history of trauma or surgery has a femoral abscess, even in the absence of abdominal symptoms.

**MeSH Keywords:** Abscess • Autopsy • Hernia, Obturator

**Abbreviations:** OH – obturator hernia; T-A compound – compound of tramadol hydrochloride and acetaminophen; NF – necrotizing fasciitis

**Full-text PDF:** <http://www.amjcaserep.com/abstract/index/idArt/899791>

 1311   3  15



## Background

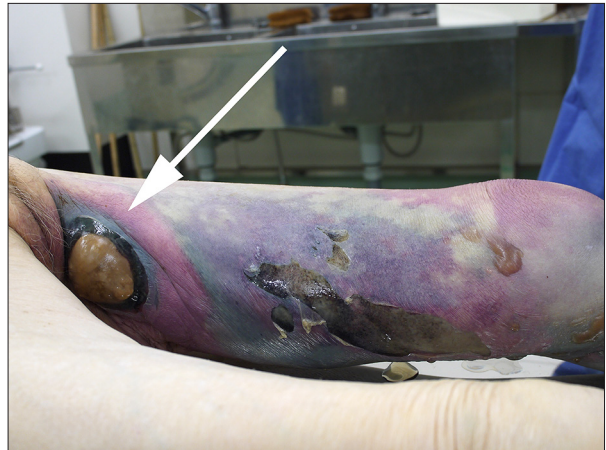Richter's obturator hernia (OH) is a rare abdominal hernia that accounts for 0.05–0.4% of all abdominal hernias [1–3]. Because it presents without any clear signs or symptoms, unless a computed tomography (CT) scan is performed, it is difficult to diagnose; therefore, surgical intervention in the early stages rarely occurs [4,5]. Here we present an atypical case of a femoral abscess, which was not suspected to be associated with OH, but at autopsy it was revealed to be the result of an OH perforation.

## Case Report

An 89-year-old woman visited our emergency room (ER) with complaints of sudden left coxalgia and a gait disorder. Her past medical history included osteoporotic vertebral collapse (Th12) and spondylolisthesis (L2), and she had undergone total gastrectomy due to gastric cancer 7 years prior. She regularly visited her orthopedist, and she was prescribed felbinac-containing patches for her chronic back pain. Thirty-three days prior to her first visit to our ER, she was also prescribed a 2-week course of a compound of tramadol hydrochloride and acetaminophen (T-A compound) for pain, and domperidone for possible side effects of the T-A compound. Despite these treatments, she began to complain of nausea and constipation, so her prescription was changed to pregabalin 5 days before she visited our ER.

Her vitals were stable. Therefore, the ER doctor did not perform a blood test with low suspicion of acute inflammatory disease. On physical examination, abdominal distention was not observed, and she did not complain of bowel dysfunction. Her complaint was focused on left coxalgia, but visual examination and palpation revealed nothing abnormal on the pelvic and femoral areas. Costovertebral angle knocking pain was not observed. Dorsalis pedis arteries were bilaterally palpable. Plain abdominal X-rays did not reveal any signs of gastrointestinal diseases, nor new fractures of the pelvis and/or the vertebra. Genital and rectal examinations were not performed because the ER doctor did not suspect any gynecologic, rectal, or urologic diseases. The ER doctor suspected her symptoms were due to peripheral neuralgia aggravated by osteoporotic vertebral collapse and spondylolisthesis. She was prescribed loxoprofen sodium hydrate.

However, she arrived at our ER again in a coma-like state 23 days after her first visit to our hospital. According to her family, she did not have any history of trauma or surgery in the inguinal area. Her Glasgow Coma Scale score was evaluated as 3/15 (E1V1M1). On clinical assessment, her temperature was 35.8°C, her heart rate was regular at 93 beats per minute,



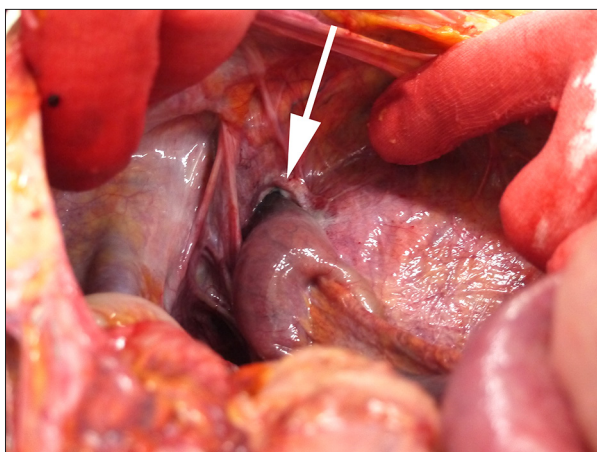
**Figure 1.** Postmortem appearance of the patient's left thigh. A red to purple-colored discoloration with flaccid blisters is visible. Note the balloon-like swelling with brown to purple discoloration (white arrow). This area is the subdermal pneumatosis, indicating gas-gangrene.

and her blood pressure was 174/93 mm Hg. Physical examination revealed there was a 5×5 cm abscess that demonstrated gas-containing swelling with erythema and necrosis in her left proximal femoral region (Figure 1).

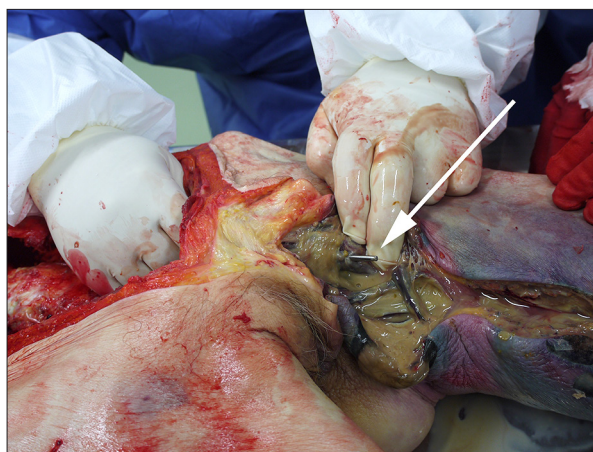
Her blood test results were as follows: hemoglobin 14.5 mg/dL, leukocyte count 27,600 cells/ $\mu$ L, neutrophil count 25,778 cells/ $\mu$ L, urea 73 mmol/L, creatinine 1.94 mg/dL, potassium 7.6 mmol/L, sodium 140 mmol/L, and C-reactive protein 25.05 mg/dL. Plain abdominal X-ray revealed a small amount of gas in the inguinal region. At that time, she was diagnosed with gas-gangrenous fasciitis of the left femoral region with hyperkalemia due to that condition.

The patient was treated with calcium gluconate and insulin with 5% dextrose in order to reduce the hyperkalemia; however, she went into asystole and died. The patient's asystole was due to hyperkalemia because of rhabdomyolysis of the left femoral region caused by gas-gangrenous fasciitis. However, the cause of the gas-gangrenous fasciitis was still unclear. Consent for a full body autopsy was obtained from the family members, and an autopsy was performed in order to make a definite diagnosis of the cause of the femoral fasciitis.

The autopsy revealed that the small intestine was incarcerated in the left obturator foramen as a Richter's hernia with partial necrosis and penetration into the left obturator foramen (Figure 2). A gas-containing abscess had formed and extended from the left obturator foramen to the deep femoral region (Figure 3). A culture from the pus of the abscess revealed *Escherichia coli*, *Klebsiella oxytoca*, and *Enterococcus* sp. (i.e., enteric flora). No recurrence of the gastric cancer was observed. Therefore, the deep femoral abscess caused by



**Figure 2.** The left obturator hernia is shown (white arrow). From the peritoneal side, the inflammation is less significant as a white coating surrounded by the small intestine (white arrowhead); however, the pelvic side shows penetration of the hernia leading to the disastrous deep femoral abscess.



**Figure 3.** Left obturator hernia, penetrated through the left obturator foramen into the necrotizing fasciitis of the left inguinal-femoral region. The tip of the Kocher's forceps (white arrow) indicates the left obturator foramen through which the left obturator hernia penetrated.

Richter's incarceration of the left OH contributed to gas-gangrenous fasciitis resulting in hyperkalemia, which led to cardiac arrest. Her first symptoms (i.e., left coxalgia and gait disorder) seemed to be connected with the OH.

## Discussion

OH was initially described by Ronsil in 1724 [6]. Richter's hernia is an abdominal hernia in which only a segment of bowel circumference is involved and strangulated in the hernial orifice [7]. The incidence of OH is higher in multiparous and elderly emaciated women than in men because of their wider pelvis, more triangular obturator canal opening, and greater transverse diameter of the obturator canal [4]. OH with a femoral abscess is a rare condition, with only 16 cases having been reported [8].

Early diagnosis of OH is difficult because it usually shows non-specific signs and symptoms that do not contribute to making a diagnosis of OH [4,5]. Up to 80% of patients with OH show symptoms of bowel obstruction, which is often because a high proportion develop Richter's herniation of the bowel into the obturator canal [9]. Compression of the obturator nerve by the hernial sac, which is known as the Howship-Romberg sign, affects 12.5–65.0% of patients [9]. Detecting a mass by external palpation is challenging because the pectineus muscle usually covers the obturator sac; therefore, there is a low frequency of detecting palpable masses [5]. A CT scan is more useful for making a definitive and preoperative diagnosis of OH, with sensitivity and accuracy superior to those of ultrasonography or herniography [4]. Diagnosis of OH can be still difficult even

with abdominal CT when clinical signs and symptoms are subtle [10]. First-choice treatment of OH is a herniorrhaphy via laparotomy. However, more minimally invasive trans-inguinal surgeries have been proposed [11].

In this case, symptoms of bowel obstruction were not clearly recognized, probably because of the patient's medication history. The T-A compound and pregabalin were believed to have masked her abdominal symptoms; her nausea could have been one of the symptoms of bowel obstruction instead of an adverse effect of the T-A compound. The left coxalgia the patient complained of 23 days before her death could have been less recognized by the patient because of the pain medication. The patient seemed not to have noticed the femoral abscess but her family did, only a day before her death. These reasons may be why the diagnosis of OH was delayed.

Delayed diagnosis in this case was due to a low index of suspicion of OH because there were no symptoms of bowel obstruction. In our case, the patient did not have any of these risk factors for necrotizing fasciitis (NF): trauma, fish-fin injury, chronic skin ulcer, burns, post-operative wound infection, insect bite, colcutaneous fistula, a history of drug abuse, or multiple needle punctures at the affected site [12–15]. However, in this case, the obstruction was caused by necrosis of the small bowel due to OH. The NF led to hyperkalemia, which caused asystole and death. We regret that no pelvic CT scan was performed in order to enable suspicion of OH before she developed NF.

OH must be taken into account in the differential diagnosis of abscesses in the femoral area without any history of trauma or surgery, even if abdominal symptoms are not present.

CT scans in cases of suspected OH are necessary because the physical symptoms are not specific, and a delayed diagnosis of OH can eventually cause fatal NF.

## Conclusions

Obturator hernia accompanied by femoral abscess is extremely rare. However, we should keep in mind that a suspicion of

OH is necessary when a patient with no history of trauma or surgery has a femoral abscess, even without any abdominal symptoms.

## Statement

The Ethics Committee of Tochigi Medical Center Shimotsuga approved this report. There are no competing interests involving this report.

## References:

1. Cueto-Garcia J, Rodriguez-Diaz M, Elizalde-Di Martino A, Weber-Sanchez A: Incarcerated obturator hernia successfully treated by laparoscopy. *Surg Laparosc Endosc*, 1998; 8: 71–73
2. Ziegler DW, Rhoads JE Jr: Obturator hernia needs a laparotomy, not a diagnosis. *Am J Surg*, 1995; 170: 67–68
3. Ijiri R, Kanamaru H, Yokoyama H et al: Obturator hernia: The usefulness of computed tomography in diagnosis. *Surgery*, 1996; 119: 137–40
4. Kulkarni SR, Punamiya AR, Naniwadekar RG et al: Obturator hernia: A diagnostic challenge. *Int J Surg Case Rep*, 2013; 4: 606–8
5. Nasir BS, Zendejas B, Ali SM et al: Obturator hernia: The Mayo Clinic experience. *Hernia*, 2012; 16: 315–19
6. Yip AW, AhChong AK, Lam KH: Obturator hernia: A continuing diagnostic challenge. *Surgery*, 1993; 113: 266–69
7. Jayant K, Agarwal R, Agarwal S: Richter type of incarcerated obturator hernia; misery still continues. *Pol Przegl Chir*, 2014; 86: 490–92
8. Kubo N, Yoshizawa Z, Hanaoka T, Nakamura K: A case of a perforated obturator hernia with a femoral abscess treated a pectineus muscle flap. *BMC Surg*, 2015; 15: 107
9. Mantoo SK, Mak K, Tan TJ: Obturator hernia: Diagnosis and treatment in the modern era. *Singapore Med J*, 2009; 50: 866–70
10. Tokushima M, Aihara H, Tago M et al: Obturator hernia: A diagnostic challenge. *Am J Case Rep*, 2014; 15: 280–83
11. Togawa Y, Muronoi T, Kawaguchi H et al: Minimal incision transinguinal repair for incarcerated obturator hernia. *Hernia*, 2014; 18: 407–11
12. Huang WS, Hsieh SC, Hsieh CS et al: Use of vacuum-assisted wound closure to manage limb wounds in patients suffering from acute necrotizing fasciitis. *Asian J Surg*, 2006; 29: 135–39
13. Flandrin A, Rouleau C, Azar CC et al: First report of a necrotising fasciitis of the breast following a core needle biopsy. *Breast J*, 2009; 15: 199–201
14. Tsai YH, Hsu RW, Huang TJ et al: Necrotizing soft-tissue infections and sepsis caused by *Vibrio vulnificus* compared with those caused by *Aeromonas* species. *J Bone Joint Surg Am*, 2007; 89: 631–36
15. Ozalay M, Ozkoc G, Akpınar S et al: Necrotizing soft-tissue infection of a limb: Clinical presentation and factors related to mortality. *Foot Ankle Int*, 2006; 27: 598–605