

# Endoscopic nasogastric tube insertion for treatment of benign afferent loop obstruction after radical gastrectomy for gastric cancer

## A 16-year retrospective single-center study

Yuning Cao, MD<sup>a</sup>, Xiangheng Kong, MD<sup>b,\*</sup>, Daogui Yang, MD<sup>b</sup>, Senlin Li, MD<sup>a</sup>

### Abstract

Afferent loop obstruction is an uncommon complication associated with Billroth-II distal gastrectomy. Inappropriate treatment may result in life-threatening events as perforation and peritonitis. For the benign afferent loop obstruction, Braun or Roux-en-Y reconstruction has been reported as the choice. However, the edematous afferent loop may result in anastomotic fistula. In this study, a less invasive technique was described for treatment of benign afferent loop obstruction. The aim of this study was to investigate the effectiveness and safety of endoscopic nasogastric tube insertion for treatment of benign afferent loop obstruction.

We conducted a retrospective review of the data of 2548 gastric cancer patients who underwent distal gastrectomy from January 2002 to January 2018. Patients who developed benign afferent loop obstruction were treated by this procedure. Outcomes were recorded. Follow-up was scheduled at 3, 6, and 12 months after the treatment.

Twenty-six patients (1.0%) developed afferent loop obstruction. The median age, consisting of 19 men and 7 women, was 60 years (range 36–69 years). Of these 26 patients, 23 underwent the endoscopic treatment. The obstructive symptoms had a rapid relief in all the 23 patients. No one died due to this procedure. However, 2 patients underwent surgical treatment due to intestinal obstruction because of adhesion at >4 and 7 months after the endoscopic drainage, respectively.

Endoscopic nasogastric tube insertion is an effective and safe procedure for treatment of benign afferent loop obstruction. In addition, it could be considered as the first step in treatment, especially in high-surgical-risk patients.

**Abbreviations:** ALO = afferent loop obstruction, CT = computed tomography, PTBD = percutaneous transhepatic biliary drainage, PTDD = percutaneous transhepatic duodenal drainage.

**Keywords:** afferent loop obstruction, Billroth-II reconstruction, nasogastric tube, Roux-en-Y reconstruction

## 1. Introduction

Afferent loop obstruction (ALO) is an uncommon complication associated with Billroth-II reconstruction or Roux-en-Y reconstruction after gastrectomy.<sup>[1]</sup> Various etiologies of ALO have been reported, and the treatment differs between malignant and benign etiologies. For patients in whom this syndrome is due to

malignant obstruction, less invasive, nonsurgical therapy, such as percutaneous transhepatic biliary drainage (PTBD), percutaneous transhepatic duodenal drainage (PTDD),<sup>[2–5]</sup> direct percutaneous tube duodenal enterostomy<sup>[6]</sup> or self-expanding metal stents placement in afferent loop<sup>[7,8]</sup> is preferred because these patients are in poor condition due to the advanced stage of their malignancy. On the contrary, for patients with benign obstruction, surgical intervention including adhesiolysis,<sup>[7]</sup> jejunojunctionostomy with Braun procedure or Roux-en-Y conversion have been recommended as the choice.<sup>[9,10]</sup> However, the dilated afferent loop is edematous that may result in anastomotic fistula after jejunojunctionostomy. Therefore, some treatment with decompression of the afferent loop should be suggested because even if it is not a radical treatment, it can improve the intestinal wall edema and provide a favorable condition for next surgical treatment.

A simple and less invasive technique, endoscopic nasogastric tube insertion into obstructed afferent loop, was described as an alternative treatment for ALO, and the result is reported herein. The main aim of this study was to describe the procedure, and evaluate the safety and effectiveness of this treatment.

## 2. Materials and methods

### 2.1. Patients

We retrospectively reviewed the surgical database of 2548 gastric cancer patients who underwent distal gastrectomy with Billroth-II or Roux-en-Y reconstruction at the Liaocheng people's

Editor: Goran Augustin.

YC and XK are joint first authors.

*Informed consent statement:* Patients were not required to give informed consent to the study because the analysis used anonymous clinical data that were obtained after each patient agreed to treatment by written consent.

The authors have no funding and conflicts of interest to disclose.

<sup>a</sup> Department of Digestion, <sup>b</sup> Department of Gastrointestinal Surgery, Liaocheng People's Hospital, Liaocheng, Shandong Province, China.

\* Correspondence: Xiangheng Kong, Department of Gastrointestinal Surgery, Liaocheng People's Hospital, No. 67 on Dongchang Road, Liaocheng 252000, Shandong Province, China (e-mail: surgok@outlook.com).

Copyright © 2019 the Author(s). Published by Wolters Kluwer Health, Inc. This is an open access article distributed under the terms of the Creative Commons Attribution-Non Commercial-No Derivatives License 4.0 (CCBY-NC-ND), where it is permissible to download and share the work provided it is properly cited. The work cannot be changed in any way or used commercially without permission from the journal.

Medicine (2019) 98:28(e16475)

Received: 11 February 2019 / Received in final form: 23 June 2019 / Accepted: 24 June 2019

<http://dx.doi.org/10.1097/MD.00000000000016475>

hospital, Shandong province, China, between January 2002 and January 2018. Billroth-II or Roux-en-Y reconstruction is routinely performed in an antecolic manner with 10 to 15 cm of the afferent limb. The distance, in Roux-en-Y reconstruction, between the gastrojejunostomy and jejunojejunostomy is 30 to 40 cm. The diagnosis of ALO was confirmed by computed tomography (CT) scan. Patients with ALO caused by malignant lesions or mechanical factors such as internal herniation or adhesion were excluded from this study. This study was approved by Institutional Review Board at Liaocheng people's hospital.

## 2.2. Methods

Patients with ALO who were ruled out diagnosis of malignant and mechanical obstruction by CT were transferred to the endoscopy suite and were treated by endoscopic approach with insertion of a nasogastric tube into the obstructed afferent loop under intravenous sedation. Two methods were used for these procedures.

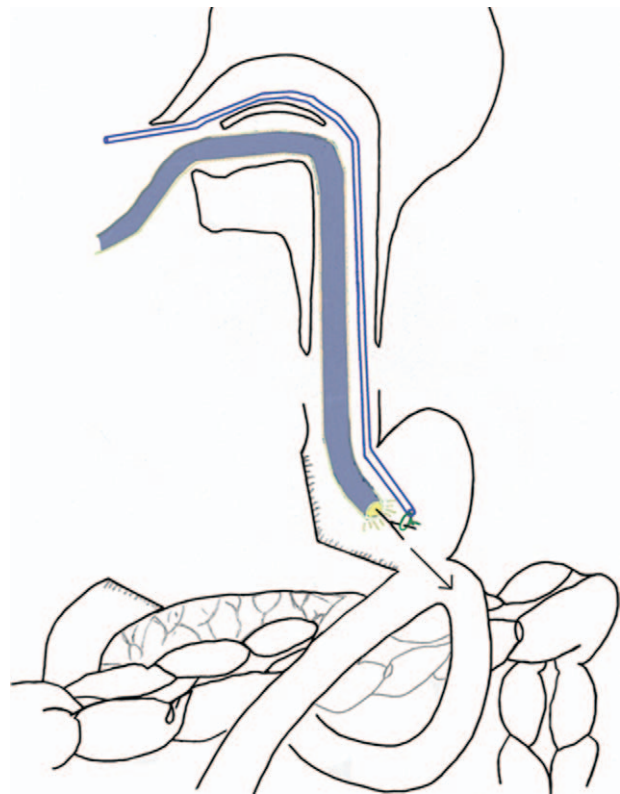
**Method 1:** A long nasogastric tube, 33.3 mm of diameter and 130 cm of the length (Flocare nasogastric tube, Nutricia Co. Ltd., Wuxi, China), was chosen because it was long enough to get to distal end of afferent loop. In this procedure, a suture was tied to the tip of the nasogastric tube, and then the tube was inserted through the nose into the remnant stomach or jejunum. The endoscope was advanced into the stomach or jejunum and an endoscopic biopsy forceps grasped the suture at the tip of the tube. The scope and long tube were advanced from the stomach or jejunum into the afferent loop (Fig. 1). In this procedure, bile and pancreatic juice were extracted immediately by the endoscope for decompression when the scope reached to the dilated afferent loop. Then the scope was removed, and the long nasogastric tube was fixed on the nose and attached to the negative pressure drainage vessel.

**Method 2:** If endoscopic finding revealed a narrowed and swollen entrance of the afferent loop, a guide-wire of 260 cm (0.035-in. Jagwire, Boston Scientific Corporation, Shanghai, China) and an ultrathin transnasal gastroscope (EVIS LUCERA Gastrointestinal Videoscope GIF-XP260N, Olympus Corporation, Shanghai, China) were used to perform this procedure. The guide-wire was inserted through anastomotic stoma of the afferent loop under endoscope first (Fig. 2A). The transnasal gastroscope was then removed leaving the guide-wire in place (Fig. 2B). Finally, the nasogastric tube was advanced along the guide-wire into the afferent loop (Fig. 2C). After intraoperative radiograph was performed for identification of the tube's position (Fig. 2D), the long nasogastric tube was fixed on the nose and attached to the negative pressure drainage vessel.

An oral liquid diet was administered after the procedure. When abdominal pain disappeared, the drainage volume reduced, usually <50 mL in our experience and the non-dilated afferent loop was confirmed by ultrasonography, nasogastric tube was removed.

## 2.3. Follow-up study

Telephone follow-up was scheduled at 3, 6, and 12 months after the treatment, or when the patients developed some clinical symptoms suspected to be related to the treatment. Observations during follow-up mainly included clinical symptoms and sometimes contrast-enhanced CT. The end of follow-up was January 10, 2019.



**Figure 1.** Diagram showed that the endoscope grasped the long nasogastric tube and advanced to the afferent loop.

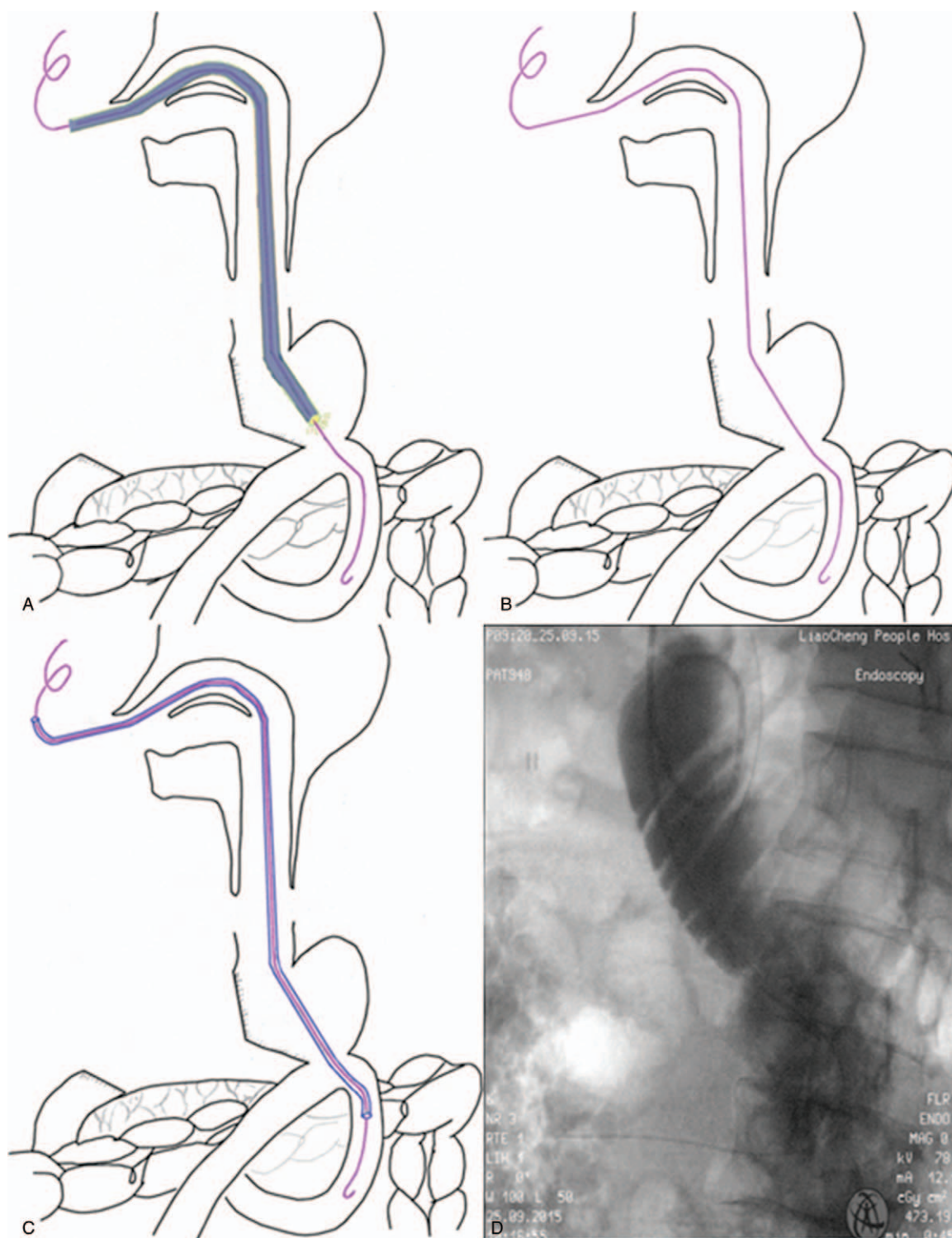
## 2.4. Statistical analysis

Data were collected prospectively by using a computerized database. Quantitative data were given as an overall spread (median) pattern. The categorical data were analyzed by the Pearson chi-square test. The statistical tests were 2-tailed. *P* values of <.05 were considered statistically significant. All calculations and analysis were performed by the SPSS software package version 16.0 (SPSS Inc., Chicago, IL).

## 3. Results

Of the 2548 patients, 26 (1.0%) with ALO were identified and reviewed (Table 1). The median age of the patients, consisting of 19 men and 7 women, was 60 years (range 36–69 years). Twenty-two of the 26 patients had advanced gastric cancer, and the remaining 4 were in the early stage of the disease. The intervals between the initial gastric resections and the diagnosis of ALO ranged from 8 to 43 days (median 14 days). With regard to the reconstruction methods, the incidence of ALO was higher in the Billroth-II group than in the Roux-en-Y group, 1.4% (25/1734) and 0.1% (1/814), respectively, with an odds ratio (OR) of 11.89 (95% CI 1.6–87.90, *P* = .002).

Of these 26 patients with ALO, 23 patients who performed the endoscopic treatment were included in this study, whereas the other 3 patients were excluded from the analysis because of internal herniation in 1 patient with Roux-en-Y reconstruction and peritoneal recurrence in 2 patients with Billroth-II reconstruction. The target of this study was the group of 23 patients who underwent endoscopic treatment.



**Figure 2.** Diagram A showed that the guide-wire was inserted through endoscope into afferent loop. Diagram B showed that the transnasal gastroscope was removed leaving the guide-wire in the afferent loop. Diagram C showed that the nasogastric tube was advanced along the guide-wire into the afferent loop. Radiograph D identified the tube's position.

All of the 23 patients underwent endoscopic treatment in 24 hours after ALO diagnosed by CT scan. The endoscopic procedure was successfully performed in all the 23 patients. With regard to the endoscopic appearances, 17 of which showed mucosa inflammatory edema or even inflammatory stenosis of

gastrojejunal anastomosis (Fig. 3A, B), 2 with mucosa intussusception (Fig. 3C), and, surprisingly, 4 without any obvious lesion (Fig. 3D).

The obstructive symptoms had a rapid relief after the endoscopic treatment in all the 23 patients. Liquid diets were

**Table 1****Characteristics of patients with afferent loop obstructions.**

Characteristics	N=26	
Median age, y		
Median	60 (36–69)	
Sex		
Male: female	19:7	
Stage (UICC 8th)		
T1N0M0	4	
T2–4aNxM0	22	
Intervals, d		
Median	14 (8–43)	
Reconstruction		
Billroth-II	25 (25/1734)	<i>P</i> =.002
Roux-en-Y	1 (1/814)	

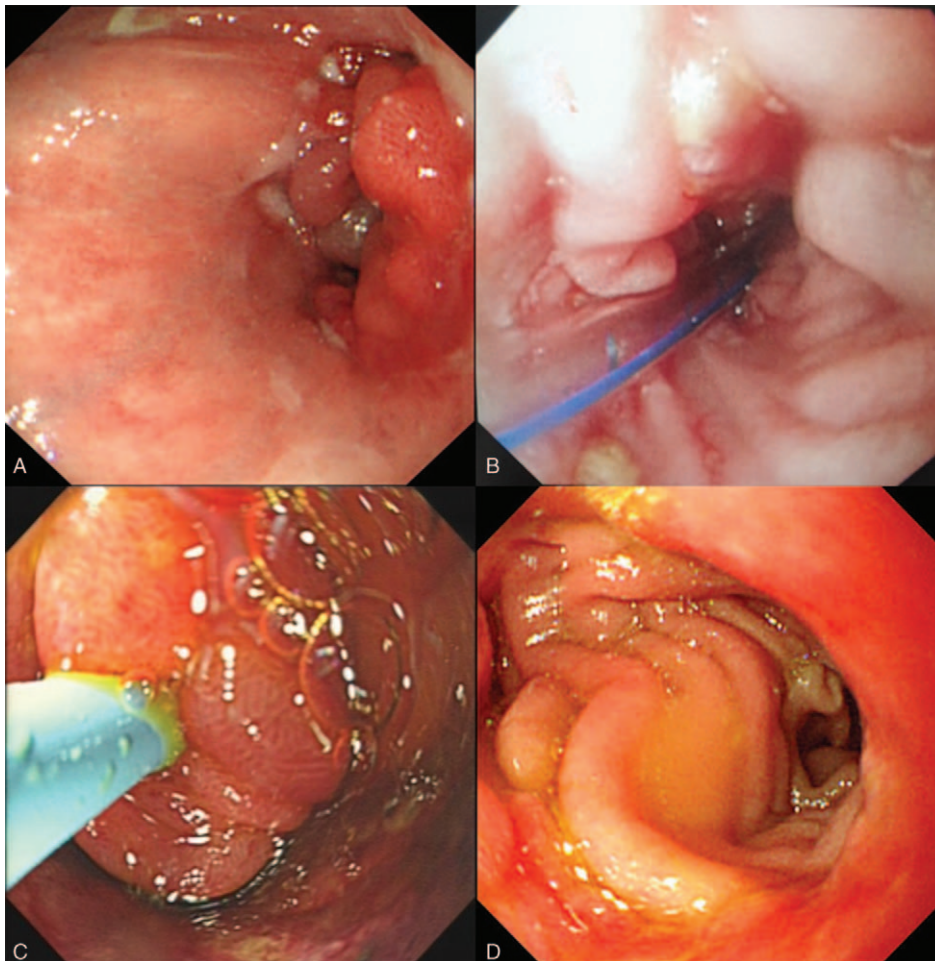
UICC=Union for International Cancer Control.

given after the procedure. Nasogastric tube was successfully removed from 3 to 14 days (median 4 days). However, 2 patients underwent laparoscopic operation or laparotomy due to intestinal obstruction because of adhesion at >4 and 7 months after the endoscopic treatment respectively. No patient died due to this procedure.

**4. Discussion**

This study revealed ALO occurred after distal gastrectomy with Billroth II reconstruction at an incidence of 1.0% that was similar with the reported incidence that ranged from 0.3% to 1.0%.<sup>[11–15]</sup> However, the obstructive causes in this series, shown on initial CT examination, were not as those reported in the literatures, which include internal herniation, adhesions, kinking, intussusception, a gastrointestinal stone, or stomal stenosis due to inflammatory changes or malignancy.<sup>[15–21]</sup> In this study, the further testing by endoscopy were performed to observe the endoscopic appearance of gastrojejunal anastomosis that included mucosa inflammatory edema, inflammatory stenosis, mucosa intussusception, and normal endoscopic appearance. To our best knowledge, this study is the first to report the endoscopic characteristics of obstructive causes.

Due to the changes of anatomical structures in gastrointestinal tract after distal gastrectomy with Billroth II reconstruction, erosiveness of gastric and duodenal juice may lead to mucosa injury and inflammation in gastrojejunal anastomosis. Severe inflammation may not only result in anastomotic stenosis, but also lead to gastrointestinal motility dysfunction, and so it could further lead to incomplete or even complete ALO. In addition,



**Figure 3.** Endoscopic image. A: Endoscopic photo shows mucosa inflammatory edema of gastrojejunal anastomosis. B: Endoscopic photo shows stenosis of gastrojejunal anastomosis. C: Endoscopic photo shows mucosa intussusception of gastrojejunal anastomosis. D: Normal appearance of gastrojejunal anastomosis.

mucosa inflammatory edema of gastrojejunal anastomosis may increase the chance of mucosa intussusception.

In general, that the mucosa inflammatory edema, mucosa intussusception, or stenosis of gastrojejunal anastomosis, as the explicit mechanical obstructive factors, may result in incomplete or complete ALO is the obvious fact that requires no further explanation. However, with regard to the normal endoscopic appearance leading to ALO, the mechanism may involve multiple factors. The duodenum has weaker peristalsis because, as the retroperitoneal viscera, the bowel movement is restricted by the surrounding tissue. In addition, the vagus is cut at the radical gastrectomy, which may cause the inhibition of intestinal peristalsis. Furthermore, according to the principle of communication vessels, the gastrojejunal anastomosis position, above the level of the duodenal stump, has the higher pressure that can prevent the duodenal emptying. Those all factors list above may be why the normal endoscopic appearance can lead to ALO.

For the management of ALO, surgical revision procedures such as adhesiolysis,<sup>[7]</sup> jejunojunostomy with Braun procedure, or Roux-en-Y gastrojunostomy have been the established treatments of choice.<sup>[9,10]</sup> However, some patients would be poor candidates for a second surgical procedure because of debilitated state, associated peritoneal adhesion, or disseminated tumor. For those who are not candidates for surgery, the percutaneous transhepatic route via the biliary tree (PTBD or PTDD) for catheter placement in the obstructed afferent loop has provided effective palliation but in some cases may induce life-threatening septicemia caused by reflux of bowel content into the bile duct through the drainage tube.<sup>[2-5]</sup> In addition, two case reports suggested that direct percutaneous tube enterostomy of the obstructed afferent loop may be an alternative approach to relieve the symptoms,<sup>[6]</sup> however, this procedure may lead to peritonitis and frequent catheter dislodgement caused by bowel peristalsis. Moreover, not all the cases have the appropriate puncture localization whether by ultrasound-guided or CT-guided.

In general, the direct percutaneous puncture approach should be avoided because of potential complications such as peritoneal spillage of bowel contents, peritonitis, septicemia, hemorrhage, and frequent catheter dislodgement caused by bowel peristalsis.<sup>[2,3,22]</sup> So, endoscopic management of ALO was suggestive. Two case reports suggested endoscopic placement of an enteral metallic stent insertion through the stenosis of afferent loop to relieve the obstruction.<sup>[23,24]</sup> However, this procedure was only applied to ALO caused by malignant lesions. On the contrary, a case report suggested endoscopic decompression as the first treatment for ALO due to benign lesions.<sup>[25]</sup> In that procedure, endoscope was got over the stenosis of the afferent loop for bile drainage, which was a temporary and one-off decompression for the obstructed afferent loop. ALO may reappear after endoscopic decompression if obstructive conditions have not yet been excised. Furthermore, the operation may come with the risk of anastomotic injury if that was performed at the early stage after gastrojejunal reconstruction.

Significantly, all the procedures for ALO as described above were applied to only a case or several cases, and even with their unavoidable complication. However, in this series, endoscopic insertion of nasogastric tube to the afferent loop by the wire-guide technique could be sufficiently avoid anastomotic injury. Moreover, retaining nasogastric tube could sustain the drainage and decompression of afferent loop until symptoms disappeared after normal eating had been resumed, which could both avoid

the secondary endoscopic decompression due to recurrence of ALO, and alleviate edema of afferent loop for reduction of postoperative complications if definitive treatment by surgery was needed. This procedure, therefore, could be considered as the first step in treatment for ALO, whether eventually the conservative treatment or surgical treatment was needed.

In fact, the endoscopic decompression with nasogastric tube for the benign ALO has a high treatment success rate and few complications. This procedure is selected than any other treatments because that the ALO is actually a special type of intestinal obstruction and gastrointestinal decompression is the basis therapy for all types of intestinal obstruction treatment. The decompression of afferent loop is just the more accurate drainage for ALO.

The results of this study are subject to some limitations. First, it is a retrospective study. Different endoscopic procedures are performed in the cases. The procedures described in method 1 are performed in part of earlier cases, which are more likely to lead to injury of the gastrojejunal anastomosis. Thus, the safer endoscopic procedures of guide-wire intubation described in method 2 are performed in later cases. Moreover, the nasogastric tube placement time varied among the cases. The tube indwelling time in earlier cases was relatively long while in later cases relatively short. Second, this study has a limitation due to its small sample size. Despite these limitations, the results of this study showed that postoperative afferent loop obstruction, which is difficult to treat, could be treated effectively and safely with endoscopic nasogastric tube insertion for decompression. In particular, the main advantages of this procedure are early oral intake and avoid surgical treatment, thereby resulting in an earlier return to daily life activities.

## 5. Conclusions

In conclusion, endoscopic nasogastric tube insertion for decompression of the obstructive afferent loop is an effective and safe procedure for treatment of benign ALO. In addition, this procedure is less invasive than surgery and could be considered as the first step in treatment, especially in high-surgical-risk patients. Long-term studies, involving more patients, are still necessary to confirm this suggestion.

## Author contributions

**Conceptualization:** Yuning Cao, Xiangheng Kong.

**Data curation:** Daogui Yang.

**Investigation:** Yuning Cao, Xiangheng Kong.

**Methodology:** Yuning Cao, Xiangheng Kong.

**Project administration:** Daogui Yang.

**Software:** Senlin Li.

**Supervision:** Xiangheng Kong.

**Validation:** Xiangheng Kong.

**Writing – original draft:** Yuning Cao.

**Writing – review & editing:** Yuning Cao, Xiangheng Kong.

## References

- [1] Blouhos K, Boulas KA, Tsalis K, et al. Management of afferent loop obstruction: reoperation or endoscopic and percutaneous interventions? *World J Gastrointest Surg* 2015;7:190–5.
- [2] Lee LI, Teplick SK, Haskin PH, et al. Refractory afferent loop problems: percutaneous transhepatic management of two cases. *Radiology* 1987;165:49–50.

- [3] Morita S, Takemura T, Matsumoto S, et al. Septic shock after percutaneous transhepatic drainage of obstructed afferent loop: case report. *Cardiovasc Intervent Radiol* 1989;12:66–8.
- [4] Moriura S, Ikeda S, Kimura A, et al. Jaundice due to afferent loop obstruction following hepatectomy for a hilar cholangiocarcinoma. *Abdom Imaging* 1996;21:226–7.
- [5] Yao NS, Wu CW, Tiu CM, et al. Percutaneous transhepatic duodenal drainage as an alternative approach in afferent loop obstruction with secondary obstructive jaundice in recurrent gastric cancer. *Cardiovasc Intervent Radiol* 1998;21:350–3.
- [6] Kim YH, Han JK, Lee KH, et al. Palliative percutaneous tube enterostomy in afferent-loop syndrome presenting as jaundice: clinical effectiveness. *J Vasc Interv Radiol* 2002;13:845–9.
- [7] Kanno Y, Ohira T, Harada Y, et al. Metal stent placement in the afferent loop obstructed by peritoneal metastases-experience of five cases. *Clin Endosc* 2018;51:299–303.
- [8] Jinno N, Naitoh I, Nagura Y, et al. Percutaneous transhepatic self-expanding metallic stent placement for the treatment of malignant afferent loop obstruction. *Intern Med* 2018;57:333–7.
- [9] Kim DJ, Lee JH, Kim W. Afferent loop obstruction following laparoscopic distal gastrectomy with Billroth-II gastrojejunostomy. *J Korean Surg Soc* 2013;84:281–6.
- [10] Herrington JL Jr. Editorial: Roux-en-Y diversion as an alternate method of reconstruction of the alimentary tract after primary resection of the stomach. *Surg Gynecol Obstet* 1976;143:92–3.
- [11] Wise SW. Case 24: Afferent loop syndrome. *Radiology* 2002;16:142–5.
- [12] Quinn WF, Gifford JH. The syndrome of proximal jejunal loop obstruction following anterior gastric resection. *Calif Med* 1950;72:18–21.
- [13] Gris  K, McFadden D. Anastomotic technique influences outcomes after partial gastrectomy for adenocarcinoma. *Am Surg* 2001;67:948–50.
- [14] Aoki M, Saka M, Morita S, et al. Afferent loop obstruction after distal gastrectomy with Roux-en-Y reconstruction. *World J Surg* 2010;34:2389–92.
- [15] Gayer G, Barsuk D, Hertz M, et al. CT diagnosis of afferent loop syndrome. *Clin Radiol* 2002;57:835–9.
- [16] Mitty WF Jr, Grossi C, Nealon TF Jr. Chronic afferent loop syndrome. *Ann Surg* 1970;172:996–1001.
- [17] Stalsberg H, Taksdal S. Stomach cancer following gastric surgery for benign conditions. *Lancet* 1971;27:1175–7.
- [18] Gale ME, Gerzof SG, Kiser LC, et al. CT appearance of afferent loop obstruction. *AJR Am J Roentgenol* 1982;138:1085–8.
- [19] Tsutsui S, Kitamura M, Shirabe K, et al. Afferent loop syndrome due to scarring of a stomal ulcer following a Billroth II gastrectomy. *Endoscopy* 1995;27:410.
- [20] Wada N, Seki M, Saikawa Y, et al. Jejunal limb obstruction caused by a cholesterol stone 15 years after a total gastrectomy and 20 years after a cholecystectomy: report of a case. *Surg Today* 2000;30:181–4.
- [21] Kim HC, Han JK, Kim KW, et al. Afferent loop obstruction after gastric cancer surgery: helical CT findings. *Abdom Imaging* 2003;28:624–30.
- [22] Bezreh JS. Percutaneous catheter drainage of closed-loop small-bowel obstruction. *AJR Am J Roentgenol* 1983;141:797–8.
- [23] Burdick JS, Garza AA, Magee DJ, et al. Endoscopic management of afferent loop syndrome of malignant etiology. *Gastrointest Endosc* 2002;55:602–5.
- [24] Kim JK, Park CH, Huh JH, et al. Endoscopic management of afferent loop syndrome after a pylorus preserving pancreaticoduodenectomy presenting with obstructive jaundice and ascending cholangitis. *Clin Endosc* 2011;44:59–64.
- [25] De Martino C, Caiazzo P, Albano M, et al. Acute afferent loop obstruction treated by endoscopic decompression. Case report and review of literature. *Ann Ital Chir* 2012;83:555–8.