

An upper cervical cord compression secondary to occult follicular thyroid carcinoma metastases successfully treated with multiple radioiodine therapies

A clinical case report

Ping Dong, MD^a, Ni Chen, MD^b, Lin Li, MD^{a,*}, Rui Huang, MD^{a,*}

Abstract

Rationale: The spine is the most common site of bone metastases due to thyroid cancer; however, spinal cord compression as a complication of metastatic thyroid cancer is very rare.

Patient concerns: A 48-year-old female patient was presented to the Neurosurgical Department, complaining of progressive back neck pain with bilateral upper extremities numbness and weakness for 4 months.

Diagnosis: Imaging studies revealed osteolytic destruction in bodies and accessories of the second and third cervical vertebrae with a huge soft-tissue mass compressing spinal cord and causing swelling. After the neurosurgical decompression surgery, the pathological examination established a metastatic follicular carcinoma originating from the thyroid gland.

Interventions: Her cervical spinal metastases were hardly removed by surgery and the risks of external beam radiation therapy (EBRT) were very high. So she underwent a total thyroidectomy and received multiple radioiodine (RAI) and concomitant glucocorticoid therapies postoperatively. Radioiodine whole-body scan (WBS) showed multiple abnormal radioiodine uptakes. Then single-photon emission tomography/computed tomography (SPECT/CT) located these spinal metastases involving cervical, lumbar, and sacral vertebrae.

Outcomes: After 5 times RAI therapy, her thyroglobulin obviously decreased, with the cervical lesion shrinkage and no spinal cord edema.

Lessons: RAI therapy and concomitant glucocorticoid therapy could be used for spinal metastases of FTC, even with spinal cord compression.

Abbreviations: ATA = American Thyroid Association, CNS = central nervous system, DTC = differentiated thyroid carcinoma, EBRT = external beam radiation therapy, FTC = follicular thyroid cancer, MRI = magnetic resonance imaging, NIS = sodium-iodide symporter, Pax-8 = paired box gene 8, RAI = radioiodine, SPECT/CT = single-photon emission tomography/computed tomography, Tg = thyroglobulin, TRAb = thyrotrophin receptor antibody, TTF-1 = thyroid transcription factor 1, WBS = whole-body scan.

Keywords: bone metastases, follicular thyroid carcinoma, glucocorticoid, radioiodine, spinal cord compression

1. Introduction

Bone metastases originating from differentiated thyroid carcinoma (DTC) are not uncommon, and occur in approximately 2% to 13% of all DTC patients.^[1] Spinal metastases are found in

approximately half of the patients with bone metastases.^[2–4] They is a frequent complication especially in FTC and it is associated with osteodynia, vertebral fractures, and spinal cord compression.^[5] Spinal cord compression, as a bone metastases complication of thyroid carcinoma, is uncommon and occurs mainly during the late stage of the disease.^[6] Current American Thyroid Association (ATA) guidelines state that surgical resection and stereotactic external beam radiation therapy (EBRT) are the mainstays of therapy for central nervous system (CNS) metastases and radioiodine (RAI) therapy and concomitant glucocorticoid therapy can be considered if CNS metastases concentrate RAI.^[7] As relatively few cases being described in the literature, RAI protocol of such patients with spinal metastases and spinal cord compression of DTC origin was insufficient.^[8] The aim of the present case report was to share our experience: how to treat patients with cervical spinal DTC metastases with RAI to improve understanding of this rare entity.

2. Case report

A 48-year-old female patient was presented to the Neurosurgical Department, complaining of progressive back neck pain with

Editor: Jianxun Ding.

The authors have no conflicts of interest to disclose.

^a Department of Nuclear Medicine, ^b Department of Pathology, West China Hospital, Sichuan University, Chengdu, Sichuan, P.R. China.

* Correspondence: Lin Li, Department of Nuclear Medicine, West China Hospital, Sichuan University, Chengdu, Sichuan, P.R. China (e-mail: lillinhuaxi@sina.com); Rui Huang, Department of Nuclear Medicine, West China Hospital, Sichuan University, Chengdu, Sichuan, P.R. China (e-mail: huangrui1977@163.com).

Copyright © 2017 the Author(s). Published by Wolters Kluwer Health, Inc. This is an open access article distributed under the Creative Commons Attribution-NoDerivatives License 4.0, which allows for redistribution, commercial and non-commercial, as long as it is passed along unchanged and in whole, with credit to the author.

Medicine (2017) 96:41(e8215)

Received: 6 April 2017 / Received in final form: 29 July 2017 / Accepted: 17 August 2017

<http://dx.doi.org/10.1097/MD.00000000000008215>

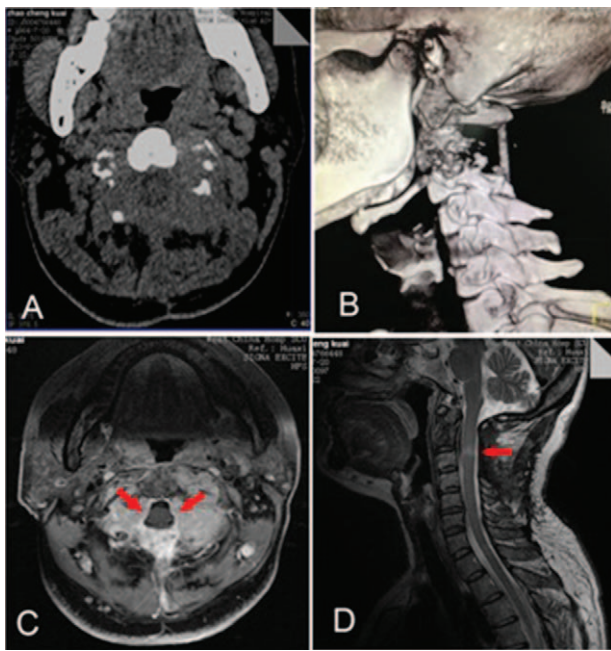


Figure 1. A and B, Transversal CT and three-dimensional reconstruction showed osteolytic destruction in bodies and accessories of the second and third cervical vertebrae. (C and D, red arrow) In the same region, MRI demonstrated a huge mass, with a high signal intensity on the contrast-enhanced T1W image, compressing spinal cord and causing it swelling. CT = computed tomography, MRI = magnetic resonance imaging.

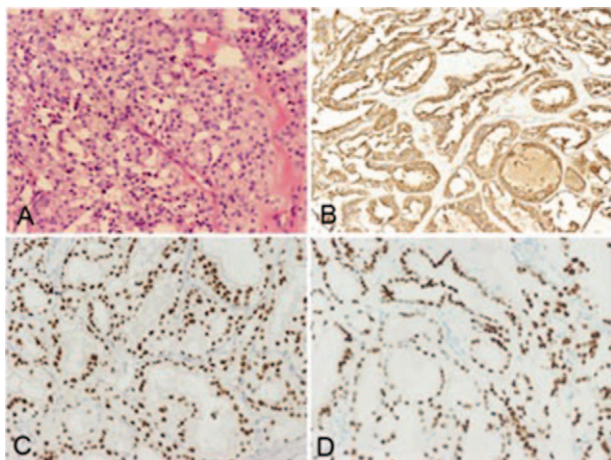


Figure 2. The pathological examination revealed a metastatic follicular carcinoma (A, H&E) originating from thyroid gland, which was determined by detecting Tg (B), Pax-8 (C), and TTF-1 (D) expression in tumor cells.

bilateral upper extremities numbness and weakness for 4 months. Transversal computed tomography (CT) and three-dimensional reconstruction showed osteolytic destruction in bodies and accessories of the second and third cervical vertebrae (Fig. 1A and

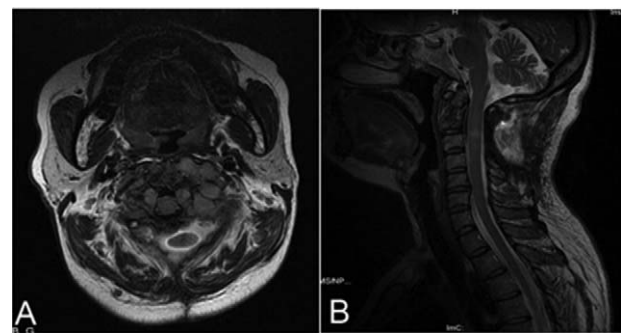


Figure 3. A and B, The spine cord compression and edema still existed on postoperative MRI. MRI = magnetic resonance imaging.

B). In the same region, magnetic resonance imaging (MRI) demonstrated a huge mass, with a high signal intensity on the contrast-enhanced T1W image, compressing spinal cord (Fig. 1C, red arrow) and causing swelling (Fig. 1D, red arrow).

After the neurosurgical decompression surgery, the pathological examination revealed a metastatic follicular carcinoma originating from the thyroid gland (Fig. 2A), which was determined by detecting the thyroglobulin (Tg), paired box gene 8 (Pax-8), and thyroid transcription factor 1 (TTF-1) expression on tumor cells (Fig. 2B, C, and D, respectively).

Her symptom of back pain and numbness gradually recovered, but the spine cord compression and edema still existed on postoperative MRI (Fig. 3A and B). Then the patient underwent a total thyroidectomy and central lymph node dissection, but the pathological examination only found multiple follicular adenomas without evidence of carcinoma and regional lymph node metastases. Staging for the patient was done (TxN0M1) in accordance with the 8th edition of the AJCC/UICC staging system. Given the difficulties in complete resection of cervical metastases and high risks of EBRT, RAI therapy was performed on October 10, 2013. Meanwhile, methylprednisolone and mannitol were prescribed to prevent radioactive inflammation of spinal cord (Table 1). There were no obvious spine cord compression symptoms or side effects of glucocorticoid during the period of treatment.

¹³¹I-WBS revealed multiple abnormal uptake lesions (Fig. 4A) and SPECT/CT located these osteolytic bone metastases involving C2 and C3 (Fig. 4B, red arrow), C5 spinous process (Fig. 4B, blue arrow), L1 (Fig. 4C, purple arrow), S1 (Fig. 4C, white arrow). There was little residual thyroid tissue on the right thyroid bed (Fig. 4B, yellow arrow). Even levothyroxine had been withdrawn for 5 weeks (because of nonavailability of rhTSH in Mainland China), her TSH was still low (3.97 mU/L, normal range, 0.27–4.2 mU/L) with normal FT₃ (Table 2), which might be almost due to these functional bone metastases.

Given the favorable therapeutic reaction and little radioactive inflammation, the patient was preformed with other 4 RAI therapies (Table 3). And these four ¹³¹I-WBSs were similar to the

Table 1
Prescription of methylprednisolone and mannitol.

	Before RAI	During RAI	After RAI
Methylprednisolone	20 mg qd p.o. × 2 wk	500 mg qd ivgtt × 3 d 250 mg qd ivgtt × 3 d 125 mg qd ivgtt × 2 d	20 mg qd p.o. × 2 wk 10 mg qd p.o. × 2 wk 5 mg qd p.o. × 2 wk
Mannitol	—	125 ml bid ivgtt × 8 d	—

bid=bis in die, p.o.=per os, ivgtt=intravenously gutta, qd=quaque die, RAI=radioactive iodine.

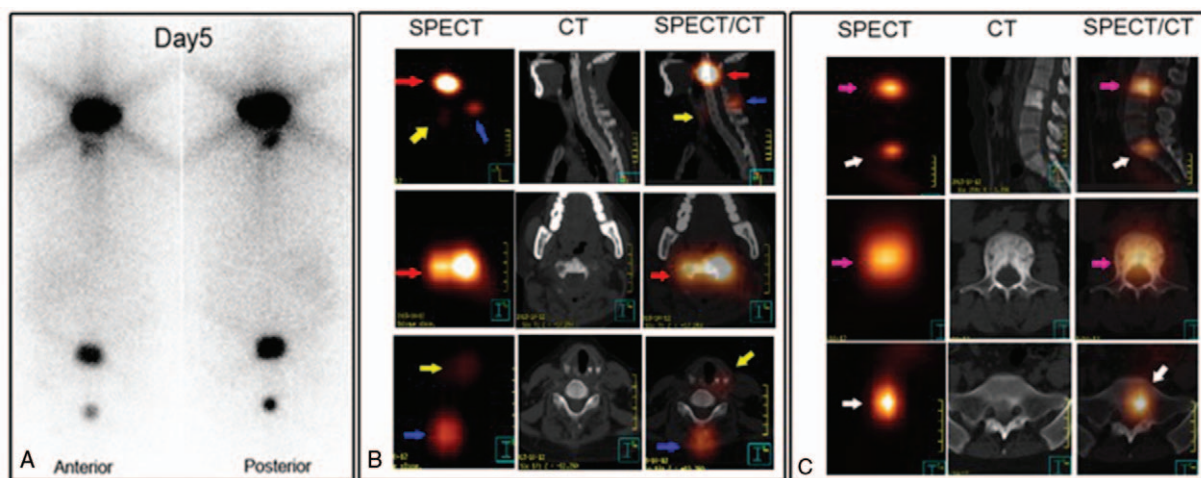


Figure 4. ¹³¹I whole-body scan revealed multiple abnormal uptake lesions (A) and SPECT/CT located these osteolytic bone metastases involving C2 and C3 (B, red arrow), C5 spinous process (B, blue arrow), L1 (C, purple arrow), S1(C, white arrow). There was little residual thyroid tissue on the right thyroid bed (B, yellow arrow). SPECT/CT = single-photon emission tomography/computed tomography.

Table 2

Thyroid function studies before and after RAI.

Time	TSH (0.27–4.2 mU/L)	FT ₃ (3.6–7.5 pmol/L)	FT ₄ (12–22 pmol/L)	Tg (1.4–78 ug/L)	TgAb (<115 IU/mL)
TSH stimulation before 1st RAI	3.97	4.57	8.83	451.2	428.8
TSH suppression after 1st RAI	0.051	6.55	20.77	299.1	17.28
TSH stimulation before 2nd RAI	17.33	2.9	4.77	1637	19.93
TSH suppression after 2nd RAI	0.092	5.51	18.32	68.35	14.97
TSH stimulation before 3rd RAI	>100	2.98	4.31	1369	25.23
TSH suppression after 3rd RAI	0.251	6.09	22.25	58.27	<10
TSH stimulation before 4th RAI	89.43	2.46	5.92	1075	15.21
TSH suppression after 4th RAI	0.081	4.97	21.29	36.68	13.05
TSH stimulation before 5th RAI	32.91	1.92	5.56	388.9	20.83
TSH suppression after 5th RAI	0.059	5.06	18.46	45.75	<10

FT₃=free triiodothyronine, FT₄=free thyroxine, RAI=radioactive iodine, Tg=thyroglobulin, TgAb=thyroglobulin antibody, TSH=thyrotropin.

first ¹³¹I-WBS previously (Fig. 5). Her last outpatient follow-up was on March 26, 2017. On physical examination, she was afebrile and normotensive without back neck pain or extremities numbness. Her workup included a TSH level of 0.059 mU/L (normal range, 0.27–4.2 mU/L), a FT₃ level of 5.06 pmol/L (normal range, 3.6–7.5 pmol/L), an FT₄ level of 18.46 pmol/L (normal range, 12–22 pmol/L), a sharply decreased Tg level of 45.75 ug/L compared with pre-RAI therapy of 451.2 ug/L (normal range, 1.4–78 ug/L), a TgAb level of <10 IU/mL (normal range, <115 IU/mL), normal blood routine, and normal albumin and liver enzyme levels. And imaging studies included the cervical

vertebra of MRI which demonstrated significant shrinkage of cervical vertebrae lesions with no spinal cord edema (Fig. 6A and B) and chest CT with negative result.

This case report was approved by the Ethics Committee of West China Hospital of Sichuan University, Chengdu, China, and the written informed consent was obtained.

3. Discussion

Distant bone metastases, as a common complication of FTC, occur mainly during the late stages of the disease.^[6] Spinal metastases typically affect the thoracic (60%–80%), lumbar (15%–30%), and cervical spine (< 10%).^[9,10] Upper cervical metastasis with spinal cord compression from follicular thyroid carcinoma is a rare event. The chief presenting symptom of spinal metastases is pain (83%–95%), and some patients may show incomplete paralysis or paraplegia.^[5,9,10]

We surveyed the literature indicating that only a few sporadic cases of DTC patients with spinal cord compression are due to vertebral metastasis. Most of them underwent surgical approach, RAI and TSH suppression therapy, and other palliative treatments including laminectomy, excision, embolization, and EBRT.^[6,8,11] Among these sporadic cases, Selvakumar et al^[11] reported that a female with symptomatic cervical cord

Table 3

RAI therapy: time, time interval, and dose.

Time	Time interval (mo)	Dose (mCi)
1st RAI 10/10/2013	—	150
2nd RAI 04/16/2014	6	200
3rd RAI 10/22/2014	6	200
4th RAI 07/22/2015	9	250
5th RAI 11/30/2016	16	250
		In total 1050

RAI = radioiodine.

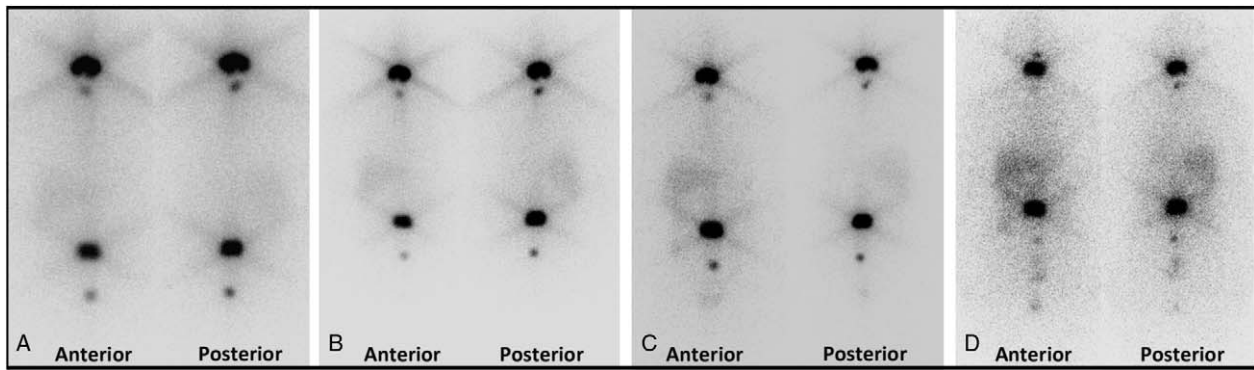


Figure 5. (A, B, C, and D, respectively) Other 4 ^{131}I -WBSs also revealed the same multiple abnormal uptake lesions as the first ^{131}I -WBS depiction. WBS = whole-body scan.

compression due to spinal metastases of papillary carcinoma but achieving neurologically stable after multidisciplinary treatments including surgery, EBRT, and a RAI therapy. Management of patients with spinal cord compression due to upper cervical metastases from FTC must involve a multidisciplinary approach including surgery (total thyroidectomy and resection of metastatic lesions), EBRT, RAI therapy, and TSH suppression therapy.^[5,7,10] A total thyroidectomy is to remove the primary tumor and to facilitate radioiodine therapy. Resection of metastatic lesions is associated with improved survival and quality of life.^[5] EBRT is a palliative treatment indicated only when pain, risk of fracture, and neurological complications of spinal cord compression are present.^[12–14] Radioiodine therapy is considered the first-line treatment for sodium-iodide symporter (NIS) positive metastatic lesions. TSH suppression therapy intends to reduce the impetus for further tumor growth.^[5,7] Glucocorticoids can relieve and prevent spinal cord compression during RAI therapy. Methylprednisolone is a synthetic corticosteroid with higher anti-inflammatory activity than prednisolone (1.25 times) and a low mineralocorticoid effect. It has been used to treat acute spinal cord injury and ease surgically related pain and inflammation.^[7,15–17] So we chose methylprednisolone instead of prednisolone for this patient. There are some studies that reported that glucocorticoids would reduce thyroidal uptake of RAI and lower its effective half-life in a dose-dependent manner, perhaps by increasing glomerular filtration rate and thus renal iodine clearance.^[18,19] So we performed ^{131}I -WBS in 2, 5, 7 days after the treatment of 150 mCi ^{131}I , respectively. And these ^{131}I -WBS images showed no obviously decreasing radio-

activities in the metastatic lesions, which indicated that high-dose glucocorticoid may not affect the uptake of iodine and its retention in these lesions.

The patient's thyroid status was nearly euthyroid after withdrawal of levothyroxine for 3 weeks or more. There are 3 reported potential mechanisms that might be involved in this situation. First, metastatic thyroid cancers may function autonomously to produce thyroid hormones.^[20–23] Second, the TSH receptor in the metastatic tumor may induce the formation of thyrotrophin receptor antibody (TRAb), favoring the production of thyroid hormone by the metastatic tissue. Finally, some metastases from FTC express 5'-iodothyronine deiodinase activity. If patients with these tumors receive levothyroxine, there could be an increase in the conversion of thyroxine to T3 in the metastatic tumor tissue.^[23–25] As for our patient, the reason may be that metastases that function autonomously produce thyroid hormones, because of multiple radioactive metastases and remarkable decrease of serum thyroglobulin after RAI.

As previously reported by Selvakumar et al,^[11] the current cervical spinal metastatic patient from an occult FTC also underwent surgery both for primary disease and metastatic lesions and RAI therapy. But our patient underwent multiple RAI concomitant glucocorticoid therapies compared with the patient reported by Selvakumar et al who just received only 1 time of RAI therapy without glucocorticoid therapy.

Compared with other similar cases published including reported by Selvakumar et al,^[6,8,11] there were some differences in our manuscript. The patient's cervical spinal metastases could not be completely resected, still existing spinal cord compression and edema, which may be worsened after RAI. With the regimen of methylprednisolone and mannitol, she underwent 5 RAI therapies without obvious side effects and achieved partial remission. Additionally, her metastases were functional lesions, as we discussed above.

To the best of our knowledge, this was the first reported case that attempted to use multiple RAI therapies concomitant glucocorticoid therapies to successfully treat a patient with spinal cord compression due to upper cervical metastases from occult FTC. During these 5 therapeutic processes, the patient did not have any significant adverse sequelae and her serum thyroglobulin obviously decreased with cervical lesions shrinkage. We recommended her to do resection of her cervical lesions again. However, she refused. So the patient will receive more RAI therapy when certain standards are met.

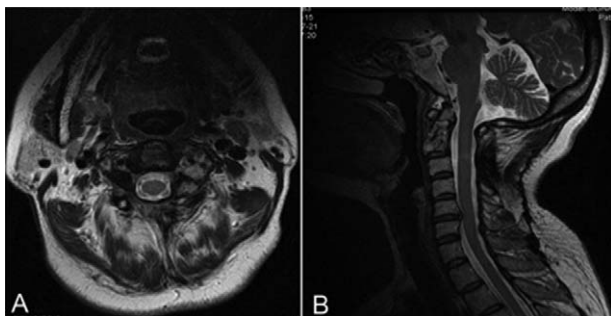

Figure 6. A and B, The cervical vertebrae lesion was shrinkage and there was no spinal cord edema.

In conclusion, FTC with spinal cord compression should be early diagnosed and multidisciplinary approaches should be applied, including surgery, EBRT, RAI, and concomitant glucocorticoid therapy, to improve patients' survival rate and quality of life.

References

- [1] Muresan MM, Olivier P, Leclere J, et al. Bone metastases from differentiated thyroid carcinoma. *Endocr Relat Cancer* 2008;15:37–49.
- [2] Pittas AG, Adler M, Fazzari M, et al. Bone metastases from thyroid carcinoma: clinical characteristics and prognostic variables in one hundred forty-six patients. *Thyroid* 2000;10:261–8.
- [3] Wu K, Hou SM, Huang TS, et al. Thyroid carcinoma with bone metastases: a prognostic factor study. *Clin Med Oncol* 2008;2:129–34.
- [4] Farooki A, Leung V, Tala H, et al. Skeletal-related events due to bone metastases from differentiated thyroid cancer. *J Clin Endocrinol Metab* 2012;97:2433–9.
- [5] Kushchayeva YS, Kushchayev SV, Wexler JA, et al. Current treatment modalities for spinal metastases secondary to thyroid carcinoma. *Thyroid* 2014;24:1443–55.
- [6] Hsiao FC, Chen CL, Lin TY, et al. Metastatic spinal cord compression as initial presentation of occult follicular thyroid carcinoma. *J Med Sci* 2008;8:89–94.
- [7] Haugen BR, Alexander EK, Bible KC, et al. 2015 American thyroid association management guidelines for adult patients with thyroid nodules and differentiated thyroid cancer: the American Thyroid Association (ATA) guidelines task force on thyroid nodules and differentiated thyroid cancer. *Thyroid* 2016;26:1–33.
- [8] McNeeley MF, Sabath A, Linnau KF. Follicular thyroid carcinoma presenting as acute cord compression due to thoracic vertebral metastasis. *Radiol Case Rep* 2012;7:687.
- [9] Ramadan S, Ugas MA, Berwick RJ, et al. Spinal metastasis in thyroid cancer. *Head Neck Oncol* 2012;4:1–9.
- [10] Sciubba DM, Petteys RJ, Dekutoski MB, et al. Diagnosis and management of metastatic spine disease: a review. *J Neurosurg Spine* 2010;13:94–108.
- [11] Selvakumar VP, Goel A, Kumar K. Cervical cord compression as initial presentation of papillary thyroid carcinoma: a case report. *Indian J Surg Oncol* 2016;7:349–52.
- [12] Gerszten PC, Burton SA, Ozhasoglu C, et al. Radiosurgery for spinal metastases: clinical experience in 500 cases from a single institution. *Spine (Phila Pa 1976)* 2007;32:193–9.
- [13] Demura S, Kawahara N, Murakami H, et al. Total en bloc spondylectomy for spinal metastases in thyroid carcinoma. *J Neurosurg Spine* 2011;14:172–6.
- [14] Bernstein MB, Chang EL, Amini B, et al. Spine stereotactic radiosurgery for patients with metastatic thyroid cancer: secondary analysis of phase i/ii trials. *Thyroid* 2016;26:1269–75.
- [15] Hurlbert RJ. Methylprednisolone for the treatment of acute spinal cord injury: point. *Neurosurgery* 2014;61:32–5.
- [16] de la Motte L, Kehlet H, Vogt K, et al. Preoperative methylprednisolone enhances recovery after endovascular aortic repair: a randomized, double-blind, placebo-controlled clinical trial. *Ann Surg* 2014;260:540–9.
- [17] Sadra V, Khabbazi A, Kolahi S, et al. Randomized double-blind study of the effect of dexamethasone and methylprednisolone pulse in the control of rheumatoid arthritis flare-up: a preliminary study. *Int J Rheum Dis* 2014;17:389–93.
- [18] Hautzel H, Pizar E, Yazdan-Doust N, et al. Qualitative and quantitative impact of protective glucocorticoid therapy on the effective ¹³¹I half-life in radioiodine therapy for Graves disease. *J Nucl Med* 2010;51:1917–22.
- [19] Salvatore D, Fenzi G. Do glucocorticoids affect outcome in Graves' disease following radioiodine therapy? *Nat Clin Pract Endocrinol Metab* 2006;2:194–5.
- [20] Ikejiri K, Furuyama M, Muranaka T, et al. Carcinoma of the thyroid manifested as hyperthyroidism caused by functional bone metastasis. *Clin Nucl Med* 1997;22:227–30.
- [21] Nishihara E, Amino N, Miyauchi A. Fractionated radioiodine therapy for hyperthyroidism caused by widespread metastatic follicular thyroid carcinoma. *Thyroid* 2010;20:569–70.
- [22] Tan J, Zhang G, Xu W, et al. Thyrotoxicosis due to functioning metastatic follicular thyroid carcinoma after twelve I-131 therapies. *Clin Nucl Med* 2009;34:615–9.
- [23] Girelli ME, Casara D, Rubello D, et al. Severe hyperthyroidism due to metastatic papillary thyroid carcinoma with favorable outcome. *J Endocrinol Invest* 1990;13:333–7.
- [24] Kim BW, Daniels GH, Harrison BJ, et al. Overexpression of type 2 iodothyronine deiodinase in follicular carcinoma as a cause of low circulating free thyroxine levels. *J Clin Endocrinol Metab* 2003;88:594–8.
- [25] Miyauchi A, Takamura Y, Ito Y, et al. 3,5,3'-Triiodothyronine thyrotoxicosis due to increased conversion of administered levothyroxine in patients with massive metastatic follicular thyroid carcinoma. *J Clin Endocrinol Metab* 2008;93:2239–42.