

## CASE REPORT

Nagoya J. Med. Sci. 77. 315 ~ 320, 2015

# GRAFTED VERTEBRAL FRACTURE AFTER IMPLANT REMOVAL IN A PATIENT WITH SPINE-SHORTENING VERTEBRAL OSTEOTOMY

HIROAKI NAKASHIMA<sup>1</sup>, MD; YASUTSUGU YUKAWA<sup>2</sup>, MD, PhD; KEIGO ITO<sup>2</sup>, MD, PhD; MASAOKI MACHINO<sup>2</sup>, MD; SHUNSUKE KANBARA<sup>2</sup>, MD; DAIGO MORITA<sup>2</sup>, MD; SHIRO IMAGAMA<sup>1</sup>, MD, PhD; NAOKI ISHIGURO<sup>1</sup>, MD, PhD; and FUMIHIKO KATO<sup>2</sup>, MD

<sup>1</sup>Department of Orthopedic Surgery, Nagoya University Graduate School of Medicine, Nagoya, Japan  
<sup>2</sup>Department of Orthopedic Surgery, Chubu Rosai Hospital, Nagoya, Japan

### ABSTRACT

We experienced the rare complication of a vertebral fracture that was caused by implant removal after bony fusion had been achieved in a patient who underwent spine-shortening osteotomy (SSO) for tethered cord syndrome (TCS). We propose that the removal of the implant used for SSO should be contraindicated. The patient (a 27-year-old female) presented to our institution with a history of progressive severe lower back pain, gait disturbance, and urinary incontinence. As an infant, she had undergone surgery for spina bifida with lipoma. Magnetic resonance imaging of the spine revealed tethering of the spinal cord to a lipoma. We performed SSO at the level of the L1 vertebra level. After spine shortening and fixation using a posterior approach, the L1 vertebral body was completely removed anteriorly and replaced with a left iliac bone graft. The patient's symptoms improved after surgery. After bony fusion was achieved after surgery, we decided to remove the spinal implant after we explained the advantages and disadvantages of the procedure to the patient. We performed implant removal surgery safely 2 years later; however, the patient complained of severe lower back pain 10 days after the surgery without any history of trauma. Reconstruction computed tomography showed fracture of the grafted vertebra. We performed a repeat posterior fixation, which relieved the lower back pain; she has experienced no complications in the subsequent 5 years. In summary, we report a case of a rare complication of the fracture of a grafted vertebra after removal of an implant used in SSO for TCS. Spinal stability could not be maintained without the spinal posterior implant after SSO. Postoperative fracture after spinal implant removal is rare but possible, and patients must be informed of this potential risk.

Key Words: implant removal; spine-shortening vertebral osteotomy; tethered cord syndrome; grafted vertebral fracture

### INTRODUCTION

Tethered cord syndrome (TCS) is caused by abnormal traction of the spinal cord by several pathological conditions.<sup>1-4)</sup> TCS occurs mainly in the pediatric population but is sometimes also observed in adults. Adult TCS presents with two types of symptoms: *de novo* symptoms and

---

Received: September 24, 2014; accepted: December 24, 2014

Corresponding author: Hiroaki Nakashima, MD

Department of Orthopedic Surgery, Nagoya University Graduate School of Medicine, 65 Tsurumai, Showa-ku, Nagoya, Aichi 466-8560, Japan

TEL: +81-52-744-2446, FAX: +81-52-744-2449, E-mail: hirospine@gmail.com

recurrent symptoms after untethering in childhood.<sup>3, 4)</sup> Untethering has been a standard treatment in patients with adult TCS.<sup>5)</sup> However, untethering surgery was reported to have a high rate of complications such as cerebrospinal fluid leakage and neurological deterioration.<sup>1-4)</sup> Moreover, patients with recurrent symptoms lasting longer than 5 years exhibited less frequent neurological improvements than patients with recurrent symptoms lasting less than 5 years after untethering.<sup>6)</sup> Therefore, spine-shortening osteotomy (SSO) has recently been performed for patients with adult TCS, particularly in patients with symptoms that have recurred for more than 5 years.<sup>1-4)</sup>

Excellent clinical and radiological outcomes after SSO have been reported previously;<sup>1, 2)</sup> however, we experienced the rare complication of the fracture of the grafted vertebra after implant removal. Some surgeons advocate implant removal because of the perceived risks associated with retained implants, including stress shielding, the risk of late infection, allergy, toxicity, titanium deposition, and carcinogenic potential.<sup>7-10)</sup> In contrast, other surgeons do not advocate this surgery because of postoperative complications and consideration to cost effectiveness.<sup>7, 8)</sup> Therefore, the necessity of implant removal remains controversial. The complications following spinal implant removal surgery have been rarely reported,<sup>11-13)</sup> and the risks associated with this procedure are unclear. To the best of our knowledge, a fracture of the grafted vertebra has not been reported previously. We report this case to demonstrate the risk of postoperative fracture after spinal implant removal.

## CASE REPORT

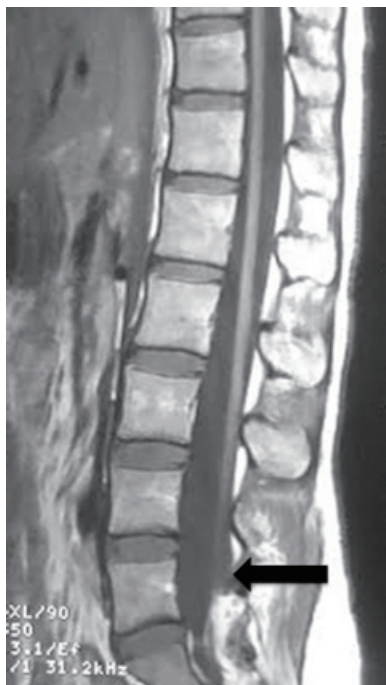A 27-year-old female with a progressive history of lower back pain, gait disturbance, and delayed urination presented to our institution. She had a past history of spinal surgery for spina bifida with lipoma (conducted 20 days after birth). The lipoma was reduced surgically at that time, and her skin was closed; however, equinus foot and enuresis appeared later in her childhood. Left Achilles tendon extension surgery was performed when she was 7 years old. The symptoms of lower back pain, gait disturbance, and urinary incontinence became severe after the age of 20 years, therefore, she was referred to our hospital. A physical examination revealed bilateral hyperreflexia of the patellar tendon, hypreflexia of the left ankle, and motor weakness in the left lower extremity (manual muscle testing scores: iliopsoas, 3; hamstring, 3; quadriceps, 4; tibialis anterior, 2; gastro-cutaneous, 2). Magnetic resonance imaging of the patient's spine revealed tethering of the spinal cord to a lipoma-like abnormal tissue in the lumbar spine with high signal intensities on T1- and T2-weighted images (Figure 1a).

The patient was diagnosed with adult TCS. We decided to perform vertebral osteotomy and spine-shortening surgery at the L1 vertebra level (Figure 1b). The laminae and transverse processes of the T12–L2 vertebrae were exposed, and pedicle screws were placed bilaterally at the T11 and L3 vertebrae. Then, temporary rods were fixed in place for column stability while we performed the osteotomy. The lower half of the T12 lamina, the bilateral lower articular processes at T12, and bilateral L1 superior articular processes were resected, and the bilateral L1 pedicles and bilateral transverse processes were then removed. A T12–L1 discectomy and L1 upper one-third vertebral body resection were performed thereafter. The defect measured 20 mm at this point. Next, the T12 and L2 vertebrae were compressed gradually using a pedicle screw-rod construct with somatosensory and motor-evoked potential monitoring; an 18-mm shortening was accomplished using this method. A posterior arthrodesis (T11–L3) was then performed using a harvested autograft. Subsequently, the anterior procedure was performed using the retroperitoneal or extrapleural approach in the right decubitus position. The lateral and anterior aspects of the L1 vertebral body were exposed, and the remaining L1 vertebral body was resected completely

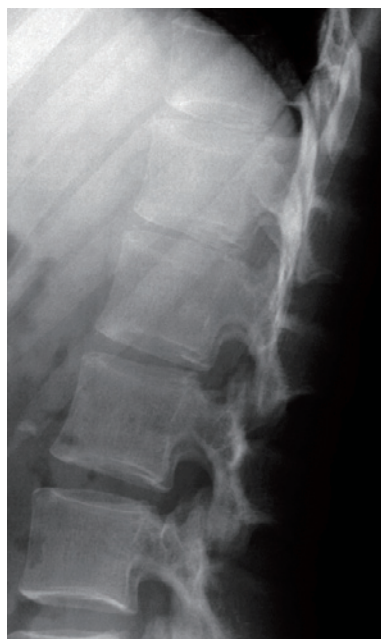## GRAFTED VERTEBRAL FRACTURE AFTER IMPLANT REMOVAL

after the removal of the discs above and below. Finally, anterior interbody fusion was performed after anterior decompression using a left iliac crest graft (Figure 1c).

After the surgery, the patient's low back pain subsided, and her proximal lower leg muscle weakness improved 6 months after surgery (manual muscle testing scores: iliopsoas, 4; hamstring, 4; quadriceps, 5). The achievement of bony fusion in both the anterior and posterior parts of the spine was confirmed using reconstruction computed tomography imaging 1 year after the surgery. We made the decision to remove the implant 2 years after the surgery after we explained the advantages and disadvantages of the procedure to the patient. Implant removal was performed without complications (Figure 1d). However, 10 days after the implant removal surgery, the patient complained of severe lower back pain without any trigger such as trauma. Reconstruction computed tomography images revealed a fracture of the grafted vertebral body (Figure 1d). We then decided to perform posterior fixation again. This second posterior fixation relieved the patient's lower back pain, and fusion of the grafted vertebral body was observed 6 months after this surgery. The patient has not experienced any additional complications in the 5 years following the second surgery (Figure 1e).

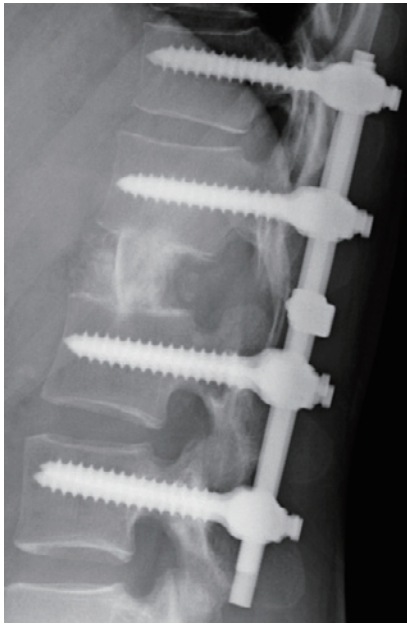


**Fig. 1(a)**

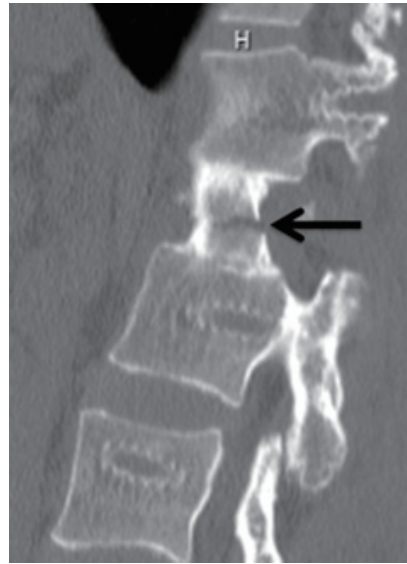

**Fig. 1(b)**

**Fig. 1** (a) Preoperative T1-weighted sagittal magnetic resonance image; the black arrow shows tethering of the spinal cord. (b) Lateral plain radiograph image on the initial visit to our hospital.

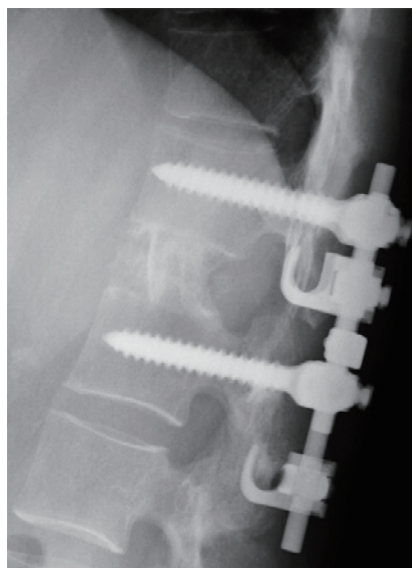


**Fig. 1(c)**



**Fig. 1(d)**

**Fig. 1** (c) A postoperative lateral plain radiograph at the initial spinal-shortening surgery. (d) A computed tomography sagittal reconstruction image when the grafted vertebral fracture (arrow) was found.



**Fig. 1(e)**

**Fig. 1** (e) A lateral plain radiograph at final follow-up.

## DISCUSSION

SSS is an alternative technique for untethering surgery used to treat adult TCS,<sup>1-4, 6)</sup> and excellent clinical outcomes have been reported.<sup>2)</sup> Numerous studies have reported the potential complications associated with implants after orthopedic surgery, including stress shielding, the risk of late infection, allergy, toxicity, titanium deposition, and carcinogenic potential.<sup>7-10)</sup> Overall, it is a common procedure, particularly in pediatric orthopedics; it accounts for approximately 5% of all orthopedic procedures in the United States,<sup>14)</sup> and in one report, 81% of patients underwent implant removal after fracture healing in Finland.<sup>15)</sup> In the field of spinal surgery, several orthopedic surgeons performed implant removal despite the lack of sufficient evidence regarding its safety and efficacy.<sup>11, 12, 16-20)</sup> In contrast, other surgeons doubted the benefit of implant removal because of postoperative complications and the cost of the procedure.<sup>7, 8)</sup> As a result, it remains controversial whether implants should be removed.

Complications regarding spinal implant removal have been reported only rarely.<sup>11-13)</sup> Vanichkachorn *et al.* reported one case of potential large vessel injury during the removal of a broken pedicle screw.<sup>12)</sup> Waelchli *et al.* and Cappuccio *et al.* reported vertebral compression fractures of the instrumented vertebral body adjacent to the fractured vertebra due to removal of pedicle screws.<sup>11, 13)</sup> However, there have been no previous reports of the fracture of the grafted vertebra after implant removal.

In the present case, we performed implant removal surgery after SSO in accordance with the patient's insistence and in consideration of the benefits mentioned above. However, fracture of the grafted vertebra was observed soon after the surgery. When the SSO was performed, osteotomy at the level of the L1 vertebra was selected because of the smaller spinal body size in this region, the easier approach secondary to the straight spinal alignment around the thoracolumbar area, and the lower risk of diminishing the lumbar range of motion compared with other lumbar levels.<sup>2)</sup> There have been no reports on spinal stability after posterior elements were removed from the thoracolumbar junction. However, it can be considered that there is insufficient stability for the bending or torsion of the spine in the absence of posterior spinal elements at this junction, which was the cause of the fracture of the grafted vertebra observed in the present case. Surprisingly, in previous reports of postoperative fractures after implant removal, the fractured vertebrae were all in the thoracolumbar junction (L1 in two cases and T12 in one case);<sup>11, 13)</sup> therefore, the thoracolumbar junction might have a higher risk of fracture after implant removal. Because the necessity for implant removal surgery is controversial, we recommend that spinal implants not be removed, particularly in cases of SSO or osteotomy surgery on a spinal posterior element such as total en-block spondylectomy. It is crucial to understand the inherent risks as well as to know the expected benefits of this procedure. Further long-term and large-scale studies are needed to elucidate whether spinal implant removal surgery is necessary.

## ACKNOWLEDGMENTS

The authors wish to thank Ms. M Fujimoto for assistance with data collection.

There are no conflicts of interests.

Disclosure of funding: Nothing

## REFERENCES

- 1) Kokubun S, Ozawa H, Aizawa T, Ly NM, Tanaka Y. Spine-shortening osteotomy for patients with tethered cord syndrome caused by lipomyelomeningocele: Clinical article. *Journal of Neurosurgery: Spine*, 2011; 15: 21–27.
- 2) Miyakoshi N, Abe E, Suzuki T, Kido T, Chiba M, Shimada Y. Spine-shortening vertebral osteotomy for tethered cord syndrome: report of three cases. *Spine*, 2009; 34: E823–E825.
- 3) Hüttmann S, Krauss J, Collmann H, Sörensen N, Roosen K. Surgical management of tethered spinal cord in adults: report of 54 cases. *Journal of Neurosurgery: Spine*, 2001; 95: 173–178.
- 4) Shih P, Halpin RJ, Ganju A, Liu JC, Koski TR. Management of recurrent adult tethered cord syndrome. *Neurosurgical focus*, 2010; 29: E5.
- 5) Filler AG, Britton JA, Uttley D, Marsh HT. Adult postrepair myelomeningocele and tethered cord syndrome: good surgical outcome after abrupt neurological decline. *Br J Neurosurg*, 1995; 9: 659–666.
- 6) Grande AW, Maher PC, Morgan CJ, Choutka O, Ling BC, Raderstorf TC, Berger EJ, Kuntz IV C. Vertebral column subtraction osteotomy for recurrent tethered cord syndrome in adults: a cadaveric study. *Journal of Neurosurgery: Spine*, 2006; 4: 478–484.
- 7) Raney EM, Freccero DM, Dolan LA, Lighter DE, Fillman RR, Chambers HG. Evidence-based analysis of removal of orthopaedic implants in the pediatric population. *Journal of Pediatric Orthopaedics*, 2008; 28: 701–704.
- 8) Busam ML, Esther RJ, Obremsky WT. Hardware removal: indications and expectations. *Journal of the American Academy of Orthopaedic Surgeons*, 2006; 14: 113–120.
- 9) Cundy TP, Antoniou G, Sutherland LM, Freeman BJ, Cundy PJ. Serum titanium, niobium, and aluminum levels after instrumented spinal arthrodesis in children. *Spine (Phila Pa 1976)*, 2013; 38: 564–570.
- 10) Kasai Y, Iida R, Uchida A. Metal concentrations in the serum and hair of patients with titanium alloy spinal implants. *Spine (Phila Pa 1976)*, 2003; 28: 1320–1326.
- 11) Cappuccio M, De Iure F, Amendola L, Martucci A. Vertebral body compression fracture after percutaneous pedicle screw removal in a young man. *J Orthop Traumatol*, 2014.
- 12) Vanichkachorn JS, Vaccaro AR, Cohen MJ, Cotler JM. Potential large vessel injury during thoracolumbar pedicle screw removal: a case report. *Spine*, 1997; 22: 110–113.
- 13) Waelchli B, Min K, Cathrein P, Boos N. Vertebral body compression fracture after removal of pedicle screws: a report of two cases. *European Spine Journal*, 2002; 11: 504–506.
- 14) Rutkow IM. Orthopaedic operations in the United States, 1979 through 1983. *J Bone Joint Surg Am*, 1986; 68: 716–719.
- 15) Bostman O, Pihlajamaki H. Routine implant removal after fracture surgery: a potentially reducible consumer of hospital resources in trauma units. *J Trauma*, 1996; 41: 846–849.
- 16) Alanay A, Vyas R, Shamie AN, Sciocia T, Randolph G, Wang JC. Safety and efficacy of implant removal for patients with recurrent back pain after a failed degenerative lumbar spine surgery. *Journal of spinal disorders & techniques*, 2007; 20: 271–277.
- 17) Rathjen K, Wood M, McClung A, Vest Z. Clinical and radiographic results after implant removal in idiopathic scoliosis. *Spine*, 2007; 32: 2184–2188.
- 18) Hanson B, van der Werken C, Stengel D. Surgeons' beliefs and perceptions about removal of orthopaedic implants. *BMC Musculoskeletal disorders*, 2008; 9: 73.
- 19) Stavridis SI, Bucking P, Schaeren S, Jeanneret B, Schnake KJ. Implant removal after posterior stabilization of the thoraco-lumbar spine. *Arch Orthop Trauma Surg*, 2010; 130: 119–123.
- 20) Alpert HW, Farley FA, Caird MS, Hensing RN, Li Y, Vanderhave KL. Outcomes following removal of instrumentation after posterior spinal fusion. *J Pediatr Orthop*, 2014; 34: 613–617.