

# Correlation and Reliability of Cervical Sagittal Alignment Parameters between Lateral Cervical Radiograph and Lateral Whole-Body EOS Stereoradiograph

Weerasak Singhatanadgige<sup>1</sup> Daniel G. Kang<sup>2</sup> Panya Luksanapruksa<sup>3</sup> Colleen Peters<sup>2</sup> K. Daniel Riew<sup>4</sup>

<sup>1</sup>Department of Orthopedic Surgery, Faculty of Medicine, Chulalongkorn University and King Chulalongkorn Memorial Hospital, Thai Red Cross Society, Bangkok, Thailand

<sup>2</sup>Department of Orthopedic Surgery, Washington University, St. Louis, Missouri, United States

<sup>3</sup>Department of Orthopedic Surgery, Faculty of Medicine, Siriraj Hospital, Mahidol University, Bangkok, Thailand

<sup>4</sup>Department of Orthopedic Surgery, Columbia University, New York, New York, United States

Address for correspondence Weerasak Singhatanadgige, MD, MS, Department of Orthopedic Surgery, Faculty of Medicine, Chulalongkorn University and King Chulalongkorn Memorial Hospital, Thai Red Cross Society, 1873 Rama IV Road, Pathumwan, Bangkok, Thailand 10330 (e-mail: dr.weerasaks@gmail.com).

Global Spine J 2015;6:548–554.

## Abstract

**Study Design** Retrospective analysis.

**Objective** To evaluate the correlation and reliability of cervical sagittal alignment parameters obtained from lateral cervical radiographs (XRs) compared with lateral whole-body stereoradiographs (SRs).

**Methods** We evaluated adults with cervical deformity using both lateral XRs and lateral SRs obtained within 1 week of each other between 2010 and 2014. XR and SR images were measured by two independent spine surgeons using the following sagittal alignment parameters: C2–C7 sagittal Cobb angle (SCA), C2–C7 sagittal vertical axis (SVA), C1–C7 translational distance (C1–7), T1 slope (T1-S), neck tilt (NT), and thoracic inlet angle (TIA). Pearson correlation and paired *t* test were used for statistical analysis, with intra- and interrater reliability analyzed using intraclass correlation coefficient (ICC).

**Results** A total of 35 patients were included in the study. We found excellent intrarater reliability for all sagittal alignment parameters in both the XR and SR groups with ICC ranging from 0.799 to 0.994 for XR and 0.791 to 0.995 for SR. Interrater reliability was also excellent for all parameters except NT and TIA, which had fair reliability. We also found excellent correlations between XR and SR measurements for most sagittal alignment parameters; SCA, SVA, and C1–C7 had  $r > 0.90$ , and only NT had  $r < 0.70$ . There was a significant difference between groups, with SR having lower measurements compared with XR for both SVA (0.68 cm lower,  $p < 0.001$ ) and C1–C7 (1.02 cm lower,  $p < 0.001$ ). There were no differences between groups for SCA, T1-S, NT, and TIA.

**Conclusion** Whole-body stereoradiography appears to be a viable alternative for measuring cervical sagittal alignment parameters compared with standard radiography.

## Keywords

- ▶ cervical lateral radiograph
- ▶ EOS
- ▶ whole-body stereoradiography
- ▶ cervical sagittal alignment
- ▶ reliability
- ▶ correlation

received  
August 5, 2015  
accepted after revision  
September 29, 2015  
published online  
November 26, 2015

DOI <http://dx.doi.org/10.1055/s-0035-1569462>  
ISSN 2192-5682.

© 2016 Georg Thieme Verlag KG  
Stuttgart · New York

License terms



XR and SR demonstrated excellent correlation for most sagittal alignment parameters except NT. However, SR had significantly lower average SVA and C1–C7 measurements than XR. The lower radiation exposure using single SR has to be weighed against its higher cost compared with XR.

## Introduction

Cervical sagittal alignment is an important component of global spinal alignment, allowing optimized energy expenditure during upright human posture by positioning the head over the pelvis and maintaining appropriate horizontal gaze.<sup>1</sup> Cervical radiographs (XRs) are most commonly performed in the standing position with the arms relaxed on either side of the body, which is considered the most physiologic position during standing. Advances in imaging technology have continued, and recently there has been increasing interest in the use of standing whole-body stereoradiography (SR) when evaluating spinal deformity. The purported advantages of SR include lack of magnification, lack of parallax distortion, simultaneous two-dimensional (anteroposterior and lateral) high-quality imaging of the entire skeleton with lower radiation exposure, as well as capabilities for three-dimensional image reconstruction.<sup>2</sup> However, both arms must be forward flexed at the shoulders during SR imaging to reduce obstruction by arm overlapping the thoracic and lumbar regions, and a previous study has found arm positioning, particularly arms flexed with hands touching the clavicle, may change cervical sagittal alignment during XR imaging. Previous studies have demonstrated that arm positioning is an important factor during XR imaging, changing sagittal alignment parameters of the thoracic and lumbar spine.<sup>3–8</sup> In fact, Park et al found that lateral whole-spine XRs with hands positioned touching the clavicle were associated with a decrease in T1 slope (T1-S), posterior translation of the head, hypolordotic cervical spine, and downward gazing when compared with standing lateral cervical XRs with arms relaxed on either side of the body.<sup>9</sup>

To our knowledge, no study to date has compared cervical sagittal alignment parameters obtained from standing lateral cervical XRs versus lateral whole-body SRs. The purpose of this study is to evaluate the correlation and reliability of cervical sagittal alignment parameters measured from lateral cervical XRs compared with lateral whole-body EOS SRs (EOS Imaging, Paris, France). We hypothesized that the difference in arm position and in the trajectory of the radiation beam between standard cervical XR and SR would result in a difference for all cervical sagittal alignment parameters.

## Materials and Methods

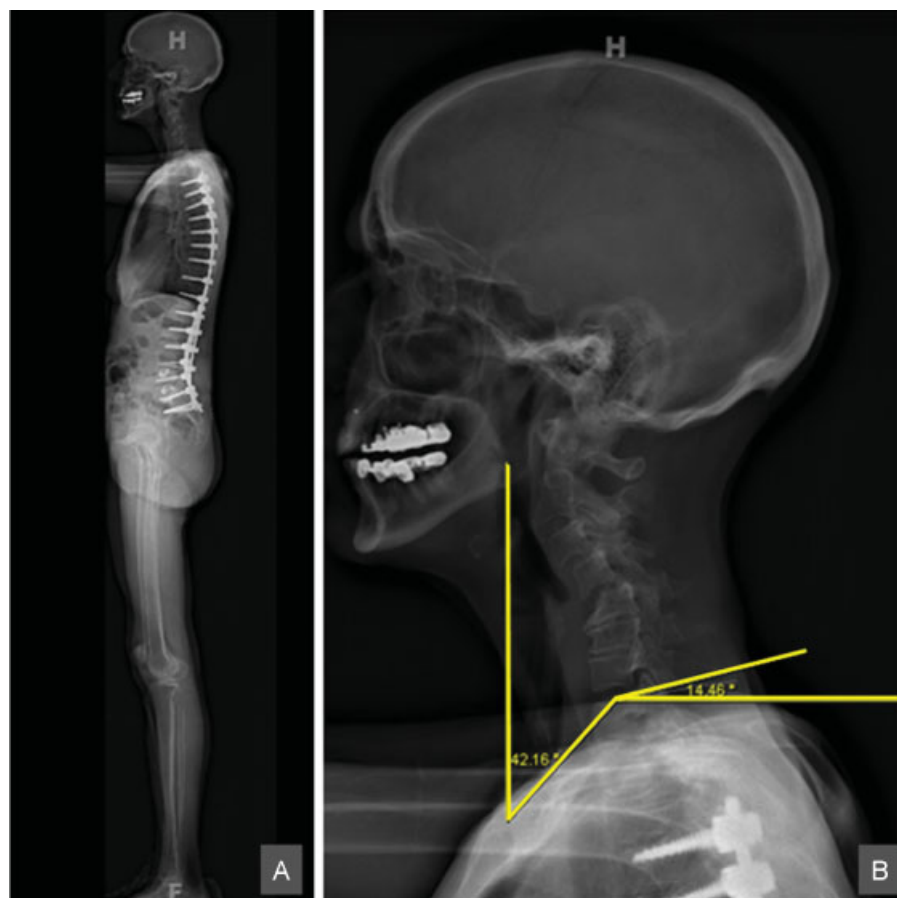We retrospectively evaluated adult patients with a primary diagnosis of cervical deformity treated by a single surgeon between January 2010 and December 2014 with both lateral cervical XRs and lateral SRs obtained within 1 week of each other. At our institution, lateral cervical XRs are routinely obtained with the patient standing, with the arms in a relaxed neutral position, hanging at the side of the body; this image is

compared with SRs obtained with EOS imaging, which are acquired with patients standing and arms forward flexed at the shoulders.

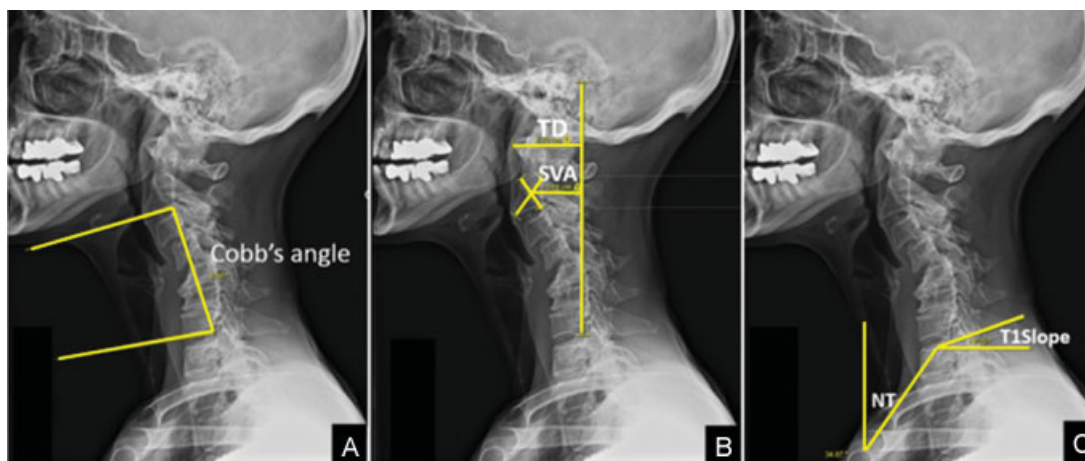
Cervical sagittal alignment measurements were performed using a picture archiving and communications system, with each XR measured side by side on the same computer monitor to allow equal magnification/resolution of the cervical region from the lateral whole-body SR compared with the lateral cervical XR (→ Fig. 1). For each patient, XR and SR images were measured by two independent spine surgeon reviewers on two separate occasions, using the following cervical sagittal alignment parameters: C2–C7 sagittal Cobb angle (SCA), C2–C7 sagittal vertical axis (SVA), C1–C7 translational distance (C1–C7), T1-S, neck tilt (NT), and thoracic inlet angle (TIA) (→ Fig. 2).

C2–C7 Cobb angle was measured by drawing the angle between a line parallel to the inferior end plate of C2 and a line parallel to the inferior end plate of C7.<sup>10</sup> Positive values demonstrate kyphotic alignment and negative values, lordotic alignment. The distance between the vertical plumb line from the center of C2 and the vertical line from the posterosuperior corner of C7 was measured for C2–C7 SVA. Translational distance was defined by the distance from anterior tubercle of C1 to the vertical line from the posteroinferior corner of C7 to evaluate the horizontal translation of the head position.<sup>10</sup> T1-S was defined by the angle between the line parallel to the upper end plate of T1 and the horizontal line.<sup>11</sup> NT is the angle formed by the line from the mid-T1 upper end plate to the cranial-most aspect of the midsternum and the vertical line from the cranial-most aspect of the midsternum. TIA was then calculated by the formula  $TIA = T1\ Slope + NT$ .<sup>12</sup>

The measuring parameters from cervical XR and SR were analyzed using R package “irr.” The intrarater reliability was quantified by intraclass correlation coefficient (ICC) (3, 1), termed by Shrout and Fleiss.<sup>13</sup> This type of ICC is appropriate when study patients are a random sample of the underlying patient population, and a test and retest are only two occasions of interest. Only two variance components are involved: the variance of study subjects and the variance of random errors. The interrater reliability was quantified by ICC (2, 1). This type of ICC is appropriate when both study patients and raters are a random sample from their respectively underlying populations. Three variance components are involved: the variance of the study subjects, the variance of the raters, and the variance of random errors. ICC values of more than 0.75 represent excellent reliability, values between 0.4 and 0.75 represent fair to good reliability, and value less than 0.4 represent poor reliability.<sup>14</sup> The relationships between the parameters obtained from XRs and those from SRs were compared by correlation analysis (Pearson correlation coefficient) and paired *t* test. A *p* value less than 0.05 was considered statistically significant.



**Fig. 1** (A) Whole-body lateral stereoradiography. (B) Magnified cervical spine from whole-body lateral stereoradiography.



**Fig. 2** Measurement parameters. (A) C2–C7 Cobb angle. (B) C2–C7 sagittal vertical axis (SVA) and C1–C7. (C) T1-slope and neck tilt (NT). Abbreviation: TD, translational distance.

## Results

A total of 35 (12 male, 23 female) patients, with mean age of 59 years old, were included in the study.

### Intrarater Reliability

Intrarater reliability was excellent for all cervical sagittal alignment parameters in both the XR and SR groups, with ICC ranging from 0.799 to 0.994 for XR and 0.791 to 0.995 for SR. C1–C7 demonstrated the highest intrarater ICC in both groups

(0.994 XR, 0.995 SR), with NT having the lowest intrarater ICC in both groups (0.799 XR, 0.791 SR; ► **Table 1**).

### Interrater Reliability

Interrater reliability was excellent for all cervical sagittal alignment parameters in both the XR and SR groups, except NT and TIA parameters, which had fair reliability. Interrater ICC was highest for SVA (0.990) in the XR group and C1–C7 (0.978) in the SR group, with NT having the lowest interrater ICC in both groups (0.465 XR, 0.414 SR; ► **Table 2**).

**Table 1** Intratester reliability of cervical sagittal alignment

Parameters	Cervical lateral radiograph						EOS lateral stereoradiograph (EOS Imaging, Paris, France)					
	Measuror 1			Measuror 2			Measuror 1			Measuror 2		
	ICC <sup>a</sup>	95% CI	P	ICC <sup>a</sup>	95% CI	P	ICC <sup>a</sup>	95% CI	P	ICC <sup>a</sup>	95% CI	P
C2-C7 Cobb angle (degrees)	0.986	0.972-0.993	<0.001	0.966	0.934-0.983	<0.001	0.987	0.974-0.993	<0.001	0.962	0.926-0.981	<0.001
C2-C7 SVA (cm)	0.994	0.988-0.997	<0.001	0.986	0.973-0.993	<0.001	0.992	0.983-0.996	<0.001	0.969	0.939-0.984	<0.001
C1-C7 (cm)	0.994	0.989-0.997	<0.001	0.994	0.988-0.997	<0.001	0.995	0.991-0.998	<0.001	0.981	0.964-0.991	<0.001
T1-S (degrees)	0.947	0.897-0.973	<0.001	0.965	0.931-0.982	<0.001	0.943	0.891-0.971	<0.001	0.944	0.892-0.971	<0.001
NT (degrees)	0.799	0.637-0.893	<0.001	0.897	0.806-0.947	<0.001	0.895	0.803-0.946	<0.001	0.791	0.624-0.889	<0.001
TIA (degrees)	0.850	0.723-0.921	<0.001	0.926	0.859-0.962	<0.001	0.900	0.811-0.948	<0.001	0.870	0.758-0.932	<0.001

Abbreviations: CI, confidence interval; ICC, intraclass correlation coefficient; NT, neck tilt; SVA, sagittal vertical axis; T1-S, T1 slope; TIA, thoracic inlet angle.  
 Note: 95% CI is the 95% upper and lower boundaries for the confidence interval of ICC.  
<sup>a</sup>ICC (3, 1); two random sample components model, two tails.

**Table 2** Interrater reliability of cervical sagittal alignment

Parameters	Cervical lateral radiograph			EOS lateral stereoradiograph (EOS Imaging, Paris, France)								
	First measurement			Second measurement			First measurement			Second measurement		
	ICC <sup>a</sup>	95% CI	P	ICC <sup>a</sup>	95% CI	P	ICC <sup>a</sup>	95% CI	P	ICC <sup>a</sup>	95% CI	P
C2-C7 Cobb angle (degrees)	0.956	0.915-0.977	<0.001	0.943	0.891-0.971	<0.001	0.957	0.918-0.978	<0.001	0.959	0.921-0.979	<0.001
C2-C7 SVA (cm)	0.990	0.981-0.995	<0.001	0.969	0.940-0.984	<0.001	0.974	0.948-0.987	<0.001	0.951	0.901-0.975	<0.001
C1-C7 (cm)	0.983	0.966-0.991	<0.001	0.979	0.959-0.989	<0.001	0.978	0.957-0.989	<0.001	0.968	0.936-0.984	<0.001
T1-S (degrees)	0.851	0.666-0.930	<0.001	0.884	0.621-0.954	<0.001	0.795	0.629-0.891	<0.001	0.793	0.523-0.904	<0.001
NT (degrees)	0.486	-0.099-0.800	0.086	0.465	-0.101-0.778	0.079	0.414	-0.089-0.725	0.067	0.454	-0.087-0.757	0.062
TIA (degrees)	0.700	0.340-0.859	0.001	0.803	0.547-0.909	<0.001	0.499	0.132-0.730	0.005	0.704	0.398-0.854	<0.001

Abbreviations: CI, confidence interval; ICC, intraclass correlation coefficient; NT, neck tilt; SVA, sagittal vertical axis; T1-S, T1 slope; TIA, thoracic inlet angle.  
 Note: 95% CI is 95% upper and lower boundaries for the confidence interval of ICC.  
<sup>a</sup>ICC (2, 1); three random sample components model, two tails.

### Correlation Analysis XR versus SR

We found excellent correlations between XR and SR measurements for most cervical sagittal alignment parameters, with SCA, SVA, and C1–C7 having  $r > 0.90$ . T1-S and TIA were between 0.75 and 0.90, and only NT had an  $r < 0.70$ . We found a significant difference between the groups, with SR having lower measurements compared with XR for both SVA (0.68 cm lower,  $p < 0.001$ ) and C1–C7 (1.02 cm lower,  $p < 0.001$ ). There were no differences between the groups for the other cervical sagittal alignment parameters (SCA, T1-S, NT, and TIA; ► **Tables 3** and **4**, ► **Fig. 3**).

### Discussion

Cervical sagittal imbalance remains a complex problem,<sup>9,15</sup> and optimal imaging to assess cervical sagittal alignment parameters is important during patient evaluation and particularly preoperative planning. When cervical sagittal imbalance or deformity is identified, additional standing full-length spine XRs are recommended to assess whether other regions of the spine may also have deformity and contribute to global sagittal imbalance. However, obtaining several separate XRs is often time-consuming with repeated radiation exposure. Recent advances in imaging techniques

**Table 3** Correlation of cervical alignment parameters between cervical lateral radiograph and lateral whole-body stereoradiograph (from measurer 1)

Parameters	First measurement				Second measurement			
	Radiograph, mean (SD)	EOS, mean (SD)	Pearson correlation coefficient	$p^a$	Radiograph, mean (SD)	EOS, mean (SD)	Pearson correlation coefficient	$p^a$
C2–C7 Cobb angle (degrees)	2.55 (24.12)	4.21 (24.93)	0.970	0.118	2.65 (24.67)	4.52 (24.97)	0.975	0.055
C2–C7 SVA (cm)	5.02 (2.79)	4.37 (2.45)	0.945	<0.001	5.04 (2.77)	4.46 (2.45)	0.953	<0.001
C1–C7 (cm)	7.74 (3.61)	6.75 (3.18)	0.945	<0.001	7.79 (3.76)	6.83 (3.31)	0.952	<0.001
T1-S (degrees)	31.36 (13.53)	30.91 (12.22)	0.848	0.714	31.92 (14.66)	29.25 (12.91)	0.824	0.067
NT (degrees)	46.90 (9.63)	48.50 (9.79)	0.598	0.282	45.81 (7.84)	48.29 (9.72)	0.583	0.081
TIA (degrees)	78.26 (14.13)	79.42 (12.89)	0.783	0.456	77.72 (15.67)	77.54 (14.28)	0.801	0.912

Abbreviations: NT, neck tilt; SD, standard deviation; SVA, sagittal vertical axis; T1-S, T1 slope; TIA, thoracic inlet angle.

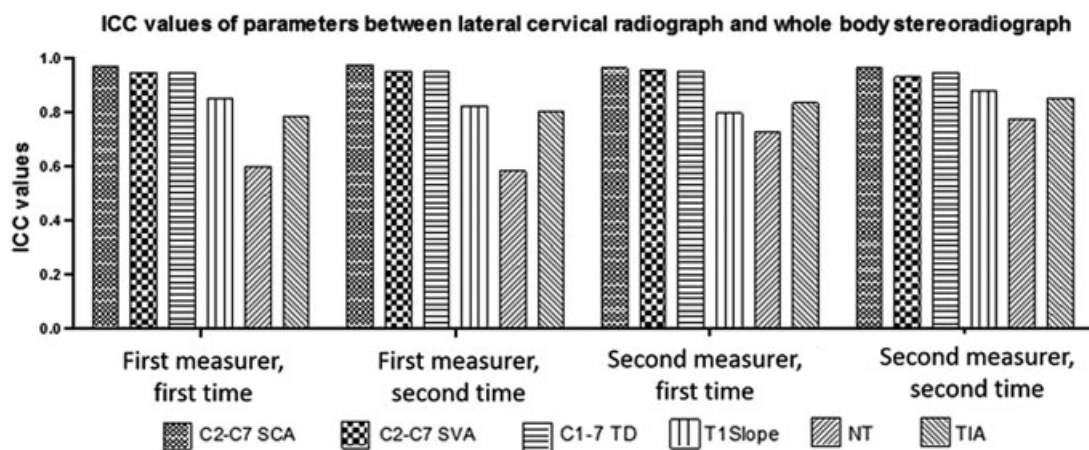
<sup>a</sup>Paired *t* test (two tails).

**Table 4** Correlation of cervical alignment parameters between cervical lateral radiograph and lateral whole-body stereoradiography (from measurer 2)

Parameters	First measurement				Second measurement			
	Radiograph, mean (SD)	EOS, mean (SD)	Pearson correlation coefficient	$p^a$	Radiograph, mean (SD)	EOS, mean (SD)	Pearson correlation coefficient	$p^a$
C2–C7 Cobb angle (degrees)	1.81 (22.88)	3.38 (24.78)	0.963	0.175	1.78 (23.85)	3.40 (24.10)	0.962	0.157
C2–C7 SVA (cm)	4.96 (2.73)	4.38 (2.45)	0.956	<0.001	5.10 (2.80)	4.21 (2.35)	0.931	<0.001
C1–C7 (cm)	7.66 (3.74)	6.58 (3.25)	0.951	<0.001	7.67 (3.75)	6.60 (3.23)	0.947	<0.001
T1-S (degrees)	35.10 (14.69)	33.39 (14.31)	0.796	0.282	36.49 (16.35)	34.18 (15.40)	0.879	0.091
NT (degrees)	36.08 (10.11)	36.91 (12.18)	0.726	0.564	35.90 (10.40)	36.70 (13.10)	0.775	0.574
TIA (degrees)	71.18 (16.63)	70.30 (17.21)	0.833	0.597	72.39 (16.34)	70.88 (18.13)	0.853	0.351

Abbreviations: NT, neck tilt; SD, standard deviation; SVA, sagittal vertical axis; T1-S, T1 slope; TIA, thoracic inlet angle.

<sup>a</sup>Paired *t* test (two tails).



**Fig. 3** ICC values of cervical alignment parameters between lateral cervical radiograph and lateral whole-body stereoradiography. Abbreviations: ICC, intraclass correlation coefficient; NT, neck tilt; SCA, sagittal Cobb angle; SVA, sagittal vertical axis; TD, translational distance; TIA, thoracic inlet angle.

include full-body SR, which allows low-dose, high-quality imaging of the entire spinal column and pelvis, as well as assessing for concomitant length discrepancy/deformity of the lower extremities and joints (hips, knees, ankles).<sup>16</sup> Despite the purported advantages of SR, the difference in arm positioning compared with the standing lateral cervical XR and the effect on cervical sagittal alignment parameters is not completely understood.

Our study found most cervical sagittal alignment parameters (SCA, SVA, and C1–C7) measured from lateral cervical XRs and lateral whole-body EOS SRs had excellent correlation, with excellent intra- and interrater reliability in both groups. Our results regarding SCA are similar to a previous report by Vidal et al that also found excellent intra- (ICC = 0.847 to 0.955) and interrater (ICC = 0.846 to 0.954) reliability for SCA measured on SR imaging, both in the upper cervical spine (C1–C3) and lower cervical spine (C3–C7).<sup>14</sup> However, this study was performed in patients with adolescent idiopathic scoliosis, and although global sagittal alignment using the C7 plumb line was also found to have excellent reliability, other cervical sagittal alignment parameters were not evaluated.

Intra- and interrater reliability were lowest for NT and TIA, which had fair reliability. We postulate the lower reliability for NT and TIA was due to poor visualization of the sternum on both imaging techniques, and they may be suboptimal cervical sagittal alignment parameters in the setting of spinal deformity. Similarly, there was only fair correlation between the XR and SR groups for NT, which further emphasizes that NT may not be an ideal cervical sagittal alignment parameter.

The most important finding from our study was the significant difference in mean values for both SVA and C1–C7 between the XR and SR groups. We found the SR group had a mean SVA that was 0.68 cm lower and mean C1–C7 that was 1.02 cm lower than the XR group, although there was excellent correlation with  $r > 0.900$  for both measurements. The most plausible explanation for our findings is the difference in arm positioning during XR and SR imaging, with forward arm flexion during SR causing the head position to shift posteriorly. Our findings are similar to a previous study

by Park et al, who evaluated cervical sagittal alignment parameters in 101 asymptomatic adults and found that lateral whole-spine XRs with arms flexed in the hand-touching-clavicle position also resulted in posterior head translation compared with lateral cervical XRs.<sup>9</sup> However, the study also found the arm-flexed position in the whole-spine XRs resulted in significantly lower T1-S, cervical hypolordosis, and downward gaze. Our study did not find differences in T1-S or SCA; however, this discrepancy may be explained by the smaller sample size of our study, as well as the difference in studied population between symptomatic adults with cervical deformity versus asymptomatic adults. We postulate that patients with symptomatic cervical deformity have degenerative changes with less flexibility of the subaxial spine. Also, the forward flexion arm position for SR is not as exaggerated as the whole-spine lateral XR, which requires additional muscle activation/strain with elbow and wrist flexion to touch the clavicles.

Weaknesses of our study include the retrospective design and the potential for selection bias based on nonconsecutive sampling of patients. Also, changes in pain or worsening deformity over time may have resulted in differences in cervical sagittal alignment parameters; however, we attempted to reduce this confounding variable by including only patients with XR and SR images obtained less than 1 week apart. Also, our study may have had insufficient sample size to avoid type II error for various cervical sagittal alignment parameters.

## Conclusion

Based on the findings of our study, we believe SR is a reliable method for determining most cervical sagittal alignment parameters and a viable alternative to lateral cervical XR despite differences in arm position during imaging. However, measurements requiring visualization of the sternum such as NT and TIA may not be reliable and do not appear to be optimal cervical sagittal alignment parameters. Also, SR results in slight posterior head translation and subsequently

lower SVA and C1–7 translational distance compared with lateral cervical XR and may underestimate regional cervical sagittal alignment parameters in patients with cervical deformity or sagittal imbalance. The lower radiation exposure using single SR has to be weighed against its higher cost compared with XR.

#### Disclosures

Weerasak Singhatanadgige, none

Daniel G. Kang, none

Panya Luksanaprukha, none

Colleen Peters, none

K. Daniel Riew, Board membership: AOSpine; Royalties: Biomet, Metronic; Grant: AOSpine, Cerapedics, Metronic; Honorarium: NASS, AOSpine

#### References

- Duval-Beaupère G, Schmidt C, Cosson P. A Barycentremetric study of the sagittal shape of spine and pelvis: the conditions required for an economic standing position. *Ann Biomed Eng* 1992;20(4):451–462
- Morvan G, Mathieu P, Vuillemin V, et al. Standardized way for imaging of the sagittal spinal balance. *Eur Spine J* 2011;20(5, Suppl 5):602–608
- Marks MC, Stanford CF, Mahar AT, Newton PO. Standing lateral radiographic positioning does not represent customary standing balance. *Spine (Phila Pa 1976)* 2003;28(11):1176–1182
- Marks M, Stanford C, Newton P. Which lateral radiographic positioning technique provides the most reliable and functional representation of a patient's sagittal balance? *Spine (Phila Pa 1976)* 2009;34(9):949–954
- Horton WC, Brown CW, Bridwell KH, Glassman SD, Suk SI, Cha CW. Is there an optimal patient stance for obtaining a lateral 36° radiograph? A critical comparison of three techniques. *Spine (Phila Pa 1976)* 2005;30(4):427–433
- Aota Y, Saito T, Uesugi M, Ishida K, Shinoda K, Mizuma K. Does the fists-on-clavicles position represent a functional standing position? *Spine (Phila Pa 1976)* 2009;34(8):808–812
- Faro FD, Marks MC, Pawelek J, Newton PO. Evaluation of a functional position for lateral radiograph acquisition in adolescent idiopathic scoliosis. *Spine (Phila Pa 1976)* 2004;29(20):2284–2289
- Vedantam R, Lenke LG, Bridwell KH, Linville DL, Blanke K. The effect of variation in arm position on sagittal spinal alignment. *Spine (Phila Pa 1976)* 2000;25(17):2204–2209
- Park SM, Song KS, Park SH, Kang H, Daniel Riew K. Does whole-spine lateral radiograph with clavicle positioning reflect the correct cervical sagittal alignment? *Eur Spine J* 2015;24(1):57–62
- Harrison DE, Harrison DD, Cailliet R, Troyanovich SJ, Janik TJ, Holland B. Cobb method or Harrison posterior tangent method: which to choose for lateral cervical radiographic analysis. *Spine (Phila Pa 1976)* 2000;25(16):2072–2078
- Scheer JK, Tang JA, Smith JS, et al; International Spine Study Group. Cervical spine alignment, sagittal deformity, and clinical implications: a review. *J Neurosurg Spine* 2013;19(2):141–159
- Lee SH, Kim KT, Seo EM, Suk KS, Kwack YH, Son ES. The influence of thoracic inlet alignment on the craniocervical sagittal balance in asymptomatic adults. *J Spinal Disord Tech* 2012;25(2):E41–E47
- Shrout PE, Fleiss JL. Intraclass correlations: uses in assessing rater reliability. *Psychol Bull* 1979;86(2):420–428
- Vidal C, Ilharreborde B, Azoulay R, Sebag G, Mazda K. Reliability of cervical lordosis and global sagittal spinal balance measurements in adolescent idiopathic scoliosis. *Eur Spine J* 2013;22(6):1362–1367
- Tang JA, Scheer JK, Smith JS, et al; ISSG. The impact of standing regional cervical sagittal alignment on outcomes in posterior cervical fusion surgery. *Neurosurgery* 2012;71(3):662–669, discussion 669
- Illés T, Somoskeőy S. The EOS™ imaging system and its uses in daily orthopaedic practice. *Int Orthop* 2012;36(7):1325–1331