

Received: 2012.12.19
Accepted: 2013.02.08
Published: 2013.05.23

ISSN 1507-6164
© Am J Case Rep, 2013; 14: 169-172
DOI: 10.12659/AJCR.883920

Sticky platelets syndrome in a young patient with massive pulmonary embolism

Authors' Contribution:
Study Design A
Data Collection B
Statistical Analysis C
Data Interpretation D
Manuscript Preparation E
Literature Search F
Funds Collection G

ABCDEF 1 **Stanislava Darulová**
ABCDEF 1 **Matej Samoš**
BCDE 2 **Juraj Sokol**
BCD 2 **Radoslava Šimonová**
ADEF 1 **František Kovář**
ADEF 1 **Peter Galajda**
DEF 2 **Ján Staško**
DEF 2 **Peter Kubisz**
ADEF 1 **Marián Mokán**

1 Department of Internal Medicine I, Jessenius Faculty of Medicine, Comenius University, Martin, Slovak Republic
2 Department of Haematology and Blood Transfusion, Jessenius Faculty of Medicine, Comenius University, Martin, Slovak Republic

Corresponding Author: Matej Samoš, e-mail: matej.samos@gmail.com

Patient: Female, 51
Final Diagnosis: Sticky platelets syndrome
Symptoms: Pulmonary embolism
Medication: —
Clinical Procedure: Thrombolysis
Specialty: Hematology

Objective: Disease of unknown etiology

Background: Sticky platelets syndrome (SPS) is an inherited thrombophilia characterized by platelet hyperaggregability, which can lead to the higher risk of thrombosis. The etiology of SPS remains unclear, but several gene polymorphisms have been recently studied and autosomal dominant heredity is suspected. Although SPS is traditionally connected with arterial thrombosis, several cases of SPS as a cause of venous thromboembolism have been described.

Case Report: We report the case of a 51-year-old apparently healthy woman with massive pulmonary embolism, who required thrombolytic therapy. In this patient SPS was identified as the only condition leading to higher risk of developing thromboembolic disease.

Conclusions: Although at present few physicians have practical experience with SPS, this syndrome may lead to serious health problems or even death. The presented case points to the benefit of SPS diagnostics in standard screening of inherited thrombophilia for effective prophylaxis and treatment in patients with venous thromboembolism.

Key words: sticky platelets syndrome • venous thromboembolism • inherited thrombophilia screening

Full-text PDF: <http://www.amjcaserep.com/download/index/idArt/883920>



1284



1



2



15

Background

Sticky platelets syndrome (SPS) is an inherited thrombophilia [1] characterized by platelet hyperaggregability, which can increase risk of thrombosis. The diagnosis of SPS is based on laboratory detection of increased platelet aggregation using aggregometry (optical/impedance) with low ADP and/or epinephrine (adrenaline) concentrations, while aggregation after other inducers remain normal [2]. According to the inducer causing platelet hyperaggregation, 3 main types of SPS can be detected. The etiology of SPS remains unclear, but several gene polymorphisms have been recently studied [3,4] and an autosomal dominant heredity is suspected [5,6]. Although SPS is traditionally connected with arterial thrombosis, several cases have been reported in which SPS was a cause of venous thromboembolism [1,7–9].

We report the case of a 51-year-old apparently healthy woman presenting with pulmonary embolism, in which SPS was identified as the only condition leading to higher risk of thromboembolic disease development.

Case Report

A 51-year-old woman was admitted to the internal medicine department in a state of shock of unclear etiology. She was hypotensive, tachycardic, and dyspneic, with incipient blue mask. On ECG the typical signs of pulmonary embolism were detected (Figure 1) and according to the CT-pulmo-angiographic examination, bilateral massive pulmonary embolism was clearly confirmed (Figure 2). The shock was immediately treated with volume expanders (*Gelafundine 500 ml intravenously 6 times*) and vasoactive therapy (*Noradrenaline 8 mg in 5% glucose 500 ml, 1ml/hour intravenously*) was begun. After getting the patient's condition under control, thrombolytic therapy was initiated. According to current guidelines, the thrombolytic therapy was started with an intravenous bolus of alteplase 10 mg and then 40 mg intravenously during the first hour and

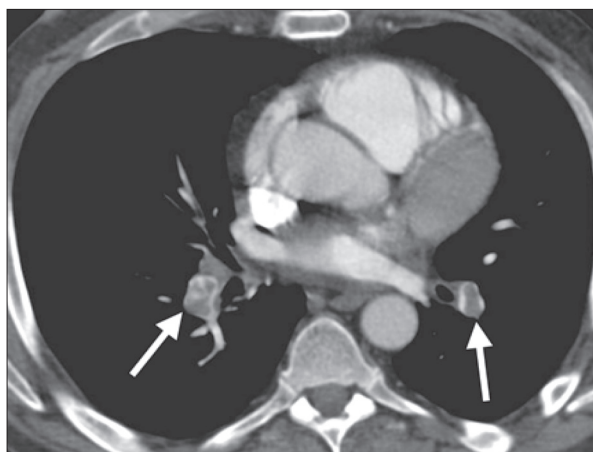


Figure 2. CT – pulmoangiography.

50 mg intravenously during the second hour. Intravenous anticoagulation with heparin was initiated after alteplase treatment to complete the treatment (*Heparin 10 000 j. bolus and consequently 1000 units/hour intravenously*). This therapy was administrated with a positive effect and led to the stabilization of patient's condition.

After stabilization of patient's condition, the cause of pulmonary embolism was investigated, but there was nothing in the history suggesting a cause. The patient was normostenic, with BMI 23, a non-smoker, without hormonal therapy or contraception. Except of a simple infection of the upper airways last month, she was healthy, without any history of serious internal diseases, trauma, or surgery.

According to the differential diagnosis of pulmonary embolism, the patient underwent deep venous system ultrasonography, but no thrombosis was found.

To exclude inflammation as an etiologic agent, a search for all focuses was subsequently conducted. The patient was examined by a stomatologist and an otorhinolaryngologist; cultivation of nasal and throat swabs was done and gastrofibroscopy

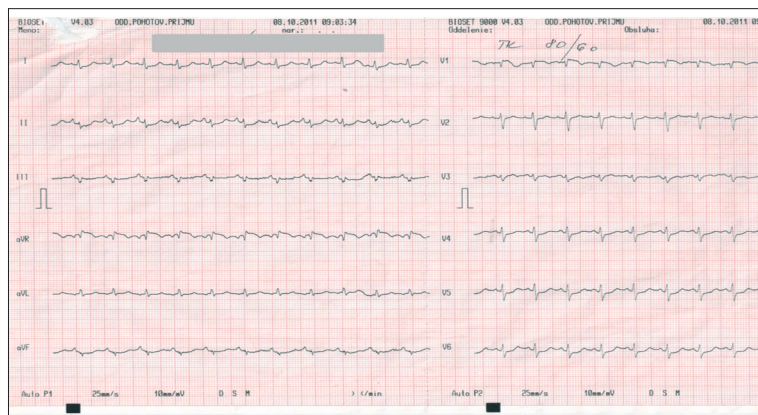


Figure 1. Patient's ECG on admission.

Table 1. Haematological screening for the thrombophilic state.

PCR DNA analysis	Coagulation factors function	Natural coagulation inhibitors
Methyl Tetrahydrofolate Reductase C677T: C/T	Factor VIII function: 1,883 IU/ml	Antithrombin III function: 104,2%
Factor V Leiden R506Q: G/G	Factor XI function: 1,35 IU/ml	Protein C function: 135%
Factor II ntG20210A: G/G		Protein S function: 84%
CYP4V2 p.Q259K: K/K (*cytochrome P450, family 4, subfamily V, polypeptide 2)		
Factor XI: c.56-282T>c: C/T		
Factor XI: c.1481-188C>T: C/T		
Screening for antiphospholipid syndrome		
1.) Anti-β2-glycoprotein I: 1,8 IU/ml 2.) Kaolin clotting time - ratio: 0,87 3.) Dilute Russell's Viper Venom Time - ratio: 1,12		
4.) Tissue thromboplastin inhibition (TTI) * TTI 1: 50 ratio: 1,28 * TTI 1: 500 ratio: 1,62		
5.) Partial thromboplastin time - lag time (PTT-LT) * PTT - LT control: 33s * PTT - LT patient: 35s * PTT - LT ratio: 1,061		
6.) Partial thromboplastin time - lupus anticoagulans (PTT-LA) * PTT - LA control: 30s * PTT - LA patient: 34,4s * PTT-LA ratio: 1,14		

* DNA CYP4 and DNA factor XI were examined just in frame of the research of importance of these polymorphisms for venous thrombembolism incidence.

was also preformed, but no pathology was found. Gynecological examination was without any pathological finding, except for a hematoma of the right breast as a side effect of thrombolysis.

Screening for oncologic diseases (hemocult testing of stool, onco markers – CA 19-9, 125, 15-3, CEA, alpha-phetoprotein, CT of lungs and abdomen) was also negative; therefore, after this step the complete hematological examination for excluding the hereditary coagulation disorder was performed, but all results were normal (Table 1). Only a slight elevation of coagulation factor VIII was detected, but was most likely reactive. In DNA analysis, only the heterozygote form of MTHFR mutation was found. After completion of all screening examinations to clarify the etiology of pulmonary embolism, we decided to examine the platelet aggregometry. Although SPS does not typical cause pulmonary embolism, in our patient we confirmed SPS type I using optical aggregometry.

Discussion

SPS is a hereditary thrombophilia, first described in the literature in 1983, but for a long time it has been primarily just a theoretical term with little practical basis. In 1995 it was proposed as a possible cause of unexplained arterial and venous thromboses [1]. According to Bick et al. [1] SPS is responsible for 21% of arterial and 13.2% of venous thromboembolic events that are otherwise unexplainable. However, in the literature it is predominantly known as a hematologic disorder connected with arterial thrombosis. There are just a few publications about the venous complications of this syndrome.

This hereditary, probably autosomally dominant, platelet disorder can be diagnosed by using platelet aggregometry, which makes confirmation easy if the hyperaggregability of platelets is induced by subliminal concentrations of adenosine diphosphate (ADP) and epinephrine (type I), epinephrine alone (type II), or ADP alone (type III) [2,5]. After activated protein C resistance, it is the second most frequent hereditary thrombophilia, and it has been suggested that it is connected with other hereditary thrombophilic states [3]. Clinically, patients may present with symptoms of acute coronary syndrome, transient cerebral ischemic attacks, stroke, retinal thrombosis, peripheral arterial thrombosis, and venous thrombosis [5].

In our case, the SPS was also the only found risk factor explaining why a quite healthy young woman with no coagulation-influencing treatment had a highly fatal pulmonary embolism. After stabilizing the patient's condition and providing thrombolytic therapy, we started to search for the etiology of the thromboembolic event. But all basal examinations – exclusion of inflammatory and oncologic disease, and deep vein thrombosis – were negative. We continued with the screening of hereditary thrombophilia. A slight elevation of coagulation factor VIII was detected, which was most likely reactive (factor VIII is the reactant of acute phase reaction) [10], and its role as an important risk factor for venous thromboembolism is not generally accepted [11]. DNA analysis revealed the heterozygote form of methylenetetrahydrofolate reductase (MTHFR) mutation. This hereditary disorder is often connected to folic acid and vitamin B12 metabolism, and if patient has a normal level of homocysteine it is not clinically significant for the hemostatic disorder [12,13].

Nowadays, the examination of SPS is a standard part of thrombophilic screening in some hemostasis and thrombosis centres, especially in patients under age 35 years after an attack of arterial thrombosis and in patients with repeated or progressive occurrence of vein thrombosis despite anticoagulation therapy [5]. These requirements were not met by our patient

But when all performed examinations seemed to yield negative results, we decided to try platelet aggregometry, with a positive result for SPS type I. In the literature, the combination of SPS with other hereditary thrombophilic states has been described in patients with arterial and venous thrombosis, but in our case a single SPS seems to have caused the thromboembolic event.

Conclusions

Although sticky platelets syndrome has been known since 1983 [1], it is still a new phenomenon, and few clinicians have practical experience in dealing with it. Clinically, this syndrome can be silent, or it can be presented by stroke, transient cerebral ischemic attacks, acute coronary syndrome, and arterial or venous thrombosis [5]. Although some previous reports found

that SPS can be responsible for 21% of arterial thrombosis and 13.2% of venous thrombosis unexplainable by another reason, most data in the literature associates it with arterial thromboembolism [1,14]. However, the results from recently a published study suggest that it may be a more frequent cause of venous thrombosis/pulmonary embolism than is traditionally thought [15]. The criteria for its screening are limited and include only patients under age 35 and who have had arterial thrombosis, as well as patients with repeating or progressive occurrence of vein thrombosis despite anticoagulation therapy [5]. In the routine hematological screening of hereditary thrombophilia, this examination is not included. SPS testing is known and easy, but perhaps due to lack of practical experience with this thrombophilia, it is not part of the routine examination of hereditary thrombophilia. Despite this lack of clinical experience, SPS is serious risk factor for patient health and thus the benefit of SPS testing for the standard screening of thrombophilia deserves consideration.

Acknowledgments

This study was supported by project APVV (Slovak Research and Development Agency) 0222-11 and by project CEPV II (ITMS 26220120036) which is co-financed from EC sources.

References:

1. Bick RL: Sticky platelet syndrome: a common cause of unexplained arterial and venous thrombosis. *Clin Appl Thromb Hemost*, 1998; 2: 77–81
2. Bartošová L, Dobrotová M, Hollý P et al: Sticky platelet syndrome – its diagnostics and therapy. *Lek Obz*, 2008; 7–8: 512–13 [in Slovak]
3. Kubisz P, Ivanková J, Hollý P et al: The glycoprotein IIIa PLA1/A2 polymorphism – a defect responsible for Sticky platelet syndrome? *Clin Appl Thromb Hemost*, 2006; 1: 117–19
4. Muñoz X, Obach V, Hurtado B et al: Association of specific haplotypes of GAS6 gene with stroke. *Thromb Haemost*, 2007; 2: 406–12
5. Mammen EF: Ten years' experience with the „Sticky platelet syndrome“. *Clin Appl Thromb Hemost*, 1995; 1: 66–72
6. Šimonová R, Bartošová L, Chudý P et al: Nine kindreds of familiar Sticky platelet syndrome phenotype. *Clin Appl Thromb Hemost*, 2012; [Epub ahead of print]
7. Rac MW, Minns Crawford N, Worley KC: Extensive thrombosis and first trimester pregnancy loss caused by sticky platelet syndrome. *Obstet Gynecol*, 2011; 117: 501–3
8. Kahles H, Trobisch H, Kehren H: Disseminated coronary occlusion and massive pulmonary embolism in a 40-year-old woman. *Dtsch Med Wochenschr*, 2006; 131(13): 672–75
9. Muhlfeld AS, Kettcher M, Schwamborn K et al: Sticky platelet syndrome: an unrecognized cause of graft dysfunction and thromboembolic complications in renal transplant recipients. *Am J Transplant*, 2007; 7: 1865–68
10. Cucuianu M, Plesca Z, Bodizs G et al: Acute phase reaction and the hemostatic balance. *Rom J Intern Med*, 1996; 34: 13–18
11. Kyrle PA: High factor VIII and the risk of venous thromboembolism. *Hämostaseologie*, 2003; 23: 41–44
12. Yin G, Yan Z, Chen K, Jin X: C677T methyltetrahydrofolate reductase polymorphism as a risk factor involved in venous thromboembolism: A population based case – control study. *Mol Med Report*, 2012; 6: 1271–75
13. Gouvela L O, Canhao P: MTHFR and the risk for cerebral venous thrombosis – a meta – analysis. *Thromb Res*, 2010; 125: 153–58
14. Kannan S, Dhanasegaran S, Raji V: Recurrent arterial thrombosis In a young male: Sticky Platelet Syndrome. *The Internet Journal of Hematology*, 2008; 4(1): 10.5580/d76
15. Kotuličová D, Chudý P, Škereňová M et al: Variability of GP6 gene in patients with sticky platelet syndrome and deep venous thrombosis and/or pulmonary embolism. *Blood Coagul Fibrinolysis*, 2012; 23: 543–47