

## Case Report

## Bilateral Breast Reconstruction With Profunda Artery Perforator Flaps and Immediate Implant Augmentation

Carrie K. Chu, MD, MS; Michael DeFazio, MD; Rene D. Largo, MD; and Merrick Ross, MD

Aesthetic Surgery Journal Open Forum  
2020, 1–6  
© 2020 The Aesthetic Society.  
This is an Open Access article distributed  
under the terms of the Creative Commons  
Attribution-NonCommercial-NoDerivs  
licence (<http://creativecommons.org/licenses/by-nc-nd/4.0/>), which permits  
non-commercial reproduction and dis-  
tribution of the work, in any medium,  
provided the original work is not altered or  
transformed in any way, and that the work  
is properly cited. For commercial re-use,  
please contact [journals.permissions@](mailto:journals.permissions@oup.com)  
[oup.com](mailto:journals.permissions@oup.com)  
DOI: 10.1093/asjof/ojz036  
[www.asjopenforum.com](http://www.asjopenforum.com)

**OXFORD**  
UNIVERSITY PRESS

## Abstract

The smaller volume of the profunda artery perforator (PAP) flap relative to that of abdominal flaps limits the size of breast reconstruction that may be achieved. Immediate implant augmentation of abdominal free flaps has been performed, but immediate implant augmentation of PAP flaps has never been described. A 54-year-old woman with BRCA2 mutation, submuscular implants, and previous abdominoplasty presented for nipple-sparing mastectomies (NSM). Autologous tissue volume was inadequate to support reconstruction to the desired size. She wished to avoid serial expansion. Skin quality was unsuitable for direct-to-implant reconstruction. The patient underwent bilateral NSM. The previous implants were removed with capsule preservation. Bilateral PAP flaps were harvested and anastomosed to the internal mammary vessels. Moderate classic profile 170-mL smooth round silicone implants were placed into the existing capsule pockets with lateral capsulorrhaphy. There were no flap, implant, or infectious complications. Initial mastectomy skin and nipple ischemia completely resolved without necrosis. Donor site healing was uneventful. At 8 months, the reconstruction is supple and the implants remain well-positioned without rippling. One minor revision was performed for fat grafting and to correct lateral nipple deviation. PAP flap breast reconstruction with immediate implant augmentation is technically feasible. Advantages include improved prosthetic coverage, allowing for immediate reconstruction to a larger size with reduced concern regarding mastectomy skin necrosis and threat to the device, optimal implant camouflage, and improved substrate for secondary fat grafting if necessary.

## Level of Evidence: 5

Editorial Decision date: December 19, 2019; online publish-ahead-of-print January 14, 2020.

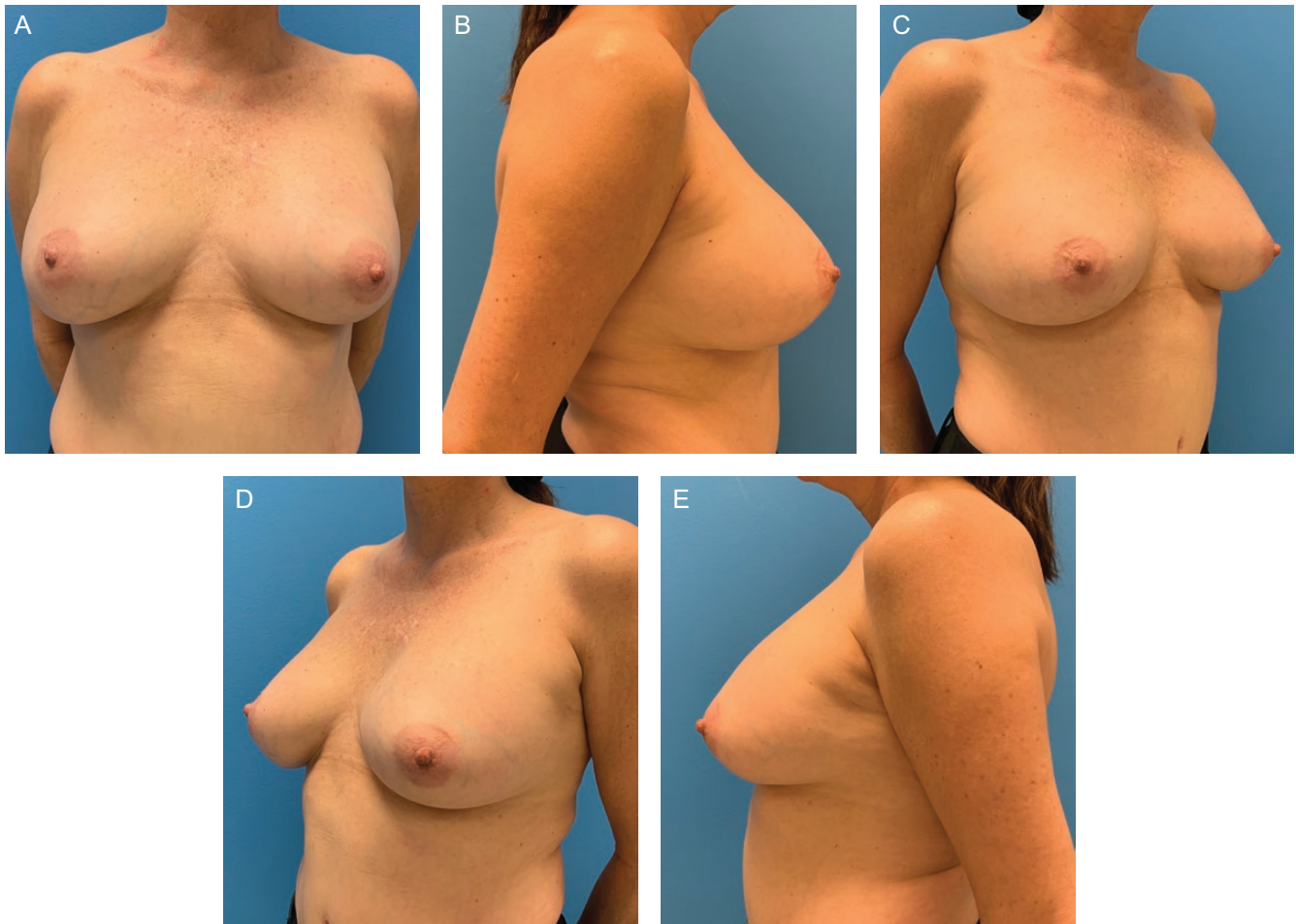

The profunda artery perforator (PAP) flap affords a favorable alternative to abdomen-based tissue options for autologous breast reconstruction. Since the initial description of the PAP flap by Allen for this indication, flap reliability and predictability have been consistently demonstrated.<sup>1-3</sup> One limitation, however, is the relatively small flap volume when compared with abdominal counterparts, rendering significant limitations to achievable size during bilateral reconstruction.

Drs Chu, DeFazio, and Largo are from Department of Plastic Surgery, The University of Texas MD Anderson Cancer Center, Houston, TX. Dr Ross is from Department of Surgical Oncology, The University of Texas MD Anderson Cancer Center, Houston, TX.

## Corresponding Author:

Dr. Carrie K. Chu, Assistant Professor, Department of Plastic Surgery, The University of Texas MD Anderson Cancer Center, 1400 Pressler Street, Unit 1488, Houston, TX 77030.  
E-mail: [ckchu@mdanderson.org](mailto:ckchu@mdanderson.org); Twitter: [@DrCarrieChu](https://twitter.com/DrCarrieChu)



**Figure 1.** Preoperative views of this 54-year-old female with BRCA gene mutation with submuscular smooth round 200-mL saline implants presenting for prophylactic nipple-sparing mastectomies and immediate reconstruction. She previously underwent traditional abdominoplasty. Body mass index was 23 kg/m<sup>2</sup>.

Options to increase breast volume and projection of autologous reconstructions include fat grafting, flap stacking, and implant augmentation.<sup>3–5</sup> Flap augmentation using implants is conventionally performed secondarily, but immediate prosthetic insertion during flap reconstruction has also been described with or without use of a bioprosthesis adjunct for implant control.<sup>5,6</sup> Advantages of immediate implant augmentation of flaps include potential for single-stage reconstruction to a larger desired size and improved device coverage.<sup>6</sup> Possible disadvantages include risk of flap compromise, prosthetic infection, and implant malposition.<sup>5,7</sup>

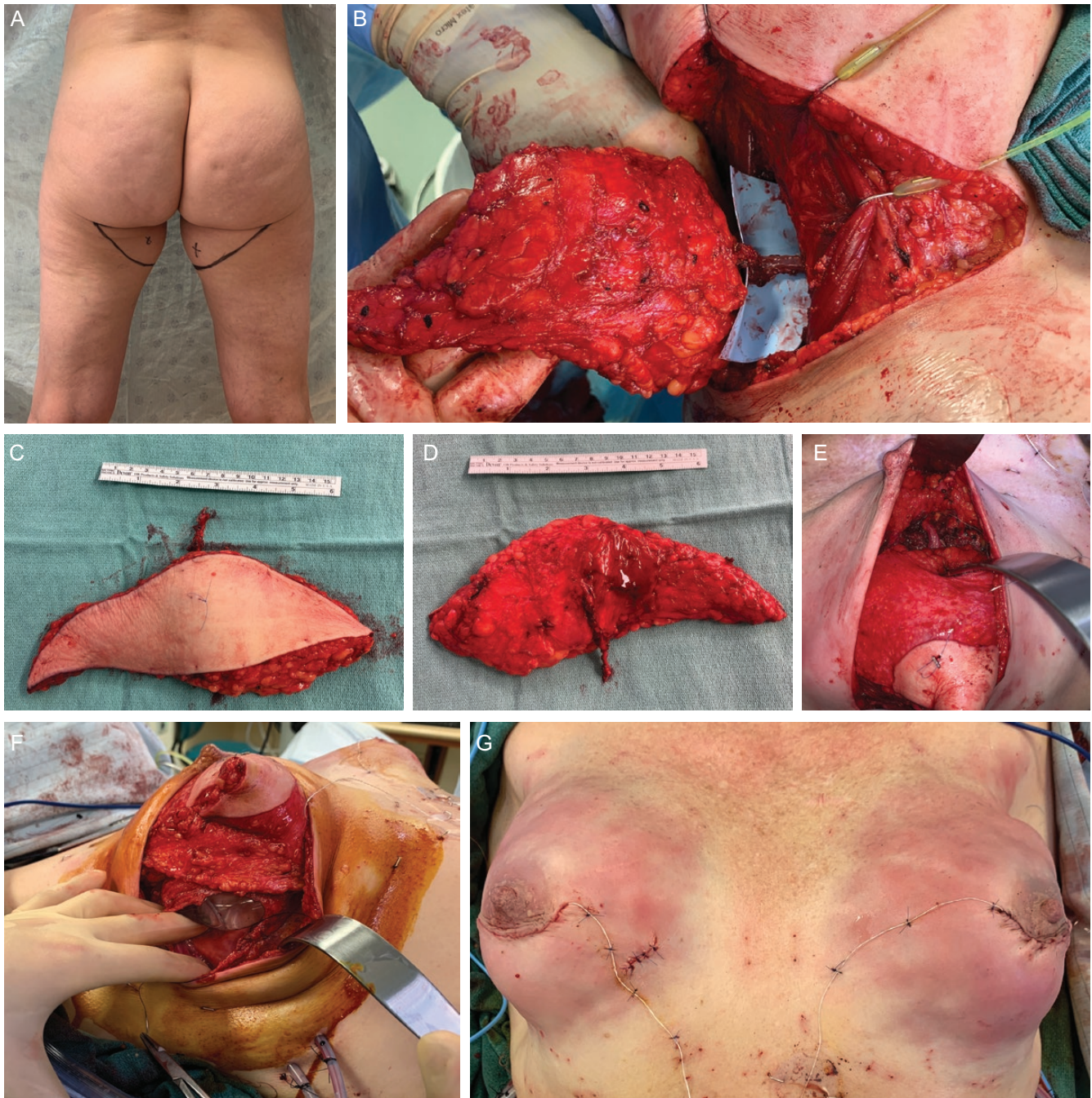To the best of our knowledge, immediate implant augmentation of PAP flaps following mastectomy has never been described. Considering the inherent size limitations of this otherwise versatile flap, its combination with implants in a hybrid technique would substantially enhance its application potential for breast reconstruction, especially in thin women desiring natural appearing reconstructions while maintaining volume.

## CASE REPORT

A 54-year-old healthy woman with BRCA2 mutation presented in January 2019 seeking risk-reducing mastectomies with nipple preservation (Figure 1). Surgical history included submuscular saline implant augmentation and traditional abdominoplasty. Body mass index was 23, while bra cup size was “C.” The implants were well-positioned without discernable capsular contracture. She lacked adequate autologous tissue volume in the thighs, buttocks, or lower back to support reconstruction to her desired size. The skin quality is thin and unsuitable for implant-only direct-to-implant reconstruction to the expected size. Geography limited her ability to undergo serial tissue expansion.

The patient underwent bilateral nipple-sparing mastectomies (NSM) via periareolar incisions with lateral radial extension. Specimen weights were 192 g on the right and 182 g on the left. The previous implants filled to 200 mL were removed with capsule preservation. Direct-to-implant reconstruction was not feasible based on examination of

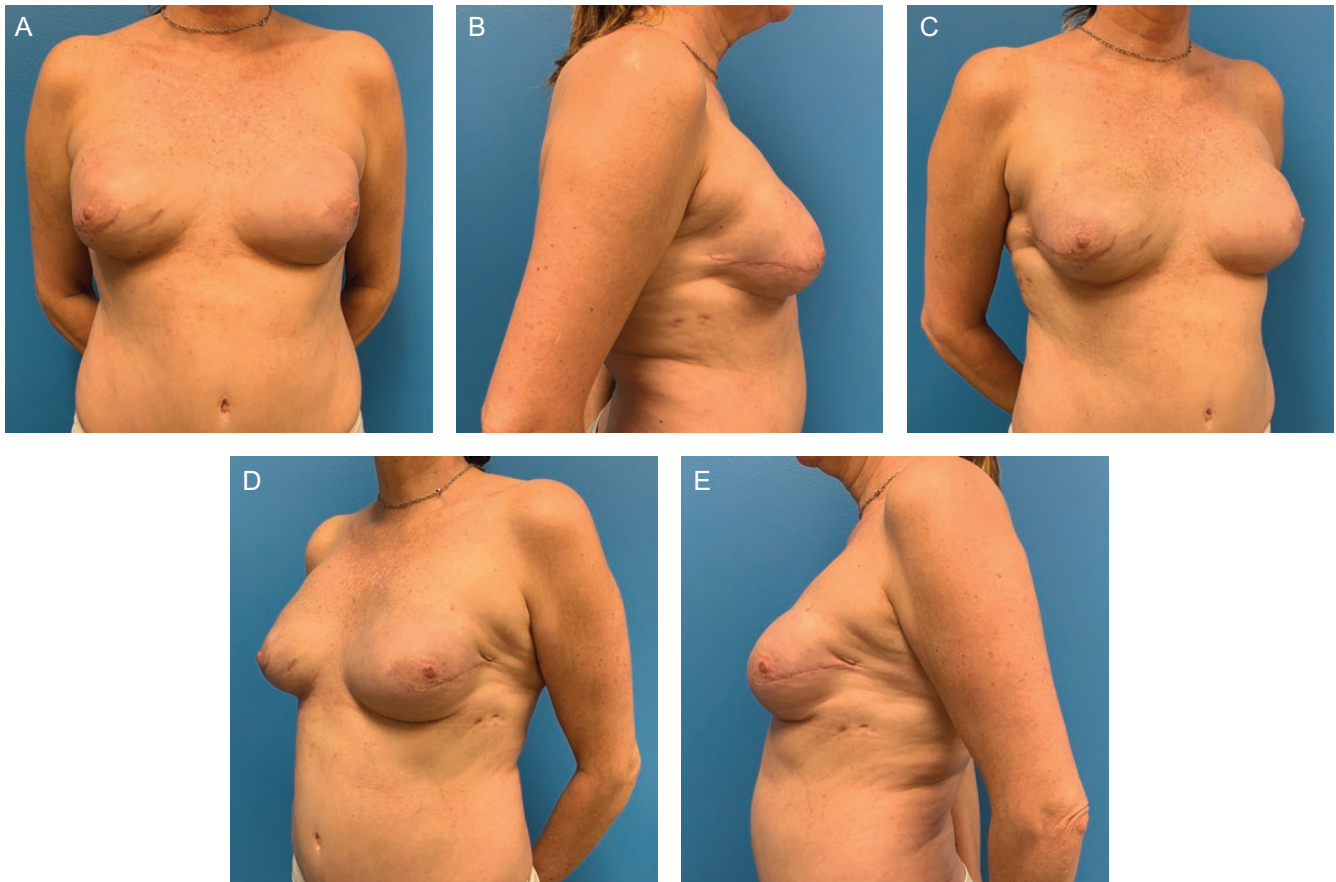



**Figure 2.** Intraoperative views. (A) Profunda artery perforator (PAP) flap markings. (B) Intramuscular dissection of perforators through the substance of adductor magnus. (C) Harvested PAP flap. (D) Harvested PAP flap with pedicle length of 7 cm. (E) Revascularized PAP flap with pedicle anastomosed to the internal mammary vessels. (F) New smooth round moderate classic profile gel implants (170 mL) were inserted into the capsule. The PAP flap was de-epithelialized, coned, and buried. (G) On-table appearance after completion of reconstruction with evolving breast skin and nipple ecchymosis. An area of full thickness thermal injury was excised and closely linearly on the right breast.

the mastectomy skin with indocyanine green laser angiography. Bilateral PAP flaps were harvested (Figure 2). The right and left breast flap weights were 225 and 167 g, respectively. Arterial anastomoses were performed with interrupted 9-0 nylon and veins were coupled with 2.5-mm

devices on both sides, anastomosed in end-to-end fashion to the antegrade internal mammary arteries and veins. Ischemia times were 36 and 45 min. Moderate classic profile 170-mL smooth round silicone implants were placed into the existing capsule pockets with lateral capsulorrhaphy for



**Figure 3.** (A–E) Postoperative appearance at 3-month follow-up.

pocket control. Total implant coverage was achieved after flap coning. The flaps were de-epithelialized and buried with implantable Doppler monitoring. Total operative time was 9 h and 24 min (Figure 2).

The patient was discharged on postoperative day 5 with viable free flaps. Initial mastectomy skin flap and nipple ischemia were treated with nitropaste with subsequent resolution. There were no infectious or other implant-related complications. The donor site healed uneventfully. A secondary revision was performed at 3 months postoperatively for fat grafting and correction of left lateral nipple malposition with transposition, concurrently with laparoscopic salpingo-oophorectomy. A total of 100 g were injected on the right and 52 g on the left.

Postoperative photos at 3 and 6 months are shown in Figures 3–5. At 8-month follow-up, the reconstruction is supple and the implants remain soft and well-positioned. The implants are nonvisible and nonpalpable, and there is no skin rippling.

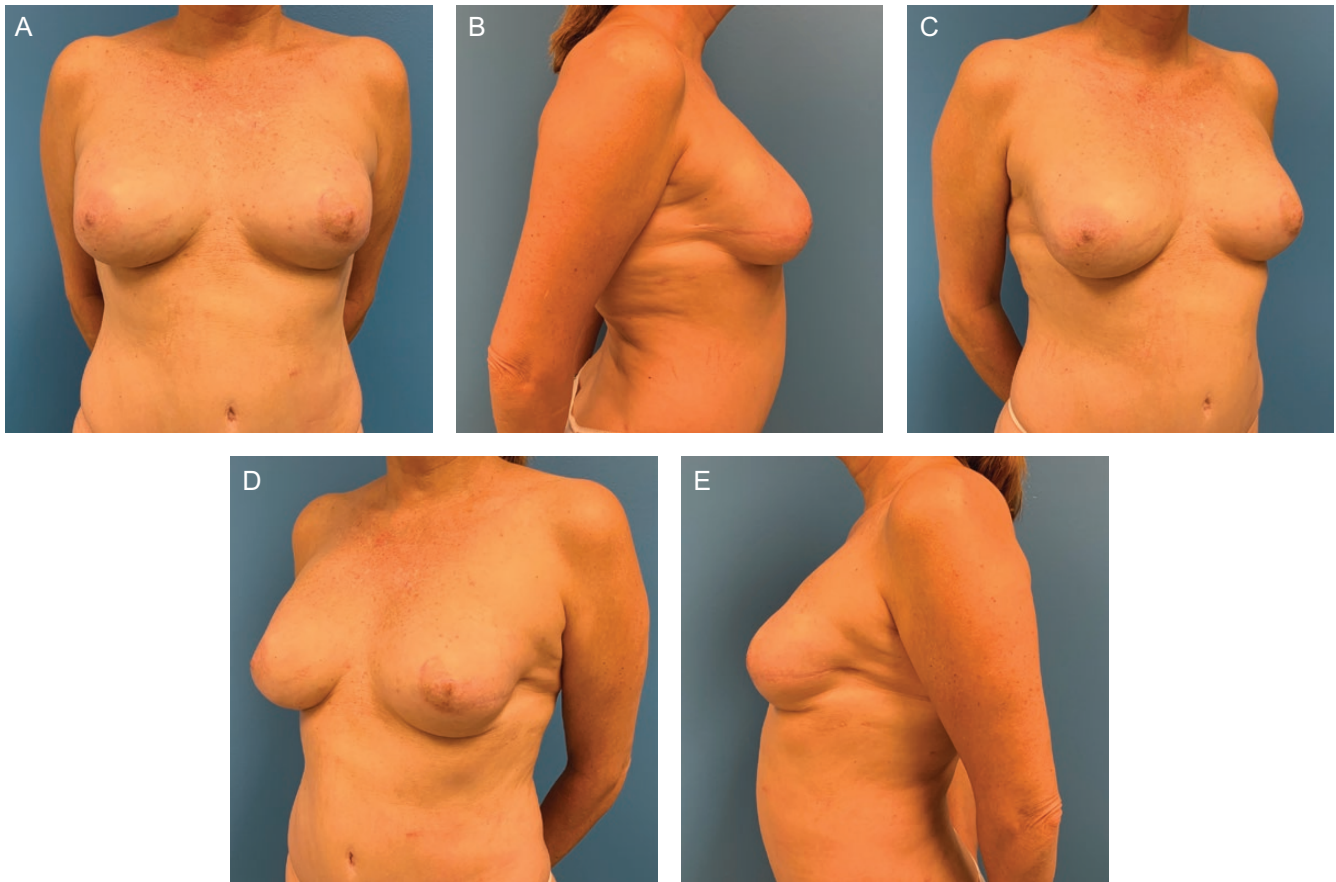
## DISCUSSION

The addition of implant augmentation to breast reconstruction with PAP flaps addresses several challenges

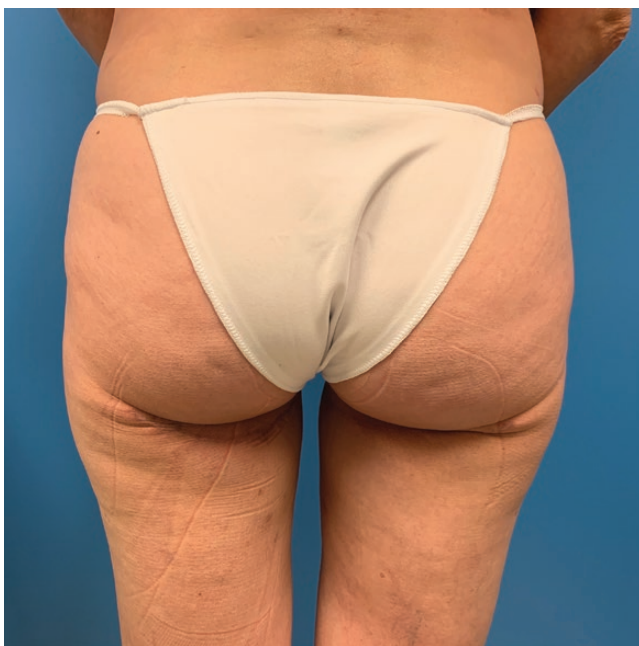related to breast reconstruction in thin women. Implant-only reconstruction in this population is prevalent, but rippling, implant visibility, and device palpability are common problems that arise.<sup>8</sup> Autologous fat grafting may help ameliorate these complaints to some extent. However, the paucity of tissue substrate to serve as a vascularized bed for fat graft take within the thin mastectomy flap limits the capacity for fat injection in these thin women in whom donor fat is already a scarce resource.<sup>4</sup> Device-based reconstruction, especially using the direct-to-implant approach, is limited in initial volume due to concerns of mastectomy skin ischemia and implant extrusion.<sup>9</sup> On the other hand, conventional autologous donor site volumes in thin patients are often inadequate to support reconstruction to the desired size. While stacked flaps are feasible, some women are intolerant of the added scar burden depending on the permutation of the flap combinations necessary.

Using a hybrid approach to breast reconstruction in these women allows for improved implant coverage, mitigating the concerns of rippling, visibility, and device exposure due to excessive size and inadequate overlying soft tissue envelope. Secondary intention healing of small areas of full thickness mastectomy skin flap necrosis may





**Figure 4.** (A–E) Postoperative appearance 8 months after initial surgery with secondary correction of left nipple lateral malposition and bilateral fat grafting.



**Figure 5.** Postoperative donor site appearance at 8-month follow-up.

be tolerated with a well-vascularized underlying tissue flap. The addition of the implant maintains the size flexibility of the reconstruction even in thin patients and provides the added benefit of projection, which can be problematic in autologous flaps. The most classic example of the hybrid autologous-implant concept for breast reconstruction is the latissimus flap that is often combined with implant or expanders.<sup>10</sup> The additional protection afforded by autologous tissue may also reduce implant-related complications in the setting of previous radiation.<sup>10</sup> With the technical refinement and increased predictability associated with modern microvascular surgery, the use of a free flap for the tissue component should be a natural and safe evolutionary step, as evidenced by recently published experience with immediately augmented deep inferior epigastric artery perforator flaps.<sup>6</sup> The combination of implants with the PAP flap, which is often the only available donor site in thin women, is especially palatable in patients with low body mass indices. The projection advantages of the implant combined with PAP flap coning create aesthetically complementary benefits.

Although implant augmentation of any autologous flap may be undertaken secondarily, there are advantages

to immediate device placement. In this patient with pre-existing, well-positioned implants, the periprosthetic capsule provided a unique opportunity for immediate implant placement with proper pocket control, without the need for mesh, bioprosthetic, or aggressive flap inset to maintain implant position. Capsule preservation also facilitated control of the implant position medially, thus avoiding interference with pedicle lie. Although the patient developed lateral nipple deviation, immediate hybrid reconstruction allowed for sufficient breast volume maintenance to limit the severity of nipple deviation that is often problematic after NSM in larger breasts. In the short-term postoperative period, the layer of vascularized tissue overlying the implant may facilitate recovery of nipple ischemia and subsequently allowed for safe secondary nipple transposition to address the correctable malposition, which was more severe on the left. The need for correction may have been avoided with suture anchoring of the deep surface of the nipple-areolar complex to the PAP flap, another advantage of implant coverage with vascularized tissue. Although this patient underwent a secondary procedure, the immediate hybrid approach, as in more conventional direct-to-implant reconstruction, obviates the need for serial tissue expansion and provides the possibility of an immediate single-stage breast reconstruction.

Limitations of this study include those inherent to case report study design. The short follow-up time of 8 months precludes assessment of long-term implant outcomes.

## CONCLUSION

PAP flap breast reconstruction with immediate implant augmentation is technically feasible. The present report is, to the best of our knowledge, the first description of this combination. Advantages include improved prosthetic coverage, which, in the short term, allows for immediate reconstruction to a larger size with reduced concern regarding mastectomy skin necrosis and threat to the device. In the long term, thicker soft tissue coverage avoids implant visibility and rippling and provides adequate vascularized environment to support additional fat grafting if desired. In NSM, the addition of vascularized tissue over the implant facilitates control of nipple position as well as secondary correction of malposition without risk to the device.

## Disclosures

The authors declared no potential conflicts of interest with respect to the research, authorship, and publication of this article.

## Funding

The authors received no financial support for the research, authorship, and publication of this article.

## REFERENCES

1. Allen RJ, Haddock NT, Ahn CY, Sadeghi A. Breast reconstruction with the profunda artery perforator flap. *Plast Reconstr Surg.* 2012;129(1):16e-23e.
2. Allen RJ, Jr., Lee ZH, Mayo JL, Levine J, Ahn C, Allen RJ Sr. The profunda artery perforator flap experience for breast reconstruction. *Plast Reconstr Surg.* 2016;138(5):968-75.
3. Haddock NT, Gassman A, Cho MJ, Teotia SS. 101 consecutive profunda artery perforator flaps in breast reconstruction: lessons learned with our early experience. *Plast Reconstr Surg.* 2017;140(2):229-39.
4. Weichman KE, Broer PN, Thanik VD, et al. Patient-reported satisfaction and quality of life following breast reconstruction in thin patients: a comparison between microsurgical and prosthetic implant recipients. *Plast Reconstr Surg.* 2015;136(2):213-20.
5. Roehl KR, Baumann DP, Chevray PM, Chang DW. Evaluation of outcomes in breast reconstructions combining lower abdominal free flaps and permanent implants. *Plast Reconstr Surg.* 2010;126(2):349-57.
6. Momeni A, Kanchwala S. Hybrid prepectoral breast reconstruction: a surgical approach that combines the benefits of autologous and implant-based reconstruction. *Plast Reconstr Surg.* 2018;142(5):1109-15.
7. Black CK, Graziano FD, Fan KL, Defazio MV, Nahabedian MY. Combining abdominal flaps and implants in the breast reconstruction patient: a systematic and retrospective review of complications and outcomes. *Plast Reconstr Surg.* 2019;143(3):495e-503e.
8. Maxwell GP, Gabriel A. Bioengineered breast: concept, technique, and preliminary results. *Plast Reconstr Surg.* 2016;137(2):415-21.
9. Gdalevitch P, Ho A, Genoway K, et al. Direct-to-implant single-stage immediate breast reconstruction with acellular dermal matrix: predictors of failure. *Plast Reconstr Surg.* 2014;133(6):738e-47e.
10. Chang DW, Barnea Y, Robb GL. Effects of an autologous flap combined with an implant for breast reconstruction: an evaluation of 1000 consecutive reconstructions of previously irradiated breasts. *Plast Reconstr Surg.* 2008;122(2):356-62.