


CLINICAL ARTICLE

Percutaneous Endoscopic Lumbar Discectomy *via* Transforaminal Approach Combined with Interlaminar Approach for L4/5 and L5/S1 Two-Level Disc Herniation

Zhi Zhou, MD^{1,2}, Hai-jian Ni, MD¹, Wei Zhao, MD³, Guang-fei Gu, MD¹, Jia Chen, MD¹, Yan-jie Zhu, MD^{1,2}, Chao-bo Feng, MD^{1,2}, Hao-yu Gong, MD¹, Yun-shan Fan, MD^{1,2}, Shi-sheng He, MD^{1,2} 

¹Orthopaedics Department, Shanghai Tenth People's Hospital and ²Spinal Pain Research Institute, Tongji University School of Medicine, Shanghai and ³Orthopaedics Department, Taian City Central Hospital, Shandong, China

Objective: The purpose of the present study was to discuss a new surgical strategy that combines percutaneous endoscopic transforaminal discectomy (PETD) with percutaneous endoscopic interlaminar discectomy (PEID) for L4/5 and L5/S1 two-level disc herniation.

Methods: This was a retrospective study. A total of 19 patients with L4/5 and L5/S1 two-level lumbar disc herniation (LDH) who underwent percutaneous endoscopic lumbar discectomy (PELD) in our hospital from January 2015 to June 2016 were retrospectively examined. The average age of these 19 patients was 42.21 ± 14.88 years old, including 12 men and 7 women. One experienced surgeon who had carried out more than 3000 lumbar surgeries performed PELD for these patients. During the PELD surgery, the transforaminal approach was adopted for L4/5 level disc herniation and the interlaminar approach was adopted for L5/S1 level disc herniation. The demographic data, operation time (min), fluoroscopy times, hospital stay (days), and complications were recorded and analyzed. The visual analogue scale (VAS), Oswestry disability index (ODI) scores, and the modified MacNab criteria were used to evaluate the surgical outcomes. MRI was conducted to evaluate the radiographic improvement.

Results: All patients underwent PELD *via* the transforaminal approach combined with the interlaminar approach successfully and achieved satisfactory efficacy. The follow-up points were 3, 12, and 18 months. The average hospital stay (days) and the average follow up (months) were 3.32 ± 0.98 and 18.63 ± 3.84 , respectively. The operation time and fluoroscopy times were 85.79 ± 12.90 min and 39.05 ± 4.59 times, respectively. The fluoroscopy times (frequency) for L4/5 and L5/S1 were 26.95 ± 6.41 and 12.11 ± 3.49 ($t = 7.00$, $P < 0.05$). Furthermore, there was no significant difference for fluoroscopy times between male and female patients ($t = 0.89$, $P = 0.99$). The preoperative back pain (VAS-Back) and the last follow-up VAS-Back were 5.58 ± 2.01 and 2.37 ± 1.01 , respectively ($t = 7.14$, $P < 0.05$). The preoperative leg pain (VAS-Leg) and the last follow-up VAS-Leg were 7.00 ± 1.56 and 1.63 ± 1.01 , respectively ($t = 20.97$, $P < 0.05$). There were significant differences between preoperative VAS-Back and the last follow-up VAS-Back in men ($t = 4.61$, $P < 0.05$) and women ($t = 6.57$, $P < 0.05$). In addition, there was significant differences between preoperative VAS-Leg and the last follow-up VAS-Leg in men ($t = 13.48$, $P < 0.05$) and women ($t = 26.87$, $P < 0.05$). There were significant differences between preoperative ODI scores ($44.84 \pm 10.82\%$) and the last follow-up ODI scores ($11.12 \pm 5.80\%$) ($t = 10.92$, $P < 0.05$). Preoperative ODI scores and the last follow-up ODI scores were significantly different for men ($t = 8.80$, $P < 0.05$) and women ($t = 6.63$, $P < 0.05$). All patients received significant pain relief and functional improvement after the surgery. Except for two cases of postoperative dysesthesia and one dural tear, no severe complications occurred. The dysesthesia symptoms of these two patients disappeared within 1 week with the application of dexamethasone and neurotrophic drugs and the dural tear case also recovered

Address for correspondence Shi-sheng He, Orthopaedics Department, Shanghai Tenth People's Hospital, Tongji University School of Medicine, Shanghai 200072, China. Tel: +86 17621148007; Fax: 66307270; Email: tjhss7418@tongji.edu.cn.

Disclosure: There were no any potential conflicts of interest among all authors.

Received 26 June 2020; accepted 18 October 2020

well as the dural laceration was small. No poor results were reported and 89.47% of patients achieved excellent or good recovery.

Conclusion: Percutaneous endoscopic lumbar discectomy via the transforaminal approach combined with the interlaminar approach under epidural anesthesia can treat L4/5 and L5/S1 two-level disc herniation safely and effectively.

Key words: Epidural anesthesia; Interlaminar approach; Percutaneous endoscopic lumbar discectomy; Transforaminal approach; Two-level disc herniation

Introduction

Symptomatic lumbar disc herniation (LDH) is one of the main reasons for low back pain and leg pain and presents a heavy economic and health burden to patients and society¹. Generally, spinal surgery is necessary when conservative treatment for LDH fails. The surgical treatments mainly include conventional open surgery, microsurgery, and endoscope-assisted surgery. Even with good results, for conventional open surgery and microsurgery, subsequent damage and complications can occur^{2, 3}.

Endoscopes have been used since the early 1980s to observe the intervertebral space after completing open surgery⁴. As a typical endoscope-assisted spinal surgery, percutaneous endoscopic lumbar discectomy (PELD) has development significantly over the past two decades. Yeung and Hoogland reported the Yeung endoscopic spine system (YESS) and the transforaminal endoscopic spine system (TESSYS) techniques, respectively. The two techniques are collectively referred to as percutaneous endoscopic transforaminal discectomy (PETD)^{5, 6}. As a crucial and challenged step in PETD, puncture is difficult to achieve in some L5/S1 level disc herniation cases, which leads to surgical failure⁷. In 2006, Ruetten introduced percutaneous endoscopic interlaminar discectomy (PEID)². PEID uses a posterior approach, passing through the lamina and ligamentum flavum, which can, consequently, cause dural laceration and other complications⁸. PELD mainly including PETD and PEID. PELD has become the most popular minimally invasive spine surgery (MISS) for LDH⁹. Many researches have confirmed that PELD has equivalent effectiveness to conventional surgery and has advantages such as smaller incision, lower blood loss, more rapid recovery, shorter hospital stay, less risk of iatrogenic instability, and less postoperative pain¹⁰. However, the inclusion criteria for patients for PELD is strict and limited at the primary application stage. The indication spectrum of PELD has been expanded extensively in recent 10 years due to the introduction of techniques such as foraminoplasty and corresponding instruments like high-speed endoscopic drills, flexible curved forceps, and endoscopic trephines⁸.

Today, multiple-level LDH is common due to changes in study and work habits. Normally, two-level disc herniation can be treated by conventional lumbar laminectomy¹¹. With the development of MISS and associated surgical instruments, two-level disc herniation can also be resected

through the transforaminal approach with just one portal skin incision¹². However, the puncture trajectory might not be the best for each level and so that massive bone resection is inevitable. Excessive resection of bone structures might decrease the integrity of the spinal structure and increase the risk of bleeding and iatrogenic lumbar instability¹³. For patients who have a high iliac crest, a hypertrophic transverse process, or a severely narrowed L5/S1 foramen, the transforaminal approach might not succeed in removing L4/5 and L5/S1 discs with just one portal skin incision because of the bony barriers in the puncture trajectory. For LDH with a narrowed foramen, foraminoplasty has been applied to resect the partial ventral bone of the superior articular process to enlarge the foramen; this approach was first introduced by Knight *et al.*¹⁴. Although foraminoplasty can achieve an extensive surgical view, it may also cause excess bone resection, neural injury, and postoperative complications like incomplete decompression¹⁵. To address this, percutaneous bichannel endoscopic surgery was first proposed by Kambin in 1987 to overcome the limited surgical view of PELD. Two skin incisions have been made for endoscopic and instrumental portals, respectively, but for single-level herniation^{16, 17}.

The theory of bichannel surgery inspired our study of the transforaminal approach combined with the interlaminar approach for two-level LDH. Wu *et al.* conducted a study to describe the two-level PELD technique in the transforaminal approach for single-level highly migrated disc herniation and to investigate its clinical outcomes, which verified the feasibility of two-level PETD¹⁸. Owens *et al.* carried out a study of 2262 cases to determine whether patients with LDH with substantial back pain improve with decompression alone. Approximately half of the patients (1159 cases) underwent two-level discectomy and achieved good pain relief¹⁹. Even though the puncture trajectory could be designed separately for the two levels, this would significantly extend the length of the operation and increase radiation exposure. In addition to the transforaminal approach, the interlaminar approach is another well-developed endoscopic technique for LDH surgery³. The interlaminar approach has advantages in the treatment of L5/S1 level disc herniation because it bypasses the blockade of the iliac crest and reduces the difficulty of puncture^{10, 20}. Because this technique involves approaching the herniated disc through the spinal canal, it increases the risk of dural laceration, epidural fibrosis, hematoma

formation, and scar tissue formation^{21, 22}. As for L4/5 and L5/S1 two-level herniation, it is difficult to resect two herniated discs through one single laminar interspace. Separate approaches to L4/5 and L5/S1 laminar spaces would increase the damage to the spinal canal and risks of related complications. PETD and PEID have specific indications and advantages for single-level LDH, respectively. Neither PETD nor PEID is a good option for two-level LDH. A combination of the transforaminal approach and the interlaminar approach to treat two-level LDH could make full use of their advantages, which could be a good strategy.

To our knowledge, there is no research exploring the feasibility of PETD combined with PEID for L4/5 and L5/S1 two-level disc herniation. The current study aimed to: (i) discuss the feasibility of PETD combined with PEID; (ii) explore the security and efficacy of the new surgical strategy; and (iii) introduce the early experience of PELD *via* the transforaminal approach combined with the interlaminar approach for L4/5 and L5/S1 two-level disc herniation.

Materials and Methods

Inclusion and Exclusion Criteria

This study was approved by the institutional review board of our hospital and informed consent was obtained from all individual participants included in the study.

The current study retrospectively analyzed 19 patients who underwent PELD in our department because of L4/5 and L5/S1 two-level disc herniation from January 2015 to June 2016. All patients enrolled met the following inclusion criteria: (i) low back pain and sciatica history, (ii) imaging findings confirming L4/5 and L5/S1 two-level disc herniation, and (iii) failure of standard conservative treatment for at least 3 months. The exclusion criteria were: (i) radiographic findings were not consistent with patients' symptoms or signs, (ii) more than two levels of disc herniation, (iii) far lateral L5/S1 disc herniation, (iv) lumbar instability, severe spinal canal stenosis, cauda equina syndrome, or other spinal diseases, and (v) other severe underlying diseases.

Surgical Procedure

The surgical diagrams of PETD combined with PEID for L4/5 and L5/S1 two-level disc herniation are shown in Fig. 1. PETD for L4/5 was first conducted followed by PEID for L5/S1.

Patient Preparation

All patients enrolled were confirmed as having L4/5 and L5/S1 two-level disc herniation by preoperative images (Fig. 2A–C) and were hospitalized for the surgery. They were treated by the same medical team. One experienced surgeon

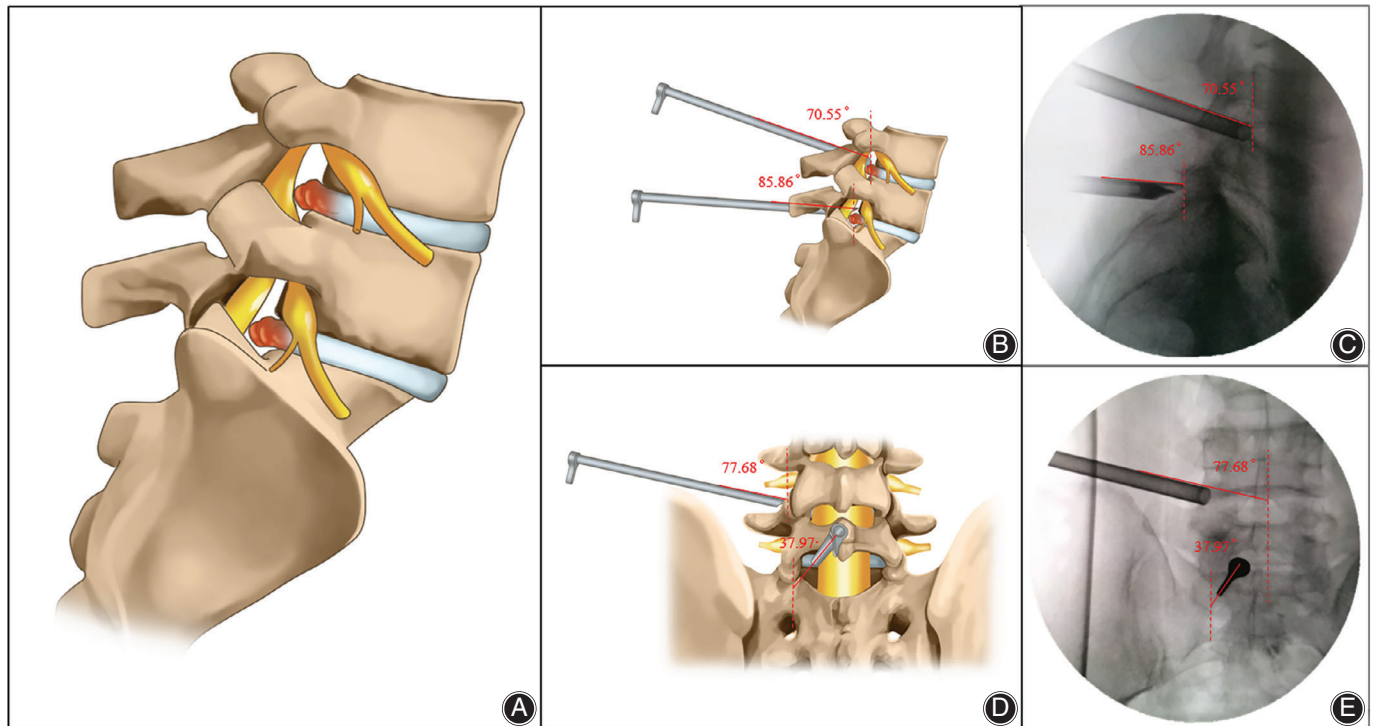


Fig 1 Diagrams of the new surgical strategy. (A) Lateral schematic of L4/5 and L5/S1 two-level disc herniation. (B, C) Lateral diagram and X-ray of percutaneous endoscopic transforaminal discectomy (PETD) for L4/5 level disc herniation combined with percutaneous endoscopic interlaminar discectomy (PEID) for L5/S1 level disc herniation. (D, E) Anteroposterior diagram and X-ray of PETD for L4/5 combined with PEID for L5/S1.

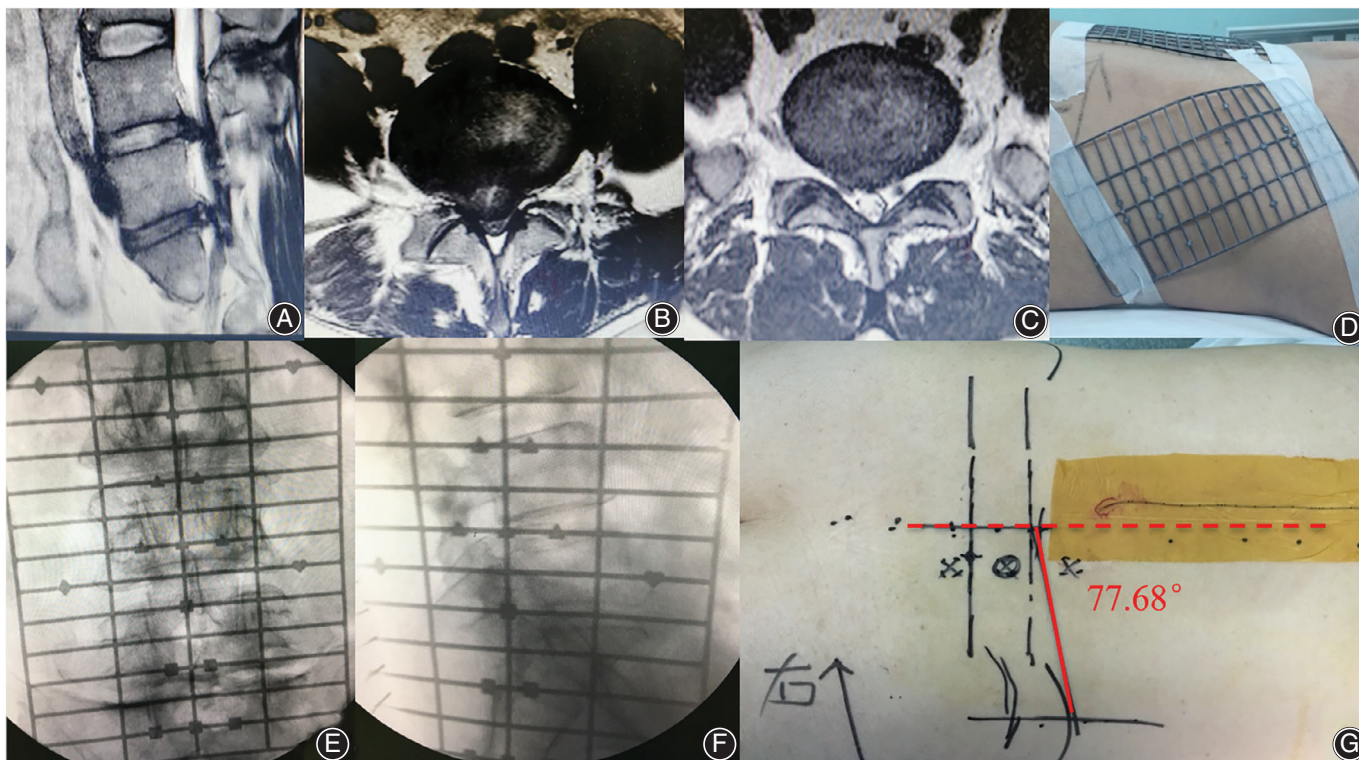


Fig 2 Surface location of percutaneous endoscopic lumbar discectomy (PELD) via the transforaminal approach combined with interlaminar approach for L4/5 and L5/S1 two-level disc herniation. (A–C) MRI of L4/5 and L5/S1 two-level disc herniation. (D) Patients were placed on a radiolucent operating table in a prone position under epidural anesthesia. Surface locators were attached to the posterior and the lateral side of lumbar region. (E, F) Anteroposterior and lateral X-ray view with surface locator. (G) The rough shape of anatomical structures like pedicles and the iliac crest were drawn on skin. Puncture targets and trajectories for both L4/5 and L5/S1 levels were marked on skin.

who had carried out more than 3000 lumbar surgeries performed PELD for these 19 patients. First, patients were placed on a radiolucent operating table in a prone position under epidural anesthesia. The anesthesia effect should be controlled carefully to preserve motor function and only block sensation during the surgery. The vital signs of patients were monitored during the operation. Then, a grid-like surface locator was used for the surface location (Fig. 2D). The rough shape of anatomical structures, like pedicles and the iliac crest, could be drawn on the skin with the help of intraoperative X-rays (Fig. 2E–G).

Percutaneous Endoscopic Transforaminal Discectomy for L4/5 Level

The transforaminal approach was routinely adopted for L4/5 level disc herniation. The puncture trajectory of this level was designed according to preoperative imaging findings and surface location. Then, a puncture needle was inserted into the target, the superior articular process of L5. A crucial procedure, satisfactory puncture is difficult to achieve and may require several attempts and fluoroscopy sometimes. After the confirmation of the ideal position of the puncture needle

by X-ray, skin incision and soft tissue dilation were performed. Keeping the guidewire in position, foraminoplasty was performed by bone drill to enlarge the intervertebral foramen. The working cannula was then introduced. Discography was routinely performed to identify the herniated disc. After the confirmation of the ideal position by X-ray, the endoscopic system was introduced through the working cannula. Disc forceps were used to remove the herniated disc (Fig. 3A), and bipolar probes were used to coagulate bleeding points. The decompression was considered sufficient when all the herniated mass had been removed (Fig. 3B), and pulsation of the dural sac was confirmed under endoscopic view.

Percutaneous Endoscopic Interlaminar Discectomy for L5/S1

For L5/S1, puncture could be a huge challenge using the transforaminal approach because of the bony obstacles. In this study, the interlaminar approach was routinely adopted for L5/S1 level disc herniation. According to preoperative imaging findings and surface location, a puncture needle was inserted into the lesion side of the L5/S1 lamina interspace.

The following procedures were skin incision and serial dilation. The working cannula was rotated along the dilator and ideal position was confirmed by X-ray (Figs 1C, E and 3C). For some cases with narrowed interlaminar space, the placement of the working cannula was difficult, and a perfect angle of puncture played an important role. The endoscopic system was then introduced through the working cannula. To expose the ligamentum flavum clearly under endoscopic view, soft tissues like muscle and fascia should be removed using grasping forceps, and bleeding points should be coagulated carefully using bipolar probes. The working cannula was rotated forward into the spinal canal, which was opened by partial resection of ligamentum flavum. Anatomy structures like nerve roots and the dural sac could be exposed by irrigation and removing epidural fat. After the identification of the herniated mass, the oblique opening of the working cannula could be used to tract nerve roots and the dural sac by rotation. Then, the extruded tissue should be removed completely with disc forceps. The decompression was considered sufficient when the mobility of the nerve root and the pulsation of the dural sac were confirmed under endoscopic view (Fig. 3D, E).

Closing the Skin Incision

After the satisfactory decompression achieved by PETD combined with PEID. One stitch was typically enough to

close each skin incision. All patients received MRI examination on the third day after surgery.

Outcome Measures

The demographic data, operation time, fluoroscopy times, hospital stay, and complications were recorded and analyzed. All patients were followed up in the outpatient department for at least 12 months after their operation. The 10-point visual analogue scale (VAS) was used to assess back pain (VAS-Back) and leg pain (VAS-Leg). VAS-Back and VAS-Leg were recorded on the day before surgery and at 1-day, 3-month, and last follow up after the surgery. Oswestry disability index (ODI) scores and modified MacNab criteria were adopted as functional evaluation methods. ODI scores and modified MacNab criteria were recorded on the day before surgery and at the last follow up after the surgery.

Demographic Data

The demographic data, including age and gender of the 19 patients, were recorded.

Operation Time

The operation time was from anesthesia to incision closure.

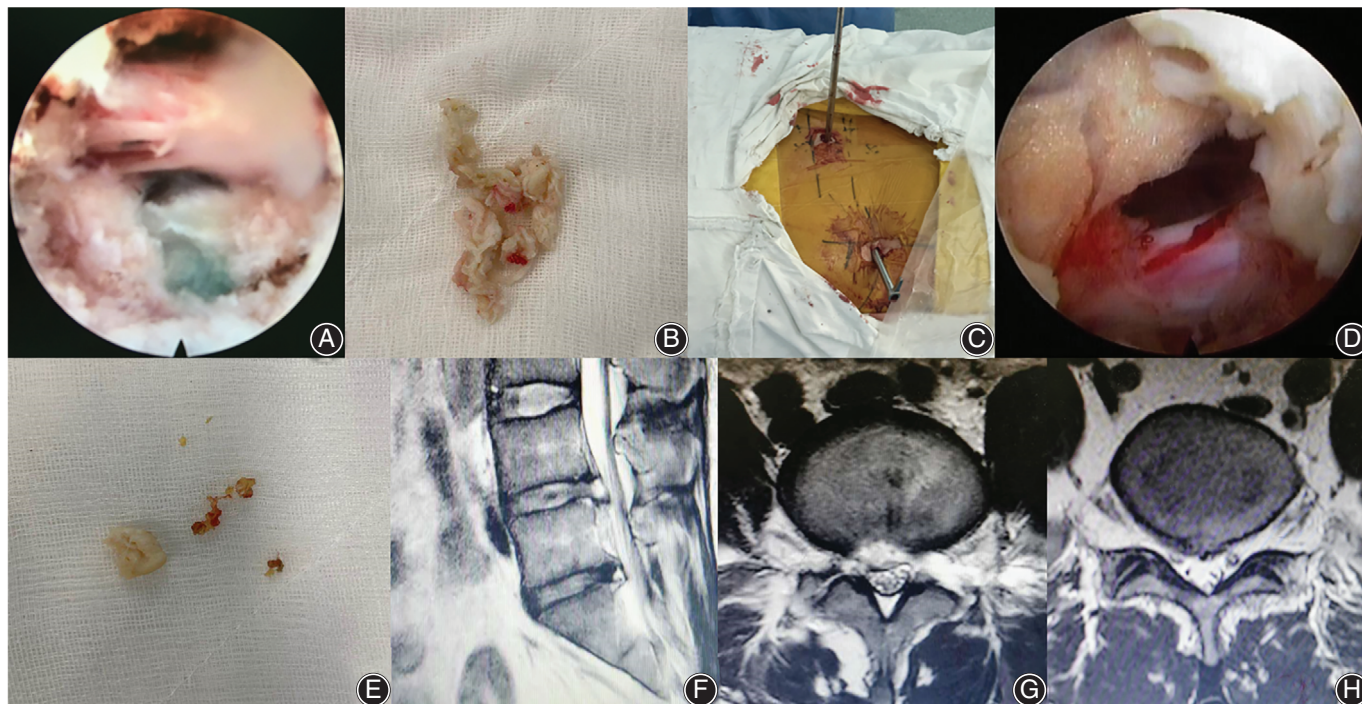


Fig 3 Endoscopic and general view of percutaneous endoscopic transforaminal discectomy (PETD) combined with percutaneous endoscopic interlaminar discectomy (PEID), and postoperative MRI. (A) Endoscopic view of L4/5 after decompression. (B) The removed herniated disc from L4/5. (C) The general view of transforaminal approach combined with interlaminar approach for L4/5 and L5/S1 two-level disc herniation. (D) Endoscopic view of L5/S1 after decompression. (E) The removed herniated disc from L5/S1. (F–H) Postoperative MRI (Day 3) revealed a satisfactory decompression.

Fluoroscopy Times

Fluoroscopy times (frequency) were recorded using a C-arm fluoroscopy machine to evaluate the radiation exposure.

Hospital Stay

Hospital stay was calculated from the first day in the hospital to the day of discharge.

Complications

Complications like postoperative bleeding, neural injury, dysesthesia, dural laceration, and scar tissue formation were recorded after the surgery.

Visual Analogue Scale

The VAS is the most commonly used questionnaire for quantification of pain. It is a continuous scale comprised of a horizontal or vertical line, usually 10 cm in length. For pain intensity, the scale is most commonly anchored by “no pain” (score of 0) and “pain as bad as it could be” (score of 10). A score of 0 is considered no pain, 1–3 mild pain, 4–6 moderate pain, and 7–10 severe pain.

Oswestry Disability Index

The ODI is a principal condition-specific outcome measure used in the management of spinal disorders and to assess patient progress in routine clinical practice. The ODI score system includes 10 sections: pain intensity, personal care,

TABLE 1 Demographic data and surgery-related data

Variables	Results
Gender (male : female)	12:7
Age (years old)	42.21 ± 14.88
Conservative time (months)	9.68 ± 8.54
Operation time (min)	85.79 ± 12.90
Fluoroscopy times (frequency)	39.05 ± 4.59
L4/5 level	26.95 ± 6.41
L5/S1 level	12.11 ± 3.49
Hospital stay (days)	3.32 ± 0.98
Follow up (months)	18.63 ± 3.84
Complications (cases)	
Postoperative dysesthesia	2
Dural tear	1

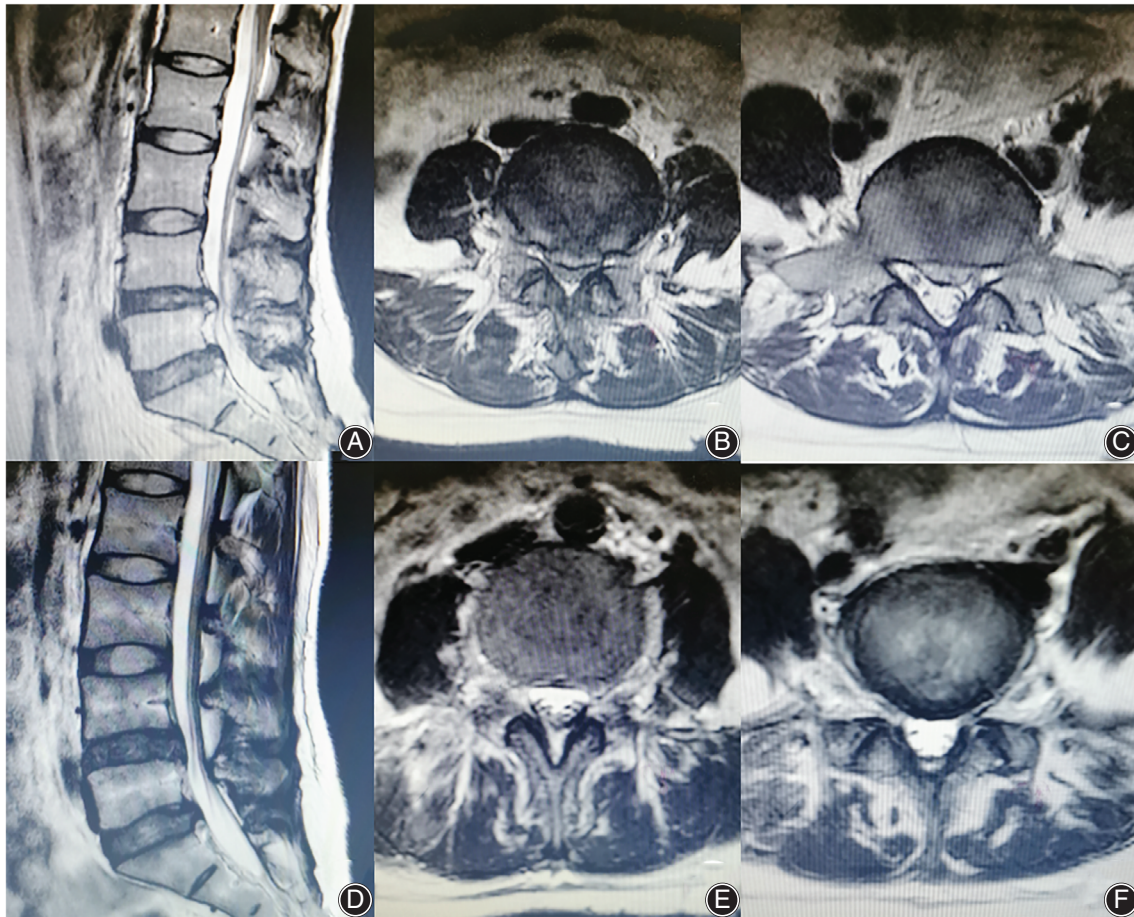


Fig 4 A 29-year-old female patient. (A–C) The preoperative MRI revealed L4/5 and L5/S1 two-level disc herniation. (D–F) Postoperative MRI (Day 3) showed that the compression was released.

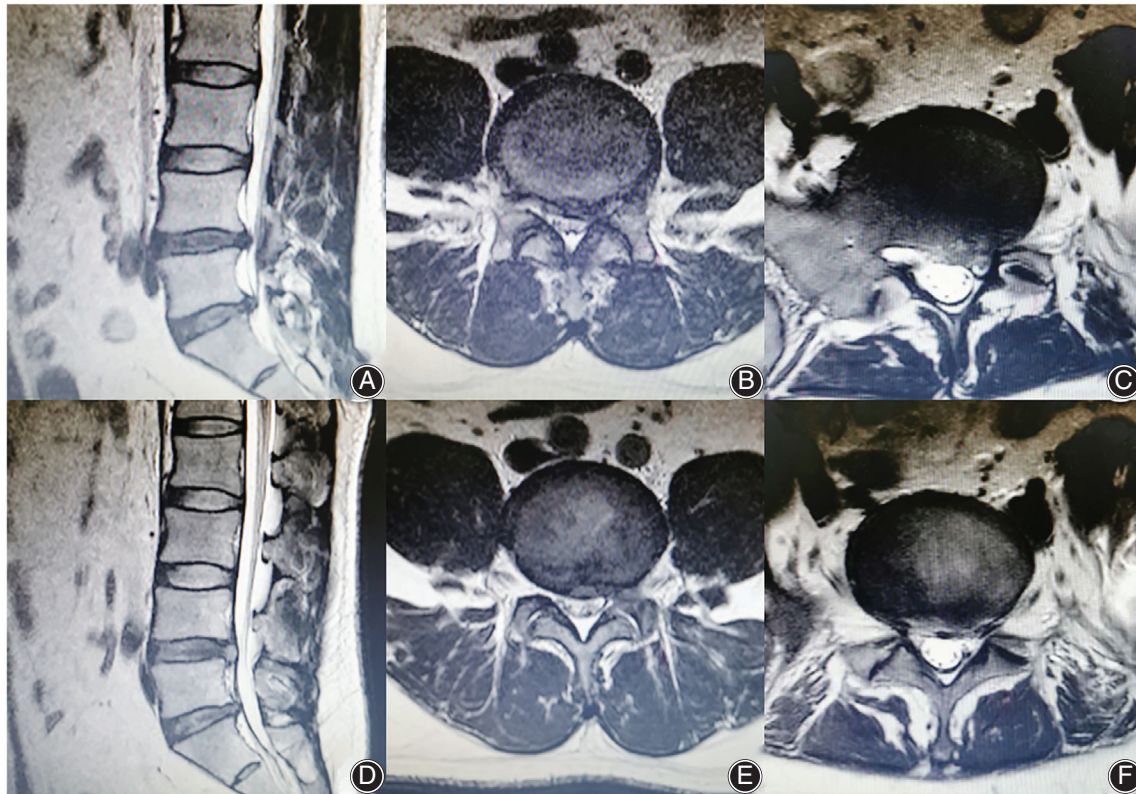

Fig 5 A 49-year-old male patient. (A–C) The preoperative MRI revealed L4/5 and L5/S1 two-level disc herniation. (D–F) Postoperative MRI (Day 3) showed that the compression was released.

TABLE 2 Pain relief and functional improvement

Variables	Preoperative	One day postoperative	Three months postoperative	Last follow-up
VAS-Back	5.58 ± 2.01	4.05 ± 1.08*	2.74 ± 1.05*	2.37 ± 1.01*
VAS-Leg	7.00 ± 1.56	3.58 ± 1.30*	2.11 ± 0.94*	1.63 ± 1.01*
ODI scores	44.84% ± 10.82%	—	—	11.12% ± 5.80%*

* Represents a statistical difference from preoperative data ($P < 0.05$); ODI, Oswestry disability index; visual analogue scale; VAS-Back, visual analogue scale score for back; VAS-Leg, visual analogue scale score for leg.

TABLE 3 Modified MacNab criteria results

Variables	Cases	Percentage
Excellent	4	21.05
Good	13	68.42
Fair	2	10.53
Poor	0	—

lifting, walking, sitting, standing, sleeping, sex life, social life, and traveling. For each section of six statements, the total score is 5. Intervening statements are scored according to rank. If more than one box is marked in each section, the highest score is taken. If all 10 sections are completed, the

score is calculated as follows: total scored out of total possible score $\times 100$. If one section is missed (or not applicable) the score is calculated as follows: (total score/(5 \times number of questions answered)) $\times 100\%$. A score from 0% to 20% is considered mild dysfunction, 21% to 40% moderate dysfunction, 41% to 60% severe dysfunction, and 61% to 80% is considered disability; patients with a score of 81% to 100% are either long-term bedridden or exaggerating the impact of pain on their life.

Modified MacNab Criteria

The modified MacNab criteria were used to evaluate the efficacy of surgery. The modified MacNab criteria include four

grades: excellent, good, fair, and poor. Excellent: symptoms disappear completely, with a return to original work and life; good: mild symptoms, with slightly limited activity, and no impact on work and life; fair: symptoms are relieved, activities are limited, affecting normal work and life; poor: there is no difference before and after treatment, with symptoms possibly aggravated.

Statistical Analysis

In this study, SPSS (version 21.0, IBM, Chicago, IL, USA) was used to perform all statistical analyses. Results were presented as mean \pm SD. *t*-tests were used to compare the continuous variables, such as operating time, fluoroscopy times, and VAS-Back, VAS-Leg, and ODI scores. $P < 0.05$ was regarded as statistically significant.

Results

Follow-up

In all 19 patients, PETD combined with PEID surgery was successfully completed. All patients were followed up (time points: 3, 12, and 18 months) for at least 12 months, with an average follow up of 18.63 ± 3.84 months.

General Results

This study reviewed 12 men and 7 women who underwent PELD for L4/5 and L5/S1 two-level disc herniation. The average age of these patients was 42.21 ± 14.88 years old (range, 18–67 years old). This combined approach took an average operation time of 85.79 ± 12.90 min and average fluoroscopy times of 39.05 ± 4.59 times. The fluoroscopy times during the interlaminar approach for L5/S1 level disc herniation were lower than for the transforaminal approach for L4/5 level disc herniation ($t = 7.00$, $P < 0.05$). The fluoroscopy times needed for the transforaminal approach was 26.95 ± 6.41 times, while the number needed for the interlaminar approach was 12.11 ± 3.49 times (Table 1). Furthermore, there was no significant difference for fluoroscopy times between women and men ($t = 0.89$, $P = 0.99$).

Radiographic Improvement

On the postoperative MRI (Day 3), no compression of the nerve was observed, and it was evident that the protruded disc tissue had been removed sufficiently. Sufficient space surrounding the nerve was observed through the postoperative MRI. Combined with the significant pain relief after the surgery, the postoperative MRI (Day 3) revealed satisfactory decompression (Fig. 3F–H). MRI improvement in another two cases is shown in Figs 4 and 5.

Visual Analogue Scale

All patients received significant pain relief after the surgery and the change in the VAS trend at every follow-up time point is presented in Table 2. The VAS-Back changed from 5.58 ± 2.01 before the operation to 4.05 ± 1.08 1 day after the surgery ($t = 3.62$, $P < 0.05$). At the last follow up, the

average VAS-Back score of these patients reduced from 5.58 ± 2.01 to 2.37 ± 1.01 ($t = 7.14$, $P < 0.05$). The VAS-Leg score changed from 7.00 ± 1.56 before the operation to 3.58 ± 1.30 1 day after the surgery ($t = 7.53$, $P < 0.05$). The average VAS-Leg score reduced from 7.00 ± 1.56 to 1.63 ± 1.01 ($t = 20.97$, $P < 0.05$). Furthermore, for men, the VAS-Back decreased from 5.17 ± 2.13 before the operation to 2.25 ± 1.14 at the last follow up ($t = 4.61$, $P < 0.05$) and the VAS-Leg decreased from 6.83 ± 1.85 to 1.50 ± 1.00 ($t = 13.48$, $P < 0.05$). For women, the VAS-Back decreased from 6.29 ± 1.70 before the operation to 2.57 ± 0.79 at the last follow up ($t = 6.57$, $P < 0.05$) and the VAS-Leg decreased from 7.29 ± 0.95 to 1.86 ± 1.07 ($t = 26.87$, $P < 0.05$).

Oswestry Disability Index

The functional improvement of the patients was satisfactory. All ODI data is shown in Table 2. At the last follow up, the average ODI scores improved from $44.84 \pm 10.82\%$ to $11.12 \pm 5.80\%$ ($t = 10.92$, $P < 0.05$). For male patients, the average ODI scores decreased from $48.50 \pm 10.59\%$ preoperatively to $18.00 \pm 6.50\%$ at the last follow up ($t = 8.80$, $P < 0.05$). For female patients, the average ODI scores decreased from $38.57 \pm 9.64\%$ preoperatively to $13.71 \pm 3.15\%$ at the last follow up ($t = 6.63$, $P < 0.05$).

Modified MacNab Criteria

No poor result was reported and 89.47% of patients achieved an excellent or good recovery (Table 3).

Complications

There were two cases of postoperative dysesthesia. The dysesthesia symptom of these two patients disappeared in 1 week with the application of dexamethasone and neurotrophic drugs. There was one case of dural tear at L5/S1 level. The dural laceration was too small to repair, and the patient recovered well. No recurrence was observed during the follow up (Table 1).

Discussion

Percutaneous Endoscopic Transforaminal Discectomy and Percutaneous Endoscopic Interlaminar Discectomy have Specific Advantages for Single-Level Lumbar Disc Herniation and Their Combination Could Treat Two-Level Lumbar Disc Herniation Well

Over the past two decades, PELD has progressed tremendously. The transforaminal approach is the most frequently used PELD technique because of its advantages such as local anesthesia, less damage to bone structure, and its minimally invasive approach to the spinal canal^{3, 23}. Two levels of adjacent herniated discs could be removed using the transforaminal approach with one portal skin incision¹². However, under certain conditions, like a high iliac crest, two separated transforaminal puncture trajectories are necessary to remove L4/5 and L5/S1 discs. A transforaminal puncture at L5/S1 level could be difficult and time-consuming for

patients with a high iliac crest and a hypertrophic transverse process^{24, 25}. In such cases, the interlaminar approach might be a good option as it bypasses the blockade of the iliac crest and the transverse process¹⁰. However, this technique invades into the spinal canal and retracts the nerve root and the dural sac. Compared with the transforaminal approach, there is increased risk of epidural fibrosis, nerve irritation, and other complications during the interlaminar approach^{21, 22}. The combination of the transforaminal approach and the interlaminar approach could make full use of their advantages.

Early Experience of Percutaneous Endoscopic Lumbar Discectomy via Transforaminal Approach Combined with Interlaminar Approach for L4/5 and L5/S1 Two-Level Disc Herniation

For the patients with L4/5 and L5/S1 two-level disc herniation enrolled in the present study, the transforaminal approach was adopted for the upper level disc. The puncture strategy, which was quite familiar for spinal surgeons who were good at minimally invasive spine surgery, could be easily designed and successfully performed^{26, 27}. As access to this level was less challenging, an ideal position of the puncture needle could be achieved with low-dose radiation exposure. The working cannula could be smoothly placed without massive osseous resection. In addition, operations under the endoscopic system were convenient as the working cannula could be introduced in an ideal direction for better exposure of the herniated level. For L5/S1 disc herniation, the interlaminar approach was chosen in this study. Because the puncture requirement in the interlaminar approach was relatively low, the puncture needle could be easily inserted with low-dose radiation exposure too. Because the working cannula was introduced into the lesion side of the laminar interspace directly, operating on the herniated mass under the endoscopic system was not difficult. In the current study, no severe complications occurred, and all patients received immediate pain relief after the surgery. The functional improvement was satisfactory. Indeed, 89.47% of patients had an excellent or good recovery at the last follow up. The surgical strategy introduced in the current study was safe and effective.

Comparison Between Percutaneous Endoscopic Lumbar Discectomy and Percutaneous Endoscopic Interlaminar Discectomy

Both the transforaminal approach and the interlaminar approach could treat LDH successfully²⁸. A randomized controlled study with 2 years of follow up proved that PELD *via* both the transforaminal approach and the interlaminar approach could achieve an equal treatment effect to the

microsurgical technique for LDH³. By reviewing LDH patients who received PELD more than 10 years previously, a retrospective study demonstrated that the long-term outcomes of PELD *via* both the transforaminal approach and the interlaminar approach were good too²⁹. Nevertheless, there are still differences between the two techniques. According to a randomized controlled study, the interlaminar approach showed advantages in operation time and fluoroscopy times over the transforaminal approach in PELD for L5/S1 disc herniation. The treatment efficiency between the two approaches was similar¹⁰. Another retrospective study demonstrated that the transforaminal approach would be better for shoulder type, centrally located, and recurrent disc herniation. The interlaminar approach might be a better choice for axillary type and migrated discs³⁰.

The anesthesia strategy was another issue to consider when choosing PELD with the transforaminal approach combined with the interlaminar approach. For the transforaminal approach, local anesthesia was normally recommended because it reduced the risk of exiting nerve root injury³¹. General anesthesia, which is normally adopted for the interlaminar approach^{10, 30}, has been applied in the transforaminal approach before³². However, it might not be a wise choice because of the increased risk of neural injury during the transforaminal approach. Even though local anesthesia could be applied in the interlaminar approach too³³, the anesthesia effect might not be satisfactory for a two-level surgery. Epidural anesthesia, which could be controlled to preserve motor function and only block sensation by adjusting the anesthetic dosage used³⁴, was chosen in this study. The anesthesia effect was good and no anesthesia-associated complications occurred.

Limitations

There are several limitations of this study. First, this is a retrospective study with a small sample size. Large-scale studies are necessary to further evaluate the surgical effect of this strategy. Second, there is no comparison with other surgical techniques. The current study introduced an effective and safe strategy for the treatment of L4/5 and L5/S1 two-level disc herniation, but further efforts should be devoted to finding an ideal treatment for L4/5 and L5/S1 two-level disc herniation.

Conclusion

Percutaneous endoscopic lumbar discectomy *via* the transforaminal approach combined with the interlaminar approach under epidural anesthesia can treat L4/5 and L5/S1 two-level disc herniation safely and effectively.

References

1. Deyo RA, Loeser JD, Bigos SJ. Herniated lumbar intervertebral disk. *Ann Intern Med*, 1990, 112: 598–603.
2. Ruetten S, Komp M, Godolias G. A new full-endoscopic technique for the interlaminar operation of lumbar disc herniations using 6-mm endoscopes:

prospective 2-year results of 331 patients. *Minim Invasive Neurosurg*, 2006, 49: 80–87.

3. Ruetten S, Komp M, Merk H, Godolias G. Full-endoscopic interlaminar and transforaminal lumbar discectomy versus conventional microsurgical technique: a

- prospective, randomized, controlled study. *Spine (Phila Pa 1976)*, 2008, 33: 931–939.
4. Forst R, Hausmann B. Nucleoscopy—a new examination technique. *Arch Orthop Trauma Surg*, 1983, 101: 219–221.
 5. Yeung AT, Tsou PM. Posterolateral endoscopic excision for lumbar disc herniation: surgical technique, outcome, and complications in 307 consecutive cases. *Spine (Phila Pa 1976)*, 2002, 27: 722–731.
 6. Hoogland T, Schubert M, Miklitz B, Ramirez A. Transforaminal posterolateral endoscopic discectomy with or without the combination of a low-dose chymopapain: a prospective randomized study in 280 consecutive cases. *Spine (Phila Pa 1976)*, 2006, 31: E890–E897.
 7. Choi KC, Lee JH, Kim JS, *et al*. Unsuccessful percutaneous endoscopic lumbar discectomy: a single-center experience of 10,228 cases. *Neurosurgery*, 2015, 76: 372–380.
 8. Pan M, Li Q, Li S, *et al*. Percutaneous endoscopic lumbar discectomy: indications and complications. *Pain Physician*, 2020, 23: 49–56.
 9. Gao X, Tang K, Xia Y, *et al*. Efficacy analysis of percutaneous endoscopic lumbar discectomy combined with PEEK rods for giant lumbar disc herniation: a randomized controlled study. *Pain Res Manag*, 2020, 2020: 3401605.
 10. Nie H, Zeng J, Song Y, *et al*. Percutaneous endoscopic lumbar discectomy for L5-S1 disc herniation via an interlaminar approach versus a transforaminal approach: a prospective randomized controlled study with 2-year follow up. *Spine (Phila Pa 1976)*, 2016, 41: B30–B37.
 11. Chung SB, Lee SH, Kim ES, Eoh W. Implementation and outcomes of a critical pathway for lumbar laminectomy or microdiscectomy. *J Korean Neurosurg Soc*, 2012, 51: 338–342.
 12. Kim HS, Ju CI, Kim SW, Kim JG, Lee SM, Kim BW. Minimally invasive percutaneous endoscopic 2 levels adjacent lumbar discectomy through 1 portal skin incision: preliminary study. *Asian J Neurosurg*, 2015, 10: 95–101.
 13. Sairoyo K, Chikawa T, Nagamachi A. State-of-the-art transforaminal percutaneous endoscopic lumbar surgery under local anesthesia: discectomy, foraminoplasty, and ventral facetectomy. *J Orthop Sci*, 2018, 23: 229–236.
 14. Knight MT, Vajda A, Jakab GV, Awan S. Endoscopic laser foraminoplasty on the lumbar spine—early experience. *Minim Invasive Neurosurg*, 1998, 41: 5–9.
 15. Kim HS, Ju CI, Kim SW, Kim JG. Endoscopic transforaminal suprapedicular approach in high grade inferior migrated lumbar disc herniation. *J Korean Neurosurg Soc*, 2009, 45: 67–73.
 16. Heo DH, Son SK, Eum JH, Park CK. Fully endoscopic lumbar interbody fusion using a percutaneous unilateral biportal endoscopic technique: technical note and preliminary clinical results. *Neurosurg Focus*, 2017, 43: E8.
 17. Kambin P, Brager MD. Percutaneous posterolateral discectomy—anatomy and mechanism. *Clin Orthop Relat Res*, 1987, 223: 145–154.
 18. Wu X, Fan G, Gu X, Guan X, He S. Surgical Outcome of Two-Level Transforaminal Percutaneous Endoscopic Lumbar Discectomy for Far-Migrated Disc Herniation. *BioMed Research International*. 2016, 2016: 1–6. <http://dx.doi.org/10.1155/2016/4924013>.
 19. Owens RK II, Carreon LY, Bisson EF, Bydon M, Potts EA, Glassman SD. Back pain improves significantly following discectomy for lumbar disc herniation. *Spine J*, 2018, 18: 1632–1636.
 20. Choi G, Lee SH, Raiturker PP, Lee S, Chae YS. Percutaneous endoscopic interlaminar discectomy for intracanalicular disc herniations at L5-S1 using a rigid working channel endoscope. *Neurosurgery*, 2006, 58: ONS59–ONS67.
 21. Kim CH, Chung CK. Endoscopic interlaminar lumbar discectomy with splitting of the ligament flavum under visual control. *J Spinal Disord Tech*, 2012, 25: 210–217.
 22. Choi G, Pophale CS, Patel B, Uniyal P. Endoscopic spine surgery. *J Korean Neurosurg Soc*, 2017, 60: 485–497.
 23. Nellensteijn J, Ostelo R, Bartels R, Peul W, van Royen B, van Tulder M. Transforaminal endoscopic surgery for lumbar stenosis: a systematic review. *Eur Spine J*, 2010, 19: 879–886.
 24. Fan G, Wang T, Hu S, Guan X, Gu X, He S. Isocentric navigation of percutaneous endoscopic transforaminal discectomy at the L5/S1 level in difficult puncture cases: a technical note. *Pain Physician*, 2017, 20: E531–E540.
 25. Choi KC, Park CK. Percutaneous endoscopic lumbar discectomy for L5-S1 disc herniation: consideration of the relation between the iliac crest and L5-S1 disc. *Pain Physician*, 2016, 19: E301–E308.
 26. Fan G, Wang C, Gu X, Zhang H, He S. Trajectory planning and guided punctures with isocentric navigation in posterolateral endoscopic lumbar discectomy. *World Neurosurg*, 2017, 103: 899–905.
 27. Fan G, Gu X, Liu Y, *et al*. Lower learning difficulty and fluoroscopy reduction of transforaminal percutaneous endoscopic lumbar discectomy with an accurate preoperative location method. *Pain Physician*, 2016, 19: E1123–E1134.
 28. Dowling A, Lewandrowski KU, da Silva FHP, Parra JAA, Portillo DM, Gimenez YCP. Patient selection protocols for endoscopic transforaminal, interlaminar, and translaminar decompression of lumbar spinal stenosis. *J Spine Surg*, 2020, 6: S120–S132.
 29. Eun SS, Lee SH, Sabal LA. Long-term follow-up results of percutaneous endoscopic lumbar discectomy. *Pain Physician*, 2016, 19: E1161–E1166.
 30. Choi KC, Kim JS, Ryu KS, Kang BU, Ahn Y, Lee SH. Percutaneous endoscopic lumbar discectomy for L5-S1 disc herniation: transforaminal versus interlaminar approach. *Pain Physician*, 2013, 16: 547–556.
 31. Hoogland T, van den Brekel-Dijkstra K, Schubert M, Miklitz B. Endoscopic transforaminal discectomy for recurrent lumbar disc herniation: a prospective, cohort evaluation of 262 consecutive cases. *Spine (Phila Pa 1976)*, 2008, 33: 973–978.
 32. Ruetten S, Komp M, Merk H, Godolias G. Recurrent lumbar disc herniation after conventional discectomy: a prospective, randomized study comparing full-endoscopic interlaminar and transforaminal versus microsurgical revision. *J Spinal Disord Tech*, 2009, 22: 122–129.
 33. Du J, Tang X, Jing X, Li N, Wang Y, Zhang X. Outcomes of percutaneous endoscopic lumbar discectomy via a translaminar approach, especially for soft, highly down-migrated lumbar disc herniation. *Int Orthop*, 2016, 40: 1247–1252.
 34. Fang G, Ding Z, Song Z. Comparison of the effects of epidural anesthesia and local anesthesia in lumbar transforaminal endoscopic surgery. *Pain Physician*, 2016, 19: E1001–E1004.