

Viral involvement in the pathogenesis and clinical features of ophthalmic pterygium (Review)

AIKATERINI K. CHALKIA¹, DEMETRIOS A. SPANDIDOS² and EFSTATHIOS T. DETORAKIS¹

Departments of ¹Ophthalmology and ²Virology, University Hospital of Heraklion, 71110 Heraklion, Crete, Greece

Received June 17, 2013; Accepted July 12, 2013

DOI: 10.3892/ijmm.2013.1438

Abstract. Pterygium is a potentially vision-threatening fibro-vascular lesion originating from the conjunctiva that often extends on the corneal surface. Although it has been extensively studied, its pathogenesis has yet to be fully elucidated. Recent evidence on molecular genetic abnormalities in pterygium suggested neoplastic changes of limbal stem cells potentially associated with exposure to ultraviolet (UV) light. Human papillomavirus (HPV) is an oncogenic virus, associated with squamo-proliferative lesions of the anogenital region, skin and oropharynx. Several studies have shown HPV involvement in the pathogenesis of conjunctival neoplastic lesions, including papilloma and squamous cell carcinoma. The involvement of HPV as a co-factor in the pathogenesis of pterygium, although suggested by several studies using PCR and immunohistochemical techniques, remains controversial. Moreover, a marked variation in the prevalence of HPV in ophthalmic pterygium has been reported by different studies. Ethnic susceptibility and methodological differences in the detection of HPV may account for this variation. Surgical excision, often using sophisticated techniques, is the standard current method of therapy for pterygium. However, recurrences are frequent and recurrent lesions tend to be more aggressive. If indeed HPV is involved in pterygium pathogenesis or recurrence, anti-viral medications or vaccination may be new options in pterygium therapy.

Contents

1. Introduction
2. Theories of infectious pathogenetic co-factors in pterygium
3. Virus detection in pterygium
4. Current status on HPV detection in pterygium
5. HPV detection in ocular surface lesions
6. Methodologies for HPV detection in pterygium

Correspondence to: Dr Efstathios T. Detorakis, Department of Ophthalmology, University Hospital of Heraklion, 71110 Heraklion, Crete, Greece

E-mail: detorakis@hotmail.com

Key words: pterygium, cornea, HPV, virus, pathogenesis

7. Potential therapeutic interventions in HPV-infected pterygium
8. Conclusion

1. Introduction

Pterygium is a wing-shaped fibrovascular lesion of the ocular surface of unknown origin and pathogenesis. It grows at the inter-palpebral conjunctival area, more often nasally, and invades adjacent corneal epithelium (Fig. 1). Pterygium growth can cause irregular astigmatism, corneal scarring, restriction of ocular motility, or chronic ocular surface inflammation (1). Treatment thus far is exclusively surgical, however, pterygium often tends to recur aggressively. This has led to the use of sophisticated surgical techniques in an effort to reduce recurrence rates (Fig. 2) (2).

Although pterygium pathogenesis remains an enigma, epidemiologic studies suggest that it is a sun-related eye disease (ophthalmoheliosis). In fact, the prevalence of pterygium seems to be associated with geographical latitude, with higher prevalences in areas located within 40° above and below the equator, suggesting that prolonged exposure to ultraviolet (UV) radiation may promote its development. In addition, repeated micro-trauma, mediated by exposure to dust, chronic conjunctival inflammation, genetic predisposition and ocular dryness have all been reported to be involved in pterygium, indicating a multifactorial pathogenesis (1,3). Evidence suggests that genetically altered limbal epithelial stem cells may play a critical role through a process of Bowman's layer dissolution, matrix remodeling, cell proliferation and angiogenesis, possibly with the involvement of cytokines, matrix metalloproteinases and growth factors (4-10). Notably, among the various theories proposed for pterygium pathogenesis thus far, the possibility of an infectious (probably viral) mechanism in at least a subgroup of pterygia has also recently gained ground. This possibility is important because, should it prove valid, it could justify non-invasive or minimally invasive treatment options through anti-viral medications.

2. Theories of infectious pathogenetic co-factors in pterygium

Pterygium has been previously considered a degenerative condition. This hypothesis, however, has been challenged in

recent years by the detection of important molecular genetic alterations in pterygium, including loss of heterozygosity (LOH) of microsatellite DNA or the overexpression of mutated versions of p53 with compromised function, which could promote tumor growth (11-14). Accordingly, a multi-step pathogenetic process, with the participation of genetic inheritance, UV radiation and, importantly, oncogenic viral infection has been proposed for the pathogenesis of pterygium (Fig. 3). According to this 'two-hit' hypothesis, inherited genetic alterations or exposure to environmental factors such as UVR could predispose individuals to this benign neoplastic disease ('first hit'). Oncogenic viruses, or additional UVR exposure, adding further damage to an already susceptible genetic material, may be the stimulus for the outset of development or recurrence of pterygium ('second hit') (15). This theoretical model has been recently supported by the detection of HPV strains considered high-risk for cancer development, including 16 and 18, encoding E6 and E7 proteins which interfere with p53 function (16,17).

3. Virus detection in pterygium

Many studies have been conducted to investigate the involvement of a variety of oncogenic viruses, including HPV, CMV, HSV or EBV, in the development and recurrence of pterygium (Table I). HPV presence in pterygium has been reported by several studies, with prevalence ranging from very low to almost 100% of cases (16,18-27). The prevalence of various herpes-viruses in pterygium also differs considerably among reports. Studies from Greece detected HSV in 22-45% and CMV in 40% of examined pterygia (18,28). On the other hand, in a study conducted in Taiwan Chen *et al* investigated the role of HSV in pterygium, where a prevalence of only 5% was reported (29). Another study from Turkey detected EBV-DNA in 10% of the pterygia examined (25). Such a disparity in the prevalence of oncogenic virus detection in pterygium may partly be explained by ethnic or geographical factors or by laboratory techniques. However, it may also reflect the heterogeneous nature of pterygium pathogenesis and the possibility that oncogenic viruses affect only a sub-group of ophthalmic pterygia.

4. Current status on HPV detection in pterygium

Taking into account that HPV is by far the most commonly reported oncogenic virus associated with ophthalmic pterygium, several studies have focused on HPV detection and typing to assess the potential role HPV plays in the pathogenetic process leading to pterygium development. Of note, certain studies (such as those of Sjö *et al* from Denmark, Takamura *et al* from Japan or Hsiao *et al* from Taiwan) have failed to detect HPV or report very low prevalences of HPV in examined pterygia (21-23,25,27). Moreover, Dushku *et al* detected p53 overexpression in the limbal epithelium of the pterygia studied with all the samples being negative for HPV DNA, suggesting that factors other than HPV infection were responsible for the p53 overexpression (12). To investigate the role of HPV and the variance in its prevalence in pterygium in the different studies, Piras *et al* (20) selected patients from two distant geographically populations, Italy and Ecuador. HPV

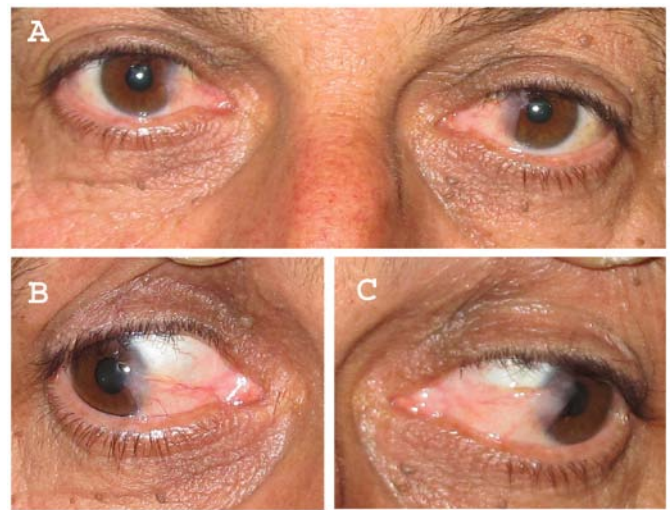


Figure 1. (A) Nasal bilateral pterygium. (B and C) The extent of advancement of the lesions on the corneal surface of the right and left eye is shown on abduction.

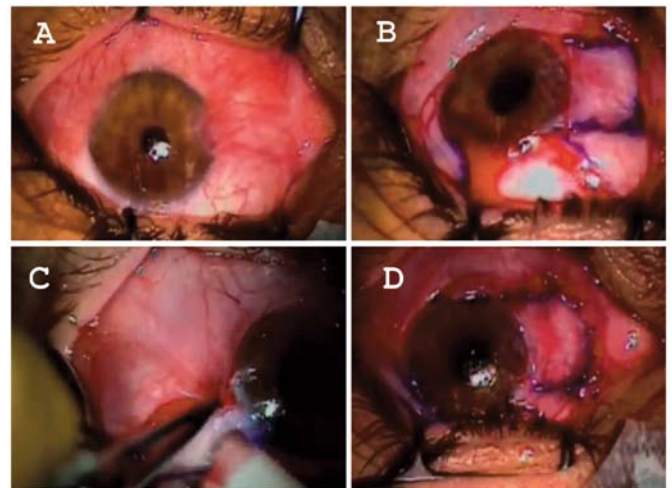


Figure 2. (A) Intraoperative views of nasal and temporal pterygium excision. (B) The nasal pterygium is excised and the defect covered with a conjunctival autograft harvested from the superior bulbar conjunctival area. (C) The temporal pterygium is excised and the defect covered with a locally raised conjunctival flap. (D) Final view at the conclusion of the procedure.

was detected in all the pterygia of Italian patients, but in only 21% of the pterygia from Ecuador. In that study, geographic and ethnic factors were proposed as a possible explanation for differences in HPV prevalence in pterygium, supporting its multi-factorial pathogenesis (20).

5. HPV detection in ocular surface lesions

Over the past three decades HPV DNA has been detected in various ophthalmic lesions of the ocular surface and even in phenotypically normal conjunctiva (30,31). HPV infection has been strongly correlated with the pathogenesis and recurrence of conjunctival papillomas, conjunctival intraepithelial neoplasia (CIN) and even squamous cell carcinoma of the conjunctiva (SCCC) (32-36). HPV may also co-exist in SCCC lesions with other oncogenic viruses, such as HIV, thus it is

Table I. Prevalence of pterygium-associated viruses in various studies.

Authors/(Refs.)	Date of publication	HPV prevalence	HSV prevalence	CMV prevalence	EBV prevalence	Country of the study	Method of detection
Spandidos, <i>et al</i> (28)	1994	-	45%	40%	0%	Greece	PCR
Detorakis, <i>et al</i> (18)	2001	24% (Type 18)	22%	-	-	Greece	PCR
Gallagher, <i>et al</i> (19)	2001	50% (Types 6,11,16)	-	-	-	UK	PCR
Piras, <i>et al</i> (20)	2003	100% 21% (Types 52, 54, <i>cand</i> HPV90, unknown)	-	-	-	Italy Ecuador	PCR- sequencing
Schellini, <i>et al</i> (21)	2006	0%	-	-	-	Brazil	PCR
Sjö, <i>et al</i> (34)	2007	4.4% ^a (Type 6)	-	-	-	Denmark	PCR-ISH
Chen, <i>et al</i> (29)	2008	-	5% ^a	-	-	Taiwan	PCR-ISH
Takamura, <i>et al</i> (23)	2008	4.8% ^b	-	-	-	Japan	PCR-HC II
Rodrigues, <i>et al</i> (24)	2008	58.3% (Types 1, 2, 16)	-	-	-	Brazil	PCR
Otlu, <i>et al</i> (25)	2009	0%	-	-	10%	Turkey	Real-time PCR
Tsai, <i>et al</i> (16)	2009	24% (Types 16, 18)	-	-	-	Taiwan Poland	Nested-PCR PCR
Pieczk-Sidor, <i>et al</i> (26)	2009	27.6% (Types 5, 6, 11, 16, 18, 31, 52, 59)	-	-	-		
Hsiao, <i>et al</i> (27)	2010	3% (Type 18)	-	-	-	Taiwan	PCR-ISH

^aVirus-DNA negative with ISH; ^bHPV-DNA negative with Hybrid Capture II.

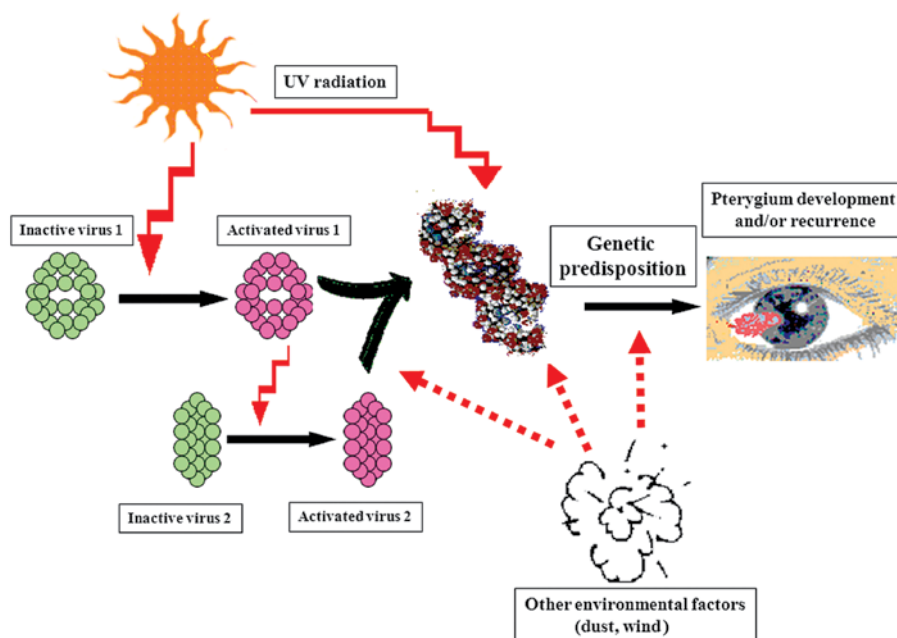


Figure 3. A proposed multi-step model for pterygium pathogenesis, in which genetic predisposition, viral involvement and environmental factors co-participate (adapted from ref. 15).

difficult to determine the importance of HPV per se in the development of these lesions (36). The fact that pterygium has also often been reported to co-exist with ocular surface neoplastic lesions (37,38), supports the hypothesis of oncogenic viral infection or co-operation as a pathogenetic model. Obtaining cells from the ocular surface via non-invasive methodologies, including exfoliation cytology techniques (39), may enable the detection of HPV-infected pterygia.

6. Methodologies for HPV detection in pterygium

HPVs are non-enveloped viruses with icosahedral symmetry, composed of a circular double-stranded DNA genome. HPVs cause infections of the skin and the mucous membranes of the anogenital region and the oropharynx. Over 100 types have been fully sequenced and some seem to play an important role in the development of tumors. According to their oncogenic potential, HPVs are divided into low- and high-risk types (oncogenic/high-risk types: 16, 18, 31, 33, 35, 39, 45, 51, 52, 56, 58, 59, 68, 73, 82 and potentially oncogenic types: 26, 53, 66) (17,40,41).

Diagnosis of the viral infection is based on the detection of the HPV-DNA. However, the mode of sample collection, the quantity of the HPV-DNA of the isolated sample and the use of various HPV-DNA detection techniques with different sensitivity and specificity, are factors that may significantly affect the detection rates of HPV infections (40).

HPV-DNA can be directly isolated from a biopsy specimen with *in situ* hybridization (ISH), Southern blotting and dot blot hybridization. However, these techniques are laborious, need a large quantity of purified DNA and their sensitivity is limited (40).

In cases where the biopsy specimen is small with a limited quantity of HPV-DNA, nucleic acid amplification assays can be used to increase the sensitivity and specificity of the test. Hybrid Capture II (HC-II) is a non-radioactive signal amplification technique, accurate for mucosal lesions, that distinguishes high-risk from low-risk HPV-types, but is not appropriate for genotyping (40-42).

Due to its high sensitivity, polymerase chain reaction (PCR) is frequently associated with a high rate of false-positive results (43). Southern blot, dot blot, reverse dot blot, digestion with restriction endonucleases or direct sequence analysis performed after DNA amplification can help increase the sensitivity and specificity of the test (41,42). Real-time PCR or quantitative PCR (qPCR) permits rapid detection and quantification of the viral load during the various cycles of the PCR process (real-time) (43). Reverse transcriptase-PCR (RT-PCR) is a qualitative assay that permits the identification of viral gene expression with the use of reverse transcriptase. The combination of the two techniques, quantitative RT-PCR or real-time RT-PCR (qRT-PCR), is considered to be the first choice assay for the detection of viral gene expression as it combines quantitative and qualitative advantages of the two methods (44,45).

7. Potential therapeutic interventions in HPV-infected pterygium

Current treatment of pterygium includes surgical excision and occasionally adjunctive therapy. Several surgical techniques have been described: bare sclera closure, sliding conjunc-

tival flaps, use of autologous conjunctival and limbal grafts or amniotic membranes (2,46) (Fig. 2). Due to the possible complications and costs of surgical treatment and the risk of recurrence, often aggressive, various adjunctive therapies have been proposed, including β -irradiation and the use of mitomycin C or 5-fluorouracil. However these methods have been associated with corneoscleral necrosis and melting, limbal stem cell deficiency and variable recurrence rates. B-irradiation has also been associated with cataract formation (2,46).

Interferons are a family of proteins with antiviral, antiproliferative, antiangiogenic and immunomodulatory properties, produced from the organism in response to various stimuli (47). The recombinant form α -2b (IFN- α -2b) has been used for the treatment of condylomata acuminata, chronic hepatitis B and C, Kaposi sarcoma, malignant melanoma, hairy cell leukemia and follicular lymphoma (47). Unlike mitomycin C and 5-fluorouracil, adverse effects associated with the topical or sub-conjunctival administration of IFN- α -2b are less severe (48-52). IFN- α -2b in the form of eye drops has successfully been used thus far in the management of CIN and conjunctival papilloma (48-51). IFN- α -2b has also been reported to prevent the recurrence of pterygium (52). However, additional investigation is required to fully assess the value of this treatment modality in the treatment of pterygium.

8. Conclusion

Despite controversies in the medical literature concerning HPV involvement in pterygium (possibly due to racial susceptibility or methodological differences), most studies agree that HPV is detected in at least a sub-group of pterygia and that HPV infection may affect both pathogenesis and clinical behaviour (including recurrence) of these lesions. Accordingly, it would be interesting to explore the possibility of anti-viral medications or even vaccination, which may represent novel options in the therapy of selected, HPV-infected pterygia.

References

1. Detorakis ET and Spandidos DA: Pathogenetic mechanisms and treatment options for ophthalmic pterygium: Trends and perspectives (Review). *Int J Mol Med* 23: 439-447, 2009.
2. Hirst LW: The Treatment of pterygium. *Surv Ophthalmol* 48: 145-180, 2003.
3. Coroneo MT: Pterygium as an early indicator of ultraviolet insolation: a hypothesis. *Br J Ophthalmol* 77: 734-739, 1993.
4. Chui J, Coroneo MT, Tat LT, Crouch R, Wakefield D and Di Girolamo N: Ophthalmic pterygium: a stem cell disorder with premalignant features. *Am J Pathol* 178: 817-827, 2011.
5. Detorakis ET, Zaravinos A and Spandidos DA: Growth factor expression in ophthalmic pterygia and normal conjunctiva. *Int J Mol Med* 25: 513-516, 2010.
6. Di Girolamo N, Wakefield D and Coroneo MT: Differential expression of matrix metalloproteinases and their tissue inhibitors at the advancing pterygium head. *Invest Ophthalmol Vis Sci* 41: 4142-4149, 2000.
7. Tsai YY, Chiang CC, Yeh KT, Lee H and Cheng YW: Effect of TIMP-1 and MMP in pterygium invasion. *Invest Ophthalmol Vis Sci* 51: 3462-3467, 2010.
8. Aspiotis M, Tsanou E, Gorezis S, Ioachim E, Skyrilas A, Stefanidou M and Malamou-Mitsi V: Angiogenesis in pterygium: study of microvessel density, vascular endothelial growth factor, and thrombospondin-1. *Eye (Lond)* 21: 1095-1101, 2007.
9. Solomon A, Li DQ, Lee SB and Tseng SC: Type plasminogen activator in primary pterygium body fibroblasts by inflammatory cytokines. *Invest Ophthalmol Vis Sci* 41: 2154-2163, 2000.

10. Solomon A, Grueterich M, Li DQ, Meller D, Lee SB and Tseng SC: Overexpression of insulin-like growth factor-binding protein-2 in pterygium body fibroblasts. *Invest Ophthalmol Vis Sci* 44: 573-580, 2003.
11. Detorakis ET, Sourvinos G, Tsamprakakis J and Spandidos DA: Evaluation of loss of heterozygosity and microsatellite instability in human pterygium: clinical correlations. *Br J Ophthalmol* 82: 1324-1328, 1998.
12. Dushku N, Hatcher SL, Albert DM and Reid TW: P53 expression and relation to human papillomavirus infection in pingueculae, pterygia, and limbal tumors. *Arch Ophthalmol* 117: 1593-1599, 1999.
13. Soussi T, Dehouche K and Bérout C: P53 website and analysis of P53 gene mutations in human cancer: forging a link between epidemiology and carcinogenesis. *Hum Mutat* 15: 105-113, 2000.
14. Freed-Pastor WA and Prives C: Mutant p53: one name, many proteins. *Genes Dev* 26: 1268-1286, 2012.
15. Detorakis ET, Drakonaki EE and Spandidos DA: Molecular genetic alterations and viral presence in ophthalmic pterygium. *Int J Mol Med* 6: 35-41, 2000.
16. Tsai YY, Chang CC, Chiang CC, Yeh KT, Chen PL, Chang CH, Chou MC, Lee H and Cheng YW: HPV infection and p53 inactivation in pterygium. *Mol Vis* 15: 1092-1097, 2009.
17. Burk RD, Chen Z and Van Doorslaer K: Human papillomaviruses: genetic basis of carcinogenicity. *Public Health Genomics* 12: 281-290, 2009.
18. Detorakis ET, Sourvinos G and Spandidos DA: Detection of herpes simplex virus and human papilloma virus in ophthalmic pterygium. *Cornea* 20: 164-167, 2001.
19. Gallagher MJ, Giannoudis A, Herrington CS and Hiscott P: Human papillomavirus in pterygium. *Br J Ophthalmol* 85: 782-784, 2001.
20. Piras F, Moore PS, Ugalde J, Perra MT, Scarpa A and Sirigu P: Detection of human papillomavirus DNA in pterygia from different geographical regions. *Br J Ophthalmol* 87: 864-866, 2003.
21. Schellini SA, Hoyama E, Shiratori CA, Sakamoto RH and Candeias JM: Lack of papillomavirus (HPV) in pterygia of a Brazilian sample. *Arq Bras Oftalmol* 69: 519-521, 2006.
22. Sjö NC, von Buchwald C, Prause JU, Norrild B, Vinding T and Heegaard S: Human papillomavirus and pterygium. Is the virus a risk factor? *Br J Ophthalmol* 91: 1016-1018, 2007.
23. Takamura Y, Kubo E, Tsuzuki S and Akagi Y: Detection of human papillomavirus in pterygium and conjunctival papilloma by hybrid capture II and PCR assays. *Eye (Lond)* 22: 1442-1445, 2008.
24. Rodrigues FW, Arruda JT, Silva RE and Moura KK: Polymorphism and human papillomavirus DNA associated with pterygium. *Genet Mol Res* 7: 1251-1258, 2008.
25. Otlu B, Emre S, Turkuoglu P, Doganay S and Durmaz R: Investigation of human papillomavirus and Epstein-Barr virus DNAs in pterygium tissue. *Eur J Ophthalmol* 19: 175-179, 2009.
26. Piecyk-Sidor M, Polz-Dacewicz M, Zagórski Z and Zarnowski T: Occurrence of human papillomavirus in pterygia. *Acta Ophthalmol* 87: 890-895, 2009.
27. Hsiao CH, Lee BH, Ngan KW, Chuang WY, Yeung L, Yeh LK, Tan HY, Hui-Kang D and Lin KK: Presence of human papillomavirus in pterygium in Taiwan. *Cornea* 29: 123-127, 2010.
28. Spandidos D, Xinarianos G, Ergazaki M, Giannoudis A and Tsamprakakis J: The presence of herpesviruses in pterygium. *Int J Oncol* 5: 749-752, 1994.
29. Chen YF, Hsiao CH, Ngan KW, Yeung L, Tan HY, Yang KH, Huang SC and Lin KK: Herpes simplex virus and pterygium in Taiwan. *Cornea* 27: 311-313, 2008.
30. Karcioğlu ZA and Issa TM: Human papilloma virus in neoplastic and non-neoplastic conditions of the external eye. *Br J Ophthalmol* 81: 595-598, 1997.
31. McDonnell JM, McDonnell PJ and Sun YY: Human papillomavirus DNA in tissues and ocular surface swabs of patients with conjunctival epithelial neoplasia. *Invest Ophthalmol Vis Sci* 33: 184-189, 1992.
32. Saegusa M, Takano Y, Hashimura M, Okayasu I and Shiga J: HPV type 16 in conjunctival and junctional papilloma, dysplasia, and squamous cell carcinoma. *J Clin Pathol* 48: 1106-1110, 1995.
33. Sjö NC, Heegaard S, Prause JU, von Buchwald C and Lindeberg H: Human papillomavirus in conjunctival papilloma. *Br J Ophthalmol* 85: 785-787, 2001.
34. Sjö NC, von Buchwald C, Cassonnet P, Norrild B, Prause JU, Vinding T and Heegaard S: Human papillomavirus in normal conjunctival tissue and in conjunctival papilloma: types and frequencies in a large series. *Br J Ophthalmol* 91: 1014-1015, 2007.
35. Kiire CA and Dhillon B: The aetiology and associations of conjunctival intraepithelial neoplasia. *Br J Ophthalmol* 90: 109-113, 2006.
36. Ateenyi-Agaba C, Franceschi S, Wabwire-Mangen F, Arslan A, Othieno E, Binta-Kahwa J, van Doorn LJ, Kleter B, Quint W and Weiderpass E: Human papillomavirus infection and squamous cell carcinoma of the conjunctiva. *Br J Cancer* 102: 262-267, 2010.
37. Hirst LW, Axelsen RA and Schwab I: Pterygium and associated ocular surface squamous neoplasia. *Arch Ophthalmol* 127: 31-32, 2009.
38. Artornsombudh P, Sanpavat A, Tinnungwattana U, Tongkhomsai V, Sansopha L and Tulvatana W: Prevalence and clinicopathologic findings of conjunctival epithelial neoplasia in pterygia. *Ophthalmology* 120: 1337-1340.
39. Bandyopadhyay R, Nag D, Mondal SK, Gangopadhyay S, Bagchi K and Bhaduri G: Ocular surface disorder in pterygium: role of conjunctival impression cytology. *Indian J Pathol Microbiol* 53: 692-695, 2010.
40. Abreu AL, Souza RP, Gimenes F and Consolaro ME: A review of methods for detect human Papillomavirus infection. *Virology* 9: 262, 2012.
41. Molijn A, Kleter B, Quint W and van Doorn LJ: Molecular diagnosis of human papillomavirus (HPV) infections. *J Clin Virol* 32 (Suppl 1): S43-S51, 2005.
42. Leto Md, Santos Júnior GF, Porro AM and Tomimori J: Human papillomavirus infection: etiopathogenesis, molecular biology and clinical manifestations. *An Bras Dermatol* 86: 306-317, 2011 (In English, Portuguese).
43. Mackay IM: Real-time PCR in the microbiology laboratory. *Clin Microbiol Infect* 10: 190-212, 2004.
44. Bustin SA, Benes V, Nolan T and Pfaffl MW: Quantitative real-time RT-PCR - a perspective. *J Mol Endocrinol* 34: 597-601, 2005.
45. Jensen EC: Real-time reverse transcription polymerase chain reaction to measure mRNA: use, limitations, and presentation of results. *Anat Rec (Hoboken)* 295: 1-3, 2012.
46. Todani A and Melki SA: Pterygium current concepts in pathogenesis and treatment. *Int Ophthalmol Clin* 49: 21-30, 2009.
47. Jonasch E and Haluska FG: Interferon in oncological practice: review of interferon biology, clinical applications, and toxicities. *Oncologist* 6: 34-55, 2001.
48. Vann RR and Karp CL: Perilesional and topical interferon alfa-2b for conjunctival and corneal neoplasia. *Ophthalmology* 106: 91-97, 1999.
49. Karp CL, Moore JK and Rosa RH Jr: Treatment of conjunctival and corneal intraepithelial neoplasia with topical interferon alpha-2b. *Ophthalmology* 108: 1093-1098, 2001.
50. Schechter BA, Schrier A, Nagler RS, Smith EF and Velasquez GE: Regression of presumed primary conjunctival and corneal intraepithelial neoplasia with topical interferon alpha-2b. *Cornea* 21: 6-11, 2002.
51. Schechter BA, Rand WJ, Velazquez GE, Williams WD and Starasoler L: Treatment of conjunctival papillomata with topical interferon Alfa-2b. *Am J Ophthalmol* 134: 268-270, 2002.
52. Esquenazi S: Treatment of early pterygium recurrence with topical administration of interferon alpha-2b. *Can J Ophthalmol* 40: 185-187, 2005.