



STANDARD ARTICLE

Safety of percutaneous ultrasound-guided fine-needle aspiration of adrenal lesions in dogs: Perception of the procedure by radiologists and presentation of 50 cases

Pascaline Pey¹  | Alessia Diana¹ | Federica Rossi² | Jeremy Mortier³ |
 Ulrike Kafka⁴ | Stefanie Veraa⁵ | Anna Groth⁶ | Megan MacLellan⁷ |
 Chiara Marin¹ | Federico Fracassi¹ 

¹Department of Veterinary Medical Science, Alma Mater Studiorum, University of Bologna, Bologna, Italy

²Clinica Veterinaria dell'Orologio, Bologna, Italy

³Service of Diagnostic Imaging, Small Animal Teaching Hospital, Institute of Veterinary Science, University of Liverpool, Neston, United Kingdom

⁴James Cook University, Townsville, Queensland, Australia

⁵Division of Diagnostic Imaging, Faculty of Veterinary Medicine, Utrecht, The Netherlands

⁶North Downs Specialist Referrals, Bletchingley, United Kingdom

⁷BluePearl Pet Hospital, Blaine, Maine

Correspondence

Pascaline Pey, Department of Veterinary Medical Science, Alma Mater Studiorum, University of Bologna, Via Tolara di Sopra 50, 40064 Ozzano Emilia, Bologna, Italy.
 Email: pascaline.pey@unibo.it

Abstract

Background: Percutaneous ultrasound (US)-guided fine-needle aspiration (FNA) of adrenal gland lesions is controversial in veterinary medicine.

Objective: To evaluate the frequency and radiologists' perception of the risk of the procedure as well as determining the incidence of complications.

Methods: Retrospective study. A first survey was submitted by e-mail to all board-certified radiologists of the American College of Veterinary Radiology (ACVR) and European College of Veterinary Diagnostic Imaging (ECVDI). A second survey was sent to radiologists who declared having performed the procedure at least once in their career (observational cross-sectional case study).

Results: The first survey was sent to 977 diplomates and answered by 138. Of 138 diplomates, 40 currently performed the procedure and 98 did not; 44 of the 98 gave the hypertensive crisis risk in pheochromocytoma as a reason. To the second survey, 12 of 65 responded positively; 50 dogs with 58 lesions were recruited, including 23 pheochromocytomas. Complications were reported in 4 of 50 dogs; 3 hemorrhages (1 mild and 1 moderate) and 1 death from acute respiratory distress syndrome (possibly related to laryngeal paralysis). No hypertensive crisis was reported. There was no relationship between the method of FNA/type of needle used and occurrence of complications. Based on the recollection of these 65 radiologists, who performed approximately 200 FNA of adrenal lesions, a death rate of approximately 1% was estimated.

Conclusions and Clinical Importance: Percutaneous US-guided FNA of adrenal lesions can be considered a minimally risky procedure, despite the negative perception by radiologists.

Abbreviations: ACVR, American College of Veterinary Radiology; ALP, alkaline phosphatase; CT, computed tomography; ECVDI, European College of Veterinary Diagnostic Imaging; FNA, fine-needle aspiration; US, ultrasound.

This is an open access article under the terms of the Creative Commons Attribution-NonCommercial-NoDerivs License, which permits use and distribution in any medium, provided the original work is properly cited, the use is non-commercial and no modifications or adaptations are made.

© 2020 The Authors. *Journal of Veterinary Internal Medicine* published by Wiley Periodicals, Inc. on behalf of the American College of Veterinary Internal Medicine.

KEYWORDS

canine, carcinoma, cytology, pheochromocytoma

1 | INTRODUCTION

In dogs, fine-needle aspiration (FNA), performed percutaneously under ultrasound (US) guidance, represents the most used and least invasive technique for the collection of cytological samples of abdominal organs.^{1,2} Adrenal cytology is able to discriminate the origin (cortical or medullary) of an adrenal neoplasm with a high diagnostic accuracy (90%-100%).³ The evaluation of an adrenal cytological sample can therefore be a major benefit in the diagnostic approach of adrenal lesions, even though inaccurate in distinguishing benign from malignant lesions.³

However, performing percutaneous US-guided FNA of adrenal lesions is controversial and remains an important debate in veterinary medicine.⁴⁻⁷ The risk of hypertensive crisis discourages veterinarians from the procedure,⁴⁻⁷ although evidence is only based on reports in the human literature.⁸⁻¹¹ In veterinary medicine, risk assessment is anecdotal. Bleeding, hematic contamination of the sample, and fear of spreading the neoplasm along the needle path are other concerns that may limit the general use of US-guided FNA of adrenal lesions.¹²⁻¹⁶ A recent paper evaluated the clinical safety of this procedure.¹⁷ One complication (ventricular tachycardia) was reported out of 23 percutaneous US-guided FNA of adrenal lesions.¹⁷ The authors concluded that the procedure was relatively safe, including the 10 pheochromocytomas sampled.¹⁷

In dogs, incidental masses of adrenal glands (AGs) are frequently detected on abdominal US and computed tomography (CT), with a prevalence of 4% and 9%, respectively.^{18,19} These can be primary tumors such as cortical adenoma, cortical carcinoma, pheochromocytoma, or metastases.^{7,20,21} Potential differential diagnoses also include macronodular hyperplasia, cysts, granuloma, hematoma, and myelolipomas.^{20,21} Following adrenal lesion detection, it is crucial to determine its potential functionality (secreting versus nonsecreting), its origin (epithelial or neuroendocrine), its biological nature (malignant or benign), and its connection with adjacent vessels/organs.^{4-6,22-24} History, clinical signs, clinicopathological findings, endocrine tests and US,^{25,26} contrast-enhanced US,²⁷⁻³¹ and CT^{32,33} can assist in predicting the functional aspect of an adrenal lesion and in differentiating between a benign and malignant process. The aforementioned imaging modalities can provide an estimate of potential malignancy and can be extremely helpful in selecting the best therapeutic approach, but they cannot predict the histological type of the adrenal lesion. Several situations might complicate the diagnostic approach. Secretory masses, in particular pheochromocytoma, can produce an insufficient amount of hormone and therefore less characteristic clinical signs and equivocal endocrine testing.^{4,5,22-24} This confuses their identity with that of a nonsecretory tumor. Nonsecreting adrenal masses, in turn, are silent from a biochemical point of view and may complicate the diagnostic workup.²¹ Different types of primary tumors may coexist, or each AG may be the site of a primary

tumor.³⁴⁻³⁷ As the preoperative treatment^{38,39} and surgical approach differs from one adrenal tumor to another,⁴⁰⁻⁴⁵ prior knowledge of the tumor type before surgery is relevant and desirable.

The main objectives of this study were (1) to evaluate the frequency of percutaneous US-guided FNA of adrenal lesions performed by veterinary radiologists, radiologists' opinion about the procedure, and (2) to determine the incidence of adverse effects associated with it.

2 | MATERIALS AND METHODS

A multicenter retrospective study involving board-certified veterinary radiologists was conducted. Two consecutive online surveys, using a web-based application (Google forms, Google LLC, Mountain View, California) were distributed via e-mail. To collect the data, a dedicated e-mail account was created. Access to the data was password protected. Only 1 author had knowledge of the password. Anonymized results were then exported in a spreadsheet opened with a dedicated program (Microsoft Excel, Microsoft Corporation, Way Redmond, Washington), where no information allowing identification of the institutions, radiologists, clients, and dogs was present.

2.1 | First online survey

Approval of the American College of Veterinary Radiology (ACVR) and European College of Veterinary Diagnostic Imaging (ECVDI) board secretaries was sought. An e-mail containing the link to the survey was sent directly by ACVR and ECVDI board secretaries, for privacy purposes. The first survey was a Knowledge, Attitude and Practice study. Before the start of the survey, a description of the aim and purposes of the study were provided. We emphasized that the survey would serve as a tool to further clinical knowledge. Radiologists were free to answer to the survey.

The first survey was initially submitted to answer the first objective of the study. It aimed at evaluating the percentage of veterinary radiologists performing the procedure, how frequently they performed it, and how often complications had been noted. We also asked the reasons why some radiologists were not performing FNAs on AG lesion. For any reason other than those cited, a short answer box was provided. The first survey was sent accompanied by a brief description of the project. Questions of the survey are documented in Appendix S1.

2.2 | Second online survey

The second survey was sent to veterinary radiologists who had performed the procedure at least once in their career. This survey was

intended to recruit cases and obtain data from the radiologists. This second survey contained specific questions regarding the clinical cases, referring particularly to the technique that was used and the potential complications, in order to evaluate the incidence of adverse events related to the procedure. Questions of the survey are documented in Appendix S2.

2.2.1 | Case selection criteria

Dogs with a unilateral or bilateral AG lesion(s) that underwent US-guided FNA were included in this observational cross-sectional case study if their signalment, ultrasonographic and cytological reports, and a 48-hour follow-up were available.

2.2.2 | Medical records review

Signalment, main clinical signs, and selected clinicopathological findings such as the presence of stress leukogram, thrombocytosis, increased alkaline phosphatase (ALP), and urinary specific gravity, the presence of proteinuria (through urinary protein:urinary creatinine ratio), endogenous ACTH concentrations, results of an ACTH stimulation test or of a low- or high-dose dexamethasone suppression test, systemic blood pressure before, during and after the FNA procedure, and measurements of urinary normetanephrine/urinary creatinine or serum metanephrine concentrations were collected in an excel spreadsheet if available and evaluated. The review of the medical records was mainly aimed at obtaining useful information for a diagnosis of cortisol producing or catecholamine producing adrenal tumor.^{4-6,21-24}

2.2.3 | Ultrasound reports review

From each US report and available US images, the following criteria were collected in an excel spreadsheet and reviewed: side and size (mm) of adrenal lesions, the dimension (mm) of the contralateral AG, echogenicity (hypoechoic, hyperechoic, or isoechoic to adjacent adipose tissue), echotexture (homogeneous, heterogeneous) and contours of the lesion (smooth or irregular), presence or absence of mineralization, and finally presence or absence of vascular invasion.^{25,26} The contralateral AG was considered atrophied when its maximal thickness was less than 5.0 mm.⁴⁶⁻⁴⁸ Computed tomographic reports, when available, were also reviewed, in order to complete the diagnostic workup. The revision of the US and CT images was at the discretion of the radiologist who submitted the case, if the report was not complete enough to answer to aforementioned criteria.

2.2.4 | Fine-needle aspiration procedure review

The size of the needle (diameter in gauge and length in mm), the type of procedure (with aspiration or capillary), if other organs were

aspirated, the presence of complications post-FNA within 48 hours, the cytological diagnosis, and, when available, the histopathological diagnosis (post-adrenalectomy or necropsy) were collected in an excel spreadsheet and reviewed.

2.2.5 | Statistical analysis

Descriptive methods were used to summarize findings. The data are reported as percentages and median values (range: minimum, maximum).

3 | RESULTS

3.1 | First online survey

The first online survey was sent to 977 board-certified radiologists. Of these, 138 responded to the survey, which represents a 14% participation rate. The results of the first online survey are depicted in Figure S1. The results of the short answer box are reported in Table 1. To the fourth

TABLE 1 List of other reasons (different from those cited and depicted in Figure 1) why veterinary radiologists would not perform percutaneous ultrasound-guided fine needle aspiration of the adrenal lesions

Number of answers	Answer
4	The results would not modify the therapeutic approach, do not provide useful clinical information
3	Risk of hypertensive crisis in case of pheochromocytoma, risk of hemorrhage and cytological results unreliable
2	Risk of hypertensive crisis in case of pheochromocytoma, risk of hemorrhage
2	Risk of hypertensive crisis in case of pheochromocytoma, not requested by clinicians
2	Not requested by clinicians
1	Risk of metastatic dissemination along the needle tract, risk of hemorrhage, proximity of the aorta and caudal vena cava, cytological results unreliable
1	Risk of hypertensive crisis, technically complicated procedure
1	High risk of multiple complications
1	High risk of hemorrhage
1	Risky procedure associated to the possibility to have nondiagnostic samples
1	If the adrenal lesion is small (3-8 mm), the procedure is technically difficult; if the adrenal lesion is larger (9-15 mm), it will be necessary to know if it is functional but the surgery remains advised
1	Witnessed 1 dog dying few minutes after the procedure
1	I do not do it as I am working on mobile ultrasound

TABLE 2 List of additional complications observed following percutaneous ultrasound-guided fine needle aspiration (FNA) of the adrenal lesions, reported directly by veterinary radiologists, which were not listed in the survey

Number of answers	Complication
7	Hemorrhage
2	Death
1	Shock
1	Hypotension
1	Adhesions at the FNA puncture site between the adrenal lesion and adjacent organs/tissue. This was observed during the adrenalectomy by the surgeon, and complicated the surgery

question regarding the prevalence of complications, 15 of 67 (22%) observed adverse reactions associated with the procedure (Figure S1D). Of these 15, 3 radiologists did not specify the type of complication and 12 gave details about the observed complications, which are tabulated in Table 2. Regarding procedure-related hemorrhage, 1 radiologist specified that it was subjectively severe (but did not state if it required surgery) and 1 specified that it was mild. Regarding the 1 case of death, 1 died suddenly after the procedure and the other a few hours later. With the former case, a comment was added that it was a confirmed pheochromocytoma and that the dog was already in a critical condition before the procedure. One radiologist answered that they had never observed complications but had heard about adverse effects from colleagues. One reported a case of hypertension after the FNA of a hepatic metastasis resulting from a pheochromocytoma. Of 138 respondents, 53 (38%) were currently working in academia, 80 (58%) in private practice or teleradiology, and 5 (4%) in both academia and private practice.

3.2 | Second online survey

The second survey was sent to 65 radiologists, from the first survey who had performed the procedure at least once in their career (and not only to the 40 who declared currently performing it). Twelve of 65 (18%) positive answers were obtained, that is, radiologists willing to provide clinical cases to constitute a retrospective multicenter study. From these 12 radiologists, 50 dogs were collected, coming from 15 different centers (depending on where the radiologist was working at that time). Regarding the origin of the cases, 24 of 50 dogs were seen in the university teaching hospital or academic equivalent and 26 of 50 dogs were seen in private practice. Cases that fulfilled the inclusion criteria were obtained from 2003 to 2018.

3.2.1 | Signalment

Cross breed (19/50) and purebred dogs (31/50) were represented. Of the 50 dogs, 11 were intact males, 11 castrated males, 4 intact

females, and 24 spayed females. The median age was 11 years (4-14 years) and the median body weight was 18 kg (6-57 kg).

3.2.2 | Clinical diagnosis

In 4 of 50 dogs, the clinical signs were not available. In 6 of 46 dogs, no abnormal clinical signs were reported and the adrenal lesion was incidentally discovered during a senior wellness checkup. The main clinical signs were polyuria-polydipsia (11/46), weakness (8/46), gastrointestinal signs (6/46), weight loss (5/46), anorexia (3/46), panting (3/46), lethargy (3/46), alopecia (2/46), trembling (2/46), and polyphagia (1/46). Hypertension was observed in 3 of 46 dogs.

3.2.3 | Diagnostic imaging

In 29 of 50 dogs (58%) only the left AG, in 13 of 50 dogs (26%) only the right AG, and in 8 of 50 dogs (16%) both AGs presented lesions. The adrenal lesions measured between 8 and 80 mm, and the contralateral AG measured between 3 and 9 mm (dogs with bilateral lesions excluded). In 9 of 42 dogs (21%), the contralateral gland was considered atrophied (<5.0 mm). Regarding the echogenicity of the adrenal lesions, 20 of 58 dogs were considered hyperechoic (34%), 16 of 58 hypoechoic (28%), and 14 of 58 isoechoic (24%). Regarding the echotexture, 40 of 58 were judged heterogeneous (69%). For the contours of the adrenal lesions, 17 of 58 were described as irregularly outlined (29%), 7 of 17 lesions had a clear capsular disruption, and 41 of 58 were considered smooth and with regular contours (71%). For the presence of mineralization, 1 of 58 lesion had mineral foci reported (2%). Vascular invasion was reported in 12 of 58 lesions (21%), 6 of 12 directly into the caudal vena cava and 1 of 12 into the left renal vein. No invasion of adjacent organs or tissues was reported. All the CT findings, when available, were consistent with the US findings and did not provide additional information regarding the presumed diagnosis.

3.2.4 | Percutaneous US-guided FNA procedure, complications, and cytological and histopathological diagnosis

Fifty-eight adrenal lesions from 50 dogs were aspirated (8 bilateral adrenal lesions). The caliber of the needle used and the method performed for the FNA are reported in the Figures 1 and 2. The information regarding the needle size and method used was not available in 7 and 5 dogs, respectively. None of the dogs received treatment with phenoxybenzamine before the FNA procedure. Blood pressure monitoring was performed in 17 of 50 dogs, and no hypertensive crisis was observed in these dogs.

Cytological analysis was conclusive in 41 of 58 (71%) lesions and nonconclusive in 17 of 58 (29%) lesions. From the 51 lesions where the caliber of the needle was known, the cytological analysis was conclusive in 33 of 43 (77%) and nonconclusive in 10 of 43 (23%) lesions

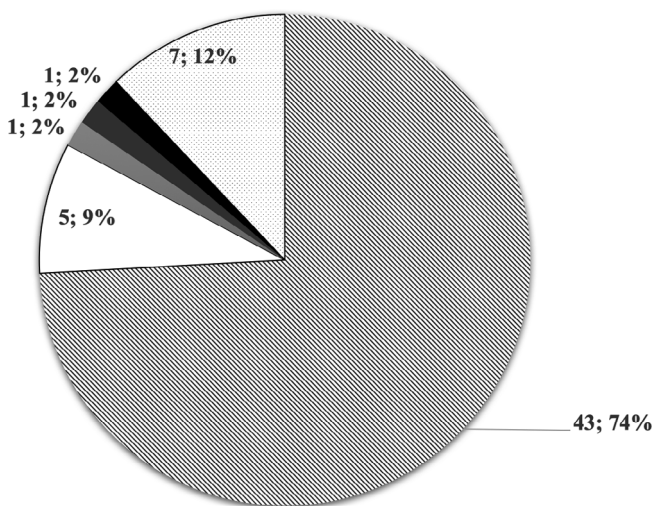


FIGURE 1 Graph representing the different calibers of needle used to perform percutaneous ultrasound-guided fine-needle aspiration of the adrenal lesions. A 22-gauge needle was used in 43 of 58 lesions (74%) (striped background), a 23-gauge needle was used in 5 of 58 lesions (9%) (white), a 25-gauge needle in 1 of 58 lesion (2%) (black), a 16-gauge needle in 1 of 58 lesion (2%) (dark gray), and a 21-gauge needle in 1 of 58 lesion (2%) (light gray). In 7 of 58 (12%), this information was not available (spotted background)

aspirated with a 22-gauge needle, conclusive in 2 of 2 lesions aspirated with a needle smaller than 22-gauge and conclusive in 5 of 6 and nonconclusive in 1 of 6 lesions aspirated with a needle larger than 22-gauge. From the 53 lesions where the information regarding the

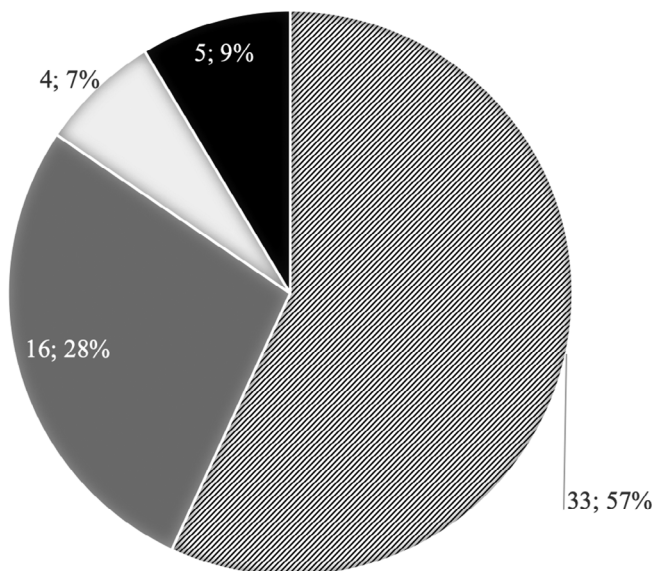


FIGURE 2 Graph representing the method used (aspiration versus capillary) to perform percutaneous ultrasound-guided fine-needle aspiration of the adrenal lesions. The fine-needle aspiration was done with capillary in 33 of 58 lesions (57%) (striped background), with aspiration in 16 of 58 lesions (28%) (dark gray) and with a mixed method in 4 of 58 lesions (7%) (light gray). This information was not available for 5 of 58 (9%) lesions (black)

FNA technique was available, the cytological analysis was conclusive in 24 of 33 (73%) and nonconclusive in 9 of 33 (27%) for the capillary technique, conclusive in 10 of 16 and nonconclusive in 6 of 16 for the aspiration technique, and conclusive in 3 of 4 and nonconclusive in 1 of 4 for a mixed technique (combined capillary and aspiration). Following the cytological analysis, 23 of 41 pheochromocytoma (56%), 6 of 41 carcinomas (14%), 5 of 41 adenoma (12%), 3 of 41 hyperplasia (7%), 2 of 41 extramedullary hematopoiesis (5%), 1 of 41 metastasis (from anal gland carcinoma) (2%), and 1 of 41 granuloma (from a migrating foreign body) (2%) were diagnosed. From the 17 of 58 cytologically inconclusive cases, hyperplasia and adenoma were not distinguishable in 6 of 17 cases; 6 of 17 were consistent with a neoplastic process, but identification of the tissue origin (neuroendocrine versus epithelial mainly) was not possible; adenoma and carcinoma could not be distinguished in 3 of 17 cases, and 2 of 17 were defined as nondiagnostic sampling.

Histopathological diagnosis was available in 8 of 58 lesions; 5 of 8 histopathological reports confirmed the cytological diagnosis (4 pheochromocytoma and 1 granuloma); 2 of 8 cytology had correctly identified cortical origin but could not definitively differentiate adenoma (1/8) from carcinoma (1/8). Of these 8 dogs, 1 received phenoxybenzamine before surgery, following results of the cytological analysis of pheochromocytoma.

Four dogs (10, 12, 35, and 45) experienced a complication, representing a complication rate of 4/50 (8%). The complication rate is reported per dog rather than per aspirate or adrenal lesion. In the remaining 46 of 50 dogs (92%), according to the clinical file, no adverse reaction was encountered in the 48 hours following the procedure. Dog 10 had moderate hemorrhage from the AG immediately after the procedure, followed by the formation of a hematoma measuring 2-3 cm. The dog was a 6-year-old male castrated Dachshund that had presented with a 3-4 cm large left adrenal mass with heterogeneous echogenicity and regular margins, without evidence of vascular invasion or atrophy of the contralateral gland. The procedure was performed under sedation, by capillary using a spinal needle (22 gauge and 63 mm in length). No other organs were aspirated during the procedure. The cytological analysis was suggestive of adenoma, and no histopathological diagnosis was available. Information regarding the main clinical signs or potential concomitant diseases and laboratory findings were not available. The dog was still alive 48 hours later. Dog 12 showed tachycardia, hyperthermia, cyanotic membranes, and death due to acute respiratory distress syndrome 28 hours after the procedure. The dog was a 7-year-old male castrated Pyrenean Mountain Dog, with a 46-mm large right adrenal mass, concurrent Wobbler syndrome, and laryngeal paralysis. The main reported clinical signs before FNA were weakness of the posterior limbs, panting, and fever. A stress-leukogram, increased ALP, and low urinary specific gravity (1012) were also present. Platelet count was within normal limits. No coagulation profile or endocrine tests were available. The right adrenal mass was hypoechoic, with irregular margins and disruption of the capsule, without evidence of vascular invasion, associated with a borderline atrophy (5.3 mm) of the contralateral AG. The FNA was performed during general anesthesia using aspiration technique, with a 22-gauge/38-mm long needle. No other organs were aspirated during

the procedure. The systemic blood pressure (systolic/diastolic [mean]) was measured before and after the procedure, and were 110/60 (85) mm Hg and 90/50 (70) mm Hg, respectively. The cytological analysis was consistent with pheochromocytoma, and no histopathological analysis was performed. Dog 35 was a mixed breed dog, male castrated, 11-year-old, 9.2 kg, presented with mild weight loss, concomitant cutaneous mast cell tumor, and salivary gland carcinoma. No blood analysis was available. The dog presented with bilateral adrenal lesions, measuring 8 and 9 mm on the left and right AGs, respectively. Both lesions were hyperechoic and heterogeneous on US and displayed smooth contours. No mineralization or vascular invasion were observed; no other ultrasonographic findings were reported regarding the rest of the abdomen. Computed tomography features were consistent with US findings with no additional information. During general anesthesia, both adrenal lesions underwent FNA procedure using a 30-gauge and 22-mm long needle with aspiration. Immediately after the FNA of the right adrenal lesion, a small amount of free fluid was noticed surrounding the adrenal, spontaneously resolved in a few hours. The dog was alive 4 months after the FNA procedure, but thoracic radiographs were consistent with pulmonary metastases. Cytological analysis of the adrenal aspirates confirmed a bilateral malignant process without distinguishing the type of tumor (pheochromocytoma versus carcinoma). No histopathologic analysis was available. Dog 45 was a 12-year-old female intact Beagle, weighing 20 kg, presented for diarrhea, vomiting, and hyporexia. No abnormality was observed on available blood work. On US, the dog presented with a heterogeneously hyperechoic lesion deforming the cranial pole (24 × 20 mm) of the left adrenal and a normal contralateral AG. No mineralization or vascular invasion was noticed. The liver and spleen were slightly heterogeneous, but no clear solid lesions were identified. The dog underwent, without sedation, FNA procedure of the left AG solely by capillary technique with a 22-gauge and 38-mm long needle: immediately following the procedure, a small amount of free fluid was observed surrounding the lesion; this was spontaneously resorbed 24 hours later during the follow-up US. The cytological analysis was consistent with adenoma or hyperplasia. No histopathologic analysis was performed. The dog was euthanized 3 years later for severe pancreatitis and aspiration pneumonia.

4 | DISCUSSION

This multicenter retrospective study confirmed that many veterinary clinicians believe percutaneous US-guided FNA of adrenal lesions to be unsafe.⁴⁻⁷ This contributes to the fact that it is not commonly performed.

From the first survey, it emerged that two thirds of radiologists currently do not perform FNAs of adrenal masses because of concern of potential adverse reactions. Although studies on the subject are limited¹⁷ with a paucity of significant data, the procedure is still not recommended or to be performed with caution.⁴⁻⁷

Through the first survey it emerged that among radiologists who have performed the procedure in the past or currently still

perform it, 78% have never encountered any complication while 22% report adverse effects. The most frequently reported complication was bleeding (7/12), followed by immediate or delayed (several hours) death (2/12). Judging from answers given by 65 veterinary radiologists who performed the procedure at least once in their career, at least 200 FNA of the adrenal lesions were performed. This would imply an estimated mortality rate of about 1%. However, this estimated number might be inaccurate as it relies on the recall of radiologists for cases over their whole career. We may consider that radiologists are more likely to recall cases with a bad outcome or the possibility that they might be unaware of any complication occurring after the patient leaves the US room. Therefore, this number should be treated with some caution and is meant to provide to the scientific community an idea of the magnitude of the risk.

Data acquired from the second survey showed that complications following the procedure were reported in only 4 of 50 dogs (8%), in which mild to moderate hemorrhage and a death (2%) due to acute respiratory distress syndrome occurred 28 hours after the FNA procedure. The latter occurred in the presence of another relevant concomitant disease (laryngeal paralysis). From both surveys, hypertensive crisis was not observed in any cases where blood pressure was monitored (18/50 dogs had blood pressure monitored in the second survey). Pheochromocytomas are suspected to be associated with a high frequency of complications. A total of 23 presumed pheochromocytoma (based on cytological analysis) and 8 lesions with nondiagnostic cytological analysis were sampled with FNA, and a complication (death) was reported in only 1 dog (3%). In the veterinary literature, there is only 1 recent reported case of adverse reaction following the FNA procedure.¹⁷ The dog experienced ventricular tachycardia, but the authors of that study specified that the dog presented with this condition before the procedure, most likely due to the presence of pericardial effusion. Consequently, the association between this adverse reaction and the FNA procedure is questionable, and the possibility that the complication had been triggered by underlying heart disease was suggested.

In our study, in the dogs that developed mild hemorrhage following the FNA procedure, results of a coagulation profile were not available; therefore, it was not possible to exclude a possible correlation between bleeding and an underlying coagulopathy.¹⁵ In these dogs, the procedure was equally performed under sedation/general anesthesia and with different FNA techniques (different needle size and different aspiration/capillary technique). In the veterinary literature, a study was carried out on the association between abnormalities in the coagulation profile and the risk of bleeding following an US-guided biopsy of abdominal organs.¹⁵ This study showed that in dogs, a prolonged prothrombin time increased the probability of hemorrhage following the procedure and that thrombocytopenia predisposed to severe hemorrhages, requiring transfusion or fluid therapy.

The dog in our study that died of respiratory distress 28 hours following the procedure had Wobbler syndrome (caudal cervical spondylomyelopathy) and laryngeal paralysis in addition to the adrenal mass. The laryngeal paralysis may have contributed to the acute

respiratory distress and is most likely the cause of death. However, this assumption could not be verified. Cytological analysis suspected a pheochromocytoma in this dog, raising the possibility that tachycardia and acute respiratory distress were triggered by the release of catecholamines following the aspiration of the mass. However, these complications occurred 28 hours after the procedure, while the half-life of the catecholamines is extremely short.⁴⁹ Since pheochromocytoma is a neoplasm that is often characterized by intermittent release of catecholamines, the distress displayed by the dog may have been due to the release of adrenaline and noradrenaline by the adrenal mass, independent of the FNA procedure.

In addition to the aforementioned recently published study,¹⁷ no other studies are available in the veterinary literature regarding complications adrenal aspiration. A similar retrospective study was recently conducted to investigate the incidence of complications of percutaneous US-guided FNA of the pancreas in dogs.⁵⁰ In this study, the percentage of complications following the procedure was also low (6.3%), similar to our results and those of Sumner et al (2018), suggesting that these techniques are not as dangerous as it is commonly believed. Studies have been carried out in the past on US-guided FNA of other abdominal organs, such as liver and spleen. They concluded that this procedure is minimally invasive and almost free of complications.⁵¹⁻⁵³ Studies in human literature report that the percentage of complications subsequent to FNA of the liver is around 0.5% and that mortality is extremely rare (0.01%).^{54,55} In our study, bleeding occurred in 1 dog in which a spinal needle (22-G; 63 mm) was used instead of a hypodermic needle and this could have influenced the risk of bleeding. In general, hypodermic, 22- to 25-gauge needles are commonly used for FNA of abdominal organs.^{1,2}

In veterinary literature, the few cases of adrenal aspiration described in the dog do not report the type of needle used. In the most recent study,¹⁷ it is specified that because of the retrospective nature of the study, these technical details about the procedure were not available but that a 25-gauge/38-mm hypodermic needle is routinely used in the clinic from which the cases were collected. No bleeding or other complications were reported following FNA.¹⁷ There is no reference in the literature commenting on the use of spinal needle for US-guided FNA of abdominal organs. The additional gesture of removing the mandrin from the spinal needle once in the adrenal lesion may have increased the duration of the procedure, induced *in situ* needle movement, and hence the risk of bleeding. This procedure was performed by capillary, a technique that is considered less invasive and traumatic to the lesion than aspiration, and consequently results in less hemodilution of the sample.¹⁴ Interestingly, a higher proportion of insufficient specimens using the capillary technique was also reported in the same paper.¹⁴

In the human literature, it is reported that hemorrhage and pneumothorax are the most frequently encountered complications following adrenal biopsy⁵⁶ and that bleeding is probably not related to the size of the needle used, at least when the diameter is above 18- to 23-gauge (core biopsy needles, not hypodermic aspirate needles).⁵⁷ It is however difficult to extrapolate the frequency of hemorrhage and pneumothorax from the human literature to veterinary patients

because of obviously different anatomy and technique. Interestingly, an overall 5.3% complication rate is reported, most minor (in 666 patients across 7 studies) when a mix of FNA and needle core biopsy techniques were used.⁵⁶

For the dog with a pheochromocytoma that died after 28 hours, a hypodermic needle of 22 gauge was used and the procedure was performed by aspiration. Since other cases of pheochromocytoma underwent FNA without complications, using both aspiration and capillary technique, it is difficult to hypothesize that there is a correlation between the technique (aspiration/capillary), and the release of catecholamines by the pheochromocytoma. The type of needle may not be incriminated, since the needle (hypodermic, of 22 gauge and 38 mm) was identical to most other cases of pheochromocytoma.

In the first survey, a radiologist reported the presence of adhesions at the FNA puncture site between the adrenal lesion and adjacent organs/tissue (cf. Table 2). This was observed during the adrenalectomy by the surgeon and complicated the surgery. Metastatic spread along the needle tract has not been reported in dogs with adrenal tumors but has been described in humans,¹⁶ and with FNA of carcinomas of other origin (eg, transitional cell carcinoma).⁵⁸ In our case, it was not specified whether the adjacent tissue to which the adrenal lesion was adherent, was infiltrated by tumor or not.

Our study compared the results of the cytological examination with the histological findings only in 8 of 58 lesions. Histology confirmed the cytological diagnosis in 5 of 8 lesions. However, the limited number of available histological analyses prevented us from reaching a conclusion with regard to the diagnostic accuracy of FNA of adrenal lesions.

In our study, excluding the dogs in which cytological examination reported the presence of a granuloma and extramedullary hematopoiesis, cytology was able to distinguish the origin of the adrenal lesion (cortical or medullary) in 48 of 55 (87%) lesions. This confirms the results of Bertazzolo et al,³ who demonstrated an accuracy of adrenal cytology in differentiating cortical lesions from medullary lesions of 90% to 100%. In our study, 5 cytological reports could not reliably distinguish between an adenoma or a cortical hyperplasia; this supports the findings of a previous publication in which differentiation between these 2 cortical lesions through cytology alone was difficult.³ Conclusions regarding the acquisition of diagnostic samples with other needle sizes were not possible in our study, due to limited numbers. It seems that the use of a 22-gauge needle yielded a conclusive cytological diagnosis in 77% of samples. Regarding the method used (ie, capillary versus aspiration), it was not possible from these results to prove the superiority of 1 technique over the other. Presumably, the types of lesions sampled by each technique were not identical between the 2 groups, and this could bias the sampling outcomes. In addition, the radiologist may have selected their technique based on vascularity/size/access/feel of the mass, which could also impact on the results.

Although the complication rate associated with the procedure seems low, is it worth taking the risk for the sake of a thorough clinical workup? There are probably a few clinical situations where percutaneous US-guided FNA of adrenal lesions is indicated, and there is no current consensus regarding the diagnostic workup of incidentaloma in

dogs, despite the high incidence reported on US and CT.^{20,21,59} The authors thought that the scientific community had to be informed of the low magnitude of the risk associated with this procedure when it is clinically indicated.

Even though 5 of 8 dogs were suspected to have pheochromocytoma according to cytological analysis, only 1 dog was pretreated with phenoxybenzamine before surgery. This goes a little against 1 of the main advantages of a presurgical FNA, as phenoxybenzamine-treated dogs had a significantly decreased death rate compared with untreated dogs.³⁹

The main limitations of our study rely on the low participation rate (14%). Although still in the range (10%-15%) of the expected participation rate for an external survey (versus 30%-40% for internal survey),⁶⁰ one can argue that the nonresponse bias may have an important impact on the value of these results. Although the impact of nonresponse bias on results cannot be as easily quantified as sampling error can, response rate can be used as one way to gauge the potential for nonresponse bias. The higher the response rate of a survey, the lower the risk of nonresponse bias. Even though the participation rate remains in the "acceptable" range, the high nonresponse bias may undermine the reliability of the results of the study, and this is not something that we could quantify. The other main limitation of the study is the potential selection bias in the recruitment of the cases. Radiologists who had decided to participate in the study may already have a strong opinion on the safety of percutaneous US-guided FNA of adrenal lesions and decided to participate in order to confirm their belief.^{61,62} In the same manner, participation to the first survey may have been influenced by the personal conviction on the topic and introduced a selection bias. Although we attempted not to use leading questions type in the first survey, we cannot assess if these questions could sway the respondents toward a particular answer. No assumption was indicated in the title of the questions to avoid encouraging a certain answer from the respondent.^{61,62} However, we provided specific options to select and despite the option for an "other" open response, this may have lead radiologists to think that they should be worried about, expect, or select from certain complications from the procedure. Completely open answers may have avoided this.

5 | CONCLUSION

According to our results, percutaneous US-guided FNA of adrenal lesions is considered a minimally risky procedure, despite veterinary radiologists' contrary opinion. In this study, the complications rate was similar to what has recently been published about FNAs of the adrenal lesions and comparable to the complication rate of FNAs of other abdominal organs. This study also confirmed good diagnostic accuracy of adrenal cytology in distinguishing neoplasms of cortical origin from those of medullary origin, indicating its relevance in the diagnostic workup of an adrenal lesion. Larger prospective studies would be recommended to investigate this technique in more detail, in order to draw additional conclusions in terms of safety and diagnostic accuracy.

ACKNOWLEDGMENTS

The authors thank all the radiologists that have participated to the online survey and taken time to contribute to the surveys, in particular Dorien S. Willems, Maurizio Longo, Marie De Swarte, Martha Larson, and Rochelle Solwei. The authors also acknowledge the European College of Veterinary Diagnostic Imaging and the American College of Veterinary Radiology for submitting to their members the online survey. The results of the study were presented at the EVDI conference, August 2019, Basel, Switzerland.

CONFLICT OF INTEREST DECLARATION

Authors declare no conflict of interest.

OFF-LABEL ANTIMICROBIAL DECLARATION

Authors declare no off-label use of antimicrobials.

INSTITUTIONAL ANIMAL CARE AND USE COMMITTEE (IACUC) OR OTHER APPROVAL DECLARATION

Authors declare no IACUC or other approval was needed.

HUMAN ETHICS APPROVAL DECLARATION

Authors declare human ethics approval was not needed for this study.

ORCID

Pascaline Pey  <https://orcid.org/0000-0003-3917-4756>

Federico Fracassi  <https://orcid.org/0000-0003-3121-2199>

REFERENCES

1. Wypij J. Getting to the point: indications for fine-needle aspiration of internal organs and bone. *Top Companion Anim Med.* 2011;26:77-85.
2. Liffman R, Courtman N. Fine needle aspiration of abdominal organs: a review of current recommendations for achieving a diagnostic sample. *J Small Anim Pract.* 2017;58:599-609.
3. Bertazzolo W, Didier M, Gelain M, et al. Accuracy of cytology in distinguishing adrenocortical tumors from pheochromocytoma in companion animals. *Vet Clin Pathol.* 2014;43:453-459.
4. Reusch C. Pheochromocytoma and multiple endocrine neoplasia. In: Feldman EC, Nelson RW, Reusch C, Scott-Moncrieff C, eds. *Canine and Feline Endocrinology.* 4th ed. St. Louis, MO: Elsevier; 2015:521-551.
5. Galac S. Pheochromocytoma. In: Ettinger SJ, Feldman EC, eds. *Textbook of Veterinary Internal Medicine.* 8th ed. St. Louis, MO: Elsevier; 2017:1838-1843.
6. Galac S, Reusch C, Kooistra H, Rijnberk A. Adrenals. In: Rijnberk A, Kooistra H, eds. 2nd ed. Hannover: Schlutersche Verlagsgesellschaft mbH & Co; 2010:93-154.
7. Bailey DB, Page RL. Tumors of the endocrine system. In: Withrow SJ, Vail DM, eds. *Withrow & MacEwen's Small Animal Clinical Oncology.* 4th ed. St. Louis, MO: Saunders Elsevier; 2007:583-609.
8. McCorkell S, Niles N. Fine-needle aspiration of catecholamine-producing adrenal masses: a possibly fatal mistake. *AJR Am J Roentgenol.* 1985;145:113-114.
9. Casola G, Nicolet V, vanSonnenberg E, et al. Unsuspected pheochromocytoma: risk of blood-pressure alterations during percutaneous adrenal biopsy. *Radiology.* 1986;159:733-735.
10. Sood S, Balasubramanian S, Harrison B. Percutaneous biopsy of adrenal and extra-adrenal retroperitoneal lesions: beware of catecholamine secreting tumours! *Surgeon.* 2007;5:279-281.

11. Vanderveen K, Thompson S, Callstrom M, et al. Biopsy of pheochromocytomas and paragangliomas: potential for disaster. *Surgery*. 2009;146:1158-1166.
12. Rose L, Dunn M, Bedard C. Effect of canine hyperadrenocorticism on coagulation parameters. *J Vet Intern Med*. 2013;27:207-211.
13. Jacoby R, Owings J, Ortenga T, et al. Biochemical basis for the hypercoagulable state seen in Cushing's syndrome. *Arch Surg*. 2001;139:1003-1006.
14. Savage C, Hopper K, Abendroth C. Fine-needle aspiration biopsy versus fine-needle capillary (nonaspiration) biopsy: in vivo comparison. *Radiology*. 1995;195:815-819.
15. Bigge L, Brown D, Penninck D. Correlation between coagulation profile findings and bleeding complications after ultrasound-guided biopsies: 434 cases (1993-1996). *J Am Vet Med Assoc*. 2001;37:228-233.
16. Voravud N, Shin DM, Dekmezian RH, Dimery I, Lee JS, Hong WK. Implantation metastasis of carcinoma after percutaneous fine-needle aspiration biopsy. *Chest*. 1992;102:313-315.
17. Sumner J, Lacorcía L, Rose A, et al. Clinical safety of percutaneous ultrasound-guided fine-needle aspiration of adrenal gland lesions in 19 dogs. *J Small Anim Pract*. 2018;59:357-363.
18. Cook A, Spaulding K, Edward J. Clinical findings in dogs with incidental adrenal gland lesions determined by ultrasonography: 151 cases (2007-2010). *J Am Vet Med Assoc*. 2014;244:1181-1185.
19. Baum JI, Boston SE, Case JB. Prevalence of adrenal gland masses as incidental findings during abdominal computed tomography in dogs: 270 cases (2013-2014). *J Am Vet Med Assoc*. 2016;249:1165-1169.
20. Melià C. Investigation of adrenal masses. In: Mooney CT, Peterson ME, eds. *BSAVA Manual of Canine and Feline Endocrinology*. 4th ed. Gloucester: British Small Animal Veterinary Association; 2012:272-277.
21. Behrend EN. Non-cortisol-secreting adrenocortical tumors and incidentalomas. In: Ettinger SJ, Feldman EC, eds. *Textbook of Veterinary Internal Medicine*. 8th ed. St. Louis, MO: Elsevier; 2017:1819-1825.
22. Pérez-Alenza D, Melià C. Hyperadrenocorticism in dogs. In: Ettinger SJ, Feldman EC, eds. *Textbook of Veterinary Internal Medicine*. 8th ed. St. Louis, MO: Elsevier; 2017:4345-4389.
23. Behrend E. Canine hyperadrenocorticism. In: Feldman EC, Nelson RW, Reusch C, Scott-Moncrieff C, eds. *Canine and Feline Endocrinology*. 4th ed. St. Louis, MO: Elsevier; 2015:377-444.
24. Behrend E, Kooistra H, Nelson R, et al. Diagnosis of spontaneous canine hyperadrenocorticism: 2012 ACVIM consensus statement (small animal). *J Vet Intern Med*. 2013;27:1292-1304.
25. D'Anjou MA, Penninck D. Adrenal glands. In: Penninck D, D'Anjou MA, eds. *Atlas of Small Animal Ultrasonography*. 2nd ed. Ames, IA: Wiley; 2015:387-402.
26. Nyland TG, Neelis DA, Mattoon JS. Adrenal glands. In: Mattoon JS, Nyland TG, eds. *Small Animal Diagnostic Ultrasound*. 3rd ed. St Louis, MO: Elsevier; 2015:541-546.
27. Pey P, Vignoli M, Haers H, et al. Contrast-enhanced ultrasonography of the normal canine adrenal glands. *Vet Radiol Ultrasound*. 2011;52:560-567.
28. Pey P, Daminet S, Smets PMY, et al. Contrast-enhanced ultrasonography of adrenal glands in dogs with pituitary-dependent hyperadrenocorticism. *Am J Vet Res*. 2013;74:417-425.
29. Pey P, Rossi F, Vignoli M, Duchateau L, Marescaux L, Saunders JH. Use of contrast-enhanced ultrasonography to characterize adrenal gland tumors in dogs. *Am J Vet Res*. 2014;75:886-892.
30. Bargellini P, Orlandi R, Dentini A, et al. Use of contrast-enhanced ultrasound in the differential diagnosis of adrenal tumors in dogs. *J Am Anim Hosp Assoc*. 2016;52:132-143.
31. Bargellini P, Orlandi R, Paloni C, et al. Contrast-enhanced ultrasonographic characteristics of adrenal glands in dogs with pituitary-dependent hyperadrenocorticism. *Vet Radiol Ultrasound*. 2013;54:283-292.
32. Wisner E, Zwingenberger A. Adrenal glands. In: Wisner E, Zwingenberger A, eds. *Atlas of Small Animal CT and MRI*. Ames, IA: John Wiley and sons, Inc; 2015:561-571.
33. Morandi F. In: Schwarz T, Saunders JH, eds. *Veterinary Computed Tomography*. Ames, IA: John Wiley and Sons, Inc; 2011:351-356.
34. Van Bokhorst KL, Kooistra HS, Boroffka SAEB, et al. Concurrent pituitary and adrenocortical lesions on computed tomography imaging in dogs with spontaneous hypercortisolism. *J Vet Intern Med*. 2019;33:72-78.
35. Ford S, Feldman E, Nelson R. Hyperadrenocorticism caused by bilateral adrenocortical neoplasia in dogs: four cases (1983-1988). *J Am Vet Med Assoc*. 1993;202:789-792.
36. Von Dehn B, Nelson R, Feldman E, et al. Pheochromocytoma and hyperadrenocorticism in dogs: six cases (1982-1992). *J Am Vet Med Assoc*. 1995;207:322-324.
37. Thuroczy J, van Sluijs F, Kooistra H, et al. Multiple endocrine neoplasias in a dog: corticotrophic tumour, bilateral adrenocortical tumours, and pheochromocytoma. *Vet Q*. 1998;20:56-61.
38. Reusch C, Feldman E. Canine hyperadrenocorticism due to adrenocortical neoplasia. Pretreatment evaluation of 41 dogs. *J Vet Intern Med*. 1991;5:3-10.
39. Herrera M, Mehl M, Kass P, et al. Predictive factors and the effect of phenoxybenzamine on outcome in dogs undergoing adrenalectomy for pheochromocytoma. *J Vet Intern Med*. 2008;22:1333-1339.
40. van Sluijs F, Sjollem B, Voorhout G, et al. Results of adrenalectomy in 36 dogs with hyperadrenocorticism caused by adrenocortical tumour. *Vet Q*. 1995;17:113-116.
41. Kyles A, Feldman E, De Cock H. Surgical management of adrenal gland tumors with and without associated tumor thrombi in dogs: 40 cases (1994-2001). *J Am Vet Med Assoc*. 2003;223:654-662.
42. Schwartz P, Kovak J, Koprowski A, et al. Evaluation of prognostic factors in the surgical treatment of adrenal gland tumors in dogs: 41 cases (1999-2005). *J Am Vet Med Assoc*. 2008;232:77-84.
43. Massari F, Nicoli S, Romanelli G, Buracco P, Zini E. Adrenalectomy in dogs with adrenal gland tumors: 52 cases (2002-2008). *J Am Vet Med Assoc*. 2011;239:216-221.
44. Barrera JS, Bernard F, Ehrhart EJ, Withrow SJ, Monnet E. Evaluation of risk factors for outcome associated with adrenal gland tumors with or without invasion of the caudal vena cava and treated via adrenalectomy in dogs: 86 cases (1993-2009). *J Am Vet Med Assoc*. 2013;242:1715-1721.
45. Mayhew PD, Culb WT, Balsa IM, et al. Phrenicoabdominal venotomy for tumor thrombectomy in dogs with adrenal neoplasia and suspected vena caval invasion. *Vet Surg*. 2018;47:227-235.
46. Benckekroun G, de Fornel-Thibaud P, Rodriguez Pineiro M, et al. Ultrasonography criteria for differentiating ACTH-dependency from ACTH-independency in 47 dogs with hyperadrenocorticism and adrenal asymmetry. *J Vet Intern Med*. 2010;24:1077-1085.
47. Choi J, Kim H, Yoon J. Ultrasonographic adrenal gland measurements in clinically normal small breed dogs and comparison with pituitary-dependent hyperadrenocorticism. *J Vet Med Sci*. 2011;73:985-989.
48. De Chalus T, Combes A, Bedu AS, et al. Ultrasonographic adrenal gland measurements in healthy Yorkshire Terriers and Labrador Retrievers. *Anat Histol Embryol*. 2013;42:57-64.
49. Eisenhofer G, Kopin IJ, Goldstein DS. Catecholamine metabolism: a contemporary view with implications for physiology and medicine. *Pharmacol Rev*. 2004;56:331-349.
50. Cordner AP, Sharkey LC, Armstrong PJ, McAteer KD. Cytologic findings and diagnostic yield in 92 dogs undergoing fine-needle aspiration of the pancreas. *J Vet Diagn Invest*. 2015;27:236-240.
51. O'Keefe D, Couto C. Fine-needle aspiration of the spleen as an aid in the diagnosis of splenomegaly. *J Vet Intern Med*. 1987;1:102-109.

52. Léveillé R, Partington BP, Biller DS, Miyabayashi T. Complications after ultrasound-guided biopsy of abdominal structures in dogs and cats: 246 cases (1984-1991). *J Am Vet Med Assoc.* 1993;203:413-415.
53. Ballegeer E, Forrest L, Dickson R, et al. Correlation of ultrasonographic appearance of lesions and cytologic and histologic diagnoses in splenic aspirates from dogs and cats: 32 cases (2002-2005). *J Am Vet Med Assoc.* 2007;230:690-696.
54. Buscarini L, Fornari F, Bolondi L, et al. Ultrasound-guided fine-needle biopsy of focal liver lesions: techniques, diagnostic accuracy and complications. A retrospective study on 2091 biopsies. *J Hepatol.* 1990; 11:344-348.
55. Chhieng DC. Fine needle aspiration biopsy of liver—an update. *World J Surg Oncol.* 2004;2:1-8.
56. Sharma K, Venkatesan A, Swerdlow D, et al. Image-guided adrenal and renal biopsy. *Tech Vasc Interv Radiol.* 2010;13:100-109.
57. Welch T, Sheedy P, Stephens D, et al. Percutaneous adrenal biopsy: review of a 10-years experience. *Radiology.* 1994;193:341-344.
58. Nyland T, Wallack S, Wisner E. Needle-tract implantation following ultrasound-guided fine-needle aspiration biopsy of transitional cell carcinoma of the bladder, urethra and prostate. *Vet Radiol Ultrasound.* 2002;43:50-53.
59. Sahdev A. Recommendations for the management of adrenal incidentalomas: what is pertinent for radiologists? *Br J Radiol.* 2017; 90:20160627.
60. Floyd J Fowler Jr. Nonresponse: implementing a sample design. In: Floyd J Fowler Jr, ed. *Survey Research Methods.* 5th. Thousand Oaks, CA: SAGE Publications, Inc 2014:43-48.
61. Green CE. Can qualitative research produce reliable quantitative findings? *Field Methods.* 2001;13:3-19.
62. Launiala A. How much can a KAP survey tell us about people's knowledge, attitudes and practices? Some observations from medical anthropology research on malaria in pregnancy in Malawi. *Anthropol Matters J.* 2009;11:1-13.

SUPPORTING INFORMATION

Additional supporting information may be found online in the Supporting Information section at the end of this article.

How to cite this article: Pey P, Diana A, Rossi F, et al. Safety of percutaneous ultrasound-guided fine-needle aspiration of adrenal lesions in dogs: Perception of the procedure by radiologists and presentation of 50 cases. *J Vet Intern Med.* 2020;34:626-635. <https://doi.org/10.1111/jvim.15743>