



Case Report

Temporary standalone percutaneous fixation with pedicle screws for the treatment of subacute tuberculous osteomyelitis with kyphotic deformity in the lumbar spine

Mokshal H. Porwal¹, Danyon J. Anderson¹, Omar Hussain, Brandon Robert Winston Laing, Hesham Soliman

Department of Neurosurgery, Medical College of Wisconsin, Milwaukee, United States.

E-mail: *Mokshal H. Porwal - mporwal@mcw.edu; Danyon J. Anderson - djanderson@mcw.edu; Omar Hussain - omhussain@mcw.edu; Brandon Robert Winston Laing - blaing@mcw.edu; Hesham Soliman - hsoliman@mcw.edu



*Corresponding author:

Mokshal H. Porwal,
Department of Neurosurgery,
Medical College of Wisconsin,
Milwaukee, United States.

mporwal@mcw.edu

Received : 13 May 2022

Accepted : 06 June 2022

Published : 17 June 2022

DOI

10.25259/SNI_457_2022

Quick Response Code:



ABSTRACT

Background: Tuberculous (TB) osteomyelitis is a rare, but challenging infection, that mandates antituberculosis antibiotics, and potentially surgical intervention. Per the Gulhane Askeri Tip Akademisi (GATA) classification system, corrective reconstruction is indicated in severe cases, where the kyphotic deformity is $>20^\circ$ (GATA Class III). Here, we describe a case of BCG vaccine-induced lumbar TB osteomyelitis at the L1-2 level in a patient presenting with mechanical pain and a focal, nonfixed kyphotic deformity of 36.1° . Surgery consisted of percutaneous fixation with pedicle screws without debridement, fusion arthrodesis, or anterior reconstruction.

Case Description: A 77-year-old male presented with L1-2 TB osteomyelitis secondary to intravesical BCG application. A 36.1° focal nonfixed kyphotic deformity was evident on standing X-rays that reduced in the supine position. He underwent posterior percutaneous screw fixation with rods extending from the T12 to L3 levels, with resolution of his mechanical pain. Nine months later, the CT demonstrated reconstitution of the vertebral bodies (i.e., volume increase of 6.99 cm^3 (21%) and 7.49 cm^3 (27%) at L1 and L2, respectively). Standing X-rays after hardware removal demonstrated 32.7° of lumbar lordosis and a reduction of focal kyphosis to 12.9° .

Conclusion: Here, we present an exceedingly rare case of BCG vaccine-induced L1-2 spinal tuberculosis with extensive vertebral body destruction and deformity. This was effectively treated with standalone temporary pedicle fixation instead of corpectomy and reconstruction.

Keywords: BCG vaccine, GATA classification, Percutaneous fixation, Spinal tuberculosis, Tuberculous osteomyelitis

INTRODUCTION

Mycobacterium tuberculosis and, rarely, *Mycobacterium bovis* are two uncommon microbes which can cause Tuberculous (TB) osteomyelitis, also referred to as Pott's disease of the spine. For TB-related infections, the treatment typically includes long-term antibiotic therapy. External brace immobilization is also often recommended for pain control and requires close clinical and radiographic follow-up.^[9] Globally, systemic dissemination of community acquired pulmonary TB is the most common source of TB osteomyelitis.^[10] Bacille Calmette–Guerin (BCG) vaccine is a live, attenuated form of *M. bovis* commonly utilized in the United States for its unique utility in the treatment of bladder cancer through intravesical administration.^[11] There is a rare, but

This is an open-access article distributed under the terms of the Creative Commons Attribution-Non Commercial-Share Alike 4.0 License, which allows others to remix, transform, and build upon the work non-commercially, as long as the author is credited and the new creations are licensed under the identical terms.

©2022 Published by Scientific Scholar on behalf of Surgical Neurology International

serious risk of systemic TB dissemination which can lead to spinal TB.^[7] We found 25 reports of spinal TB related to intravesical administration of BCG vaccine for the treatment bladder cancer.^[2]

Surgery

Per the Gulhane Askeri Tip Akademisi (GATA) classification system, correction of deformity, reconstruction, and decompression are indicated when overt deformities of $>20^\circ$, instability, or vertebral collapse are present.^[8] Temporary percutaneous fixation offers reduction of nonfixed deformities of the thoracolumbar spine and confers stability until the vertebral bodies reconstitute with adequate treatment of the infection. Here, we report an extremely rare case of BCG vaccine-induced TB osteomyelitis in the lumbar spine, with a GATA classification of Class III that typically would have warranted decompression and reconstruction.^[8] Nevertheless, we chose temporary percutaneous instrumentation, without decompression, debridement, fusion arthrodesis, or anterior reconstruction, given the nonfixed nature of his focal deformity. This allowed for stabilization and reduction of the significant, nonfixed deformity at the thoracolumbar junction along with further bone reconstitution, and ultimate hardware removal.

METHODS

We present a case report and review of the literature involving 54 patients with TB who underwent standalone percutaneous instrumentation, without fusion, for TB osteomyelitis in the thoracolumbar spine.

Case presentation

A 77-year-old male with a history of bladder cancer was treated in early 2018 with intravesical injection of BCG (i.e., a stimulant for a cell-mediated immune response). A few months following his last dose, he presented with severe lower back pain and lumbar radiculopathy. A biopsy of a L1-2 vertebral lesion documented *M. bovis* (i.e., TB osteomyelitis). Despite anti-TB antibiotics including rifampin, isoniazid, and ethambutol, his symptoms progressed. When the MRI demonstrated progressive degenerative L1–L5 stenosis, he underwent a L1-5 laminectomy. Following this procedure, his radiculopathy and hip pain resolved [Figure 1].

Recurrent symptoms/signs of TB L1–L2 osteomyelitis

Five weeks later, he experienced progressive mechanical back pain despite bracing, night sweats, and fever. X-rays and the CT studies confirmed progressive osteomyelitic destruction of the L1–L2 vertebral bodies [Figures 2a and b]. Standing X-rays demonstrated a 36.1° focal kyphotic deformity at L1-2

that reduced in recumbency; the lumbar lordosis was reduced to 15.7° . The MRI also showed minimal stenosis due the L1-2 level phlegmon [Figures 2c and d]. Volumetric analysis and comparison with CT scans demonstrated a vertebral volume of 33.81cm^3 at L1 and 27.59cm^3 at L2, corresponding to 42% and 41% L1 and L2 vertebral body destruction, mostly involving the anterior column [Figure 2].

Secondary surgery

The patient underwent posterior percutaneous pedicle screw fixation with rods from T12 to L3 that successfully reduced the kyphotic deformity [Figure 3a]. He had an uneventful postoperative recovery and completed 11 months of anti-TB treatment (i.e., 11 months of rifampin and isoniazid and 2 months of pyrazinamide, and ethambutol). CT scans 9 months postoperative demonstrated reconstitution of the bone involving the L1–L2 vertebral bodies (i.e., volumes of 40.80cm^3 at L1 and 35.08cm^3 at L2, reflecting an increase of 6.99cm^3 (21%) and 7.49cm^3 (27%), respectively), as shown in Figure 3b. However, he refused to have the rods removed until they fractured 13 months later at L1-2. They were removed without incident, and 6 weeks later, the patient was asymptomatic with upright X-rays showing a 32.7° lumbar lordosis, with focal residual kyphosis at L1-2 reduced to only 12.9° [Figures 3c and 4].

DISCUSSION

BCG treatment of bladder cancer with 5% rare complication of osteomyelitis

The BCG vaccine is a live, attenuated form of *M. bovis* commonly used to prevent tuberculosis infection in high-risk countries. A unique additional use of this vaccine is for intravesical injection in the treatment of bladder cancer; $<5\%$ of patients experience adverse reactions to this treatment.^[7] Spinal TB is one of the complications, and in this case resulted in L1–L2 TB osteomyelitis. Broeckx and Buelens, in 2020, reviewed 25 reports of TB osteomyelitis resulting from intravesical administration of BCG vaccine for bladder cancer, further documenting that this is an extremely rare phenomenon.^[2]

Anti-TB antibiotics are the mainstay treatment of spinal TB to treat the underlying infection.^[5] There are also a variety of surgical procedures available to reconstruct the spine, where TB has resulted (i.e., in up to 18% of cases) with significant osteomyelitis/bony destruction and deformity.^[1] A GATA classification system to help guide surgical intervention consists of three classes.^[8] Surgical management was suggested in our patient to minimize risk of progression from the L1–L2 osteomyelitis due to the evolving severe kyphotic deformity. In this case, despite an overt kyphotic deformity of 36.1° , we utilized standalone temporary percutaneous

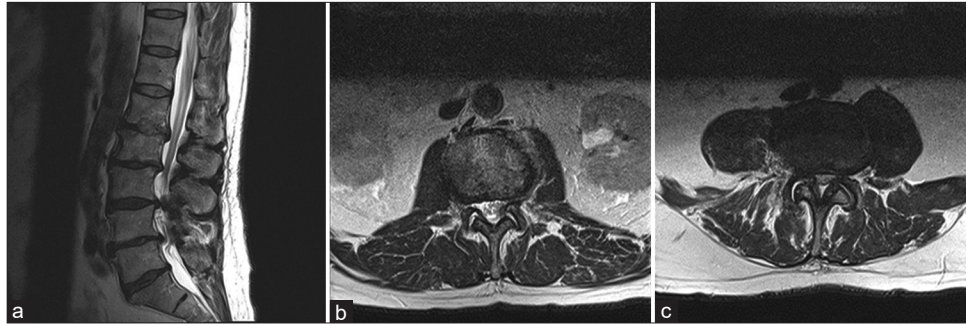


Figure 1: Prelaminectomy T2 MRI (a) sagittal lumbar spine, (b) axial L1-2 spine, (c) axial L3-4 spine multilevel degenerative changes are noted resulting in severe canal stenosis particularly at L2–L3 and L3–L4 and slightly less pronounced canal narrowing at L4–L5 and L1–L2. Multilevel foraminal narrowing are noted from L1 to S1.

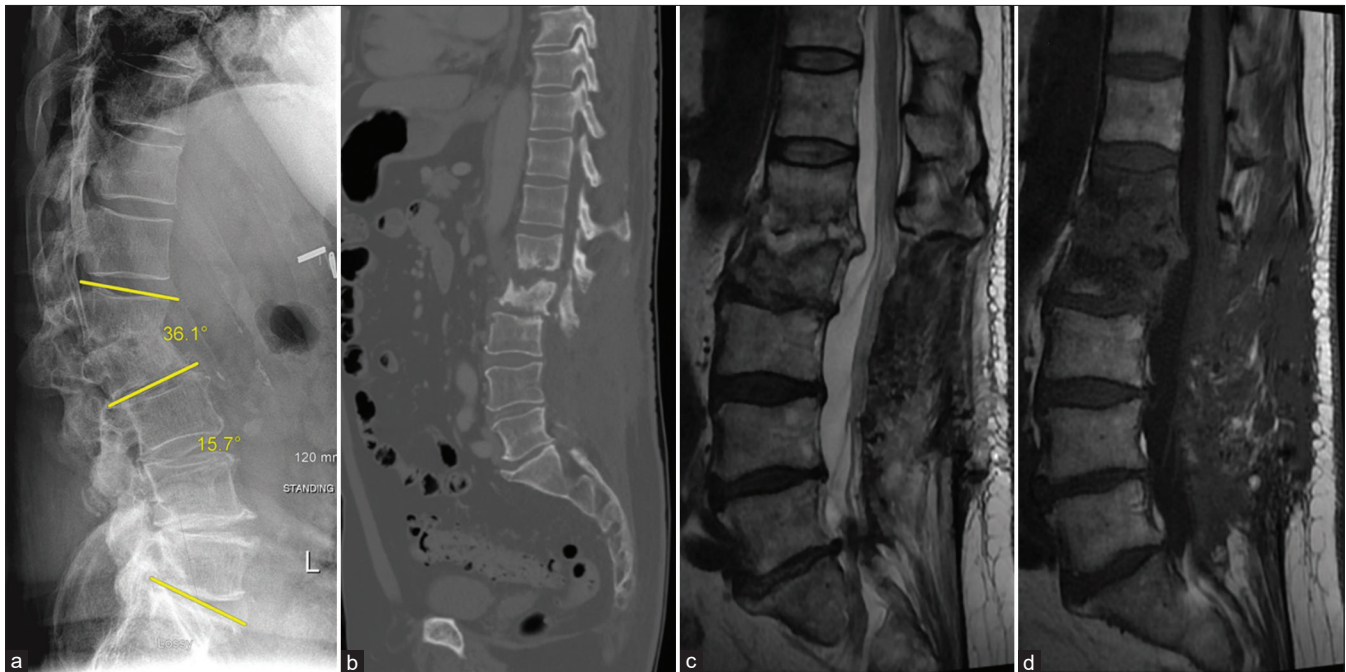


Figure 2: Prefixation scans: (a) standing lateral X-ray: lumbar Lordosis 15.7° and L1-2 kyphosis 36.1° (as illustrated by yellow lines), (b) CT scan: L1-2 erosion, L1 vertebral volume is 33.81 cm³, and L2 volume are 27.59 cm³, (c) T2, and (d) T1 sagittal lumbar spine MRI post contrast. There is L1 and L2 edema and destruction with L1-2 disk enhancement.

fixation to reduce the deformity without performing a decompression and/or a fusion.

Literature review

Percutaneous instrumentation/fixation, without fusion arthrodesis, with pedicle screws has been previously described in the setting of bacterial pyogenic osteomyelitis, including spinal TB [Table 1].^[3,4,6,12,13] Standalone percutaneous instrumentation, without fusion or decompression, for TB osteomyelitis in the thoracolumbar spine has been reported in a total of 56 patients in the literature. Guo *et al.* found percutaneous fixation alone to be effective in treating spinal tuberculosis in 22 patients versus a more invasive hybrid

approach.^[6] Yang *et al.* reported another 34 patients with spinal TB treated with standalone percutaneous fixation.^[13] These cases all had limited deformity except one case (>20° deformity), where application of percutaneous fixation did not yield any correction to the kyphotic deformity, perhaps due to a fixed nature of the deformity. In our case, percutaneous instrumentation alone, without fusion, allowed for excellent bone reconstitution and stabilization. CT volumetric analysis at L1 and L2 levels one year after percutaneous fixation showed a total volume increase of 6.99 cm³ (21%) and 7.49 cm³ (27%), respectively, sufficient to confer spine stability. Radiographically, standing X-rays also demonstrated sustained improvement in the patient's focal kyphosis at L1-2.

Table 1: Percutaneous fixations, without fusion arthrodesis, for spinal tuberculosis.

Authors+	Year Published	Article Type	Patients	Additional Procedures	Hardware Removed?	Complication Rate (%)
*Guo <i>et al.</i> ^[6]	2019	Retrospective	22 percutaneous fixations 20 minimally invasive fusions	None	No	0
*Carvalho <i>et al.</i> ^[3]	2011	Case	1	Discectomy and drainage (Portuguese)	No	0
*Garg and Vohra ^[4]	2014	Retrospective	8 percutaneous fixations 12 minimally invasive fusions	Posterior transpedicular decompression or anterior debridement and ventral-column reconstruction	Initially planned, but not removed	10
*Xu <i>et al.</i> ^[12]	2018	Retrospective	19	Local percutaneous endoscopic debridement and chemotherapy (Chinese)	No	Not available
*Yang <i>et al.</i> ^[13]	2016	Retrospective	34	Local chemotherapy	No	3

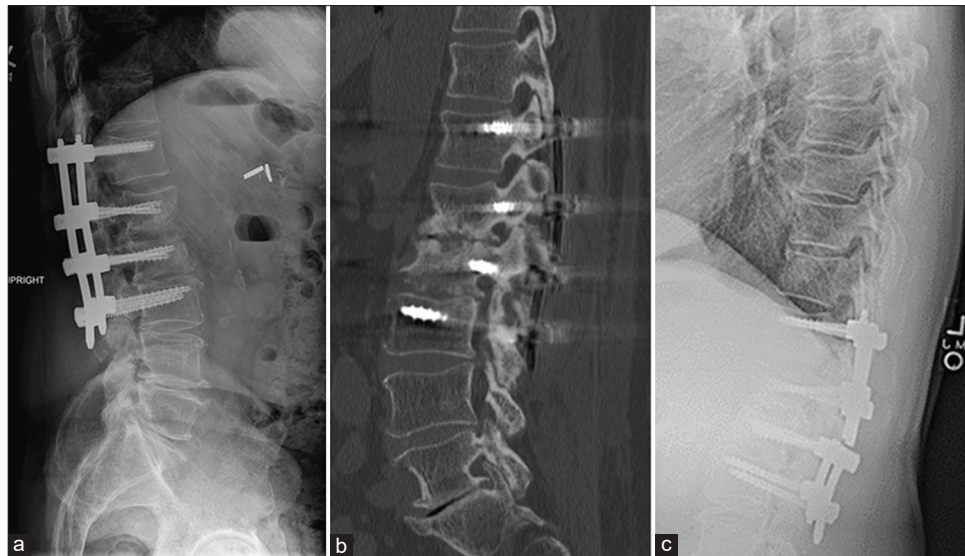

Figure 3: Post standalone percutaneous fixation scans (a) lateral X-ray post 8 months, (b) CT scan post 9 months. Reconstitution of L1 vertebral volume is 40.80 cm³ and L2 volume is 35.08 cm³. (c) Lateral X-ray 11-month post fixation showing broken rods at L1-2.

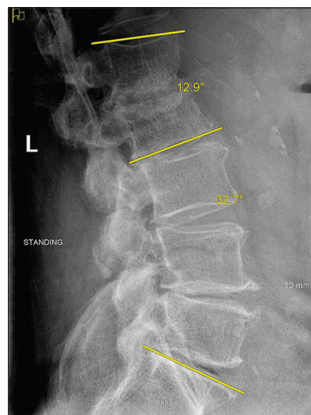


Figure 4: Two months post hardware removal standing X-rays. Lumbar lordosis is 32.7°, L1-2 Cobb: 12.9° (as illustrated by yellow lines).

CONCLUSION

We present a rare case of BCG vaccine-induced L1-2 TB osteomyelitis with extensive (42% at L1, 41% at L2) vertebral body destruction that was successfully treated with a stand-alone percutaneous fixation technique instead of utilizing traditional decompression and/or fusion procedures.

Declaration of patient consent

The authors certify that they have obtained all appropriate patient consent.

Financial support and sponsorship

Nil.

Conflicts of interest

There are no conflicts of interest.

REFERENCES

1. Alam S, Phan K, Karim R, Jonayed SA, Munir HK, Chakraborty S, *et al.* Surgery for spinal tuberculosis: A multi-center experience of 582 case. *Glob Spine J* 2016;1:65-71.
2. Broeckx S, Buelens E. Tuberculous spondylitis following intravesical bcg-instillation in the treatment of transitional cell carcinoma: Case report and systematic review. *Clin Neurol Neurosurg* 2020;194:105944.
3. Carvalho B, Pereira P, Silva PS, Silva J, Pinto M, Vazs R. Lumbar tuberculous spondylodiscitis: A minimally invasive surgical approach. *Acta Reumatol Port* 2011;36:57-60.
4. Garg N, Vohra R. Minimally invasive surgical approaches in the management of tuberculosis of the thoracic and lumbar spine. *Clin Orthop Relat Res* 2014;472:1855-67.
5. Garg RK, Somvanshi DS. Spinal tuberculosis: A review. *J Spinal Cord Med* 2011;34:440-54.
6. Guo S, Zhu K, Zhang S, Ma B, Yang M, Yan M, *et al.* Percutaneous pedicle screw fixation alone versus debridement and fusion surgery for the treatment of early spinal tuberculosis: A retrospective cohort study. *Med Sci Monit* 2019;25:1549-57.
7. Lamm DL. Efficacy and safety of bacille Calmette-Guérin immunotherapy in superficial bladder cancer. *Clin Inf Dis* 2000;31 Suppl 3:S86-90.
8. Oguz E, Sehirlioglu A, Altinmakas M, Ozturk C, Komurcu M, Solakoglu C, *et al.* A new classification and guide for surgical treatment of spinal tuberculosis. *Int Orthop* 2008;32:127.
9. Rutges JP, Kempen DH, van Dijk M, Oner FC. Outcome of conservative and surgical treatment of pyogenic spondylodiscitis: A systematic literature review. *Eur Spine J* 2016;25:983-99.
10. Schirmer P, Renault CA, Holodniy M. Is spinal tuberculosis contagious? *Int J Infect Dis* 2010;14:e659-66.
11. von Reyn CF, Vuola JM. New vaccines for the prevention of tuberculosis. *Clin Infect Dis* 2002;35:465-74.
12. Xu NJ, Chen YL, Jiang WY, Ma WH. Treatment of senile spinal tuberculosis with posterior percutaneous pedicle screw fixation combined with local percutaneous endoscopic debridement. *Zhongguo Gu Shang* 2018;31:1005-11.
13. Yang H, Song F, Zhang L, Li N, Zhang X, Wang Y. Management of spine tuberculosis with chemotherapy and percutaneous pedicle screws in adjacent vertebrae: A retrospective study of 34 cases. *Spine (Phila Pa 1976)* 2016;41:E1415-20.

How to cite this article: Porwal MH, Anderson DJ, Hussain O, Laing BR, Soliman H. Temporary standalone percutaneous fixation with pedicle screws for the treatment of subacute tuberculous osteomyelitis with kyphotic deformity in the lumbar spine. *Surg Neurol Int* 2022;13:256.