

Long-term survival in a stage IV small cell carcinoma of the endometrium

M. Viau, I. Baragar, A.D. Altman*

Department of Obstetrics, Gynecology, and Reproductive Science, University of Manitoba, Canada

ARTICLE INFO

Keywords:

Small cell carcinoma of the endometrium
Endometrial carcinoma
Chemotherapy

1. Introduction

Small cell carcinoma of the female genital tract comprises less than 2% of all gynecological malignancies, arising most commonly in the cervix (Walenkamp et al., 2009). Endometrial small cell carcinoma is a rare malignancy, with less than 100 cases reported in the literature to date. It often occurs admixed with other histologic tumour types, such as endometrioid or adenosquamous carcinomas (Matsumoto, 2011), however the natural history of the disease is determined by the presence of the small cell component (Walenkamp et al., 2009). Due to its sparse occurrence and aggressive nature (Katahira, 2004), limited evidence exists to guide treatment and survival remains poor, with literature reporting an estimated mean survival of 12 months and median survival of 2 months for those cases presenting at advanced stages. This is a case of stage IV mixed small cell carcinoma of the endometrium mixed with grade 3 endometrioid adenocarcinoma. The patient was treated with surgery, chemotherapy, and radiotherapy, and demonstrates no evidence of disease recurrence at follow-up 5 years after finishing her treatments.

2. Case

A 60-year-old patient, gravida 4 para 3, was first seen in May 2014 for a recent history of pelvic pressure and pain. She reported two episodes of post-menopausal bleeding in the preceding four months. She had reached menopause twenty years prior and stopped using combined hormone replacement therapy two years before the onset of her symptoms. Her BMI was 31.1. Her most recent cervical cytology (two years prior to presentation) was normal. She had no history of smoking nor any family history of gynecological cancers or Lynch syndrome. A transvaginal ultrasound showed a heterogeneous uterus with significant nodularity of the uterine parenchyma, 1.1 cm endometrial thickness, no

adnexal masses, and a small volume of free fluid in the pelvis.

An endometrial biopsy revealed small cell carcinoma mixed with an endometrioid adenocarcinoma. The small cell carcinoma component was comprised of sheets of tumor cells with small to intermediate-sized cells and nuclear molding. The high grade endometrioid carcinoma component was comprised of malignant glands admixed with areas of solid growth pattern. The adenocarcinoma cells were positive for Vimentin and negative for CEA. The small cell carcinoma component was positive for the neuroendocrine markers CD56 and Synaptophysin. Neither component was positive for p63.

Further work-up included a CT scan of the chest, abdomen and pelvis which revealed enlarged pelvic and para-aortic lymphadenopathy, with lymph nodes measuring up to 2 cm. The uterus was described as bulky and distorted by multiple soft tissue nodules. Bladder invasion was suspected. Tumor marker CA-125 was within normal limits.

In June 2014, the patient underwent a total abdominal hysterectomy with bilateral salpingo-oophorectomy, bilateral pelvic lymph node dissection, omentectomy and removal of tumor on the bladder. The patient was suboptimally debulked, due to fixed bilateral pelvic lymph nodes measuring up to 5 cm.

The surgical pathology revealed a mixed small cell carcinoma (Fig. 1) and endometrioid carcinoma (Fig. 2) in a background of complex hyperplasia with atypia. There was invasion to the serosal surface and involvement of the left ovary and bladder. The cervix was uninvolved. There was one positive pelvic lymph node. Pelvic washings were positive. On histology, the tumor was composed approximately of 25% of small cell carcinoma component and 75% of endometrioid carcinoma. The latter was characterized by carcinoma with neuroendocrine features demonstrating high nuclear-cytoplasmic ratio, marked hyperchromasia and coarse granular chromatin. Tumor cells in the small cell carcinoma component were positive for CD56,

* Corresponding author at: 665 William Ave, Winnipeg, MB R3E 0L8, Canada.
E-mail address: aaltman@cancercare.mb.ca (A.D. Altman).

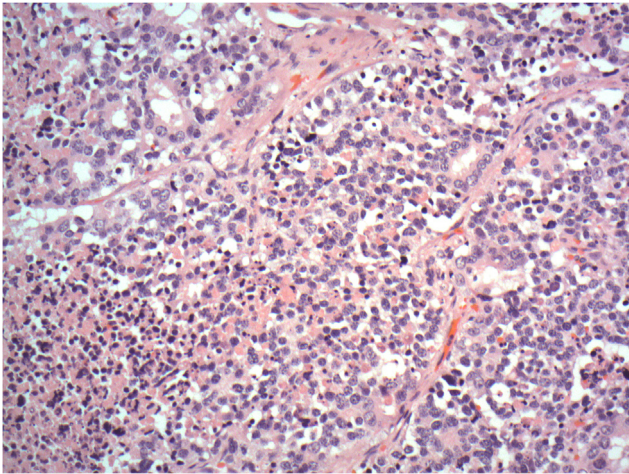


Fig. 1. Small cell carcinoma (Magnification 20×).

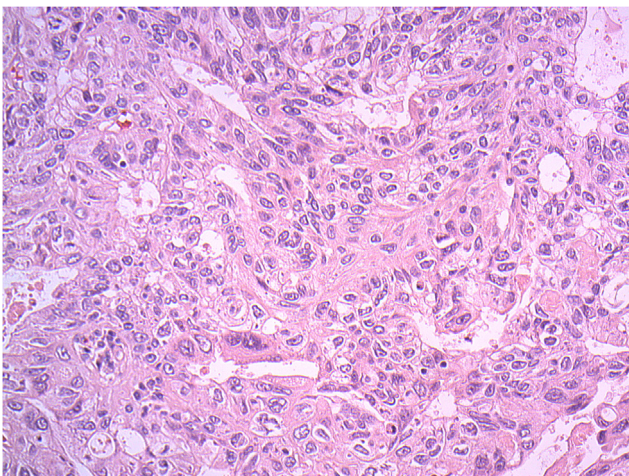


Fig. 2. High grade endometrioid carcinoma (Magnification 20×).

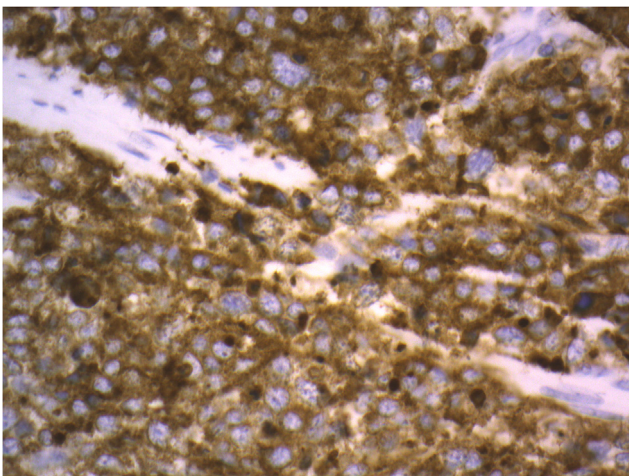


Fig. 3. Synaptophysin stain in the small cell carcinoma (Magnification 40×).

synaptophysin (Fig. 3) and pancytokeratin while being negative for chromogranin and CEA. There was extensive LVSI.

The post-operative course was complicated by a superficial wound infection and fluid overload corrected with furosemide. The patient received adjuvant chemotherapy with cisplatin at 20 mg/m² and etoposide at 100 mg/m² days 1 to 5 for five cycles of 21 days. Filgrastim,

treatment delays, and etoposide dose reductions were required to manage her neutropenia. The sixth cycle was cancelled due to hearing loss diagnosed with audiometry and grade 3 peripheral neuropathy. During her chemotherapy treatments, she was diagnosed with bilateral gonadal vein thrombosis and was successfully treated with therapeutic subcutaneous dalteparin for 6 months. Following completion of chemotherapy treatments, she received adjuvant external beam radiation therapy for a total of 4500 cGy in 25 fractions delivered by 3-dimensional conformal 4-field box technique. The Clinical Target Volume included the paraaortic lymph nodes region up to T11-T12 junction, bilateral common iliac, bilateral external and internal iliac, presacral, hypogastric lymph nodes regions as well as uterine bed.

The patient developed chronic radiation enteritis and episodes of small bowel bacterial overgrowth that were addressed medically. She is still followed-up at the gynecologic oncology clinic and has no evidence of disease 5 years after completion of her treatments.

3. Discussion

The proposed diagnostic criteria for small cell carcinoma of the endometrium are: (1) unequivocal evidence of endometrial origin, (2) dense, sheet-like growth of morphologically similar small to intermediate-sized tumor cells, with or without focal areas of spindle-shaped cells and irrespective of the presence/absence of other malignant subtypes, and (3) immunohistochemical reactivity for at least one neuroendocrine marker (van Hoesen, 1995). This case meets these criteria, with histological structure consistent with small cell carcinoma and positive reactivity to CD56 and synaptophysin.

Ninety four cases of small cell carcinoma of the endometrium in thirty one publications were found by reviewing the English-language literature since 1982. Among these, twenty three cases were FIGO stage IV disease at presentation. For most of these cases, the patients died of disease or follow-up or outcome information was unavailable (van Hoesen, 1995; D'Antonio, 2016; Huntsman, 1994; Meirmanov, 2003; Ureyen, 2013). Of those with known outcomes, mean and median survival were 10.6 and 8 months respectively, and all patients succumbed to their disease within 12 months with the notable exception of one patient who died at 36 months of respiratory failure in the setting of lung metastases (van Hoesen, 1995; D'Antonio, 2016; Huntsman, 1994; Meirmanov, 2003; Ureyen, 2013; Sato, 2010). Our case is the first reported case of a patient with stage IV disease who has survived for 5 years post-operatively without evidence of ongoing disease or recurrence, even with a suboptimal debulking.

There has been considerable variation in the reported treatments received by patients with this condition, with essentially all reported cases receiving surgery and the majority also receiving chemotherapy (in various combinations and durations) and/or radiation therapy. (Matsumoto, 2019) Our patient was treated with 5 cycles of adjuvant cisplatin and etoposide and subsequent adjuvant radiation therapy to the pelvis and para-aortic areas as described above. Among the available literature, there were only three publications which described cases of advanced (FIGO stage III or IV) endometrial small cell carcinoma on presentation remaining disease-free at > 12 months follow-up, but no clear pattern of treatment can be derived from these to account for such success (Matsumoto, 2011; Ureyen, 2013; Olson et al., 1982). The treatments presented in these cases were: (a) carboplatin/paclitaxel for 6 cycles of 21 days followed by irinotecan for 3 cycles, then presacral/aortic radiotherapy, and lastly by 3 cycles of docetaxel and gemcitabine (Matsumoto, 2011), (b) pelvic radiotherapy followed by cisplatin and adriamycin (Ureyen, 2013), and (c) 2 doses of adriamycin and cyclophosphamide (Olson et al., 1982). There is a similar degree of diversity in the reported literature regarding the treatment of less-advanced disease (FIGO stage I or II). While the relative paucity of cases proves a challenge, further data will be necessary to guide clinicians in developing treatment strategies for patients presenting with this rare but aggressive malignancy.

This case is unique for having a long follow-up period without recurrence despite that this highly aggressive disease presented at an advanced stage and unfortunately underwent suboptimal debulking. It suggests that multimodal treatment may cure this disease in rare cases. It is, however, not possible to conclude that the regimen used is superior to other combined chemotherapy regimens for patients presenting with small cell carcinoma of the endometrium, as this would have to be tested in a trial which is unlikely to happen considering the rarity of this disease.

4. Consent

Written informed consent was obtained from the patient for publication of this case report and accompanying images. A copy of the written consent is available for review by the Editor-in-Chief of this journal on request.

CRediT authorship contribution statement

M. Viau: Conceptualization, Data curation, Resources, Writing - original draft, Writing - review & editing. **I. Baragar:** Conceptualization, Data curation, Resources, Writing - original draft, Writing - review & editing. **A.D. Altman:** Conceptualization, Project administration, Supervision, Writing - review & editing.

Declaration of Competing Interest

The authors declared that there is no conflict of interest.

References

- D'Antonio, A., et al., 2016. Small cell neuroendocrine carcinoma of the endometrium with pulmonary metastasis: A clinicopathologic study of a case and a brief review of the literature. *Ann. Med. Surg. (Lond.)* 5, 114–117.
- Huntsman, D.G., et al., 1994. Small-cell carcinoma of the endometrium. A clinicopathological study of sixteen cases. *Am. J. Surg. Pathol.* 18 (4), 364–375.
- Katahira, A., et al., 2004. Small cell carcinoma of the endometrium: report of three cases and literature review. *Int. J. Gynecol. Cancer* 14 (5), 1018–1023.
- Matsumoto, H., et al., 2011. Small cell carcinoma of the endometrium: a report of two cases. *J. Obstet. Gynaecol. Res.* 37 (11), 1739–1743.
- Matsumoto, H., et al., 2019. Clinicopathologic features, treatment, prognosis and prognostic factors of neuroendocrine carcinoma of the endometrium: a retrospective analysis of 42 cases from the Kansai Clinical Oncology Group/Intergroup study in Japan. *J. Gynecol. Oncol.* 30 (6), e103.
- Meirmanov, S., et al., 2003. Small cell carcinoma of the endometrium: report of a case with analysis of Wnt/beta-catenin pathway. *Pathol. Res. Pract.* 199 (8), 551–558.
- Olson, N., Twiggs, L., Sibley, R., 1982. Small-cell carcinoma of the endometrium: light microscopic and ultrastructural study of a case. *Cancer* 50 (4), 760–765.
- Sato, H., et al., 2010. Small-cell carcinoma of the endometrium presenting as Cushing's syndrome. *Endocr. J.* 57 (1), 31–38.
- Ureyen, I., et al., 2013. Small cell carcinoma of the endometrium: A report of three cases. *J. Turk. Ger. Gynecol. Assoc.* 14 (2), 113–115.
- van Hoesen, K.H., et al., 1995. Small cell neuroendocrine carcinoma of the endometrium. *Int. J. Gynecol. Pathol.* 14 (1), 21–29.
- Walenkamp, A.M., Sonke, G.S., Sleijfer, D.T., 2009. Clinical and therapeutic aspects of extrapulmonary small cell carcinoma. *Cancer Treat. Rev.* 35 (3), 228–236.