

Role of nano curcumin on superoxide dismutase levels in leukoplakia

Sunanda Deb¹, Deepak Bhargava¹, Puja Bansal¹, Vijay Kanuru²

¹Department of Oral and Maxillofacial Pathology and Oral Microbiology, School of Dental Sciences, Sharda University, Greater Noida, Uttar Pradesh, ²Bio-Nano Scientist, Oncocur India Pvt. Ltd, Pune, Maharashtra, India

Abstract

Introduction: Oral leukoplakia has an estimated prevalence of 2% of the oral cavity, one of the risk factors for oral cancers. The most commonly linked etiology being tobacco smoking causing reactive oxygen species (ROS) induced DNA damage. Curcumin, a polyphenol derivative from herbal remedy, possesses diverse properties ranging from centuries old documented anti-inflammatory properties to recently documented anticancer properties.

Aims: Role of nano curcumin on superoxide dismutase (SOD) levels in leukoplakia patients' pre- and post-treatment

Materials and Methods: The study group comprised thirty test subjects. Single capsule of 250 mg (Brecan Plus) was given to the test group for 30 days with weekly follow-up. Blood samples were taken from the test group and were evaluated for SOD levels before and after the completion of the trial.

Results: In the study, there was a decrease in size of the lesion, number of lesions, down staging of the disease, and increase in serum SOD levels after the therapy. Binary logistic regression analysis was done to assess the predictive ability of serum SOD-dependent variable, and a positive association was noted between increase in serum SOD level and down staging of the disease.

Conclusion: Nano curcumin is an excellent medical nutrition intervention derived from traditional natural products. The study has demonstrated the clinical efficacy of these new classes of therapeutic nutraceuticals such as nanocurcumin in treating oral leukoplakia, which are suitable for long-term use.

Keywords: Curcumin, leukoplakia, superoxide dismutase

Address for correspondence: Dr. Sunanda Deb, Department of Oral and Maxillofacial Pathology and Oral Microbiology, School of Dental Sciences, Sharda University, Knowledge Park-III, Greater Noida, Gautam Budh Nagar-201 308, Uttar Pradesh, India.
E-mail: debsuchanda16@gmail.com

Submitted: 01-Aug-2021, **Accepted:** 16-Aug-2021, **Published:** 31-Mar-2022

INTRODUCTION

The sixth most prevalent human malignancy is oral carcinoma.^[1] The WHO confines the definition as "A clinical diagnosis of leukoplakia depends on the experience of the clinician." Most commonly etiology of leukoplakia is tobacco and smoking, causing reactive

oxygen species (ROS) induced DNA damage.^[2] This ROS-induced DNA damage is linked to alteration in the levels of superoxide dismutase (SOD).^[3] Either directly or through activation of inflammatory cascade, ROS is proposed to play a key role both as initiator and promoter in carcinogenesis.^[4] This can in turn provide a substantial

This is an open access journal, and articles are distributed under the terms of the Creative Commons Attribution-NonCommercial-ShareAlike 4.0 License, which allows others to remix, tweak, and build upon the work non-commercially, as long as appropriate credit is given and the new creations are licensed under the identical terms.

For reprints contact: WKHLRPMedknow_reprints@wolterskluwer.com

How to cite this article: Deb S, Bhargava D, Bansal P, Kanuru V. Role of nano curcumin on superoxide dismutase levels in leukoplakia. J Oral Maxillofac Pathol 2022;26:21-5.

Access this article online

Quick Response Code:



Website:

www.jomfp.in

DOI:

10.4103/jomfp.JOMFP_267_21

foundation for the assessment of leukoplakia, especially with respect to the treatment and its resolution. However, in spite of various treatment modalities available – surgical as well as nonsurgical methods, none have gained an universal approval.^[5] Zhang *et al.* reported that there was significant morbidity after surgical excision of leukoplakia.^[6] A significant development toward conservative management was made with the introduction of curcumin. Curcumin, a polyphenol derivative from herbal remedy, possesses diverse properties ranging from centuries old documented anti-inflammatory properties to recently documented anticancer properties.^[7] Curcumin has already been used in treatment and chemoprevention of various gastrointestinal tumors particularly colon cancers. Moreover, it has become relevant for leukoplakia as the curcumin can have a local pharmacological action on the lesion in the form of tablet apart from the systemic action of the drug. The present study has been conducted to evaluate changes in oxidant/antioxidant ratio of leukoplakia patients before and after nanocurcumin therapy using serum levels of SOD and the role of nanocurcumin as a treatment modality for leukoplakia. This was evaluated using serum SOD level in patients of leukoplakia before inception of treatment with nanocurcumin and its level in subsequent follow-up after 1 month of therapy.^[8]

Aim and objectives

Aim

Role of nanocurcumin on SOD levels in leukoplakia patients' pre and posttreatment.

Objectives

- To evaluate changes in oxidant/antioxidant ratio of leukoplakia patients before and after nanocurcumin therapy using serum levels of SOD
- To assess clinical changes in leukoplakia patients following nanocurcumin therapy
- To evaluate the role of nanocurcumin as a treatment modality for leukoplakia.

MATERIALS AND METHODS

The study was aimed to evaluate serum levels of SOD in leukoplakia patients before and after completing a 1-month regimen of *Curcuma longa*. Patients reported to the Department of Oral Maxillofacial Pathology and Microbiology, Department of Oral Medicine and Radiology, Department of Public Health Dentistry, some sourced from camps organized by the Department of Public Health Dentistry. All investigations were carried out at the Department of Oral Maxillofacial Pathology and Microbiology.

The medicine nanocurcuminoids prescribed in the study were provided by Oncocur India Pvt. Ltd.

The study group comprised 30 test subjects. Single capsule of 250 mg (Brecan Plus) was given to the test group for 30 days with weekly follow-up. Blood samples were taken from the test group and were evaluated for SOD levels before and after the completion of the trial.

Informed consent was obtained from all the participants. Ethical approval for the study was obtained from the Institutional Ethical Committee on 30/11/2018 with reference number SU/SMSandR/76-A/2018/148.

Inclusion criteria

1. Clinically diagnosed cases of leukoplakia
2. Age group: 18–65 years
3. Cooperative patients ready to sign the consent form.

Exclusion criteria

1. Other potentially malignant disorder
2. Patients with any systemic disease such as renal, cardiovascular, hepatic, or hematological
3. Patients with erythroleukoplakia.

Methodology

The study group comprised thirty test subjects. Single capsule of 250 mg (Brecan Plus) was given to the test group for 30 days with weekly follow-up. Paired t-test was used to compare the patients pre and post therapy with nanocurcumin.

Lab investigation

Patients' blood was retrieved and centrifuged (3000 revolutions/min at 4°C for 10 min). After that, serum separated from the blood. The serum was then siphoned off, and erythrocytes were washed and analyzed.

RESULTS

The present study comprised thirty patients who underwent treatment with curcumin-based therapy (nanocurcumin) and were followed up every week for a period of 1 month.

Figure 1 shows a considerable decrease in lesion size after the therapy. Figure 2 show the distribution of patients according to the size of lesion pre-therapy and post-therapy. There was a statistically significant decrease in size of the lesion posttherapy ($P < 0.0001$) with a compared mean size of $1.32 \pm 0.88 \text{ cm}^2$

Figure 3 show the distribution of patients according to the serum SOD levels (in U/ml) pre- and post-therapy. There

was a statistically significant increase in serum SOD level posttherapy ($P < 0.0001$).

A binary logistic regression analysis was done to assess the predictive ability of serum SOD level to correctly predict the outcome of the therapy. Improvement in stage (down staging) was taken as a dependent variable against serum SOD levels pre- and post-therapy which were taken as in. Positive association was noted between

posttherapy increase in serum SOD levels and the down staging of the disease. With an odds ratio of 10%, the increase in posttherapy serum SOD level was accurate in predicting the improvement in the outcome of the therapy.

DISCUSSION

There was a constellation of observations and results validating and reinforcing the role of nanocurcumin in oral leukoplakia.

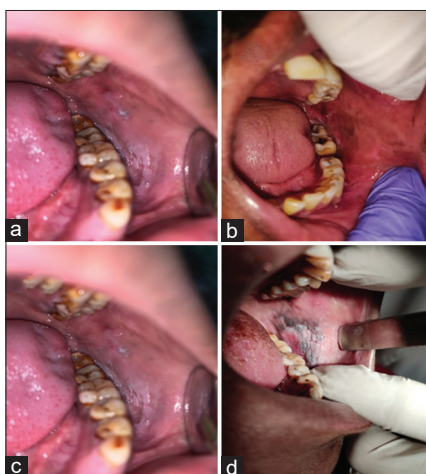


Figure 1: Patient 1: (a) Pretreatment, (b) Posttreatment and Patient 2: (c) Pretreatment, (d) Posttreatment

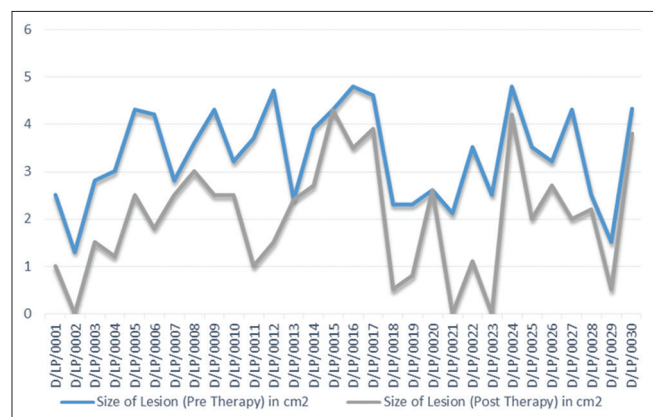


Figure 2: Line graph showing patients group distribution according to the size of lesion pre- and post-therapy

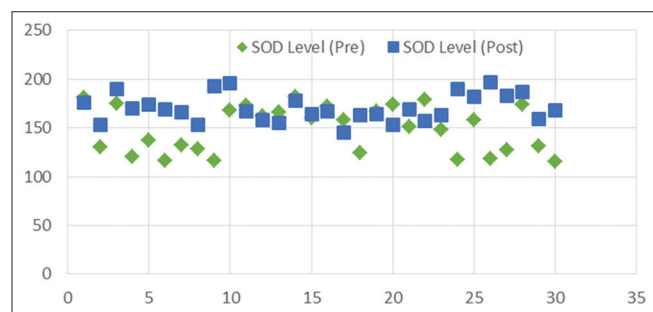


Figure 3: Scatter plot showing the distribution of patients according to the serum SOD levels (in U/ml) pre- and post-therapy

Table 1: Patients group distribution according to age

Age of patients (years)	Number of patients (%)
≤30	10 (33.3)
31-40	8 (26.6)
41-50	3 (10)
>50	9 (30)

Table 2: Distribution of patients according to the size of lesion pretherapy and posttherapy

Size of lesion pretherapy (cm ²)	Mean±SD	Size of lesion posttherapy (cm ²)	95% CI		P (two tailed)
			Lower bound	Upper bound	
3.33±1.00		2.01±1.24	0.99	1.65	<0.0001*

*Statistically significant. CI: Confidence interval, SD: Standard deviation

Table 3: Patients group according to the number of lesions pretherapy and posttherapy

Pretherapy	Mean±SD	Posttherapy	95% CI		P (two tailed)
			Lower bound	Upper bound	
1.33±0.61		1.03±0.49	0.10	0.50	0.005*

*Statistically significant. CI: Confidence interval, SD: Standard deviation

Table 4: Oral leukoplakia (OLEP) classification and staging system

L-size of the leukoplakia	P - Pathology	Staging system
L1 - Size of single or multiple leukoplakias together <2 cm	P0 - No epithelial dysplasia	Stage I - L1P0
L2 - Size of single or multiple leukoplakias together 2-4 cm	P1 - Distinct epithelial dysplasia	Stage II - L2P0 or L1L2P1
L3 - Size of single or multiple leukoplakias together >4 cm	PX - Epithelial dysplasia not specified in the pathology report	Stage IV - L3P1
Lx - Size not specified		

Oral leukoplakia(OLEP) classification was followed for clinico-pathological staging of leukoplakia

Table 5: Based on oral leukoplakia staging of the disease pretherapy and posttherapy distribution of patients

Pretherapy	Mean±SD	Posttherapy	95% CI		P (two tailed)
			Lower bound	Upper bound	
2.30±0.47		1.53±0.68	0.55	0.98	<0.0001*

*Statistically significant. CI: Confidence interval, SD: Standard deviation

Table 6: According to the improvement in staging of the disease pretherapy and posttherapy

Improved after therapy	Not improved after therapy	P
22	8	<0.05*

*Statistically significant

Table 7: Distribution of patients according to the serum superoxide dismutase levels pretherapy and posttherapy

Mean±SD (U/ml)		95% CI		P (two tailed)
Pretherapy	Posttherapy	Lower bound	Upper bound	
148.89±23.63	170.38±14.08	139.40	171.44	<0.0001*

*Statistically significant. CI: Confidence interval, SD: Standard deviation

Table 8: Binary logistic regression analysis

Serum SOD level (U/ml)	P	OR	95% CI	
			Lower bound	Upper bound
Pretherapy	0.65	0.99	0.96	1.03
Posttherapy	0.67	1.10	0.96	1.12

SOD: Superoxide dismutase, OR: Odds ratio, CI: Confidence interval

Demographics

Age

The onset of leukoplakia mostly seen in the middle-aged adults.^[9] Study by Gopinath *et al.* in 2016, most patients belonged to the age group of >50 years (50.7%), while those between 30 and 49 years constituted 41.4% of the cases and patients <30 years comprised a smaller fraction of 7.9% of the cases.^[10] Although this is the most common scenario, it sure is related to the exposure to risk factor with aging and the external environment. The patients' age group of the present study is summarized in Table 1. Most of the patients belonged to an age group of <30 years accounting for about 33.3% of the cases, still there was an increase in the number of cases as the age category approached individuals more than 50 years accounting for 30% of the cases. The fact that the present study had more patients belonging to the age group of <30 years could be attributed to the small sample size.

Gender

Most studies shown that a strong male predominance in different parts in India^[11] The present study, all the patients were male, which was a chance incidence and not by the study design. Alcohol, smoking, and betel nut chewing may be attributed to increased incidence in men. Small sample size can also be a contributing factor to this exception.

Size of the lesion

The mean size of the lesion pretherapy was $3.33 \pm 1.00 \text{ cm}^2$, while that after therapy was $2.01 \pm 1.24 \text{ cm}^2$, as shown in Table 2. This decrease in size was statistically significant ($P < 0.0001$). This is in concordance with the findings noted by Bhagat *et al.* in 2018 which they

noted that there was a reduction in size of the lesion from $4.34 \pm 2.13 \text{ cm}^2$ pretherapy to $2.12 \pm 1.55 \text{ cm}^2$ posttherapy.^[12] In another study by Kuttan *et al.*, decreased in size of lesion in 10% of the cases after therapy with curcumin-based topical ointment.^[11] However, in the present study, reduction in size was noted in almost 93.3% of cases with varying extent of response; with a complete resolution of lesion noted in three patients (1%).

Number of lesions

From Table 3, it can be seen that there was a considerable decrease in the number of the lesion after the therapy. The mean number of the lesion's pretherapy was 1.33 ± 0.61 , while that after therapy was 1.03 ± 0.49 . This decrease in the number of lesions was statistically significant ($P < 0.005$).^[11]

Oral leukoplakia (OLEP) Staging

The OLEP staging in Table 4 was used for assessing the downstaging of the disease. From Table 5, it has been observed that statistically, there is a significant improvement in the staging of disease after therapy ($P < 0.0001$). This study has used a clinical as well as a histopathological criterion in the form of OLEP staging for assessing a therapeutic response, which has not been done by any study. The criteria for clinical response (size and number of the lesion) are in concordance with the findings of the Rai *et al.*, with a $P < 0.05$ as shown in Table 6.^[13] In another study done by Gupta *et al.*, response of curcumin was assessed on the basis of histopathological response, which concluded an improvement in histology after therapy.^[14]

Serum superoxide dismutase level

Curcumin has antioxidant property mainly presence of antioxidant enzymes such as SOD and glutathione peroxidase.^[15] In this study, the serum level of SOD was evaluated pre- and post-therapy to draw a comparison between the supplementation of nanocurcumin and the down staging/resolution of the disease, and results are reported in Table 7. There was an increase in the serum SOD level from $148.89 \pm 23.63 \text{ U/ml}$ pretherapy to $170.38 \pm 14.08 \text{ U/ml}$ posttherapy, which was statistically significant ($P < 0.0001$). This is in concordance with the findings of Rai *et al.*, who concluded similar results in the reviews of many previously concluded studies.^[16]

Predictive ability of serum superoxide level

In this study, a novel method was employed to assess the predictive ability of serum SOD level in correctly predicting the outcome of the therapy. Binary logistic retrogradation analysis was done to evaluate predictive ability serum. SOD level to correctly predict the outcome of the therapy, and

summarized in Table 8. Positive association was noted between posttherapy increase in serum SOD levels and the down staging of the disease. With an odds ratio of 10%, the increase in posttherapy serum SOD level was accurate in predicting the improvement in the outcome of the therapy.

CONCLUSION

This study concluded that there was an increase in the serum SOD level as well as development in OLEP classification in leukoplakia given after nanocurcumin therapy with a single capsule of 250 mg (Breacan Plus) which was given to the patients for 30 days with weekly follow-up. Nanocurcumin is easily accessible and patient compliant treatment which can be used for the conservative management of oral leukoplakia.

Future scope of study

The study has demonstrated the clinical efficacy of these new classes of therapeutic nutraceuticals such as nanocurcumin in treating oral leukoplakia, which are suitable for long-term use. Multispecific nanonutripharmaceuticals such as nanocurcumin herald a new era in clinical care, which will be examined further for numerous conditions of oral conditions.

Financial support and sponsorship

This study was financially supported by Oncocur India Pvt. Ltd.

Conflicts of interest

There are no conflicts of interest.

REFERENCES

1. Warnakulasuriya S. Global epidemiology of oral and oropharyngeal

2. cancer. *Oral Oncol* 2009;45:309-16.
2. Ziech D, Franco R, Pappa A, Panayiotidis MI. Reactive oxygen species (ROS)--induced genetic and epigenetic alterations in human carcinogenesis. *Mutat Res* 2011;711:167-73.
3. Srivastava KC, Austin RD, Shrivastava D, Pranavadhyan G. Oxidant-antioxidant status in tissue samples of oral leukoplakia. *Dent Res J (Isfahan)* 2014;11:180-6.
4. Kovacic P, Jacintho JD. Mechanisms of carcinogenesis: Focus on oxidative stress and electron transfer. *Curr Med Chem* 2001;8:773-96.
5. Holmstrup P, Dabelsteen E. Oral leukoplakia-to treat or not to treat. *Oral Dis* 2016;22:494-7.
6. Zhang L, Poh CF, Lam WL, Epstein JB, Cheng X, Zhang X, *et al.* Impact of localized treatment in reducing risk of progression of low-grade oral dysplasia: Molecular evidence of incomplete resection. *Oral Oncol* 2001;37:505-12.
7. Park W, Amin AR, Chen ZG, Shin DM. New perspectives of curcumin in cancer prevention. *Cancer Prev Res (Phila)* 2013;6:387-400.
8. Aggarwal BB, Sung B. Pharmacological basis for the role of curcumin in chronic diseases: An age-old spice with modern targets. *Trends Pharmacol Sci* 2009;30:85-94.
9. Rajendran R. Oral leukoplakia (leukokeratosis): Compilation of facts and figures. *J Oral Maxillofacial Pathol* 2004;8:58.
10. Gopinath D, Thannikunnath BV, Neermunda SF. Prevalence of carcinomatous foci in oral leukoplakia: A clinicopathologic study of 546 Indian samples. *J Clin Diagn Res* 2016;10:C78-83.
11. Kuttan R, Sudheeran PC, Josph CD. Turmeric and curcumin as topical agents in cancer therapy. *Tumori* 1987;73:29-31.
12. Bhagat V, Arora P, Ranjan V, Rastogi T. Efficacy of curcumin in the treatment of oral leukoplakia- A prospective study. *Int J Curr Med Pharm Res* 2018;412:3959-62.
13. Rai B, Kaur J, Jacobs R, Singh J. Possible action mechanism for curcumin in pre-cancerous lesions based on serum and salivary markers of oxidative stress. *J Oral Sci* 2010;52:251-6.
14. Gupta SC, Patchva S, Aggarwal BB. Therapeutic roles of curcumin: Lessons learned from clinical trials. *AAPS J* 2013;15:195-218.
15. Nawaz A. Curcumin: A natural product of biological importance. *Gomal Univ J Res* 2011;27:7-14.
16. Rai M, Pandit R, Gaikwad S, Yadav A, Gade A. Potential applications of curcumin and curcumin nanoparticles: From traditional therapeutics to modern nanomedicine. *Nanotechnol Rev* 2015;4:161-72.