

Case Report

Bilateral costal cartilage fractures sustained in the gym during repeated bench press exercises

Yattheesh Thanalingam^{a,*}, Ahmed O.A. Krim^b, Nand Kejriwal^{a,c}^a Faculty of Medical and Health Sciences, The University of Auckland, Auckland, New Zealand^b Department of Radiology, Waikato Hospital, Waikato, New Zealand^c Department of Cardiothoracic Surgery, Waikato Hospital, Waikato, New Zealand

ARTICLE INFO

Keywords:

Costal cartilage fracture
 Costochondral injury
 Blunt chest trauma
 Bench press exercises

ABSTRACT

Costal cartilage fractures are common in high-energy blunt chest trauma but are frequently missed on imaging evaluation and accordingly underreported in the literature. In this report, we describe a case of a 32-year-old male who sustained bilateral costal cartilage fractures following repeated blunt trauma in the gym sustained during bench press exercises. The patient presented with a painful “clicking” of a rib in and out of place while bending or turning sideways. Initial chest X-ray and computed tomography (CT) imaging were reported negative for fractures; however, a closer inspection of the CT image revealed bilateral costal cartilage fractures. As the patient’s symptoms improved over time, a conservative approach to treatment with regular analgesia and advice to avoid external impact on the fracture sites was adopted. This unique case highlights an unusual mode of trauma and diagnostic complexity of costal cartilage fractures.

Introduction

Costal cartilage fractures are commonly due to high energy trauma secondary to contact sports injuries, falls, or motor vehicle accidents [1]. Clinically manifesting as late as weeks to months after acute trauma, these fractures result in rib cage instability [2]. In the absence of irregular ossification foci, costal cartilage fractures remain inconspicuous on chest radiographs due to the inadequate depiction and low radiopacity. This often necessitates imaging via computed tomography (CT), magnetic resonance imaging (MRI) or ultrasonography to diagnose and guide management [3]. We report a case of bilateral costal cartilage fractures due to repeated blunt trauma sustained in the gym.

A 32-year-old accountant presented with complaints of persistent left lower anterior chest wall pain of four month duration despite regular analgesia. He described painful “clicking” or “popping” of a rib in and out of place while bending or turning sideways. Otherwise, he is a fit gentleman who frequents the gym five times a week. The patient could not recall any history of trauma.

On examination, there was no definite tender spot over the anterior ends of the sixth or seventh ribs where the pain was most prominent, and it was difficult to elicit the hooking manoeuvre. Chest radiography showed no rib fracture or aggressive osseous lesions. Repeated ECG, D-dimer and troponin were all within normal values. The patient believed that the chest pain was due to myocarditis or costochondritis secondary to the COVID vaccine. The surgeon explained that while chest pain following COVID vaccination due to myocarditis was not uncommon, normal ECG and troponin results suggested an alternative cause to his chest wall pain.

* Corresponding author at: Faculty of Medical and Health Sciences, The University of Auckland, Auckland, New Zealand.
 E-mail address: ytha765@aucklanduni.ac.nz (Y. Thanalingam).

The CT scan was initially reported normal. However, a closer inspection of the scan by the radiologist following a request from the surgeon focussing on the area of interest revealed a transverse fracture of the costal cartilage junction of the left sixth rib, which corresponded to the site of most intense pain. Interestingly, there were two additional fractures, one at the costal cartilage junction and the other in the mid cartilage of the right sixth rib (Fig. 1). There were no other rib fractures. When the patient was informed about the findings, he recollected that there was always an impact on the lower part of the chest while he carried out bench press exercises at the gym. The patient recreated the scenario in the clinic, and it became evident that the blunt trauma from the exercise bar was the most likely explanation for the symmetrical bilateral costal cartilage fractures.

Given that the patient's pain had started to ease, a conservative approach was adopted with advice to avoid external impact on the fracture sites. Specific return advice and reevaluation was also provided should the pain worsen or impacted the patient's quality of life.

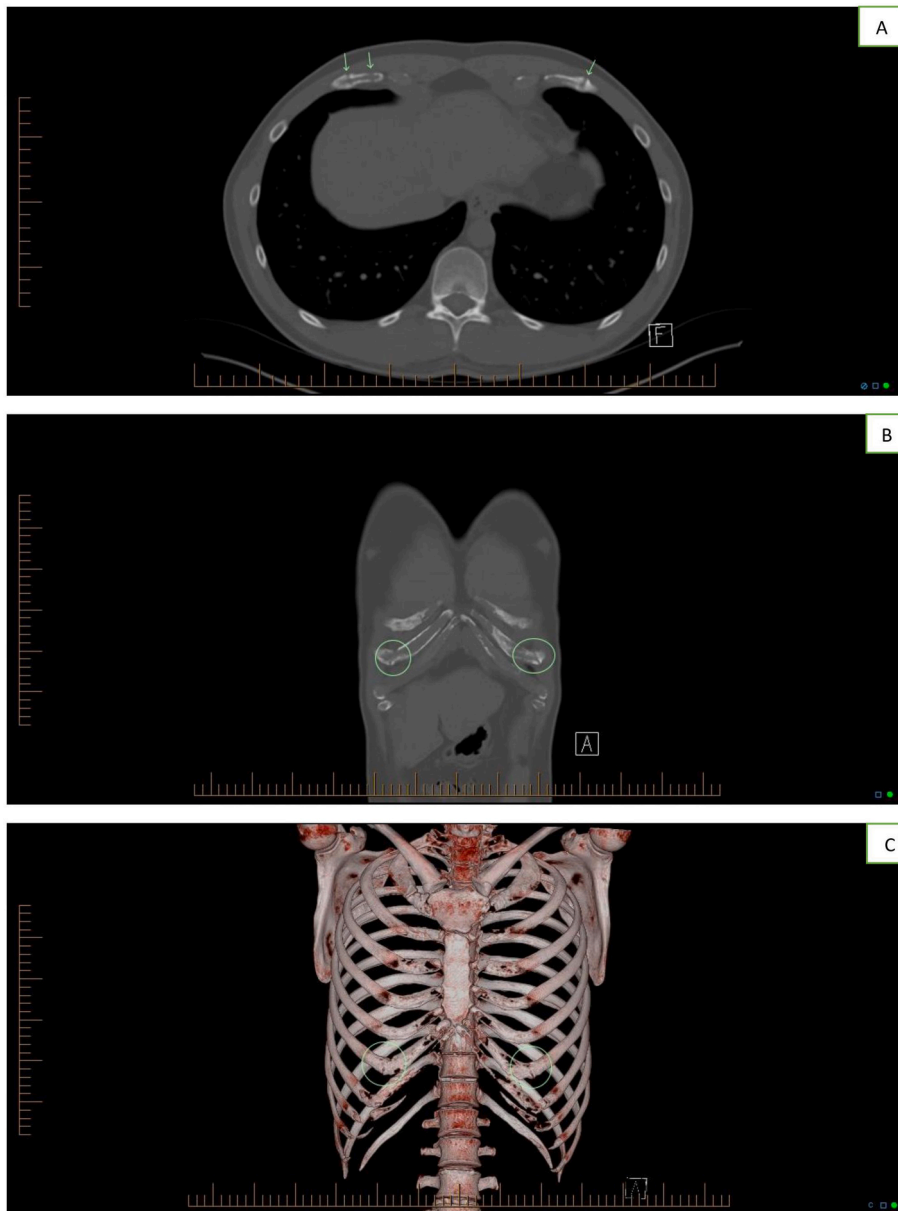


Fig. 1. A. Axial image, B. Coronal image and C. 3D image of the CT chest demonstrate bilateral costal cartilage fractures, one transverse fracture at costal cartilage junction of the left sixth rib, two fractures at the costal cartilage junction and in the mid-cartilage of the right sixth rib (Straight arrows and circles).

Discussion

The costal cartilages of the seventh, first or sixth rib are most prone to fracture, with high energy blunt chest trauma accounting for majority of costal cartilage fractures [1]. Due to the high energy nature of the trauma, other injuries that may present with costal cartilage fractures include multiple rib fractures, sternal fractures, pneumothorax, aortic injuries and hepatic injuries. Depending on the site of injury, costal cartilage fractures can be further categorised as either midchondral, costochondral or chondrosternal. While the fracture of costal cartilages of the immobile first and second ribs are due to twisting injuries (e.g. wrestling), the fractures of the costal cartilage of the lower ribs are due to direct trauma, as seen in our patient [4].

The displacement or instability resulting from the costal cartilage fractures may result in the patient experiencing severe chest pain, dyspnoea, chronic cough or paradoxical chest wall motion [2]. Upon initial presentation, our patient experienced anterior chest wall pain that was worst with rotational movements, with no other symptoms. Unlike osseous rib fractures, costal cartilage fractures cannot be detected by chest radiography unless there is a strong calcification of the involved cartilage. Interestingly, a retrospective analysis of 1461 trauma patients revealed that costal cartilage fractures were detected on initial CT imaging in only 39 % of patients [1]. This was also the case with our patient, where the scan was initially reported normal.

Given costal cartilage fractures are underreported in the literature, there is currently no consensus regarding management. The only indication for surgical intervention will be persistent pain that interfered with the patient's quality of life. Excising a segment of the cartilage, including the fractured ends will alleviate the pain, as the two ends are prevented from rubbing against each other. Stabilising the fractures with a plate is another option. However, identifying the exact location of the fractures as well as selection of the best structure to affix the plate make this a challenging procedure that is likely to produce uncertain results [5,6]. As our patient's pain had improved, the patient was managed conservatively with analgesia with specific return advice. Interestingly, an animal study reported that costal cartilage fractures in mice were well healed within 2 months. The study highlighted the importance of an intact perichondrial layer which is a key source cells which contribute to regeneration of the cartilage [7].

To our knowledge, this is the first case report in the literature describing bilateral costal cartilage fractures due to repeated blunt trauma sustained in the gym during bench press exercise. This report highlights the importance of laying emphasis on proper technique while carrying out bench press exercises in the gym to avoid direct impact on the chest wall. It is imperative to have a close collaboration between the treating surgeon and the radiologist to clinch the diagnosis.

Patient consent

Appropriate written informed consent was obtained for publication of this case report and accompanying images.

Ethics approval and consent to participate

Written informed consent were obtained from the patients.

CRediT authorship contribution statement

YT, AK and NK were all involved in the conception, critical revision, and final approval of this article. YT drafted the initial version of the article.

Declaration of competing interest

There are no financial interests or conflicts of interests to declare.

Acknowledgements

N/A

References

- [1] M.T. Nummela, F.V. Bensch, T.T. Pyhälä, S.K. Koskinen, Incidence and imaging findings of costal cartilage fractures in patients with blunt chest trauma: a retrospective review of 1461 consecutive whole-body CT examinations for trauma, *Radiology* 286 (2) (2018 Feb) 696–704.
- [2] V. Lopez, R. Ma, X. Li, J. Steele, A.A. Allen, Costal cartilage fractures and disruptions in a rugby football player, *Clin. J. Sport Med.* 23 (3) (2013 May) 232–234.
- [3] J. Malghem, B.C. Vande Berg, F.E. Lecouvet, B.E. Maldague, Costal cartilage fractures as revealed on CT and sonography, *Am. J. Roentgenol.* 176 (2) (2001 Feb) 429–432.
- [4] S.L. Varada, C.A. Popkin, E.M. Hecht, C.S. Ahmad, W.N. Levine, M. Brown, et al., Athletic injuries of the thoracic cage, *RadioGraphics* 41 (2) (2021 Mar) E20–E39.
- [5] G.E. Sollender, T.W. White, F.M. Pieracci, Fracture of the costal cartilage: presentation, diagnosis, and management, *Ann. Thorac. Surg.* 107 (4) (2019 Apr) e267–e268.
- [6] Y. Li, Y. Zhao, Y. Yang, W. Wu, X. Guo, T. Zhao, Surgical treatment of costal cartilage fractures with titanium plate internal fixation, *J. Cardiothorac. Surg.* 17 (1) (2022 Dec) 57.
- [7] Z. Piao, M. Takahara, M. Harada, H. Orui, M. Otsuji, M. Takagi, et al., The response of costal cartilage to mechanical injury in mice, *Plast. Reconstr. Surg.* 119 (3) (2007 Mar) 830–836.