



Embolizing Massive Right Atrial Thrombus in a HIV-Infected Patient

Journal of Investigative Medicine High Impact Case Reports
Volume 6: 1–4
© 2018 American Federation for Medical Research
DOI: 10.1177/2324709618802871
journals.sagepub.com/home/hic


Piruthiviraj Natarajan, MD¹ , Fowrooz Joolhar, MD^{1,2},
Sudhagar Thangarasu, MD^{1,2} , Ayham Aboeed, MD^{1,2},
Theingi Tiffany Win, MD^{1,2}, and Everardo Cobos, MD¹

Abstract

The risk of thromboembolism is increased when associated with the human immunodeficiency viral (HIV) infection. Various factors are involved in promoting thrombosis, and the presence of a patent foramen ovale augments the potential for a paradoxical embolism. We describe the case of a 56-year-old man receiving antiretroviral therapy with features of right heart failure and pulmonary embolism. Due to the high incidence of life-threatening thromboembolism in the HIV-infected group, the need for long-term anticoagulation has to be evaluated.

Keywords

HIV, right atrial thrombus, embolization, patent foramen ovale, thromboembolism, pulmonary embolus

Introduction

The thrombotic risk is increased by 40% in people infected with human immunodeficiency virus (HIV).¹ The mortality risk with venous thromboembolism among the HIV-infected is high.² Abnormalities in various clotting factors and mechanisms can result in a prothrombotic milieu.³ Antiretroviral protease inhibitors were recognized to possibly affect the thrombotic factors synthesized in liver promoting thrombosis.⁴ Opportunistic infections like cytomegalovirus are associated with endothelial damage resulting in a hypercoagulable state.⁵

A patent foramen ovale (PFO) increases the risk of recurrent stroke, and the closure of the atrial septal defect is effective in reducing the stroke risk.⁶ The mortality rate of pulmonary embolism associated with right atrial (RA) thrombus is 44.7%.⁷ Surgical clot removal is reserved for eligible hemodynamically stable patients. The higher risk groups are managed better conservatively, considering the risks associated with the surgical procedure.^{8,9} Recently, ultrasound-accelerated rheolytic thrombectomy for impending paradoxical embolism successfully reduced the complications of thrombosis.^{10,11}

Case Presentation

A 56-year-old man, HIV serology positive for 8 years, presented to the emergency department with progressive worsening of shortness of breath for 2 days. He experienced shortness of breath for the past 6 months. He had bilateral leg swelling and orthopnea in the recent months. The latest cluster definition

(CD4) cells count was 804 cells/ μ L, and he received antiretroviral therapy Genvoya (elvitegravir/cobicistat/emtricitabine/tenofovir alafenamide). He was previously diagnosed with asthma and positive IgG (immunoglobulin G) serology for hepatitis C virus (HCV). He smoked a pack of cigarettes for 20 years and engaged in unprotected sexual acts with men.

On examination, the patient had jugular venous distension and tachypnoea with bilateral basal crackles heard on auscultation. He had bilateral pitting pedal edema (grade 2) reaching the bilateral tibial tuberosity.

His respiratory symptoms worsened despite the immediate resuscitation efforts at the emergency department, and he required a mechanical ventilator due to impending type 1 respiratory failure. The CD4 cell count at the time of admission was 467 cells/ μ L with the serum HIV-1 viral load of less than 20 copies/mL. The serum HCV RNA viral load by polymerase chain reaction assay was less than 15 IU/mL. Plain chest X-ray showed cardiomegaly and moderate diffuse pulmonary congestion. The brain natriuretic peptide level was 574 pg/mL on admission. The initial transesophageal echocardiogram showed signs of a dilated right ventricle, elevated pressures, and 2 large echodensities with one tethered to the

¹Kern Medical Center, Bakersfield, CA, USA

²UCLA-David Geffen School of Medicine, Los Angeles, CA, USA

Received April 2, 2018. Revised August 8, 2018. Accepted August 30, 2018.

Corresponding Author:

Piruthiviraj Natarajan, Kern Medical Center, 1700 Mt Vernon Avenue, Bakersfield, CA 93305-4144, USA.
Email: piruthiviraj@gmail.com



Creative Commons CC BY: This article is distributed under the terms of the Creative Commons Attribution 4.0 License

(<http://www.creativecommons.org/licenses/by/4.0/>) which permits any use, reproduction and distribution of the work without further permission provided the original work is attributed as specified on the SAGE and Open Access pages (<https://us.sagepub.com/en-us/nam/open-access-at-sage>).

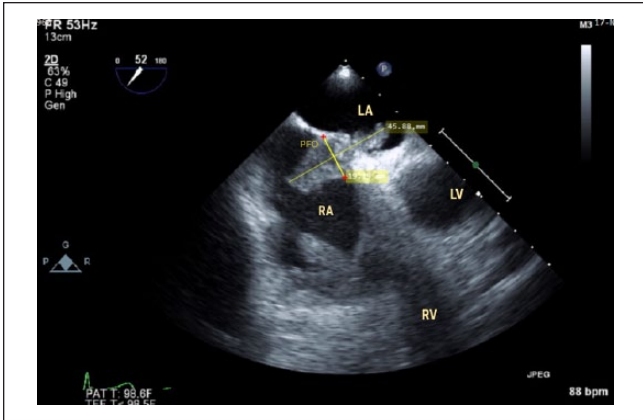


Figure 1. Interatrial thrombus at the time of admission.

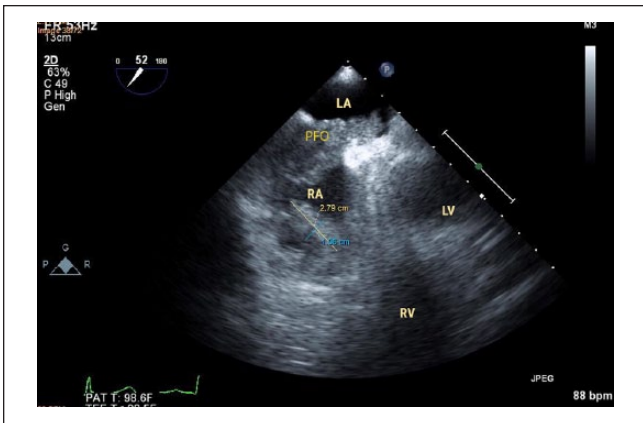


Figure 2. Interatrial thrombus reduced in size after embolization.

PFO (Figure 1) and another to the tricuspid valve (Figure 2), which suggested RA thrombus. The left ventricular ejection fraction was around 60% with grade 1 diastolic dysfunction associated with a compromised left ventricular size due to the enlarged right ventricle. The interventricular septum showed dyskinesia, secondary to elevated right ventricular pressure and volume. A large complex thrombus with mobile lobulations was found attached to the base of the tricuspid valve with 27.9×10.8 mm dimensions. The second thrombus, with complex features, measuring 45.8×19.1 mm, had crossed the PFO and protruded into the left atrium. The protruded freely mobile, small linear segment of the echo density measured 10×3 mm on the left atrial side. He received low-molecular-weight heparin (enoxaparin) 1 mg/kg to prevent further thrombosis. The qualitative cardiac troponin-I enzyme report was negative. Computed tomography of pulmonary angiogram revealed an eccentric nonocclusive thrombus in the proximal left lower lobar artery and bilateral embolization in the segmental arteries associated with consolidation in the left lower lobe with minimal pleural effusion. Venous ultrasonogram showed no deep vein thrombosis.

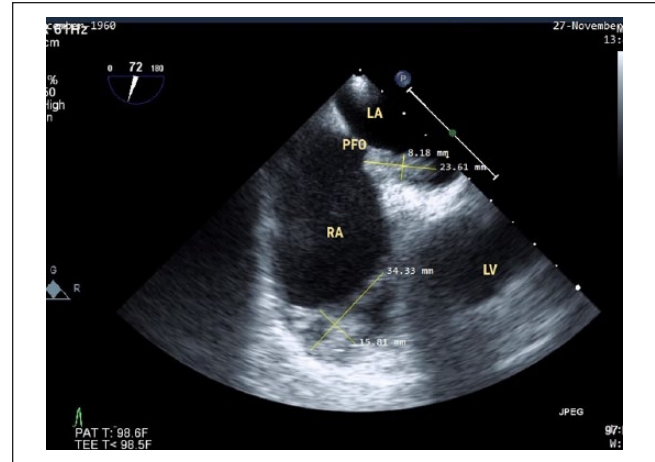


Figure 3. Thrombus tethered to the right tricuspid valve.

Transesophageal echocardiogram on the 13th day of admission showed a decreased size of the RA thrombus with features suggestive of ruptured thrombus and distal embolization (Figure 3). The RA thrombus tethered to the tricuspid valve of 3.4×1.5 mm size and PFO thrombus of the size 8.1×3.1 mm were found to be reduced in size. During the hospital course there was no clinical evidence of any further recognizable embolization. Further hospital stay for the patient was notable for continued intensive care, tracheostomy, and percutaneous endoscopic gastrostomy procedures. Goals of care were discussed with the family, and he was transitioned from critical care to long-term care facility.

Discussion

The origin of a RA thrombus is usually attributed to the embolization of a thrombus from the deep venous system.¹² A primary RA thrombus formation can occur with low blood emptying velocity within the appendage due to an increase in RA size.¹² Iatrogenic causes of RA thrombus formation, including pacemaker leads, indwelling catheters, and mechanical valves, were previously reported.^{13,14} HIV infection, obesity, age, smoking, heart failure, and sedentary life style were risk factors associated with thromboembolism in our patient.¹⁵ There is a 10-time increase in the incidence rate of thrombotic events associated with HIV infection.^{16,17} Even though an elevated brain natriuretic peptide level and presenting symptoms were suggestive of left heart failure, the etiology of the current presentation could be attributed predominantly only to the thrombus. Acquired protein C and S deficiency, deficient heparin cofactor II, antithrombin deficiency, disorder of plasmin, and increased levels of proinflammatory cytokines innate to HIV infection are the factors commonly promoting thrombosis.⁴ The HCV infection with varying viral loads are independently implicated with prothrombotic effects of higher factor VIII and lower protein S level.¹⁸ Protease inhibitors are more often associated with

prothrombotic effects when the CD4 count is less than 200 or in the presence of AIDS-defining illnesses.¹⁹ HIV proteases are aspartyl proteases and inhibition of this enzyme result in decreased regulation of coagulation.^{20,21} Moreover, the lipophilic protease inhibitors are metabolized by the cytochrome P450 systems for biotransformation and they indirectly affect cholesterol metabolism. They are speculated to affect hepatic regulation of thrombotic proteins.²²

The RA thrombus can embolize to the lung and subsequently result in the pressure to rise in the pulmonary system. As the RA pressure rises, the risk of the clot in the RA embolizing through the PFO to the left atrium increases.²³ This paradoxical embolus can result in a stroke or other end organ damage.^{24,25} Cardiac thrombectomy and PFO closure are preferred for low-risk and hemodynamically stable patients. Patients with higher risk and/or unstable hemodynamics managed with thrombolysis or anticoagulation had better outcomes.²⁶

The factors influencing the risk of thromboembolism are often irreversible in HIV-infected patients and a long-term anticoagulation can be useful to prevent further events. Intravenous anticoagulation was provided for our patient. New oral anticoagulant dabigatran administered for 1 year successfully prevented thromboembolic events without any noticeable interaction with the antiretroviral therapy in other case reports.²⁷ Current methodology for predicting thromboembolic risk in HIV-infected patients are not clear, and further studies are warranted to evaluate the role of long-term anticoagulation for this subset of patients.

Conclusion

Thromboembolism in a HIV-infected patient is a potential life-threatening event. Identifying the risk factors for thromboembolism among the HIV-infected individuals and measures for managing with long-term anticoagulation is vital. Further prospective studies to evaluate a new risk score for anticoagulation in this subset is needed.

Declaration of Conflicting Interests

The author(s) declared no potential conflicts of interest with respect to the research, authorship, and/or publication of this article.

Funding

The author(s) received no financial support for the research, authorship, and/or publication of this article.



Ethics Approval

Our institution does not require ethical approval for reporting individual cases or case series.

Informed Consent

Verbal informed consent was obtained from the patient(s) for their anonymized information to be published in this article.

ORCID iDs

Piruthiviraj Natarajan  <https://orcid.org/0000-0003-2702-7476>
Sudhagar Thangarasu  <https://orcid.org/0000-0002-1464-0709>

References

1. Malek J, Rogers R, Kufera J, Hirshon JM. Venous thromboembolic disease in the HIV-infected patient. *Am J Emerg Med.* 2011;29:278-282.
2. Fultz SL, McGinnis KA, Skanderson M, Ragini MV, Justice AV. Association of venous thromboembolism with human immunodeficiency virus and mortality in veterans. *Am J Med.* 2004;116:420-423.
3. Stahl CP, Wideman CS, Spira TJ, Haff EC, Hixon GJ, Evatt BL. Protein S deficiency in men with long-term human immunodeficiency virus infection. *Blood.* 1993;81:1801-1807.
4. Saif MW, Greenberg B. HIV and thrombosis: a review. *AIDS Patient Care STDs.* 2001;15:15-24.
5. Musselwhite LW, Sheikh V, Norton TD, et al. Markers of endothelial dysfunction, coagulation and tissue fibrosis independently predict venous thromboembolism in HIV. *AIDS.* 2011;25:787-795.
6. Dalen JE, Alpert JS. Which patent foramen ovals need closure to prevent cryptogenic strokes? *Am J Med.* 2018;131:222-225.
7. Chartier L, Béra J, Delomez M, et al. Free-floating thrombi in the right heart: diagnosis, management, and prognostic indexes in 38 consecutive patients. *Circulation.* 1999;99:2779-2783.
8. Ibebuogu UN, Khouzam RN, Sharma G, Thornton JW, Robati R, Silverman D. A thrombus in transit through a patent foramen ovale. *JAAPA.* 2014;27:32-35.
9. Kathir K. Communicating massive biatrial thrombus. *Intern Med J.* 2003;33:471-472.
10. Jolobe OMP. Ultrasound-accelerated rheolytic thrombectomy for impending paradoxical embolism. *Am J Emerg Med.* 2016;34:1711.
11. Park C, Roffi M, Noble S, et al. High-risk pulmonary embolism with impending paradoxical embolism successfully treated with percutaneous catheter-based thrombectomy. *Cardiovasculaire.* 2011;14:127-130. doi:10.4414/cvm.2011.01580
12. Benjamin MM, Afzal A, Chamogeorgakis T, Feghali GA. Right atrial thrombus and its causes, complications, and therapy. *Proc (Bayl Univ Med Cent).* 2017;30:54-56.
13. Yilmaz M, Gurlertop Y, Erdogan F. Right atrial thrombus following closure of an atrial septal defect. *Heart.* 2003;89:726.
14. Burns KE, McLaren A. Catheter-related right atrial thrombus and pulmonary embolism: a case report and systematic review of the literature. *Can Respir J.* 2009;16:163-165.
15. McLendon K, Attia M. *Deep Venous Thrombosis (DVT), Risk Factors.* Treasure Island, FL: StatPearls Publishing; 2017.
16. Mwitwa JC, Goepamang M, Mkubwa JJ, Gunness TK, Reebye D, Motumise K. Calcified right atrial thrombus in HIV infected patient. *Pan Afr Med J.* 2013;14:166. doi:10.11604/pamj.2013.14.166.2176
17. Saber AA, Aboolian A, LaRaja RD, Baron H, Hanna K. HIV/AIDS and the risk of deep vein thrombosis: a study of 45 patients with lower extremity involvement. *Am Surg.* 2001;67:645-647.
18. Kiefer EM, Shi Q, Hoover DR, et al. Association of hepatitis C with markers of hemostasis in HIV-infected and uninfected

- women in the Women's Interagency HIV Study (WIHS). *J Acquir Immune Defic Syndr.* 2013;62:301-310.
19. Jacobson MC, Dezube BJ, Aboulafla DM. Thrombotic complications in patients infected with HIV in the era of highly active antiretroviral therapy: a case series. *Clin Infect Dis.* 2004;39:1214-1222.
 20. Simon DI, Xu H, Vaughan DE. Cathepsin D-like aspartyl protease activity mediates the degradation of tissue-type plasminogen activator/plasminogen activator inhibitor-1 complexes in human monocytes. *Biochim Biophys Acta.* 1995;1268:143-151.
 21. Shen YMP, Frenkel EP. Thrombosis and a hypercoagulable state in HIV-infected patients. *Clin Appl Thromb Hemost.* 2004;10:277-280.
 22. George SL, Swindells S, Knudson R, Stapleton JT. Unexplained thrombosis in HIV-infected patients receiving protease inhibitors: report of seven cases. *Am J Med.* 1999;107:624-630.
 23. Chandrala P, Johnson K, Hallani H. Thrombus trapped in patent foramen ovale. *Eur Heart J.* 2015;36:1688.
 24. Yee J, Kumar V, Pham A, et al. Simultaneous onset of deep vein thrombosis, pulmonary embolism, cerebral infarction, and myocardial infarction in a patient with patent foramen ovale. *S D Med.* 2017;70:266-269.
 25. Sattar A, Win TT, Schevchuck A, Achrekar A. Extensive biatrial thrombus straddling the patent foramen ovale and traversing into the left and right ventricle. *BMJ Case Rep.* 2016;2016. doi:10.1136/bcr-2016-216761
 26. Baydoun H, Barakat I, Hatem E, Chalhoub M, Mroueh A. Thrombus in transit through patent foramen ovale. *Case Rep Cardiol.* 2013;2013:395879. doi:10.1155/2013/395879
 27. Perram J, Joseph J, Holloway C. Novel oral anticoagulants and HIV: dabigatran use with antiretrovirals. *BMJ Case Rep.* 2015;2015. doi:10.1136/bcr-2015-211651