

The effects of prenatal and neonatal exposure to electromagnetic fields on infant rat myocardium

Hamid Tayefi¹, Amac Kiray¹, Muge Kiray², Bekir Ugur Ergur², Husnu Alper Bagriyanik², Cetin Pekcetin², Mustafa Fidan³, Candan Ozogul²

¹Departments of Anatomy, Dokuz Eylul University Medical School, Balçova, Izmir, Turkey

²Departments of Histology & Embryology, Dokuz Eylul University Medical School, Balçova, Izmir, Turkey

³Departments of Biophysics, Dokuz Eylul University Medical School, Balçova, Izmir, Turkey

Submitted: 31 July 2009

Accepted: 8 October 2009

Arch Med Sci 2010; 6, 6: 837-842

DOI: 10.5114/aoms.2010.19288

Copyright © 2010 Termedia & Banach

Corresponding author:

Muge Kiray, MD, PhD

Department of Histology

& Embryology

Dokuz Eylul University

Medical School

Balçova, Izmir 35340, Turkey

Phone: +90 232 412 45 62

Fax: +90 232 259 05 41

E-mail:

muge.kiray@deu.edu.tr

Abstract

Introduction: Electromagnetic fields (EMF) have adverse effects as a result of widespread use of electromagnetic energy on biological systems. The aim of this study was to investigate the effects of prenatal exposure to EMF on rat myocardium by biochemical and histopathological evaluations.

Material and methods: In this study, 10 pregnant Wistar rats were used. Half of the pregnant rats were exposed to EMF of 3 mT, and the other half to sham conditions during gestation. After parturition, rat pups in the 5 EMF-exposed litters from birth until postnatal day 20 were exposed to EMF of 3 mT for 4 h/day (EMF-exposed group, $n = 30$). Rat pups in sham litters from birth until postnatal day 20 were exposed to sham conditions (sham group, $n = 20$).

Results: In the EMF-exposed group, lipid peroxidation levels significantly increased compared to sham. Superoxide dismutase activities decreased significantly in the EMF-exposed group compared to sham. TUNEL staining showed that the number of TUNEL-positive cells increased significantly in EMF-exposed rats compared with sham. Under electron microscopy, there were mitochondrial degeneration, reduction in myofibrils, dilated sarcoplasmic reticulum and perinuclear vacuolization in EMF-exposed rats.

Conclusions: In conclusion, the results show that prenatal exposure to EMF causes oxidative stress, apoptosis and morphological pathology in myocardium of rat pups. The results of our study indicate a probable role of free radicals in the adverse effects of prenatal exposure to EMF. Further studies are needed to demonstrate whether the EMF exposure can induce adverse effects on the myocardium.

Key words: electromagnetic field, myocardium, oxidative stress, apoptosis, ultrastructure

Introduction

Electromagnetic fields (EMF) have adverse effects on biological systems. Due to advances in technology and widespread use of electromagnetic energy, today everyone is exposed to EMF. 50-60 Hz EMF are generated from domestic electric distribution systems. EMF affect biological systems by prolonging the life of free radicals in the systems. Free oxygen radicals cause oxidative damage to DNA, impairment of protein function and peroxidation of lipids. Malondialdehyde (MDA) is a breakdown product of the major chain

reactions leading to the oxidation of polyunsaturated fatty acids and thus causing oxidative stress [1]. EMF could cause oxidative DNA damage and increase lipid peroxidation in tissues [2, 3]. Reports have demonstrated that oxidative damage has been implicated in myocardial injuries [4]. Ozguner *et al.* reported an increase in lipid peroxidation in rat heart following exposure to EMF [5]. Antioxidant defences and repair systems which help to protect cells against free radical destruction include superoxide dismutase (SOD), glutathione peroxidase (GPx) and catalase (CAT) [6, 7]. There are several reports which indicate that exposure to EMF reduces antioxidant enzyme activities in rat tissues [8, 9].

The cellular damage induced by oxidative stress may trigger the process of apoptosis. Free oxygen radicals may participate in the initiation of apoptotic or necrotic cell death. EMF can induce apoptosis *in vivo* and *in vitro* [10-12].

Several structural changes may occur after myocardial damage. Myocardial changes could be revealed by light or electron microscopic evaluation. The aim of this study was to investigate the effects of prenatal exposure to EMF on rat hearts by biochemical and histopathological evaluations. For biochemical evaluation, MDA levels were assessed as a marker of lipid peroxidation and the activities of SOD were determined to evaluate antioxidant status in the rat hearts. Light and electron microscopic assessment was carried out for histopathological evaluation.

Materials and methods

Animals and experimental design

All experimental protocols were approved by the Ethics Committee of Animal Care and Experimentation of the University of Dokuz Eylul, Turkey. In this study, 10 pregnant Wistar rats were used for prenatal exposure of EMF. They were housed in individual polycarbonate cages with food and water *ad libitum*. Half of the pregnant rats were exposed to EMF of 3 mT for 4 h a day, and the other half were separated for a sham group during gestation [13]. After parturition, rat pups in the 5 EMF-exposed litters from birth until postnatal day 20 were exposed to EMF of 3 mT for 4 h/day, 7 days/week (EMF-exposed group, $n = 30$). Rat pups in sham litters from birth until postnatal day 20 were exposed to sham conditions (sham group, $n = 20$). At 21 days of age, rat pups were separated from maternal rats, sacrificed and evaluated, without regard to their sex [14].

Magnetic field exposure system

EMF of 3 mT was produced by a pair of Helmholtz coils (95 cm in diameter) with 320 turns of 2.5 mm copper wire in each, mounted on a wooden frame. The distance between coils was

33 cm. Coils were connected in series to a generator delivering an AC current. The output current was 6.43 A at 50 Hz. The magnetic field intensity was measured by a digital teslameter (FW Bell, 5170). The teslameter accuracy was $\pm 2\%$ for AC.

Biochemical estimations

The animals were sacrificed 24 hours after the last exposure, and heart tissue samples were taken out for light and electron microscopic assessment and for biochemical estimations. Determination of MDA levels and antioxidant enzyme activity were performed spectrophotometrically. The Bioxytech MDA-586 (Oxis International, USA) assay for MDA and the Bioxytech SD-525 (Oxis International, USA) assay for SOD activity were performed as per the kit protocol. All enzyme activities were assayed with a Hach Lange DR5000 UV spectrophotometer.

Histopathological examination

The dissected rat hearts were immediately placed in 10% formalin in phosphate buffer overnight, processed by routine histological methods and embedded in paraffin blocks. Paraffin blocks were placed in a Leica RM2125 rotary microtome (Germany) and sections of 5 μm thickness were obtained. Sections were stained for TUNEL. The images were analysed using a computer-assisted image analyser system consisting of a microscope (Olympus BH-2 Tokyo, Japan) equipped with a high-resolution video camera (JVC TK-890E, Japan).

For ultrastructural investigations, the left ventricle pieces were placed in 2.5% glutaraldehyde for 24 hours for fixation. The tissue was postfixed with osmium tetroxide (OsO_4), dehydrated in a graded series of alcohol, and then embedded in Araldite® CY212. Thin (60–90 nm) sections were obtained with an ultramicrotome (Leica), stained with uranyl acetate and lead citrate, examined on a transmission electron microscope (Carl Zeiss Libra 120), and digitally photographed.

Terminal deoxynucleotidyl transferase mediated dUTP nick end labelling (TUNEL) method

TUNEL staining was performed using an In Situ Cell Death Detection Kit® (Roche, Mannheim, Germany) according to the manufacturer's protocol. Briefly, the sections were deparaffinized, hydrated by successive series of alcohol, washed in distilled water followed by phosphate-buffered saline (PBS) and deproteinized by proteinase K (20 $\mu\text{g}/\text{ml}$) for 30 min at 37°C. Then the sections were rinsed and incubated in the TUNEL reaction mixture. The sections were rinsed and visualized using converter-POD with 0.02% 3,3'-diaminobenzidine (DAB). The sections were counter-stained with haematoxylin.

Ten fields were randomly chosen for each slide and a total of 100 cells per field were counted (X20 objective). The apoptotic index (percentage of apoptotic nuclei) was calculated as apoptotic nuclei/total nuclei counted \times 100%. All counting procedures were performed blindly.

Statistical analysis

Results are presented as means \pm SEM. All data were analysed by Mann-Whitney test. $P < 0.05$ was considered statistically significant.

Results

Biochemical analyses

Figure 1 shows the levels of MDA in hearts of rat pups. MDA level in the sham group was 6.84 ± 0.27 .

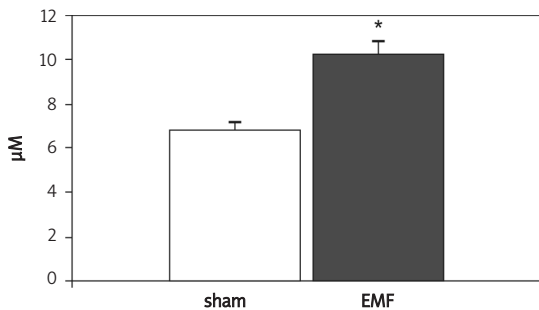


Figure 1 Effects of prenatal exposure to EMF on MDA levels in heart of rat pups. Data are mean \pm SEM
* $P < 0.05$ compared with the sham group

In the EMF-exposed group, tissue MDA levels were significantly increased compared to the sham group (10.21 ± 0.63 , $p < 0.05$). The results of SOD enzyme activities are shown in Figure 2. SOD enzyme activities decreased significantly in the EMF-exposed group compared to the sham group (425.3 ± 65.6 and 1125 ± 288.5 , respectively).

Histopathological examination

The present study shows that EMF exposure enhanced apoptotic cell death in the rat myocardium. Sham rats showed fewer TUNEL-positive cells in the myocardium. There were more TUNEL-positive cells in the EMF-exposed group, as seen in Figure 3. Quantification and statistical analysis of the TUNEL staining showed that the

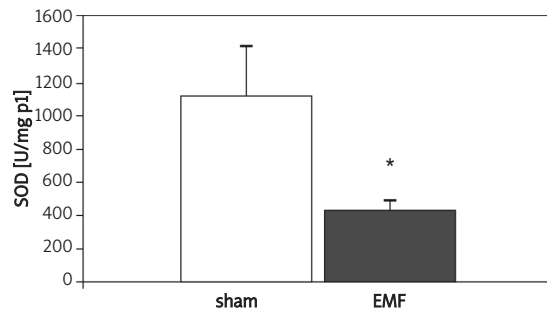


Figure 2 Effects of prenatal exposure to EMF on SOD activity in heart of rat pups. Data are mean \pm SEM
* $P < 0.05$ compared with the sham group

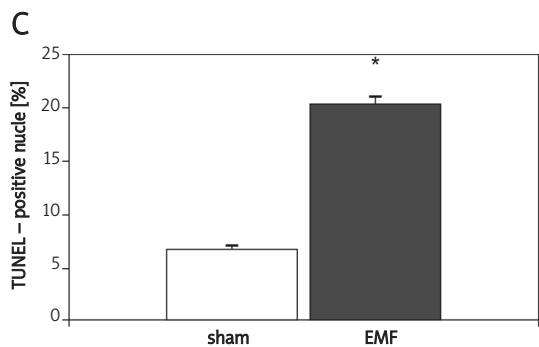
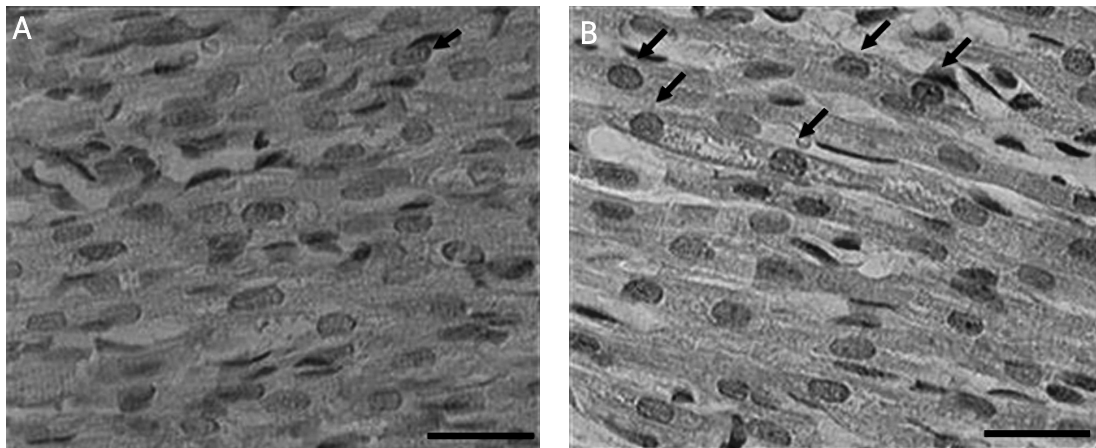


Figure 3 Upper: The effect of prenatal exposure to EMF on apoptosis in heart of rat pups. Representative photomicrographs of TUNEL-positive cells (arrows). **A** and **B** show sections of sham and EMF groups, respectively (scale bar = 30 μ m). Lower: Quantitative analysis of TUNEL-positive cells in the rat heart. Data are mean \pm SEM
* $P < 0.05$ compared with the sham group

number of TUNEL-positive cells increased significantly in EMF-exposed rats compared with sham rats ($p < 0.05$).

In electron microscopic examination, no pathological changes were observed in heart specimens of the sham group; cellular and mitochondrial structures were normal. In EMF-exposed group specimens, there were mitochondrial degeneration and dilated sarcoplasmic reticulum. Most myofibrils had disappeared or were fragmented and perivascular vacuoles had formed (Figure 4).

Discussion

In this study, we demonstrated that EMF causes oxidative damage by increasing MDA levels and suppressing SOD activities in heart tissue in a rat

model of prenatal exposure to EMF. Additionally, the findings of this study indicated that EMF exposure induced apoptosis and ultrastructural changes in heart tissue.

Our results indicate that exposure to 3 mT EMF induces lipid peroxidation in myocardial tissue of rat pups. Lipid peroxidation is one of the determinants of free radical induced oxidative damage. Experimental studies suggest that lipid peroxidation resulting from free oxygen radicals contributes to the EMF-induced oxidative damage [15, 16]. The organism has some protective defence enzymes and repair systems against oxidative damage. In this study, we assessed SOD activities in myocardial tissue of rat pups. The antioxidant enzyme activities were found to be significantly decreased in EMF-exposed rats. Our findings support those of other investigators who




Figure 4. Electron micrographs of the left ventricular myocardium of sham (A1, A2) and EMF-exposed groups (B1, B2). A1-A2, normal myocytes, mitochondria and Z-lines (Z). B1, degeneration and fragmentation of myofibrils (arrows), loss of cristae and swelling in mitochondria (*). B2, fragmentation of myofibrils (arrows) and perivascular vacuoles (*)

demonstrated an increase in lipid peroxidation and decrease in antioxidant enzyme activities in heart tissue with EMF exposure, while the effect of prenatal exposure to EMF in heart tissue has not been well established yet [5].

At the end of the experiment the cardiomyocyte apoptosis was detected by the TUNEL method. Our results showed that prenatal exposure to EMF induces apoptotic cell death in rat pups. The effect of EMF on cardiomyocyte apoptosis is associated with marked increase in MDA. The mechanism through which 3 mT EMF can affect cell death may be due to free radicals. Cardiomyocyte apoptosis is associated with several cardiac diseases. Although increased apoptotic activity in heart tissue with EMF exposure has been reported in vitro, the effect of prenatal exposure to EMF in rat pups has not been previously investigated [17].

In this study histological evidence of EMF-related myocardial tissue injury was shown with electron microscopy. The ultrastructural modifications were assessed to investigate the adverse effects of prenatal exposure to EMF in heart tissue. Under electron microscopy, mitochondrial swelling, reduction in myofibrils, expanded sarcoplasmic reticulum and perinuclear vacuolization were observed. The pathological alterations in myocardial ultrastructure have been shown in various myocardial damage models. Yaras *et al.* demonstrated that diabetic rat hearts show mitochondrial and myofibrillar degeneration. Bartel *et al.* reported pathological changes in sarcoplasmic reticulum, mitochondria and myofibrils in drug cardiotoxicity [18, 19]. In our study, we demonstrated firstly prenatally EMF-induced myocardial pathological changes in ultrastructure of rat pups.

In conclusion, the results show that prenatal exposure to EMF causes apoptosis and morphological pathological changes in myocardium of rat pups. EMF exposure induces oxidative stress through reducing SOD activity parallel to increasing lipid peroxidation. The results of our study indicate a probable role of free radicals in the adverse effects of prenatal exposure to EMF in myocardium of rat pups. Although EMF has been studied for developmental and memory abnormalities in rats, further studies are needed to demonstrate whether EMF exposure can induce adverse effects on rat myocardium.

Acknowledgments

The authors thank Sedef Menku and Ozcan Ustun for their excellent technical assistance. The authors acknowledge financial support from Dokuz Eylul University Research Foundation Grant no: 2005.KB.SAG.012.

References

1. Meral I, Mert H, Mert N, et al. Effects of 900-MHz electromagnetic field emitted from cellular phone on brain oxidative stress and some vitamin levels of guinea pigs. *Brain Res* 2007; 1169: 120-4.
2. Yurekli AI, Ozkan M, Kalkan T, et al. GSM base station electromagnetic radiation and oxidative stress in rats. *Electromagn Biol Med* 2006; 25: 177-88.
3. Yokus B, Cakir DU, Akdag MZ, Sert C, Mete N. Oxidative DNA damage in rats exposed to extremely low frequency electro magnetic fields. *Free Radic Res* 2005; 39: 317-23.
4. Annapurna A, Challa SR, Prakash GJ, Viswanath RK. Therapeutic potential of sulindac against ischemia-reperfusion-induced myocardial infarction in diabetic and nondiabetic rats. *Exp Clin Cardiol* 2008; 13: 66-70.
5. Ozguner F, Altinbas A, Ozaydin M, et al. Mobile phone-induced myocardial oxidative stress: protection by a novel antioxidant agent caffeic acid phenethyl ester. *Toxicol Ind Health* 2005; 21: 223-30.
6. Güler G, Türközer Z, Seyhan N. Electric field effects on Guinea pig serum: the role of free radicals. *Electromagn Biol Med* 2007; 26: 207-23.
7. Feher J, Nemeth E, Nagy V, Lengyel G, Feher J. The preventive role of coenzyme Q10 and other antioxidants in injuries caused by oxidative stress. *Arch Med Sci* 2007; 3: 305-14.
8. Ozguner F, Oktem F, Ayata A, Koyu A, Yilmaz HR. A novel antioxidant agent caffeic acid phenethyl ester prevents long-term mobile phone exposure-induced renal impairment in rat. Prognostic value of malondialdehyde, N-acetyl-beta-D-glucosaminidase and nitric oxide determination. *Mol Cell Biochem* 2005; 277: 73-80.
9. Elhag MA, Nabil GM, Attia AM. Effects of electromagnetic field produced by mobile phones on the oxidant and antioxidant status of rats. *Pak J Biol Sci* 2007; 10: 4271-4.
10. Kennedy MA, Rakoczy SG, Brown-Borg HM. Long-living Ames dwarf mouse hepatocytes readily undergo apoptosis. *Exp Gerontol* 2003; 38: 997-1008.
11. Kaszuba-Zwońska J, Gil K, Ziomber A, et al. Loss of interstitial cells of Cajal after pulsating electromagnetic field (PEMF) in gastrointestinal tract of the rats. *J Physiol Pharmacol* 2005; 56: 421-32.
12. Jajte J, Grzegorzczak J, Zmysłony M, Rajkowska E. Effect of 7 mT static magnetic field and iron ions on rat lymphocytes: apoptosis, necrosis and free radical processes. *Bioelectrochemistry* 2002; 57: 107-11.
13. Canseven AG, Coskun S, Seyhan N. Effects of various extremely low frequency magnetic fields on the free radical processes, natural antioxidant system and respiratory burst system activities in the heart and liver tissues. *Indian J Biochem Biophys* 2008; 45: 326-31.
14. Kurtoglu S, Gunes T, Koklu E, et al. Influence of maternal nicotine exposure on neonatal rat bone: protective effect of pentoxifylline. *Exp Biol Med (Maywood)* 2007; 232: 398-405.
15. Hashish AH, El-Missiry MA, Abdelkader HI, Abou-Saleh RH. Assessment of biological changes of continuous whole body exposure to static magnetic field and extremely low frequency electromagnetic fields in mice. *Ecotoxicol Environ Saf* 2008; 71: 895-902.
16. Seyhan N, Canseven AG. In vivo effects of ELF MFs on collagen synthesis, free radical processes, natural antioxidant system, respiratory burst system, immune system activities, and electrolytes in the skin, plasma, spleen, lung, kidney, and brain tissues. *Electromagn Biol Med* 2006; 25: 291-305.

17. Gottwald E, Sontag W, Lahni B, Weibezahn KF. Expression of HSP72 After ELF-EMF Exposure in Three Cell Lines. *Bioelectromagnetics* 2007; 28: 509-18.
18. Yaras N, Sariahmetoglu M, Bilginoglu A, et al. Protective action of doxycycline against diabetic cardiomyopathy in rats. *Br J Pharmacol* 2008; 155: 1174-84.
19. Bartel LC, Montalto de Mecca M, Fanelli SL, Rodriguez de Castro C, Diaz EG, Castro JA. Early nifurtimox-induced biochemical and ultrastructural alterations in rat heart. *Hum Exp Toxicol* 2007; 26: 781-8.