

# Coinfection by *Talaromyces marneffe* and *Mycobacterium abscessus* in a human immunodeficiency virus-negative patient with anti-interferon- $\gamma$ autoantibody: a case report

Journal of International Medical Research

49(1) 1–7

© The Author(s) 2021

Article reuse guidelines:

[sagepub.com/journals-permissions](https://sagepub.com/journals-permissions)

DOI: 10.1177/0300060520976471

[journals.sagepub.com/home/imr](https://journals.sagepub.com/home/imr)

Weizhong Jin<sup>1,#</sup> , Jianhong Liu<sup>2,#</sup>,  
Kuang Chen<sup>3,#</sup>, Ling Shen<sup>1</sup>, Yan Zhou<sup>4</sup> and  
Limin Wang<sup>1,4</sup>

## Abstract

Patients with anti-interferon (IFN)- $\gamma$  autoantibodies have weakened immune defenses against intracellular pathogens. Because of its low incidence and non-specific symptoms, diagnosis of anti-IFN- $\gamma$  autoantibody syndrome is difficult to establish during the early stages of infection. Here, we report a patient with high titers of serum anti-IFN- $\gamma$  autoantibodies suffering from opportunistic infections. The patient presented with intermittent fever for 2 weeks. During his first hospitalization, he was diagnosed with *Talaromyces marneffe* pulmonary infection and successfully treated with antifungal therapy. However, multiple cervical lymph nodes subsequently became progressively enlarged. *Mycobacterium abscessus* infection was confirmed by positive cervical lymph node tissue cultures. High-titer serum anti-IFN- $\gamma$  antibodies were also detected. Following anti-*M. abscessus* therapy, both his symptoms and lymph node lymphadenitis gradually

<sup>1</sup>Department of Respiratory Medicine, Affiliated Hangzhou First People's Hospital, Zhejiang University School of Medicine, Hangzhou, Zhejiang, P.R. China

<sup>2</sup>Department of Respiratory Medicine, Jinhua Guangfu Hospital, Zhejiang, P.R. China

<sup>3</sup>Department of Hematology, Affiliated Hangzhou First People's Hospital, Zhejiang University School of Medicine, Hangzhou, Zhejiang, P.R. China

<sup>4</sup>Departments of Respiratory Medicine, Affiliated Hangzhou First People's Hospital, Nanjin Medical University, Hangzhou, Zhejiang, P.R. China

<sup>#</sup>These authors contributed equally to this work.

## Corresponding author:

Limin Wang, Departments of Respiratory Medicine, Affiliated Hangzhou First People's Hospital, Zhejiang University School of Medicine, 261 Huansha Road, Hangzhou, Zhejiang 310006, P.R. China.  
Email: [lemonwlm@163.com](mailto:lemonwlm@163.com)



improved. Anti-IFN- $\gamma$  autoantibody syndrome should be considered in adult patients with severe opportunistic coinfections in the absence of other known risk factors.

## Keywords

Case report, anti-interferon- $\gamma$  autoantibodies, *Talaromyces marneffei*, non-tuberculous mycobacteria, adult onset immunodeficiency, *Mycobacterium abscessus*

Date received: 23 September 2020; accepted: 29 October 2020

## Background

Interferon (IFN)- $\gamma$  is produced mainly by Th1 cells, natural killer cells, and CD8<sup>+</sup> T cells. The IFN- $\gamma$ /interleukin-12/tumor necrosis factor- $\alpha$  axis plays a crucial role in host defense against intracellular pathogens.<sup>1,2</sup> Autoantibodies against IFN- $\gamma$  can inhibit IFN- $\gamma$ -dependent signal transducer and activator of transcription 1 phosphorylation in patients with adult-onset susceptibility to opportunistic infections.<sup>3</sup> Because of its low incidence and non-specific symptoms and manifestations, early diagnosis of adult-onset anti-IFN- $\gamma$  autoantibody syndrome is challenging.<sup>4</sup>

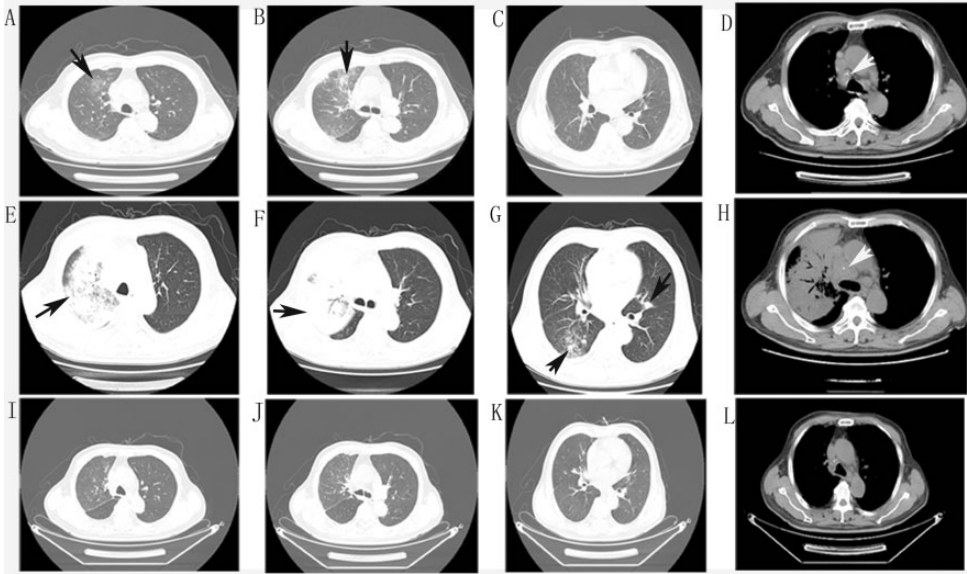
Here, we report a patient with high titer serum anti-IFN- $\gamma$  autoantibodies who suffered from pulmonary *Talaromyces marneffei* infection and infection of multiple lymph nodes by non-tuberculous mycobacteria (NTM). The details of this case may help clinicians to identify this syndrome and implement appropriate treatments early.

## Case presentation

The patient was a 68-year-old man experiencing intermittent fever of unknown cause for 2 weeks. He had a history of hypertension (8 years), kidney stones, and cervical lymphadenopathy (1 year) but no familial medical history. He had not received any treatment for cervical

lymphadenopathy. Physical examination revealed moist rales in the right lung and cervical lymph node enlargement. Laboratory tests showed increased white blood cells and chest computed tomography (CT) showed patchy infiltration in the right upper lobe with mediastinal lymph node enlargement (Figure 1; 3 December 2019). Empirical treatment with cephalosporin was ineffective, and his symptoms recurred along with a central necrotic body rash. A repeat chest CT (17 December 2019) showed aggravated alveolar consolidation in the anterior segment of the right upper lobe, scattered infiltration in the right lower lobe, slight patchy infiltration in the left lingular bronchus, and multiple mediastinal lymphadenopathies (Figure 1). Bronchoscopy and endobronchial ultrasound were performed. Cytology showed nucleated cells counts of  $400 \times 10^5/L$ , neutrophil percentage of 85%, and lymphocyte percentage of 5%. Galactomannan was 0.11 pg/mL and cryptococcal capsular antigen tests were negative in bronchoalveolar lavage fluid. Metagenomic next-generation sequencing and culture demonstrated the presence of *T. marneffei* in biopsy tissue of the right upper lobe (Figure 2).

Cervical lymph nodes were biopsied using fine-needle aspiration. Pathological findings demonstrated atrophy of lymphatic follicles with paracortical hyperplasia,



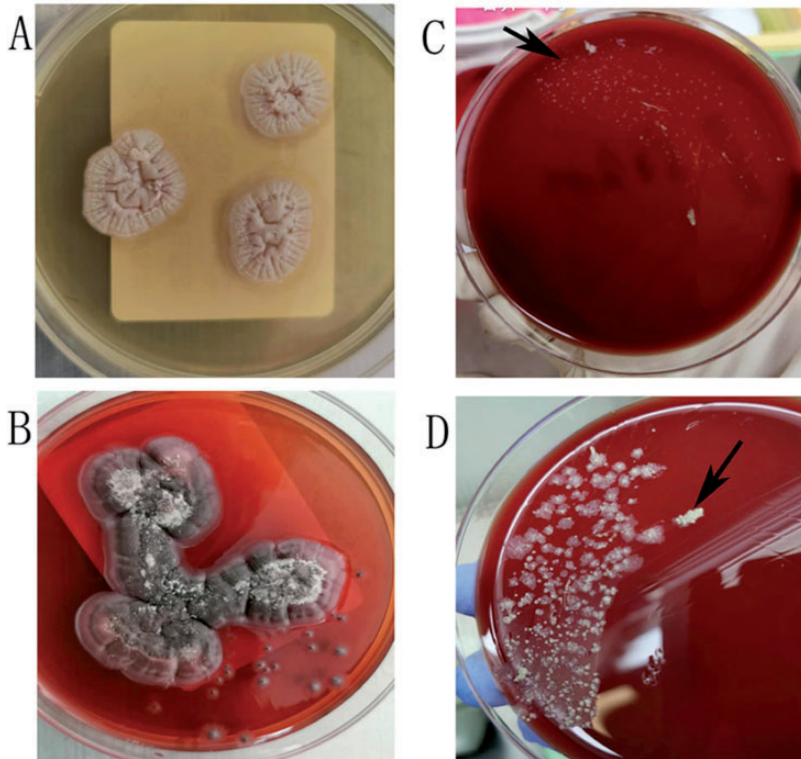
**Figure 1.** Chest computed (CT) images at different times. (A–D) Chest CT on 3 December 2019 showed patchy infiltration in the right upper lobe (black arrows) and mediastinal lymph node enlargement (white arrows). (E–H) Chest CT on 17 December 2019 showed exacerbated infiltration and alveolar consolidation in the left upper lobe, new patchy infiltration in the right lower lobe and left lingular bronchus (black arrows), and progressively enlarged mediastinal lymph nodes (white arrows). (I–L) Chest CT on 26 March 2020 showed marked improvement of pulmonary lesions after treatment.

neutrophil necrosis, histiocyte aggregation, and T-lymphocyte dysplasia. Analysis of T-cell receptor rearrangement ruled out lymphoma. Staining (acid-fast, periodic acid-Schiff, and periodic Schiff-methenamine) and microbial cultures of needle aspirate biopsies were negative for pathogens. Epstein–Barr virus-encoded small non-polyadenylated RNA 1 and 2 positive cells were  $<5$ /high power field. The patient was diagnosed with pulmonary *T. marneffeii* infection and administered voriconazole (0.2 g tablets) twice a day.

Taralomycosis is a rare condition in immunocompetent hosts. It has been previously described in patients with acquired immunodeficiency syndrome, connective tissue diseases and hematological malignancies. Serum autoantibodies [anti-nuclear antibody, anti-centromere antibody, anti-Sjögren's syndrome (SS)-A, anti-SS-B,

anti-mitochondrial antibody, anti-myeloperoxidase antibody, perinuclear and cytoplasmic anti-neutrophil cytoplasmic antibody, and anti-proteinase 3 antibody] were within normal ranges. Human immunodeficiency virus serology was negative, and blood CD4<sup>+</sup> T cell counts, (1, 3)-D glucan, galactomannan, immunoglobulin (Ig, including IgA, IgM, and total IgG), complement C3, complement C4, and procalcitonin were within normal reference ranges. Serum cryptococcal capsular antigen tests and blood tuberculosis infection T cell spot tests were negative. Serum anti-IFN- $\gamma$  autoantibodies were assessed using a standard IFN- $\gamma$  enzyme-linked immunosorbent assay and showed a high titer of 1:500.

The patient was diagnosed with pulmonary taralomycosis and adult-onset immunodeficiency syndrome arising from anti-IFN- $\gamma$  autoantibodies. He was



**Figure 2.** Cultures from lung biopsy and cervical lymph node homogenate. (A) Lung biopsy sample cultured on Sabouraud agar at 35°C showed round gray *Talaromyces marneffei* colonies. (B) Lung biopsy sample cultured on Sabouraud agar at 28°C showed a mycelial form producing a diffusible red pigment. Both (C) and (D) show colonies of *Mycobacterium abscessus* (black arrows) from cervical lymph nodes after incubation for 7 and 10 days, respectively.

followed up regularly in the clinic. Itraconazole (0.2 g capsule) was administered once a day instead of voriconazole because the patient developed a back and neck rash after 1 month of treatment.

After 3 months of antifungal treatment, his condition improved and a chest CT (26 March 2020) showed remarkable absorption of pulmonary consolidation. His mediastinal lymph nodes also reduced synchronously (Figure 1). However, the bilateral cervical, axillary, and supraclavicular lymph nodes became progressively enlarged.

Positron emission tomography (PET)-CT imaging revealed bilateral cervical and supraclavicular lymph node enlargement

and necrosis, with glucose hypermetabolism [maximum standardized uptake value (SUV) 10.2], slight retroperitoneal lymph node enlargement with slight glucose hypermetabolism, and inflammation of the right lung.

To rule out lymphoma, bone marrow needle aspiration was performed. Cytology smears showed proliferation of bone marrow cells. The cervical lymph nodes were again biopsied using fine-needle aspiration. Pathological findings revealed neutrophil necrosis, infarcts and lymphocyte infiltration into necrotic areas. Acid-fast staining and Gomori methenamine silver staining were negative for pathogens.

An enlarged cervical lymph node was surgically excised. Pathological examinations demonstrated positive acid-fast staining in a granulomatous and suppurative inflammatory background. Periodic acid-Schiff and periodic Schiff-methenamine staining were negative. *Mycobacterium abscessus* was cultured and identified from tissue homogenates (Figure 2).

Finally, the patient was diagnosed with anti-IFN- $\gamma$  autoantibody syndrome complicated by *T. marneffei* pulmonary infection and *M. abscessus* lymph node infection. According to drug sensitivity tests, anti-NTM therapy with clarithromycin and moxifloxacin was administered. The patient continuing this regimen and being actively followed up. Both his symptoms and cervical lymphadenitis gradually improved.

## Discussion and conclusions

The interactions between IFN- $\gamma$  and its receptors are critical for macrophage activation and inflammatory reactions. Adult onset immunodeficiency arising from anti-IFN- $\gamma$  autoantibody is associated with opportunistic infections by mycobacteria, *T. marneffei*, *Cryptococcus* spp., *Burkholderia* spp. and other organisms in previously healthy patients.<sup>1-5</sup>

The trigger(s) eliciting anti-IFN- $\gamma$  autoantibodies remain unknown. Recent studies showed that HLA-DRB1 and DQB1 alleles were associated with increased risk of developing anti-IFN- $\gamma$  autoantibody.<sup>5,6</sup> Although functional assessments of IFN- $\gamma$  autoantibodies were not performed in this study, the high titers and mixed opportunistic infections observed in this patient were suggestive of adult-onset immunodeficiency syndrome.

Therapies for adult-onset immunodeficiency syndrome are directed against either infectious complications or the autoantibodies themselves.<sup>7</sup> Rituximab, exogenous IFN- $\gamma$ , plasmapheresis, and

cyclophosphamide have been used to treat refractory infections<sup>8,9</sup> and showed clinical benefits, although autoantibody levels following therapy were not routinely tested.

*T. marneffei* is the only dimorphic fungus of the genus *Talaromyces* (formerly *Penicillium*). Talaromycosis is a rare opportunistic infection typically affecting immunocompromised or immunosuppressed patients. The condition is rarely observed in immunocompetent patients and in non-endemic regions outside of Southeast Asia and southern China,<sup>10-12</sup> such as Hangzhou, North Zhejiang Province, East China. Therefore, we first assessed the presence of underlying immune deficiencies in our patient such as acquired immunodeficiency syndrome, connective tissue diseases, hematological malignancies and immunosuppressants. In addition, we investigated and detected the presence of IFN- $\gamma$  autoantibodies.

The symptoms of *T. marneffei* infection typically include fever, malaise, lymph node enlargement, skin eruptions, weight loss, dyspnea, diarrhea, and hemoptysis. Chest radiography typically reveals multiple nodules and/or consolidation, often involving the upper lobes.<sup>13</sup>

In our case, enlarged mediastinal lymph nodes, as well as pulmonary lesions, improved significantly following antifungal therapy. We speculate that the patient's enlarged mediastinal lymph nodes, in addition to lung changes, were caused by talaromycosis. In addition, multiple cervical lymph nodes became progressively enlarged, suggesting different etiological factors.

Infections by NTM are common in patients with adult onset immunodeficiency syndrome caused by anti-IFN- $\gamma$  autoantibody. Henkle et al.<sup>14</sup> reported that 8.4% (28/334) of extra-pulmonary NTM infections affected the lymph nodes. Most patients affected by NTM infection have specific susceptibility factors,<sup>15</sup> including

structural lung damage or immunosuppressed status.<sup>16</sup> In our case, NTM infection of multiple lymph nodes was attributed to the presence of anti-IFN- $\gamma$  autoantibodies. NTM infections often progress to systemic dissemination in patients with anti-IFN- $\gamma$  autoantibodies.<sup>14,17</sup> In the present case, we failed to recognize underlying opportunistic infection by NTM until surgical biopsy of a cervical lymph node.

*M. abscessus* is a rapidly growing NTM that generally requires intravenous therapy and is difficult to eradicate. *M. abscessus* can be classified into three subspecies: *M. abscessus* subsp. *abscessus*, *M. abscessus* subsp. *massiliense*, and *M. abscessus* subsp. *bolletii*. The rates of response to antibiotic therapy differ for each of these subspecies. Therefore, subspecies identification is becoming increasingly important for NTM therapy.<sup>18</sup>

Giudice et al.<sup>19</sup> reported that PET-CT has the potential to identify both pulmonary and lymph node NTM infection and showed an average SUV of  $1.21 \pm 0.29$  (range: 0.90–1.70) in affected mediastinal lymph nodes. In the present case, PET-CT showed a maximum SUV of 10.2 in bilateral cervical lymph nodes. In our case, multiple lymphadenopathies, PET results and the primary reports from fine-needle aspiration biopsy could have indicated a hematological malignancy. Eventually, multiple myeloma and lymphoma were excluded upon thorough examinations.

Skin manifestations have been reported in patients with IFN- $\gamma$  autoantibody syndrome complicated by disseminated taralomycosis or NTM infection.<sup>20</sup> These manifestations can be divided into skin infections and reactive dermatitis. Our patient's rash with central necrosis was characteristic of *T. marneffei* skin infection but disappeared prior to antifungal therapy. Therefore, there was insufficient evidence of *T. marneffei* skin infection, and

the rash most likely reflected a reactive skin disorder.

In summary, anti-IFN- $\gamma$  autoantibody syndrome should be considered in patients with severe opportunistic infections in the absence of other obvious risk factors. Disseminated *T. marneffei* and NTM are the most significant complications associated with anti-IFN- $\gamma$  autoantibody syndrome.

### Ethical statement and informed consent

The study was approved by the Ethics Committee at the Hangzhou First People's Hospital of Zhejiang University and complied with the principles laid out in the Declaration of Helsinki. The patient provided written consent for the publication of this report.

### Declaration of conflicting interest

The authors declare that there is no conflict of interest.

### Funding

Funding support for publication of this work was supplied by the Zhejiang Province Nature Science Funding Commission Social Science Development Project (grant no. LGF20H010005).

### ORCID iD

Weizhong Jin  <https://orcid.org/0000-0001-9335-2336>

### References

1. Tang BS, Chan JF, Chen M, et al. Disseminated penicilliosis, recurrent bacteremic nontyphoidal salmonellosis, and burkholderiosis associated with acquired immunodeficiency due to autoantibody against gamma interferon. *Clin Vaccine Immunol* 2010; 17: 1132–1138.
2. Nekooie-Marnany N, Deswarte C, Ostadi V, et al. Impaired IL-12- and IL-23-mediated immunity due to IL-12R $\beta$ 1 deficiency in Iranian patients with mendelian

- susceptibility to mycobacterial disease. *J Clin Immunol* 2018; 38: 787–793.
3. Browne SK and Holland SM. Anticytokine autoantibodies in infectious diseases: Pathogenesis and mechanisms. *Lancet Infect Dis* 2010; 10: 875–885.
  4. Su SS, Zhang SN, Ye JR, et al. Disseminated *Talaromyces marneffei* and *Mycobacterium avium* infection accompanied Sweet's syndrome in a patient with anti-interferon- $\gamma$  autoantibodies: A case report. *Infect Drug Resist* 2019; 12: 3189–3195.
  5. Phoompoung P, Ankasekwina N, Pithukpakorn M, et al. Factors associated with acquired anti-IFN- $\gamma$  autoantibody in patients with nontuberculous mycobacterial infection. *PLoS One* 2017; 12: e0176342.
  6. Watanabe M, Uchida K, Nakagaki K, et al. Anti-cytokine autoantibodies are ubiquitous in healthy individuals. *FEBS Lett* 2007; 581: 2017–2021.
  7. Browne SK. Anticytokine autoantibody-associated immunodeficiency. *Annu Rev Immunol* 2014; 32: 635–657.
  8. Browne SK, Zaman R, Sampaio EP, et al. Anti-CD20 (rituximab) therapy for anti-interferon- $\gamma$  autoantibody-associated nontuberculous mycobacterial infection. *Blood* 2012; 119: 3933–3939.
  9. Laisuan W, Pisitkun P, Ngamjanyaporn P, et al. Prospective pilot study of cyclophosphamide as an adjunct treatment in patients with adult-onset immunodeficiency associated with anti-interferon- $\gamma$  autoantibodies. *Open Forum Infect Dis* 2020; 7: ofaa035.
  10. Li Y, Lin Z, Shi X, et al. Retrospective analysis of 15 cases of *Penicillium marneffei* infection in HIV-positive and HIV-negative patients. *Microb Pathog* 2017; 105: 321–325.
  11. Ma W, Thiryayi SA, Holbrook M, et al. Rapid on-site evaluation facilitated the diagnosis of a rare case of *Talaromyces marneffei* infection. *Cytopathology* 2018; 29: 497–499.
  12. Wang YG, Cheng JM, Ding HB, et al. Study on the clinical features and prognosis of penicilliosis marneffei without human immunodeficiency virus infection. *Mycopathologia* 2018; 183: 551–558.
  13. Zhang Z, Tao F, Li Y, et al. Disseminated *Penicillium marneffei* infection recurrence in a non-acquired immune deficiency syndrome patient: A case report. *Mol Clin Oncol* 2016; 5: 829–831.
  14. Shih DC, Cassidy PM, Perkins KM, et al. Extrapulmonary nontuberculous mycobacterial disease surveillance – Oregon, 2014–2016. *MMWR Morb Mortal Wkly Rep* 2018; 67: 854–857.
  15. Sood G and Parrish N. Outbreaks of nontuberculous mycobacteria. *Curr Opin Infect Dis* 2017; 30: 404–409.
  16. Sexton P and Harrison AC. Susceptibility to nontuberculous mycobacterial lung disease. *Eur Respir J* 2008; 31: 1322–1333.
  17. Yoshizawa K, Aoki A, Shima K, et al. Serum anti-interferon- $\gamma$  autoantibody titer as a potential biomarker of disseminated non-tuberculous mycobacterial infection. *J Clin Immunol* 2020; 40: 399–405.
  18. Koh WJ, Stout JE and Yew WW. Advances in the management of pulmonary disease due to *Mycobacterium abscessus* complex. *Int J Tuberc Lung Dis* 2014; 18: 1141–1148.
  19. Del Giudice G, Bianco A, Cennamo A, et al. Lung and nodal involvement in nontuberculous mycobacterial disease: PET/CT role. *Biomed Res Int* 2015; 2015: 353202.
  20. Jutivorakool K, Sittiwattanawong P, Kantikosum K, et al. Skin manifestations in patients with adult-onset immunodeficiency due to anti-interferon-gamma autoantibody: A relationship with systemic infections. *Acta Derm Venereol* 2018; 98: 742–747.