

Zero-iodinated contrast retrograde percutaneous coronary interventions of chronic total occlusions using gadolinium and imaging guidance: a case report of a patient with severe anaphylaxis to iodinated contrast

Ankur Gupta ^{1,2}, Saroj Neupane^{1,2}, Mir Basir ^{1,2}, and Khaldoon Alaswad^{1,2*}

¹Division of Cardiology, Department of Internal Medicine, Henry Ford Hospital, 2799 W. Grand Blvd, Detroit, MI 48202, USA; and ²Wayne State University School of Medicine, Detroit, MI 48201, USA

Received 23 October 2019; first decision 30 December 2019; accepted 1 April 2020; online publish-ahead-of-print 3 May 2020

Background

Gadolinium-based contrast agents have been used as an alternative to iodinated contrast agents for simple percutaneous coronary interventions (PCIs) in patients with obstructive coronary artery disease. Their use has been limited in complex PCI due to poor image quality with gadolinium contrast. Significant dilution of gadolinium is required in an effort to avoid malignant ventricular arrhythmias. Further, the recommended amount of gadolinium contrast that can be used is very limited.

Case summary

We describe a case of patient with severe anaphylaxis to iodinated contrast agents despite pre-exposure prophylaxis with steroids and histamine blockers who underwent intravascular imaging-guided PCI of chronic total occlusions (CTOs) of left anterior descending and dominant left circumflex arteries using gadolinium contrast.

Discussion

In patients with anaphylaxis to iodinated contrast agents (i) complex coronary interventions including CTO PCI can be successfully performed without use of iodinated contrast, and (ii) combination of intravascular ultrasound guidance and gadolinium-based contrast agents can be safely and effectively used to perform complex PCI.

Keywords

Case report • Chronic total occlusion • Complex coronary interventions • Contrast allergy • Gadolinium contrast • Percutaneous coronary intervention • Zero-iodinated contrast

Learning points

- This is first-in-man case report of the use of gadolinium-based contrast to perform successful chronic total occlusion (CTO) percutaneous coronary intervention (PCI) in a patient with severe anaphylaxis to iodinated contrast.
- Complex coronary interventions including CTO PCI can be successfully performed without use of iodinated contrast.
- In patients with anaphylaxis to iodinated contrast agents, combination of intravascular ultrasound guidance and gadolinium-based contrast agents can be safely and effectively used to perform complex PCI.

* Corresponding author. Tel: +1 313 916 9898, Fax: +1 313 916 4489, Email: kalaswa1@hfhs.org

Handling Editor: Parham Eshtehardi

Peer-reviewers: Christoph Jensen, Romain Didier, and Alice Wood

Compliance Editor: Carlos Minguito Carazo

Supplementary Material Editor: Peregrine Green

© The Author(s) 2020. Published by Oxford University Press on behalf of the European Society of Cardiology.

This is an Open Access article distributed under the terms of the Creative Commons Attribution Non-Commercial License (<http://creativecommons.org/licenses/by-nc/4.0/>), which permits non-commercial re-use, distribution, and reproduction in any medium, provided the original work is properly cited. For commercial re-use, please contact journals.permissions@oup.com

Introduction

Gadolinium-based contrast agents are used intravenously in routine clinical practice for contrast-enhanced magnetic resonance imaging. They have been used as an alternative to iodinated contrast agents to perform coronary and endovascular angiography and interventions in patients with contraindication to iodinated contrast.^{1–4} However, image quality is substantially reduced due to inability to use digital subtraction angiography during peripheral vascular interventions and need to dilute gadolinium to avoid malignant ventricular arrhythmias during coronary angiography.² Further, the amount of contrast that can be used is limited by the maximum recommended weight-based dose, which is typically 0.1 mmol/kg, that corresponds to a maximum of 0.1–0.2 mL/kg. Therefore, performing percutaneous coronary intervention (PCI) with gadolinium can be extremely challenging especially complex PCIs. We describe a case of patient with severe anaphylaxis to iodinated contrast who underwent intravascular imaging-guided PCI of chronic total occlusions (CTOs) of left anterior descending (LAD) and dominant left circumflex (LCX) arteries using gadolinium contrast.

Timeline

10 years before current presentation	Admission for unstable angina with chest pain and shortness of breath leading to the diagnosis of severe multivessel coronary artery disease. Patient underwent coronary artery bypass grafting with left internal mammary artery (LIMA) to left anterior descending (LAD), saphenous venous graft (SVG) to Ramus Intermedius, and SVG to left posterior descending artery (LPDA)
1–4 years before current presentation	Recurrent admissions for unstable angina or non-ST elevation myocardial infarction with multiple percutaneous coronary interventions (PCIs) of SVG to LPDA and LIMA to LAD
Current presentation	Canadian Class IV angina refractory to four anti-anginal medications at maximally tolerated doses. Coronary and bypass graft angiography revealed recurrent bypass graft failure with severe in-stent restenosis in both SVG to LPDA and LIMA to LAD grafts with chronic total occlusion (CTO) of proximal LAD and CTO of dominant left circumflex (LCX)
PCI attempt for current presentation	Severe bronchospasm, laryngospasm, and cardiorespiratory arrest immediately following contrast administration
2 months after current presentation	Re-attempt after pre-medication for contrast allergy—after 2 mL challenge of contrast dye, severe cardiopulmonary collapse requiring emergent venoarterial extracorporeal membranous oxygenation
4 months after current presentation	Successful zero-iodinated contrast LAD CTO PCI with gadolinium and intravascular ultrasound (IVUS) guidance
6 months after current presentation	Successful zero-iodinated contrast LCX CTO PCI with gadolinium and IVUS guidance

Case presentation

A 51-year-old woman with past history of diabetes, hypertension, hyperlipidaemia, obesity, smoking, and peripheral arterial disease presented with severe limiting angina refractory to medical therapy (beta-blockers, long-acting oral nitrates, calcium channel blockers, and ranolazine). She had history of triple-vessel coronary artery bypass 10 years ago when she presented with unstable angina and was found to have severe multivessel coronary artery disease (CAD). Over the past 4 years, she has had multiple admissions for unstable angina or non-ST elevation myocardial infarction for which she received multiple PCIs of saphenous venous graft (SVG) to left posterior descending artery (LPDA) and left internal mammary artery (LIMA) to LAD. Her SVG to ramus intermedius was known occluded. Repeat graft and coronary angiography this presentation revealed recurrent severe in-stent restenosis of the SVG to LPDA and the LIMA to LAD ([Figure 1](#), [Supplementary material online, Video S1](#)) in addition to known chronically occluded proximal LAD and dominant mid-LCX, patent proximal ramus intermedius stent with subtotal occlusion of inferior branch of ramus intermedius, and patent first obtuse marginal artery. Resting electrocardiogram showed diffuse ischaemic ST-T abnormalities ([Figure 1](#)). She had normal vital signs and unremarkable cardiopulmonary examination on presentation. Renal function was normal and left ventricular ejection fraction was 60% with normal wall motion. Due to her refractory angina and recurrent bypass graft failure, a heart team decision was made to proceed with CTO PCI of LAD and dominant LCX. Previously, patient had tolerated all interventions using iodinated contrast (Isovue-370) without allergic reaction. However, this time immediately after administration of the same iodinated contrast, she developed respiratory and haemodynamic collapse and cardiac arrest requiring brief cardiopulmonary resuscitation. A reattempt 2 months later was undertaken after pre-medication for contrast allergy. However, after challenge with 2 mL of Isovue-370 contrast, she experienced severe cardiopulmonary collapse requiring emergent placement of venoarterial extracorporeal membranous oxygenation. She fully recovered from this anaphylactic reaction. However, she continued to have severe limiting angina and a decision was made to proceed with PCI using gadolinium contrast without use of iodinated contrast. Given the severity of reaction to the contrast agent, no allergological testing was pursued after consultation with allergy and immunology specialists.

Previous coronary angiographic films were used as roadmap for procedural planning ([Figure 1](#), [Supplementary material online, Video S1](#)).

The left main coronary artery and LIMA were engaged with 8-Fr EBU 3.75 and 7-Fr IMA Launcher guide catheters (Medtronic), respectively via bilateral common femoral arterial accesses. An attempt at antegrade wire escalation with Fielder XT-A (Asahi Intecc), Pilot 200 (Abbott), and Gaia 3rd (Asahi Intecc) coronary guidewires supported by Corsair Pro 135-cm microcatheter (Asahi Intecc) was not successful in crossing the CTO. An attempt to perform antegrade dissection and re-entry using knuckled Pilot 200 guidewire failed due to knuckle favouring a small diagonal branch or LAD septal branch. The antegrade gear could not be redirected toward the LIMA to LAD anastomosis despite the use of intravascular ultrasound (IVUS) guidance. Using LIMA to LAD as the retrograde conduit, we successfully performed reverse Controlled Antegrade and Retrograde

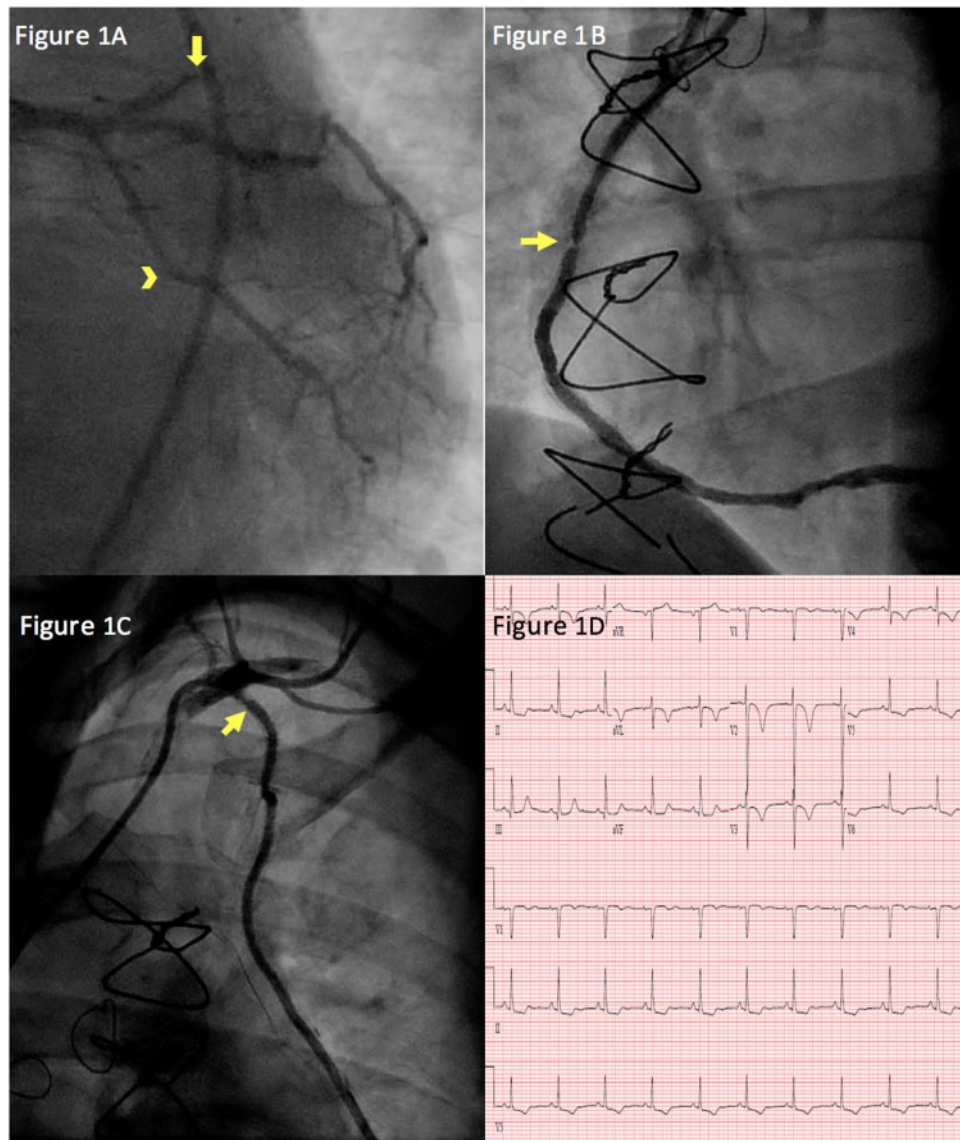


Figure 1 Diagnostic coronary angiography. Diagnostic coronary angiography was performed with iodinated contrast prior to patient's development of severe anaphylaxis to iodinated contrast. Angiography showed chronic total occlusion of proximal left anterior descending (arrow), patent proximal ramus intermedius stent, chronic total occlusion of left circumflex artery (arrowhead) in atrioventricular groove after first obtuse marginal branch (A), chronically occluded non-dominant right coronary artery and saphenous venous graft to ramus intermedius (not shown), and recurrent failure of saphenous venous graft to left posterior descending artery (B) and left internal mammary artery to left anterior descending artery (C) with severe in-stent restenosis in both grafts (arrows). Resting electrocardiogram showed diffuse ischaemic ST-T abnormalities (D).

Tracking (rCART) using Sion guidewire (Asahi Intecc) supported by Corsair Pro 150-cm microcatheter retrogradely (Figure 2, Supplementary material online, Video S2). The wire entered the left main guide catheter. Intravascular ultrasound was used to confirm the true lumen positioning of the wire in proximal LAD and left main coronary artery. Retrograde Corsair Pro microcatheter was then advanced to the left main guide and a R350 wire (Teleflex) was externalized. Under IVUS guidance, predilation and stenting of LAD into left main coronary artery was performed. Antegrade wiring of distal LAD was performed using Twin-Pass Torque (Teleflex) dual-lumen

microcatheter. The distal to proximal LAD and distal left main was stented with overlapping 2.5 mm × 38 mm, 3.0 mm × 38 mm, and 3.5 mm × 23 mm everolimus-eluting stents. Proximal optimization of stent in left main coronary artery was performed with a 5.0-mm non-compliant balloon. Intravascular ultrasound optimization of stents was performed to ensure adequate stent expansion and apposition. Kissing balloon angioplasty of left main/LAD with LCX and ramus intermedius was performed. Balloon angioplasty of inferior branch of ramus intermedius was also performed. Up until this stage no contrast agent was used. The gadolinium was mixed with normal saline in

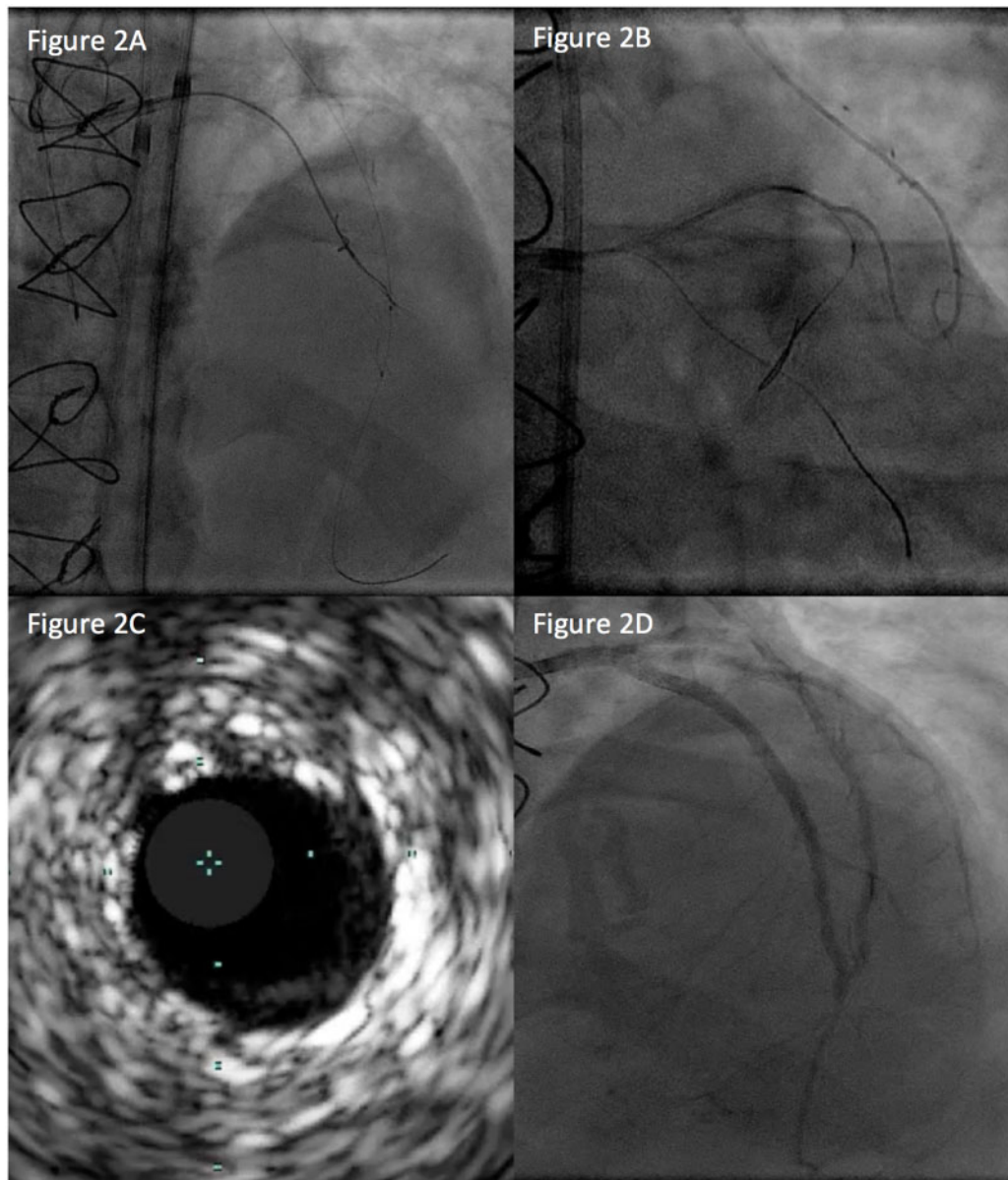


Figure 2 Zero-iodinated contrast gadolinium-based chronic total occlusion percutaneous coronary intervention of left anterior descending artery. Chronic total occlusion percutaneous coronary intervention of left anterior descending artery was successfully performed without use of iodinated contrast. Antegrade wire escalation and antegrade dissection re-entry failed to cross the lesion (A). The chronic total occlusion segment was successfully crossed retrogradely with reverse controlled antegrade and retrograde tracking strategy using left internal mammary artery to left anterior descending artery as retrograde conduit (B). Intravascular ultrasound-guided stent optimization was performed (C). No contrast (iodinated or gadolinium) was used till this stage. Post-percutaneous coronary intervention gadolinium contrast angiography confirmed Thrombolysis In Myocardial Infarction grade 3 flow in left anterior descending artery (D, see [Supplementary material online, Video S2](#)).

1:1 ratio and used to perform final angiograms that showed Thrombolysis In Myocardial Infarction (TIMI) 3 flow in LAD, ramus intermedius, and proximal LCX into first obtuse marginal branch ([Figure 2, Supplementary material online, Video S2](#)). The total intracoronary gadolinium used was 15 mmol (15 mL) diluted 1:1 with normal saline to a total of 30 mL. Gadolinium was also used for inflation of intracoronary balloons and stents. The procedure was completed

with 71 min of fluoroscopy time and 21.9 mSv effective radiation dose. The patient tolerated the procedure well and discharged home next day without any complications.

After 6 weeks from LAD CTO PCI, staged revascularization of LCX CTO was performed. With bilateral common femoral arterial access, left main coronary artery was engaged with an 8-Fr EBU 4.0 antegrade guide catheter and SVG to LPDA was engaged with a 7-Fr

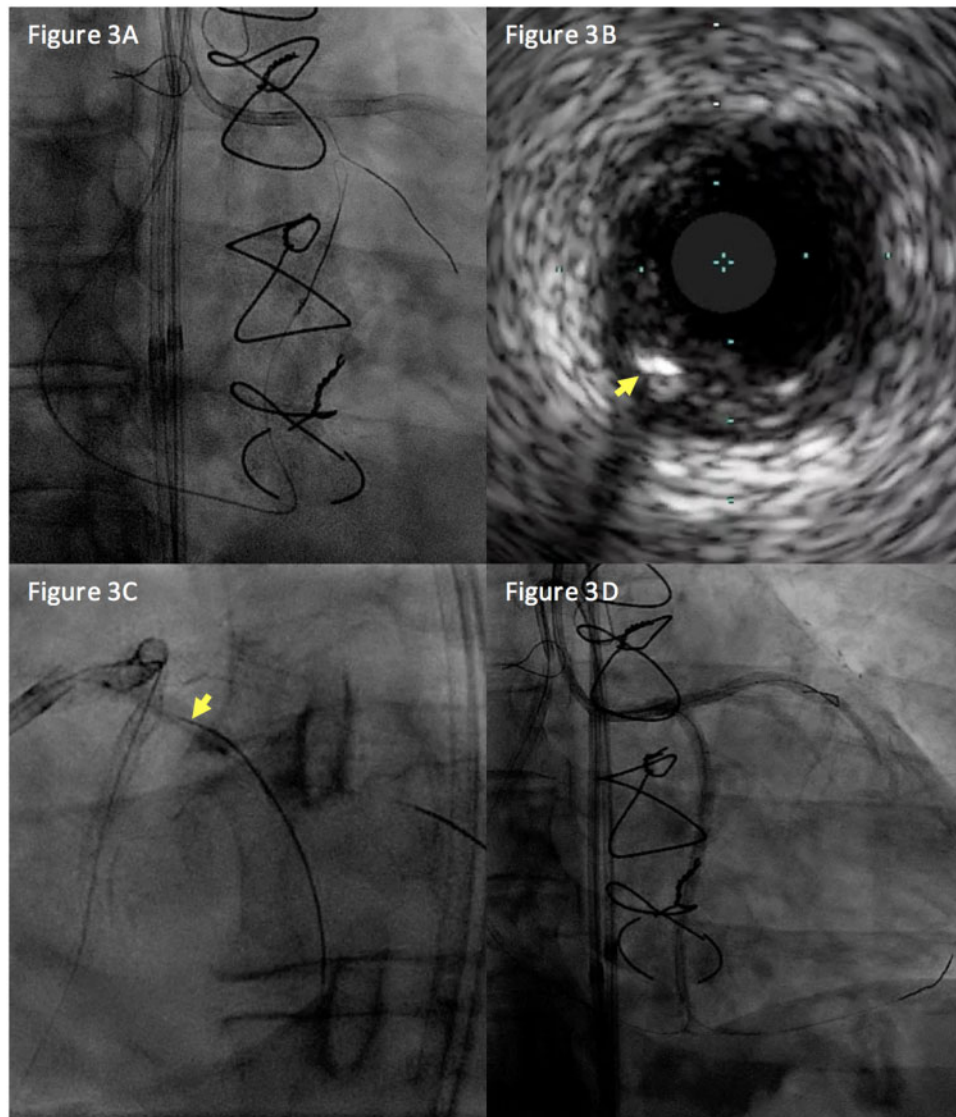


Figure 3 Zero-iodinated contrast gadolinium-based chronic total occlusion percutaneous coronary intervention of left circumflex artery. Chronic total occlusion percutaneous coronary intervention of left circumflex artery was successfully performed without use of iodinated contrast. Primary retrograde approach to chronic total occlusion percutaneous coronary intervention was taken with saphenous vein graft to left posterior descending artery as retrograde conduit (A). (B) Intravascular ultrasound image with intravascular ultrasound catheter advanced over antegrade wire in true lumen of proximal left circumflex and retrograde wire in subintimal space close to true lumen. The chronic total occlusion segment was successfully crossed with intravascular ultrasound-guided reverse controlled antegrade and retrograde tracking (C). (C) Retrograde wire (arrow) in subintimal space was used to puncture true lumen of proximal left circumflex artery. A balloon was inflated over antegrade wire to assist in bringing true lumen close to the subintimal retrograde wire. Intravascular ultrasound-guided stent optimization was performed. No contrast (iodinated or gadolinium) was used till this stage. Post-percutaneous coronary intervention gadolinium contrast angiography confirmed Thrombolysis In Myocardial Infarction grade 3 flow in left circumflex artery (D, see [Supplementary material online, Video S3](#)).

MPA1 retrograde guide catheter. The CTO segment was successfully crossed using IVUS-guided rCART technique. A 3.0 mm × 15 mm balloon over antegrade wire was inflated in proximal LCX which was then punctured via retrograde Gaia 3rd wire supported by Mamba Flex 150 cm (Boston Scientific) microcatheter ([Figure 3](#), [Supplementary material online, Video S3](#)). The retrograde wire crossed the CTO segment successfully and entered the previously

stented LAD artery antegradely. After confirming true lumen intrastent position of retrograde wire with IVUS, it was redirected from LAD towards left main coronary artery into the guide catheter. The wire was externalized using R350 wire. The distal to proximal LCX was stented with overlapping 2.5 mm × 38 mm and 3.0 mm × 38 mm everolimus-eluting stents. Intravascular ultrasound optimization of stents was performed to ensure adequate stent expansion and

apposition. Kissing balloon angioplasty of LCX and OM1 as well as LAD and LCX was performed. Up until this stage no contrast agent was used. The gadolinium was mixed with normal saline in 1:1 ratio and used to perform selective angiogram of LCX that showed TIMI 3 flow in LCX with poor antegrade filling of LPDA likely due to competitive flow from SVG (Supplementary material online, Video S3). SVG to LPDA was then closed with a 4-mm Amplatzer vascular plug (Abbott). The total gadolinium used was 8 mmol (8 mL) diluted 1:1 with normal saline to a total volume injected of 16 mL. The procedure was completed with 62 min of fluoroscopy time and 18.7 mSv effective radiation dose. The patient tolerated the procedure well and was discharged home the next day without any complications on the following medications: dual antiplatelet therapy with aspirin and prasugrel, lipid lowering therapy with rosuvastatin 40 mg nightly, and anti-anginal therapy with carvedilol, isosorbide mononitrate, nifedipine, and ranolazine. At 3-month follow-up clinic visit, patient had continued to do well with significant relief of angina from Canadian Class IV to Class I. She was taken off of her isosorbide mononitrate, nifedipine, and ranolazine by this time. She had quit smoking and was successfully pursuing the cardiac rehabilitation programme.

Discussion

Coronary artery CTO, defined as total occlusion of at least 3 months duration with TIMI 0 antegrade flow, is relatively prevalent in contemporary practice with reported presence in 31% and 89% of patients with CAD with or without prior coronary artery bypass graft surgery, respectively.⁵ Chronic total occlusion PCI is one of the most technically complex procedures in interventional cardiology. Both observational studies and randomized clinical trial data have shown that CTO PCI leads to significant reduction in anginal burden and an improvement in health status of patients compared with optimal medical therapy alone.⁶ However, these procedures are associated with long procedure times with high doses of iodinated contrast use.⁷ History of anaphylaxis to iodinated contrast agents could prevent clinically indicated catheter-based coronary revascularization. In this report, we demonstrated that in patients with anaphylaxis to iodinated contrast agents (i) complex coronary interventions including CTO PCI can be successfully performed without use of iodinated contrast, and (ii) combination of IVUS guidance and gadolinium-based contrast agents can be safely and effectively used to perform complex PCI.


Imaging- and physiology-guided zero contrast PCI has been shown to be feasible, safe, and effective for routine PCI in patients with advanced renal failure.⁸ However, patients with CTOs or calcified lesions in tortuous vessels were excluded. Limited data exists on performance of zero contrast PCI in patients with highly complex CAD especially those with CTOs. To our knowledge, this is the first-in-man case report demonstrating use of gadolinium-based contrast agent for CTO PCI. In our study, no contrast (iodinated or gadolinium) was used until after the successful crossing, dilatation, and stenting of the CTO lesions. Gadolinium contrast was then used to assess successful restoration of antegrade flow through recanalized CTO artery as well as to evaluate competitive flow through venous conduit, identification of which led to the decision to plug the graft. Gadolinium contrast during these procedures can also be used to

assess for complications, such as perforations especially if clinically suspected. In patients with severe renal dysfunction but without contrast allergy, when gadolinium may not be desired, zero contrast retrograde CTO PCI can be performed with antegrade flow confirmed at the end using fractional flow reserve or flow-based imaging techniques.⁹ In such cases, high alertness for identification of complications is needed and can be achieved with haemodynamic data, fluoroscopy, and echocardiography to evaluate for pericardial effusion that may indicate coronary perforation.

Conclusion

Chronic total occlusion PCI is feasible using gadolinium when used in combination with IVUS in patients with anaphylaxis to iodinated contrast agents.

Lead author biography



Dr Ankur Gupta is an interventional cardiologist specializing in complex high-risk indicated procedures, chronic total occlusion percutaneous coronary interventions, and mechanical circulatory support at Henry Ford Hospital, Detroit, Michigan, USA. Dr Gupta has earned doctorate in computational fluid dynamics and statistics from the University of Alabama at Birmingham and masters in health policy and management from the Harvard School of Public

Health and has previously served as the National Institutes of Health post-doctoral cardiovascular research fellow at Brigham and Women's Hospital, Harvard Medical School, Boston, MA, USA.

Supplementary material

Supplementary material is available at *European Heart Journal - Case Reports* online.

Slide sets: A fully edited slide set detailing this case and suitable for local presentation is available online as [Supplementary data](#).

Consent: The author/s confirm that written consent for submission and publication of this case report including image(s) and associated text has been obtained from the patient in line with COPE guidance.

Conflict of interest: A.G. and S.N. have received honorarium from Abiomed. M.B. is a consultant for Abbott Vascular, Abiomed, Cardiovascular Systems, Chiesi, and Zoll. K.A. is a consultant for Abbott Vascular, Boston Scientific, Cardiovascular Systems, Teleflex, and LevaNova.

References

1. Juneman E, Saleh L, Thai H, Goldman S, Movahed MR. Successful coronary angiography with adequate image acquisition using a combination of gadolinium and a

- power injector in a patient with severe iodine contrast allergy. *Exp Clin Cardiol* 2012;**17**:17–19.
2. Kalsch H, Kalsch T, Eggebrecht H, Konorza T, Kahlert P, Erbel R. Gadolinium-based coronary angiography in patients with contraindication for iodinated x-ray contrast medium: a word of caution. *J Interv Cardiol* 2008;**21**:167–174.
 3. Saleh L, Juneman E, Movahed MR. The use of gadolinium in patients with contrast allergy or renal failure requiring coronary angiography, coronary intervention, or vascular procedure. *Catheter Cardiovasc Interv* 2011;**78**:747–754.
 4. Parodi JC, Ferreira LM. Gadolinium-based contrast: an alternative contrast agent for endovascular interventions. *Ann Vasc Surg* 2000;**14**:480–483.
 5. Jeroudi OM, Alomar ME, Michael TT, El Sabbagh A, Patel VG, Mogabgab O, Fuh E, Sherbet D, Lo N, Roesle M, Rangan BV, Abdullah SM, Hastings JL, Grodin J, Banerjee S, Brilakis ES. Prevalence and management of coronary chronic total occlusions in a tertiary Veterans Affairs hospital. *Catheter Cardiovasc Interv* 2014;**84**:637–643.
 6. Werner GS, Martin-Yuste V, Hildick-Smith D, Boudou N, Sianos G, Gelev V, Rumoroso JR, Erglis A, Christiansen EH, Escaned J, di Mario C, Hovasse T, Teruel L, Bufe A, Lauer B, Bogaerts K, Goicolea J, Spratt JC, Gershlick AH, Galassi AR, Louvard Y; EUROCTO Trial Investigators. A randomized multicentre trial to compare revascularization with optimal medical therapy for the treatment of chronic total coronary occlusions. *Eur Heart J* 2018;**39**:2484–2493.
 7. Demir OM, Lombardo F, Poletti E, Laricchia A, Beneduce A, Maccagni D, Slavich M, Giannini F, Carlino M, Margonato A, Cappelletti A, Colombo A, Azzalini L. Contrast-induced nephropathy after percutaneous coronary intervention for chronic total occlusion versus non-occlusive coronary artery disease. *Am J Cardiol* 2018;**122**:1837–1842.
 8. Ali ZA, Karimi Galougahi K, Nazif T, Maehara A, Hardy MA, Cohen DJ, Ratner LE, Collins MB, Moses JW, Kirtane AJ, Stone GW, Karpaliotis D, Leon MB. Imaging- and physiology-guided percutaneous coronary intervention without contrast administration in advanced renal failure: a feasibility, safety, and outcome study. *Eur Heart J* 2016;**37**:3090–3095.
 9. Hatem R, Finn MT, Riley RF, Mathur M, Lombardi WL, Ali ZA, Karpaliotis D. Zero contrast retrograde chronic total occlusions percutaneous coronary intervention: a case series. *Eur Heart J Case Rep* 2018;**2**:1–5.