

# A modified COMS plaque for iris melanoma

Daniel J. Scanderbeg, PhD<sup>1</sup>, Deepta Vasudev, MD<sup>2</sup>, Roger K. Rice, PhD<sup>1</sup>, Michael Goldbaum, MD<sup>2</sup>, Arno J. Mundt, MD<sup>1</sup>

<sup>1</sup>Department of Radiation Oncology and Center for Advanced Radiotherapy Technologies (CART), <sup>2</sup>Department of Ophthalmology, University of California, San Diego, La Jolla, CA, USA

## Abstract

Melanoma of the iris is a rare condition compared to posterior ocular tumors and in this case report we present a 51-year-old female patient with diffuse iris melanoma. Traditional COMS (Collaborative Ocular Melanoma Study) plaques are used at our institution for radiation therapy, so a novel modification of the traditional plaque was required to allow better conformance with placement on the cornea. The usual silastic insert was machined to dimensions in compliance with the cornea, placed without incident, and treatment delivered with excellent patient tolerance of the modified plaque.

J Contemp Brachyther 2011; 3, 3: 13H33

DOI: 10.5114/jcb.2011.24819

**Key words:** brachytherapy, COMS, eye plaque, iris melanoma.

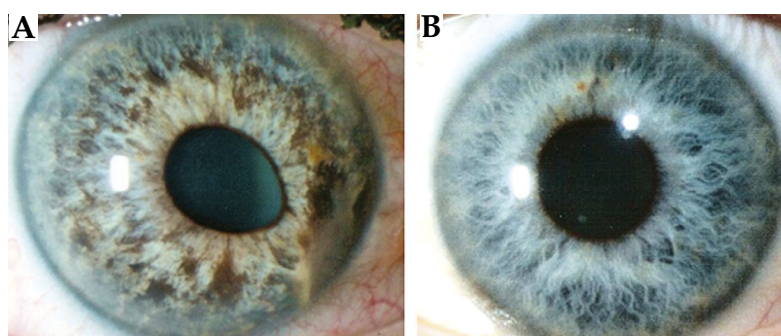
## Purpose

Iris melanoma is a rare condition, occurring only in approximately 2-10% of patients with uveal melanoma [1-3]. Thus, malignancies with posterior involvement are the most common. Plaque therapy for posterior involvement has been successful and its use has been extended to cases with anterior involvement with several studies published using COMS (Collaborative Ocular Melanoma Study) and modified COMS plaques showing excellent results, with local control 92-100% [4-7]. With such a low rate of occurrence and limited radiation therapy options, a novel approach to treat melanoma of the iris using modified COMS plaque was devised for the patient.

## Case history

A 51-year-old Caucasian female presented with three months of apparent iris color change. As per history, the pa-

tient noted no change in vision, no redness, and no history of trauma. Family and friends had noted that the right eye color appeared to be getting darker for a period of three months (Fig. 1). Two weeks prior to presentation, the patient noted a change in pupil shape and some foreign body sensation. In the lead of examination, she had 20/20 vision in both eyes, with elevated intraocular pressure of 26 mmHg in the right eye (15 mmHg in the left eye). Gonioscopy revealed 4+ diffuse pigment in the Trabecular Meshwork. The anterior chamber was deep and quiet. The iris showed diffuse pigment dispersion along with a 3.35 mm by 1 mm elevated pigmented lesion on the inferonasal iris. The pupil was peaked inferonasally. The remainder of the slitlamp examination was within normal. Dilated fundus assessment revealed a choroidal nevus superonasal to the optic nerve and measured 2.3 mm by 3.1 mm. Fluorescein angiography of the iris revealed mild leakage around the edge of the iris lesion inferonasally and some pinpoint hyperfluorescence



**Fig. 1.** Photograph comparing the patient's normal eye versus that with diffuse iris melanoma. A) Darkening of the iris to black-brown color in iris with some extension to cornea. B) Patient's normal eye

**Address for correspondence:** Daniel J. Scanderbeg, PhD, Department of Radiation Oncology, University of California, San Diego, 3855 Health Sciences Drive, La Jolla, CA 92093-0843, Phone: (858) 822-7928,

✉ e-mail: dscanderbeg@ucsd.edu

Received: 08.06.11

Accepted: 22.07.11

Published: 30.09.11

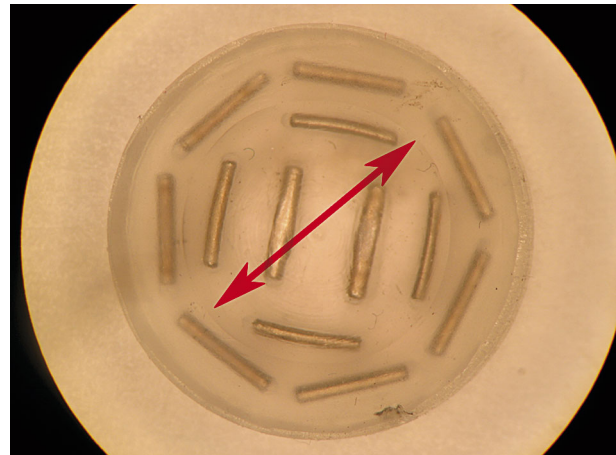
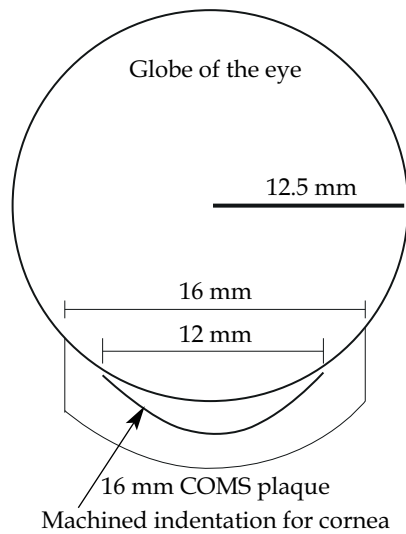


Fig. 2. Schematic diagram of insert (left) and picture showing machined indentation (arrow) to accommodate cornea curvature

within the iris lesion. The decision was made to do an iris biopsy to confirm the presence of iris melanoma, which was consistent with diffuse malignant melanoma. The risks and benefits of a  $^{125}\text{I}$  plaque therapy versus enucleation were discussed with the patient, and the decision to proceed with plaque therapy was reached.

A traditional 16 mm COMS plaque was used as the basis for treatment. The silastic insert for the 16 mm plaque was taken to the machine shop where it was immersed in liquid nitrogen to keep it hard during the modification process. A 9/16" ball end mill was used to create an indentation with a diameter of about 12 mm to a depth of approximately 1 mm. The schematic diagram along with the photograph of modified insert is shown in Fig. 2. The two center-most seed positions were omitted from the plaque as milling could compromise the integrity of the seed wells. Brachytherapy treatment plan was obtained using TG-43 formalism on a BrachyVision platform (Varian Medical Systems, Inc., Palo Alto, CA), with a prescription of 8000 cGy over 4 days. The plaque was modeled using the seed coordinates for the 16 mm COMS plaque and dose was pre-

scribed to the depth specified by the ophthalmologist. Model 6711,  $^{125}\text{I}$  seeds were ordered from GE Healthcare/Oncura (Arlington Heights, IL), the plaque assembled with the modified insert placed into the traditional 16 mm COMS plaque, and normal sterilization was carried out prior to surgery. The patient was taken to the operating room and sedated via IV sedation. Peribulbar anesthesia was performed using 0.75% marcaine and 4% lidocaine. After prepping and draping the patient in the usual sterile fashion for ophthalmic surgery, a 360 degree conjunctival peritomy was made to reflect the conjunctiva away from the limbus. The 16 mm acrylic template was then placed over the cornea and a marking pen was used to outline the borders of the plaque. The brachytherapy device was then appropriately positioned over the cornea and secured in place using 5-0 Dacron sutures passed through 4 of the islets on the device and through partial thickness sclera (Fig. 3). A bandage contact lens was placed under the radiation device to help prevent corneal abrasions. The conjunctivae was left reflected back away from the radiation device. Subconjunctival ancef was given to the patient, the eye was patched, and a shield was

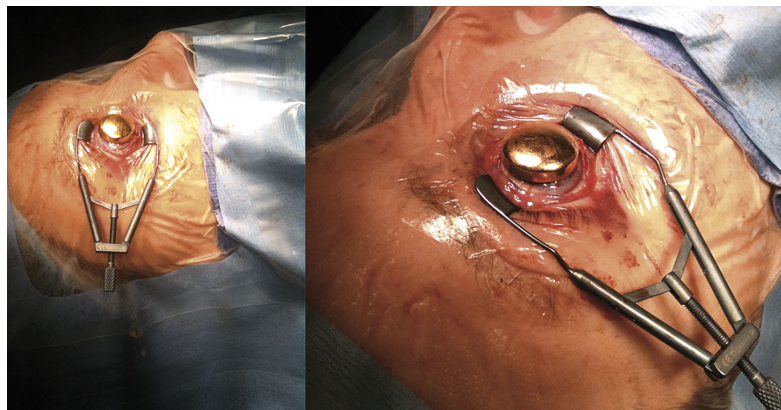


Fig. 3. Surgery with plaque positioned directly on the cornea

placed over it. Post-insertion, the radiation device was found to be secure and conformed nicely over the surface of the entire cornea. The radiation device was left in place for 4 days and then removed. Upon removal, the conjunctiva was re-approximated to the limbus with 8-0 vicryl sutures.

## Results and discussion

With the majority of ocular melanomas occurring near the posterior aspects of the globe, the silastic insert has a radius of curvature that matches the globe and is approximately 12.5 mm. However, the cornea has a radius of curvature of approximately 7.5 mm. Therefore, if a traditional silastic insert was placed over the cornea to treat an anterior tumor, there could be excessive pressure exerted on the cornea or non-conformance of the plaque to the cornea because of the mismatch in the radius of curvature. This non-conformance could lead to a rocking motion of the plaque back and forth around the cornea after placement.

There have been several publications on plaque irradiation for iris melanoma, with some using traditional COMS plaques (with or without the silastic insert) and some using modified donut-shaped or boomerang-shaped applicator [4-7]. Both of these methods were deemed unacceptable for our patient for the following reasons, respectively: 1) placement of the traditional silastic insert can cause excessive pressure on the cornea while securing the plaque in place along with possible non-conformance (described above) and 2) the donut/boomerang plaque was not indicated here as the diagnosis was diffuse melanoma and the tumor was expected to involve the entire surface of the iris. Mechanical modification of the silastic insert proved to be possible with the use of liquid nitrogen to keep the insert rigid during the milling process. Not only was the modification feasible, but the treatment plan adequately covered the tumor, and the modified insert was well tolerated by the patient during 4 days application of brachytherapy. Post-operatively, the patient was found to have minimal corneal epithelial cell loss. Two months after plaque placement and removal, the patient has normal intraocular pressure of 18 mmHg and no vision loss and the iris lesion, originally seen inferonasally, is no longer visible.

## Conclusions

Mechanical modification of the silastic insert used for traditional COMS treatment has been performed with excellent results. The modification demonstrated conformance to patient anatomy while maintaining dosimetric coverage of the tumor.

## Acknowledgements

The authors wish to thank Prof. M.B. Maple for the use of laboratory equipment at UC San Diego during this investigation.

## References

1. Marigo FA, Finger PT. Anterior segment tumors: current concepts and innovations. *Surv Ophthalmol* 2003; 48: 569-593.
2. Jensen OA. Malignant melanomas of the human uvea. Recent follow-up of cases in Denmark, 1943-1952. *Acta Ophthalmol (Copenh)* 1970; 48: 1113-1128.
3. Shields CL, Shields JA, Materin M et al. Iris melanoma: risk factors for metastasis in 169 consecutive patients. *Ophthalmology* 2001; 108: 172-178.
4. Shields CL, Shields JA, De Potter P et al. Treatment of non-resectable malignant iris tumors with custom designed plaque radiotherapy. *Br J Ophthalmol* 1995; 79: 306-312.
5. Shields CL, Naseripour M, Shields JA et al. Custom-designed plaque radiotherapy for non-resectable iris melanoma in 38 patients: Tumor control and ocular complications. *Am J Ophthalmol* 2003; 135: 648-656.
6. Finger PT. Plaque radiation therapy for malignant melanoma of the iris and ciliary body. *Am J Ophthalmol* 2001; 132: 328-335.
7. Thomson RM, Furutani KM, Pulido JS et al. Modified COMS plaques for  $^{125}\text{I}$  and  $^{103}\text{Pd}$  iris melanoma brachytherapy. *Int J Radiat Oncol Biol Phys* 2010; 78: 1261-1269.