

## CLINICAL REPORT

# Pregnancy management in a patient with stickler syndrome

Julie Gomez<sup>1</sup>  | Stephanie M. Rice<sup>2</sup> | Mona M. Makhamreh<sup>2</sup> | Huda B. Al-Kouatly<sup>2</sup> 

<sup>1</sup>Sidney Kimmel Medical College of Thomas Jefferson University, Philadelphia, PA, USA

<sup>2</sup>Division of Maternal-Fetal Medicine, Department of Obstetrics and Gynecology, Sidney Kimmel Medical College of Thomas Jefferson University, Philadelphia, PA, USA

**Correspondence**

Huda B. Al-Kouatly, Department of Obstetrics and Gynecology, Thomas Jefferson University, 833 Chestnut Street, Obstetrics and Gynecology Department, Philadelphia, PA 19107, USA.  
Email: huda.al-kouatly@jefferson.edu

**Funding information**

No financial support was received for this study.

**Abstract**

**Background:** Stickler syndrome is a collagen disorder that can affect multiple organ systems. It is characterized by ocular abnormalities, hearing loss, midfacial hypoplasia, hypermobility, and joint abnormalities. The phenotypic expression of Stickler syndrome can vary among those affected. Since Stickler syndrome is a collagen disorder, it is possible to expect pregnancy complications similar to those reported in other collagen disorders. To our knowledge, there is only one case report in the literature on the management of pregnancy and delivery of a patient with Stickler syndrome.

**Methods/Case Report:** A 37-year-old primigravid woman with a diagnosis of Stickler syndrome presented at 9 weeks gestation for prenatal genetic consultation. At 26, the patient had prophylactic laser therapy for lattice degeneration of the retina. At 32, she was found to be heterozygous for the c.1527 G>T variant in the *COL2A1* gene, which is associated with ocular abnormalities and autosomal dominant form of Stickler syndrome. Subsequently, she desired to pursue prenatal diagnostic testing for the familial variant. The patient voiced that the results would impact pregnancy management. Amniocentesis was performed at 16 weeks gestation. Results were negative for the maternal *COL2A1* variant. Karyotype was normal (46, XX).

**Results:** A multidisciplinary team using a patient-centered approach including obstetrics, ophthalmology, maternal-fetal medicine, and genetics determined that there were no contraindications for vaginal delivery. At 39 weeks, the patient underwent spontaneous vaginal delivery with no complications.

**Conclusion:** There is a paucity of data available regarding the maternal outcomes of women affected with collagen disorders, especially Stickler Syndrome. This case highlights the importance of accurate genetic diagnosis in the prenatal period and provides information to physicians caring for patients with Stickler syndrome.

**KEYWORDS**

collagen disorders, pregnancy, prenatal, Stickler syndrome

## 1 | INTRODUCTION

Stickler syndrome is a collagen disorder that can affect multiple organ systems. It is characterized by ocular abnormalities (myopia, cataract, or retinal detachment), conductive or

sensorineural hearing loss, midfacial hypoplasia, hypermobility, mild spondyloepiphyseal dysplasia, and precocious arthritis (Robin, Moran, & Ala-Kokko, 1993, pp. 2-11). There is a distinct group of physical features that may overlap with Stickler syndrome called Pierre Robin Sequence, which includes a cleft

This is an open access article under the terms of the Creative Commons Attribution-NonCommercial-NoDerivs License, which permits use and distribution in any medium, provided the original work is properly cited, the use is non-commercial and no modifications or adaptations are made.

© 2020 The Authors. *Molecular Genetics & Genomic Medicine* published by Wiley Periodicals LLC.

palate, glossoptosis, and micrognathia. The phenotypic expression of Stickler syndrome can vary among those affected. Most types of Stickler syndrome are inherited as autosomal dominant, indicating that affected individuals have a 50% chance of having affected offspring (Robin et al., 1993, p. 11; Tompson et al., 2017). The remaining types of Stickler syndrome are inherited in an autosomal recessive manner, conferring a 25% risk to offspring of carrier parents. Pathogenic variants in one of six genes: *COL2A1*, *COL11A1*, *COL11A2*, *COL9A1*, *COL9A2*, and *COL9A3* are associated with the condition. To our knowledge, there is only one case reported on the management of pregnancy and delivery of a patient with Stickler syndrome (Sanderson & Byrd, 2009). This limited information can make it difficult for providers to navigate pregnancy management, including determining the appropriate mode of delivery, of a patient with a diagnosis of Stickler syndrome, a condition that may pose increased risks in pregnancy.

Literature regarding similar collagen disorders, including Ehlers–Danlos, have reported risks during both pregnancy and labor that may be relevant to Stickler syndrome (Gilliam, Hoffman, & Yeh, 2020). Various collagen disorders increase the risk of preterm premature rupture of membranes (PPROM) and an incompetent cervix, leading to preterm delivery (Anum, Hill, Pandya, & Strauss, 2009; De Vos, Nuytinck, Verellen, & De Paepe, 1999). Since Stickler syndrome also affects collagen production, it is possible to expect pregnancy complications similar to those reported in other collagen disorders, such as PPRM.

## 2 | CASE

A 37-year-old primigravid woman with a diagnosis of Stickler syndrome presented at 9 weeks gestation for prenatal genetic consultation. She was diagnosed with Pierre Robin sequence at birth. She had myopia and worsening vision at the age of 4 and received a clinical diagnosis of Stickler syndrome at the age of 5. At 9 years of age, she began seeing a retina specialist for thin vitreous gel and at 26, she had prophylactic laser therapy for lattice degeneration of the retina. Annual retinal exams recommended by ophthalmology following laser prophylaxis have been normal. The patient also has a history of jaw augmentation at the age of 18. At 32, she underwent molecular testing for Stickler syndrome and was found to be heterozygous for the c.1527 G>T variant in the *COL2A1* gene (OMIM + 120140) which is associated with the autosomal dominant form of Stickler syndrome. This variant was considered “likely pathogenic” at the time of testing and was recently reclassified as a “pathogenic.” Significant family history includes the patient's mother, who has a personal history of hypermobility, mild scoliosis, high arched palate, and mitral valve prolapse, which are findings that may potentially be suggestive of Stickler syndrome (Figure 1). However, the

patient's mother never sought a formal genetic evaluation or targeted testing for the patient's *COL2A1* variant. The patient and her partner were planning to undergo preimplantation genetic testing for the familial variant of Stickler syndrome, when she spontaneously conceived. Subsequently, the patient desired to pursue prenatal diagnostic testing for the familial variant due to the 50% risk to the pregnancy. If affected, the patient voiced that she would terminate the pregnancy out of concern for intrafamilial variability of the condition. She recognized that she has a mild form of the disease and expressed concern for possibly having a child with a more severe phenotype. As such, a transvaginal chorionic villus sampling (CVS) was attempted at 12 weeks gestation but was unable to be completed due to a steep angle of the cervix. Transabdominal CVS was not attempted due to the posterior location of the placenta. Subsequently, amniocentesis was performed at 16 weeks gestation. Evaluation of the fetal chin at that time was normal. Results were negative for the maternal *COL2A1* variant, concluding that the fetus did not have Stickler syndrome. Karyotype was also performed due to patient's advanced maternal age and was normal (46, XX). In the second trimester, the patient's blood was drawn for routine maternal serum alpha-fetoprotein (MSAFP) screening, which was elevated at 4.44 Multiples of Median (MoM). However, amniocentesis revealed a normal level of amniotic fluid alpha-fetoprotein (AF-AFP) of 0.76 MoM. In conjunction with a normal fetal anatomy ultrasound, it was believed that the likely source of the increased MSAFP is placental in origin. Other etiologies of increased MSAFP may include, but are not limited to: maternal cystic fibrosis, for which the patient screened negative; Hepatitis, for which the patient screened negative for both Hepatitis B and C; and certain neoplasms including germ cell tumors and liver cancer, though MSAFP levels would be expected to be much higher. Cervical length screening was performed via transvaginal ultrasound at the time of the anatomy evaluation and was repeated at 23 weeks since the patient could be at risk for preterm delivery. The cervical length was normal at 37mm and 48 mm, respectively. The patient underwent growth ultrasound at 28 and 36 weeks of gestation to assess the fetal growth in the setting of elevated MSAFP and stickler syndrome. Fetal growth was normal. An appropriate mode of delivery was determined by a multidisciplinary team using a patient-centered approach, including obstetrics, ophthalmology, maternal-fetal medicine, and genetics. Unassisted vaginal delivery was determined to be safe despite the patient's ocular manifestations. At 39 weeks, the patient underwent an induction of labor. A 3,090 g female was born via spontaneous vaginal delivery. Apgar scores were 8 and 9 at 1 and 5 min, respectively. There were no maternal or neonatal complications. Blood loss was normal. Postpartum maternal visual disturbances were not reported. Patient was scheduled to follow-up with her ophthalmologist postpartum. Placental pathology was not performed.

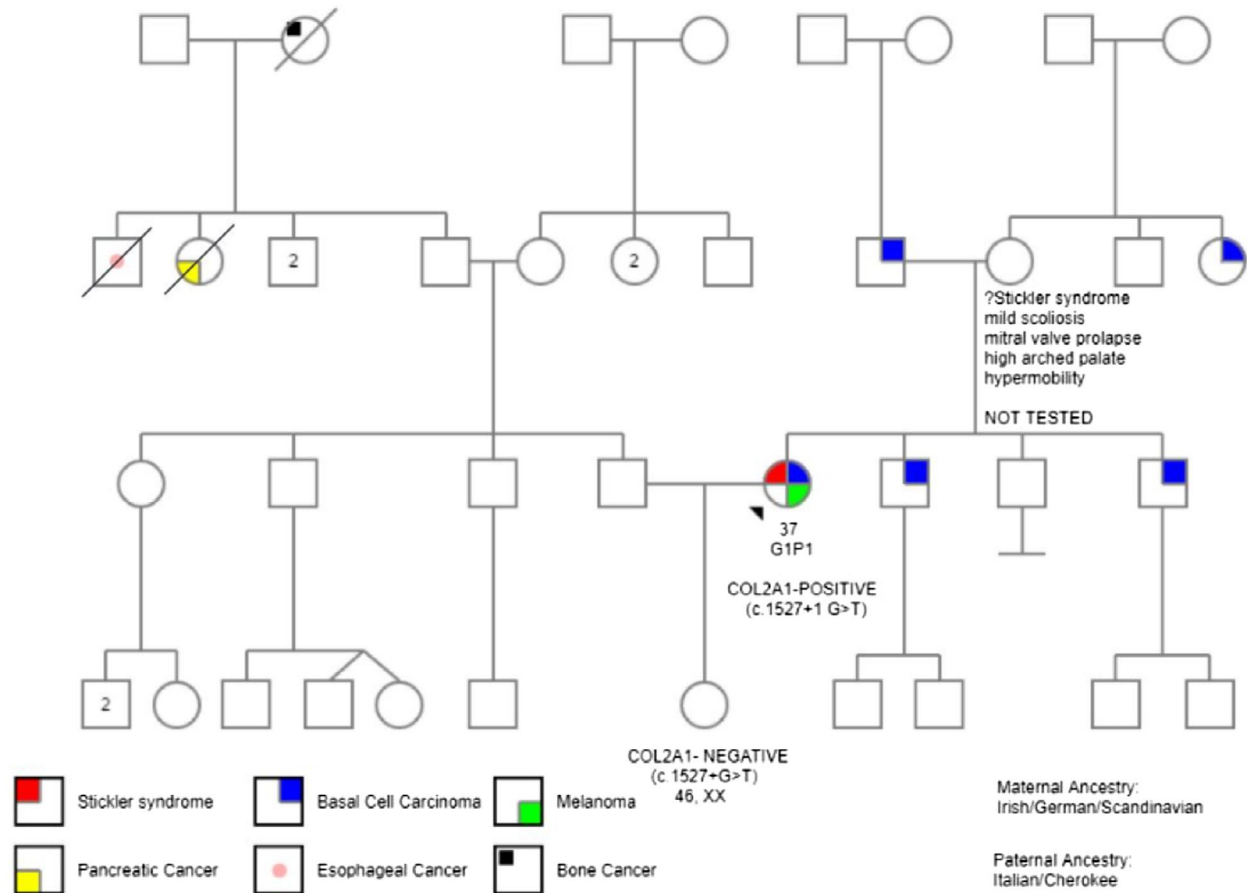


FIGURE 1 Patient's pedigree

### 3 | METHODS

#### 3.1 | Ethical compliance

IRB approval from Thomas Jefferson University is not required for case report publications. Consent has been obtained from the patient.

#### 3.2 | Genetic information

The GenBank version number for *COL2A1* has the NCBI Reference Sequence: NG\_008072.1. The mutation discussed in this case has been reported in the Ensembl database as a mutation in exon 20 of the gene, transcript: ENST00000493991.

#### 3.3 | Search strategy

This systematic review was conducted using Scopus and PubMed from inception through October 24, 2019. Duplicates were removed. Relevant articles describing any case of Stickler syndrome were identified without any time, language, or study limitations. We used the following search

terms: pregnancy, fibrillar collagens, fibril-associated collagens, *COL2A1*, *COL11A1*, *COL11A2*, *COL9A1*, *COL9A2*, *COL9A3*, Stickler, and arthro-ophthalmopathy. The reference list of each article was reviewed for additional articles and abstracts. No additional abstracts were added.

### 4 | DISCUSSION

There is a paucity of data available regarding the maternal outcomes of women affected with collagen disorders, especially Stickler Syndrome. Various collagen disorders increase the risk of preterm premature rupture of the membranes (PPROM) and an incompetent cervix; therefore, these disorders are associated with an increased risk of preterm delivery (Anum et al., 2009; De Vos et al., 1999). Stickler syndrome is also a collagen disorder; therefore, monitoring cervical length may be equally as important for proper pregnancy management as it is in other collagen disorders, such as Ehlers–Danlos syndrome (Karthikeyan & Venkat-Raman, 2018). The *COL2A1* variant that our patient carried is most commonly associated with ocular pathologies, including retinal detachment (Richards et al., 2010). Evidence surrounding labor and delivery in women with a previous

history of ocular abnormalities is both scarce and varied. In the past, retinal detachment was thought to be influenced by Valsalva-like maneuvers. However, this theory is no longer favored with the increased knowledge on properties of the vitreous and its interactions with the retina (Chiu, Steele, McAlister, & Lam, 2015). Landau et al suggest that normal deliveries are not contraindicated in healthy pregnant females with high risk for retinal pathology (Landau, Seelenfreund, Tadmor, Silverstone, & Diamant, 1995). His study of 19 deliveries in 10 women with a history of retinal pathology, including retinal detachment, retinal holes or lattice degeneration, reported no retinal status changes following unassisted labor and delivery (Landau et al., 1995). Recent studies report no retinal changes after delivery and report that history of eye disease alone, including past retinal detachment, is not an indication for cesarean delivery (Juenemann et al., 2012). This limited data leaves physicians concerned and more likely to intervene during labor in patients with a history of ocular abnormalities. A survey of 185 Obstetricians showed that 57% would recommend assisted delivery after prior surgery for a retinal detachment (Chiu et al., 2015). Twelve of the obstetricians in this study (6%) reported cases of retinal detachments following spontaneous vaginal delivery. The causes of retinal detachment were attributed to severe preeclampsia, prolonged second stage of labor, and an unknown etiology. Prior history of ocular abnormalities was not mentioned as a cause of retinal detachment in this study. To our knowledge, there is one reported case of the maternal outcome of a patient with Stickler syndrome and a history of retinal detachment (Sanderson & Byrd, 2009). This patient presented with PPRM at 32 weeks and 4 days. Following a vacuum-assisted vaginal delivery for fetal indications, there were no visual changes reported.

Our case highlights the importance of accurate genetic diagnosis. Prenatal genetic diagnosis was vital for our patient to inform her pregnancy management. Additionally, this case emphasizes the importance of data-sharing. To our knowledge, this is the second reported case of pregnancy and delivery management in a patient with Stickler syndrome. Because of the rarity of Stickler syndrome, it is important to clinically report management and outcomes in pregnant women with this condition. We propose creating a public database where providers can log their maternal cases of Stickler syndrome, methods of pregnancy management, and pregnancy outcomes, so that other providers can utilize the database as a resource and best provide prenatal care for a patient of their own who may also have the condition. This report adds to the literature providing information to obstetricians, maternal-fetal medicine specialists, geneticists, and ophthalmologists about pregnancy management and outcomes with this rare disease and emphasizes the importance of developing a multi-disciplinary strategy in such patients.

## ACKNOWLEDGMENTS

Search strategy of this work was assessed and reviewed by medical librarian Gary Kaplan, MS.

## CONFLICT OF INTEREST

The authors report no conflict of interest.

## AUTHOR CONTRIBUTIONS

Acquisition of data: JG, SR, MM, and HAK; Analysis and interpretation of data: JG, SR, MM, and HAK; Drafting of manuscript: JG, SR, MM, and HAK; Final approval of the version to be published: JG, SR, MM, and HAK; Agreement to be accountable for all aspects of the study: JG, SR, MM, and HAK.

## DATA AVAILABILITY STATEMENT

Huda B. Al-Kouatly confirms that she had full access to all the data in the study and takes responsibility for the integrity of the data and the accuracy of the data analysis.

## ORCID

Julie Gomez  <https://orcid.org/0000-0002-9011-7637>

Huda B. Al-Kouatly  <https://orcid.org/0000-0003-2922-0333>

## REFERENCES

- Anum, E. A., Hill, L. D., Pandya, A., & Strauss, J. F. 3rd (2009). Connective tissue and related disorders and preterm birth: Clues to genes contributing to prematurity. *Placenta*, 30(3), 207–215. <https://doi.org/10.1016/j.placenta.2008.12.007>
- Chiu, H., Steele, D., McAlister, C., & Lam, W. C. (2015). Delivery recommendations for pregnant females with risk factors for rhegmatogenous retinal detachment. *Canadian Journal of Ophthalmology*, 50(1), 11–18.
- De Vos, M., Nuytinck, L., Verellen, C., & De Paepe, A. (1999). Preterm premature rupture of membranes in a patient with the hypermobility type of the Ehlers-Danlos syndrome. A case report. *Fetal Diagnosis and Therapy*, 14(4), 244–247.
- Gilliam, E., Hoffman, J. D., & Yeh, G. (2020). Urogenital and pelvic complications in the Ehlers-Danlos syndromes and associated hypermobility spectrum disorders: A scoping review. *Clinical Genetics*, 97(1), 168–178.
- Juenemann, A. M., Nowomiejska, K., Oleszczuk, A., Ksiazek, P., Oleszczuk, J., & Rejdak, R. (2012). Mode of delivery and eye diseases. *Ginekologia Polska*, 83(8), 613–617.
- Karthikeyan, A., & Venkat-Raman, N. (2018). Hypermobile Ehlers-Danlos syndrome and pregnancy. *Obstetric Medicine*, 11(3), 104–109.
- Landau, D., Seelenfreund, M. H., Tadmor, O., Silverstone, B. Z., & Diamant, Y. (1995). The effect of normal childbirth on eyes with abnormalities predisposing to rhegmatogenous retinal detachment. *Graefes Archive for Clinical and Experimental Ophthalmology*, 233(9), 598–600.
- Richards, A. J., McNinch, A., Martin, H., Oakhill, K., Rai, H., Waller, S., ... Snead, M. P. (2010). Stickler syndrome and the vitreous phenotype: Mutations in COL2A1 and COL11A1. *Human Mutation*, 31(6), E1461–E1471.

- Robin, N. H., Moran, R. T., & Ala-Kokko, L. (1993). Stickler Syndrome" in GeneReviews(R). In M. P. Adam, H. H. Ardinger, & R. A. Pagon et al (Eds.), *GeneReviews is a registered trademark of the University of Washington, Seattle* (pp. 2–11). Seattle, WA: University of Washington.
- Sanderson, P., & Byrd, L. M. (2009). To push? Or not to push?: Second stage management in a patient with Stickler syndrome at risk of retinal detachment. *Journal of Obstetrics and Gynaecology*, 29(1), 61–62.
- Tompson, S. W., Johnson, C., Abbott, D., Bakall, B., Soler, V., Yanovitch, T. L., ... Young, T. L. (2017). Reduced penetrance in

a large Caucasian pedigree with Stickler syndrome. *Ophthalmic Genetics*, 38(1), 43–50.

**How to cite this article:** GomezJ, Rice SM, Makhamreh MM, Al-Kouatly HB. Pregnancy management in a patient with stickler syndrome. *Mol Genet Genomic Med.* 2020;8:e1311. <https://doi.org/10.1002/mgg3.1311>