

Retreatment of Recurrent Internal Carotid-Posterior Communicating Artery Aneurysm after Coil Embolization

Shingo TOYOTA,¹ Takuyu TAKI,¹ Akatsuki WAKAYAMA,² and Toshiki YOSHIMINE³

¹Department of Neurosurgery, Kansai Rosai Hospital, Amagasaki, Hyogo;

²Department of Neurosurgery, Osaka Neurological Institute, Toyonaka, Osaka;

³Department of Neurosurgery, Osaka University Medical School, Suita, Osaka

Abstract

Internal carotid-posterior communicating artery (IC-PC) aneurysms account for more than 20% of all intracranial aneurysms. As a result of the increase in coiling, there has also been an increase in recurrent IC-PC aneurysms after coiling. We present our experience of 10 recurrent IC-PC aneurysms after coiling that were retreated using surgical or endovascular techniques in order to discuss the choice of treatment and the points of clipping without removal of coils. From 2007 to 2014, 10 recurrent IC-PC aneurysms after coiling were retreated. When the previous frames covered the aneurysms all around or almost around except a part of the neck, coiling was chosen. In other cases, clipping was chosen. Clipping was attempted without removal of coils when it was technically feasible. Among the 10 IC-PC aneurysms retreated, 3 were retreated with coiling and 7 were retreated with clipping. In all three cases retreated with coiling, almost complete occlusion was accomplished. In the seven cases retreated with clipping, coil extrusion was observed during surgery in six cases. In most of them, it was necessary to dissect strong adhesions around the coiled aneurysms and to utilize temporary occlusion of the internal carotid artery. In all seven cases, neck clipping was accomplished without the removal of coils. There were no neurological complications in any cases. The management of recurrent lesions of embolized IC-PC aneurysms requires appropriate choice of treatment using both coiling and clipping. Clipping, especially without the removal of coils, plays an important role in safe treatment.

Key words: retreatment, recurrence, internal carotid-posterior communicating artery aneurysm, coil embolization, clipping

Introduction

Influenced by the good results of coil embolization in several clinical trials for ruptured aneurysms,¹⁾ endovascular treatment has often been selected as the first choice treatment for ruptured aneurysms in Japan. Even in the treatment of unruptured aneurysms, excellent outcomes have been reported similar to those for surgical clipping.²⁾ However, recurrence, which occurs at a certain probability level after coil embolization, is an important problem.^{3–5)} As a result of the increase in endovascular surgeries, we have more frequently experienced recurrent aneurysms after coil embolization.

Many authors have reported that re-coil embolization is safe and efficient for the retreatment of recurrent aneurysms after coil embolization.^{6–8)} On the other hand, surgical clipping is an alternative option for

retreatment, especially in cases unsuitable for coil embolization.^{9–12)} Surgical clipping for recurrent aneurysms after coil embolization is performed with or without removal of previously embolized coils. However, the removal of embolized coils contains some uncertain elements including injury of the parent artery and cerebral ischemia during the procedure.^{11,12)} Therefore, clipping with preservation of the embolized coils is desirable when it is technically feasible.^{11,13)}

Internal carotid-posterior communicating artery (IC-PC) aneurysms are common and account for more than 20% of all intracranial saccular aneurysms currently. Although the microsurgical techniques for IC-PC aneurysms have been well established with progress in intraoperative neuroendoscopy and indocyanine green (ICG) videoangiography,^{14–16)} the rate of endovascular treatment has increased recently. It is, therefore, natural that recurrent IC-PC aneurysms after coil embolization have also

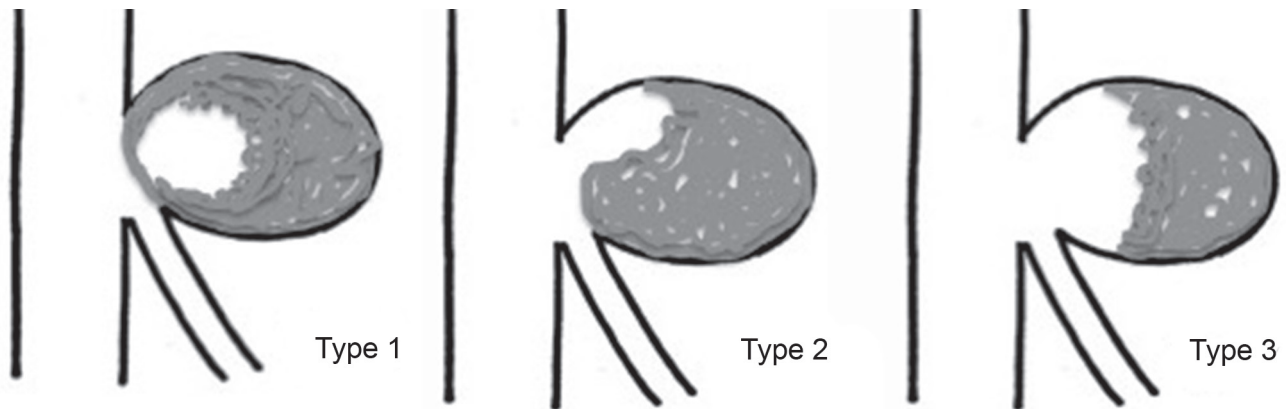


Fig. 1 Schema of the status of the recurrence. The status was classified into three types. Type 1: Previous framing coils covered aneurysms all around. Type 2: Previous framing coils covered aneurysms almost around, except a part of the neck. Type 3: Others.

increased.⁴⁾ Not only endovascular techniques, but also well-established microsurgical techniques are available and play an important role even in the retreatment of recurrent IC-PC aneurysms.

We present our experience of 10 recurrent IC-PC aneurysms after coil embolization that were retreated using surgical or endovascular techniques, in order to discuss the choice of treatment and the points of clipping without the removal of embolized coils.

Materials and Methods

From May 2007 to February 2014, 22 recurrent aneurysms after coil embolization were retreated. All retreatments were performed by the first author (S.T.).

Inclusion criteria for retreatment were as follows. In cases with a rapid increase in recurrent lesions, residuals larger than 30% of the original aneurysm or blebs in the recurrent lesions, additional treatment was considered.

Among the 22 recurrent aneurysms, 10 were IC-PC aneurysms. The choice of treatment for the 10 cases was as follows. When the previous frames covered the aneurysms all around (type 1) or almost around except a part of the neck (type 2), coil embolization was chosen. The stent-assisted technique was not utilized in this series. In other cases, surgical clipping was chosen (type 3) (Fig. 1). Surgical clipping was attempted without removal of embolized coils when it was technically feasible.

In all the cases retreated, the long diameters and the neck size of the aneurysms at initial treatment were measured. In the cases retreated with surgical clipping, the remnant neck height (RNH), the remnant neck width (RNW), and coil width (CW) at recurrence were measured (Fig. 2). The status of the coil embolization at the initial treatment was classified

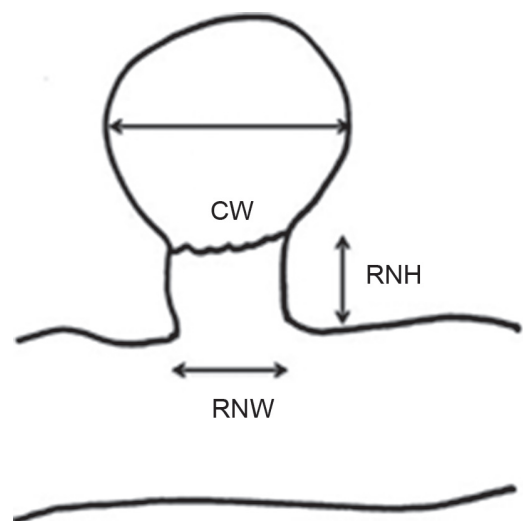


Fig. 2 Schema of the remnant neck parameters. CW: coil width, RNH: remnant neck height, RNW: remnant neck width.

using the Raymond scale.¹⁷⁾ Statistical differences between the groups retreated with endovascular surgery and that with microsurgery, in terms of age, interval to retreatment, and aneurysmal size were evaluated using Student's t-test.

Results

Among the 10 IC-PC aneurysms retreated (female 7, male 3; right side 6, left side 4; ruptured 6, unruptured 4), 3 were retreated with endovascular coiling and 7 were retreated with surgical clipping (Table 1). The average age at initial treatment was 56.5 ± 15.3 years. At the initial treatment, the average long diameter of the aneurysm was 6.5 ± 2.6 mm and the average neck size was 3.3 ± 1.0 mm.

Table 1 Profile of 10 internal carotid-posterior communicating artery aneurysms retreated with an endovascular technique or microsurgical technique

Case no.	Age (y.o.)	Sex	Side	Ruptured or unruptured	Initial size (mm)	Initial neck size (mm)	Initial Raymond scale	Recurrence status	Interval (months)	Result of retreatment
1	69	female	right	unruptured	5.6	3.1	2	type 2	6	almost complete coil embolization
2	61	female	right	ruptured	10.1	4.1	1	type 2	40	almost complete coil embolization
3	70	female	right	unruptured	12.2	4.3	2	type 1	22	almost complete coil embolization
4	63	female	left	ruptured	4.2	5.2	2	type 3	25	neck clipping without removal of coils
5	66	female	right	ruptured	4.9	3.4	2	type 3	22	neck clipping without removal of coils
6	42	male	left	ruptured	5.5	3.3	2	type 3	26	neck clipping without removal of coils
7	32	male	right	ruptured	6.8	2.6	1	type 3	26	neck clipping without removal of coils
8	68	male	left	unruptured	7.5	2.8	2	type 3	36	neck clipping without removal of coils
9	28	female	left	ruptured	4.1	2.1	1	type 3	17	neck clipping without removal of coils
10	66	female	right	unruptured	4.1	2.4	2	type 3	40	neck clipping without removal of coils
Average	56.5				6.5	3.3			26	
SD	15.3				2.6	1.0			10	

SD: standard deviation.

The status of coil embolization at the initial treatment was three cases of Raymond scale 1 and seven cases of Raymond scale 2. The status of recurrence using our schema was one case of type 1, two cases of type 2, and seven cases of type 3. The average interval to retreatment was 26 ± 10 months. There were no neurological complications in any of the retreatments. No aneurysms required "re-retreatment" during the follow-up period.

In the three cases treated with an endovascular technique (female 3, male 0; right side 3, left side 0; ruptured 1, unruptured 2), the average age at initial treatment was 64.7 ± 4.9 years. At the initial treatment, the average long diameter of the aneurysm was 8.8 ± 3.4 mm. The status of coil embolization at the initial treatment was one case of Raymond scale 1 and two cases of Raymond scale 2. The status of recurrence using our schema was one case of type 1 and two cases of type 2. The average interval to retreatment was 29 ± 17 months. In coil embolization of type 1, coil filling was performed into the framing coils previously embolized. In type 2, coil filling was performed after an additional frame was formed at the remnant neck. In all three cases, almost complete occlusion was accomplished.

In the seven cases treated with a microsurgical technique (female 4, male 3; right side 3, left side 4; ruptured 5, unruptured 2), the average age at initial treatment was 52.1 ± 17.5 years (Table 2). At the initial treatment, the average long diameter of the aneurysm was 5.3 ± 1.4 mm. The status of coil embolization at the initial treatment was two cases of Raymond scale 1 and five cases of Raymond scale 2. The status of recurrence using our schema was all type 3 cases. The average interval to retreatment was 27 ± 8 months. At recurrence, the average of RNH

was 2.6 ± 0.4 mm, the average of RNW was 3.2 ± 1.0 mm, and the average of CW was 3.8 ± 0.8 mm. The average of RNW/RNH was 1.3 ± 0.4 . The average of CW/RNH was 1.5 ± 0.3 . Coil extrusion was observed during surgery in six cases (5 initially ruptured cases, 1 initially unruptured case). In all seven cases, neck clipping was accomplished without removal of embolized coils. The patency of the posterior communicating (P-Com) artery was confirmed using ICG videoangiography.

There were no statistical differences between the groups retreated with endovascular surgery and that with microsurgery in terms of age, interval to retreatment, and aneurysmal size (Student's t-test).

Illustrated Cases

I. Case 2

A 61-year-old woman presented with subarachnoid hemorrhage (Hunt and Hess Grade 4). On the onset day, she underwent coil embolization of a ruptured right IC-PC aneurysm. The initial size of the aneurysm was 10.1 mm. The status of the coil embolization was Raymond scale 1. Approximately 3 years and 4 months after the initial treatment, coil compaction was found (Fig. 3A). The status of the recurrence was classed as type 2 based on our schema, and endovascular treatment was planned. In coil embolization, coil filling was performed after an additional frame was formed at the remnant neck. Finally, almost complete embolization was accomplished (Fig. 3B).

II. Case 3

A 70-year-old woman underwent coil embolization for a right IC-PC aneurysm revealed by cerebral

Table 2 Profile of seven IC-PC right internal carotid-posterior communicating artery aneurysms retreated with a microsurgical technique

Case no.	Age (y.o.)	Sex	RNH (mm)	RNW (mm)	CW (mm)	RNW/RNH	CW/RNH	Coil extrusion
4	63	female	2.8	5.5	3.3	2	1.2	(+)
5	66	female	2.3	3.5	4.5	1.5	2	(+)
6	42	male	2.4	3.5	4.5	1.5	1.9	(+)
7	32	male	2.8	2.7	4.4	0.96	1.6	(+)
8	68	male	3.4	2.9	4.4	0.85	1.3	(-)
9	28	female	2.1	2.1	2.6	1	1.2	(+)
10	66	female	2.2	2.5	2.7	1.1	1.2	(+)
Average	52.1		2.6	3.2	3.8	1.3	1.5	
SD	16.2		0.4	1	0.8	0.4	0.33	

CW: coil width at recurrence, RNH: remnant neck height at recurrence, RNW: remnant neck width at recurrence, SD: standard deviation.

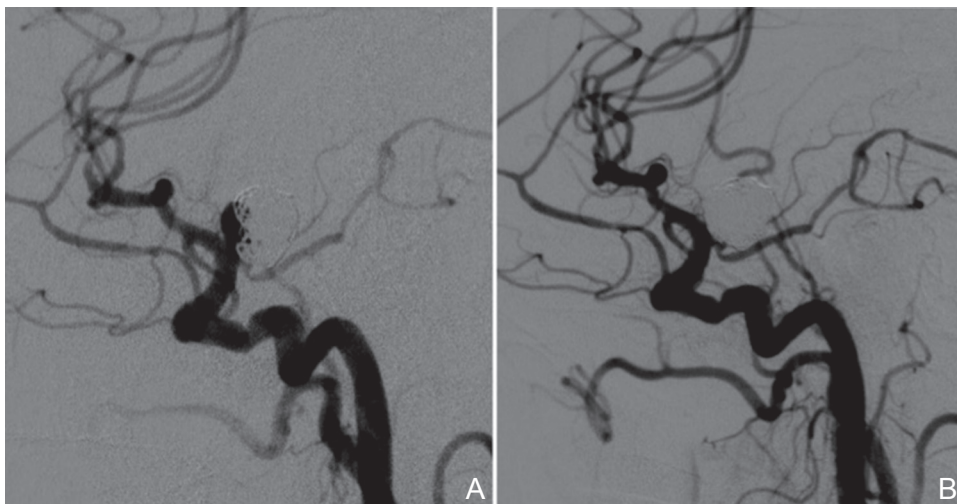

Fig. 3 Case 2: A 61-year-old woman. **A:** Approximately 3 years and 4 months after initial coil embolization for a ruptured right internal carotid-posterior communicating artery aneurysm, coil compaction was found on lateral angiography. **B:** Coil filling was performed after an additional frame was formed at the remnant neck.

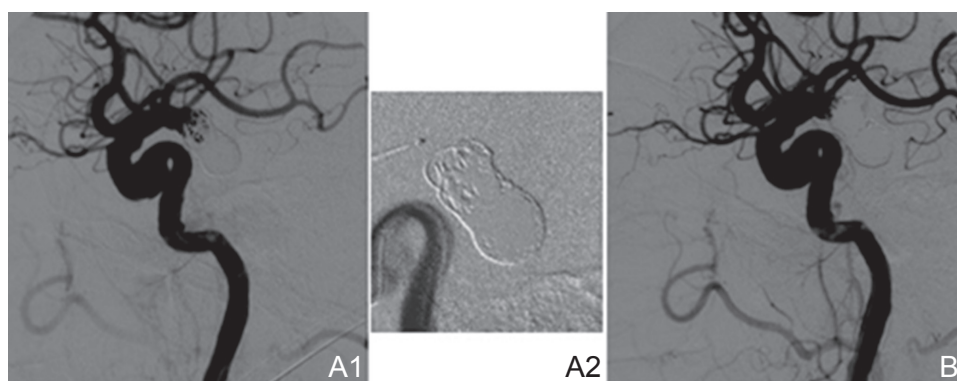


Fig. 4 Case 3: A 70-year-old woman. **A1:** Approximately 1 year and 10 months after initial coil embolization for an unruptured right internal carotid-posterior communicating artery aneurysm, coil compaction was observed on lateral angiography. **A2:** The previous framing coils covered the aneurysm all around. **B:** Coil filling was performed into the framing coils previously embolized.

magnetic resonance angiography at a medical checkup. The initial size of the aneurysm was 12.2 mm. The status of the coil embolization was Raymond scale 2. Approximately 1 year and 10 months after the initial treatment, coil compaction was found (Fig. 4A1). The status of the recurrence was classed as type 1 based on our schema (Fig. 4A2), and endovascular treatment was planned. In coil embolization, coil filling was performed into the framing coils previously embolized. Finally, almost complete embolization was accomplished (Fig. 4B).

III. Case 6

A 42-year-old man presented with subarachnoid hemorrhage (Hunt and Hess Grade 2). On the onset day, he underwent coil embolization of a ruptured left IC-PC aneurysm. The initial size of the aneurysm was 5.5 mm. The status of the coil embolization was Raymond scale 2. Approximately 2 years and 2 months after the initial treatment, an increase of the remnant neck was found (Fig. 5A). The height of the remnant was 2.4 mm and the width was 3.5 mm. The status of the recurrence was classed

as type 3 based on our schema, and neurosurgical clipping was planned.

In the operative findings, extrusion of previously embolized coils was observed (Fig. 5B). Strong adhesions between the aneurysmal dome and the tentorial dura were dissected using a careful microsurgical technique. Under temporal occlusion of the internal carotid artery (ICA), neck clipping was performed without removal of previously embolized coils (Fig. 5C, D).

IV. Case 8

A 68-year-old man underwent coil embolization for a left IC-PC aneurysm revealed by cerebral magnetic resonance angiography at a medical checkup. The initial size of the aneurysm was 7.5 mm. The status of the coil embolization was Raymond scale 2. Approximately 3 years after the initial treatment, an increase in the remnant neck was observed (Fig. 6A). The height of the remnant neck was 3.4 mm and the width was 2.9 mm. The status of the recurrence was classed as type 3 based on our schema, and neurosurgical clipping was planned.

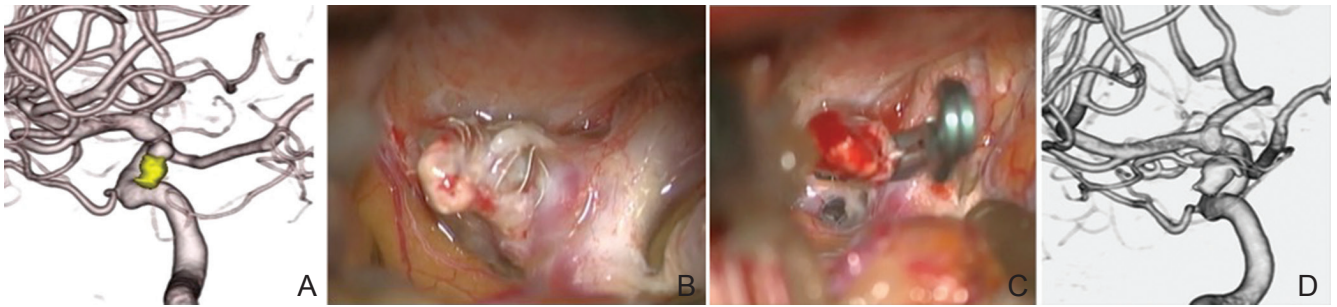


Fig. 5 Case 6: A 42-year-old man. A: Approximately 2 years and 2 months after initial coil embolization for a ruptured left internal carotid-posterior communicating artery aneurysm, an increase in the remnant neck was found on volume rendering three-dimensional (3D) digital subtraction angiography images. B: In the operative findings, extrusion of previously embolized coils was observed. C: Neck clipping was performed. D: Neck clipping without removal of previously embolized coils was confirmed with left posterior oblique view of volume rendering post-operative 3D digital subtraction angiography images.

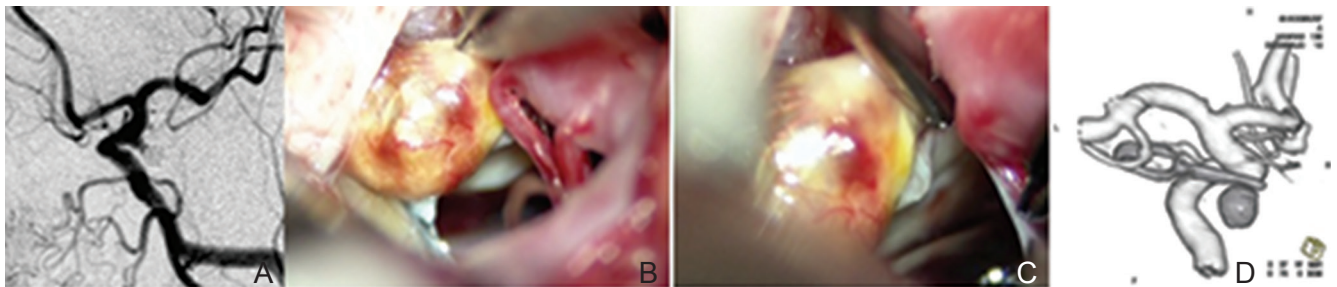


Fig. 6 Case 8: A 68-year-old man. A: Approximately 3 years after initial coil embolization for an unruptured left internal carotid-posterior communicating artery aneurysm, an increase in the remnant neck was found on left anterior oblique angiography. B: In the operative findings, extrusion of previously embolized coils was not observed. C: Neck clipping was performed. D: Neck clipping without removal of previously embolized coils was confirmed with left posterior oblique view of volume rendering post-operative three-dimensional digital subtraction angiography images.

In the operative findings, extrusion of previously embolized coils was not observed (Fig. 6B). Under temporal occlusion of the ICA, neck clipping was performed without removal of previously embolized coils (Fig. 6C, D).

V. Case 9

A 28-year-old woman presented with subarachnoid hemorrhage (Hunt and Hess Grade 2). On the onset day, coil embolization of a ruptured left IC-PC aneurysm was performed. The initial size of the aneurysm was 4.1 mm. The status of the coil embolization was Raymond scale 1. Approximately 1 year and 5 months after the initial treatment, an increase of the remnant neck was observed (Fig. 7A). The height of the remnant was 2.1 mm and the width was 2.1 mm. The status of the recurrence was classed as type 3 based on our schema, and neurosurgical clipping was planned.

In the operative findings, extrusion of previously embolized coils was observed (Fig. 7B). Strong

adhesions between the connective tissue around the exposed coils and the oculomotor nerve were dissected using a careful microsurgical technique. Under temporal occlusion of the ICA, neck clipping was performed without removal of previously embolized coils (Fig. 7C, D).

VI. Case 10

A 66-year-old woman underwent coil embolization for a right IC-PC aneurysm revealed by cerebral magnetic resonance angiography at a medical checkup. The initial size of the aneurysm was 4.1 mm. The status of the coil embolization was Raymond scale 2. Approximately 3 years and 4 months after the initial treatment, an increase in the remnant neck was found (Fig. 8A). The height of the remnant was 2.2 mm and the width was 2.5 mm. The status of the recurrence was classed as type 3 based on our schema, and neurosurgical clipping was planned.

In the operative findings, extrusion of previously embolized coils was observed (Fig. 8B). Adhesions

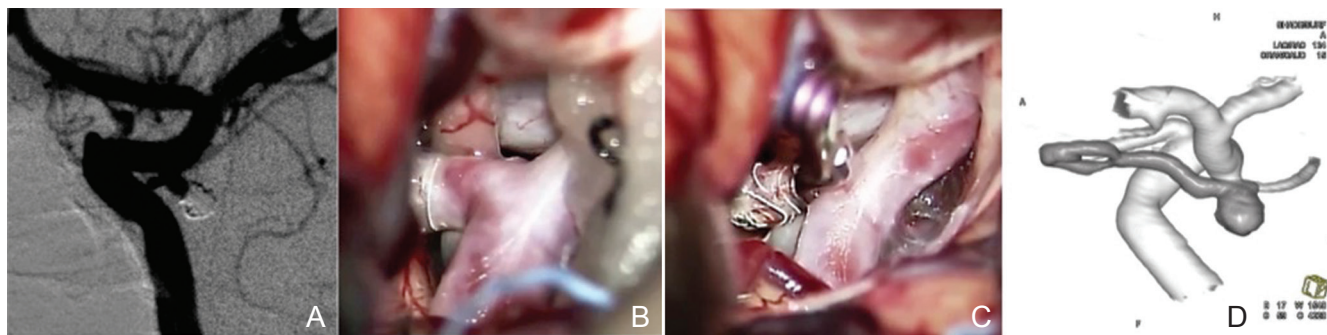


Fig. 7 Case 9: A 28-year-old woman. A: Approximately 1 year and 5 months after initial coil embolization for a ruptured left internal carotid-posterior communicating artery aneurysm, an increase in the remnant neck was evident on left anterior oblique angiography. B: In the operative findings, extrusion of previously embolized coils was observed. C: Neck clipping was performed. D: Neck clipping without removal of previously embolized coils was confirmed with left posterior oblique view of volume rendering post-operative three-dimensional digital subtraction angiography images.

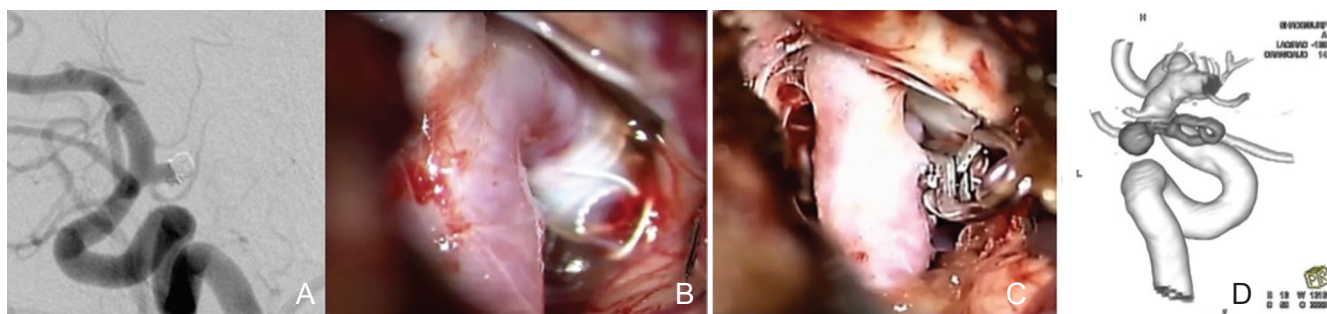


Fig. 8 Case 10: A 66-year-old woman. A: Approximately 3 years and 4 months after initial coil embolization for an unruptured right internal carotid-posterior communicating artery aneurysm, an increase in the remnant neck was evident on lateral angiography. B: In the operative findings, extrusion of previously embolized coils was observed. C: Neck clipping was performed. D: Neck clipping without removal of previously embolized coils was confirmed with right posterior oblique view of volume rendering post-operative three-dimensional digital subtraction angiography images.

between the exposed coils and the oculomotor nerve were dissected using a careful microsurgical technique. Under temporal occlusion of the ICA, neck clipping was performed without removal of previously embolized coils (Fig. 8C, D).

Discussion

In the CARAT study, the annual retreatment rates after coil embolization were 13.3%, 4.5%, and 1.1% during the first, second, and later years, respectively, but the annual re-rupture rate, which was reported at 0.11%,³⁾ after endovascular treatment was low. Byrne et al. reported a rebleeding rate of 0.4% for stable nonprogressing aneurysmal remnants after endovascular treatment, but also reported a 7.9% rebleeding rate for angiographically unstable aneurysm residuals.^{18,19)} Therefore, management of residual and recurrent lesions of embolized

cerebral aneurysms requires careful follow-up using neuroimaging modalities, and active decisions for additional treatment. In our institute, follow-up angiography or magnetic resonance angiography was obtained every 6 months postembolization. In retreatment of recurrent aneurysms, it is desirable to adopt a safe procedure because the results of the retreatment should be superior to the outcome of observation only.

IC-PC aneurysms are common and currently account for more than 20% of all intracranial saccular aneurysms. Although the microsurgical techniques for IC-PC aneurysms have been well established with the progress of intraoperative neuroendoscopy and ICG videoangiography,^{14–16)} the rate of endovascular treatment has increased recently. It is natural that recurrent IC-PC aneurysms after coil embolization have also increased and occupy a high rate among all recurrent aneurysms. In our series, we experienced

10 IC-PC aneurysms (45%) among 22 aneurysms retreated. Not only endovascular techniques, but also well-established microsurgical techniques, are available and play an important role even in the retreatment of recurrent IC-PC aneurysms.

As a retreatment of recurrent aneurysms after coil embolization, re-coil embolization is safe and efficient. There have been many reports that coil embolization is adopted as first choice for the treatment of recurrent aneurysms.⁶⁻⁸⁾ However, it is well known that not all the configurations of recurrent aneurysms are suitable for coil embolization. Especially, in cases unsuitable for coil embolization, surgical clipping can be an alternative option.^{9,12)} In this study, the choice of the retreatment depended on the morphology of the remnant neck, as we presented in the schema. Due to this strategy, cases that may have been considered to be difficult for clipping without extraction of embolized coils were treated using coil embolization. In this series, type 1 and type 2 included the aneurysms that were difficult for clipping without removal of embolized coils. As a result, straightforward cases for neck clipping, with preserving previous coils, could be selected. This is one of the reasons why we did not experience extraction of embolized coils during clipping surgery in this study. We think that our strategy could reduce the rate of clipping with extraction of embolized coils, which may be associated with high morbidity.

In this study, the strategy of the treatment depended on the morphology of the recurrent aneurysms. However, another important concept is that the choice of treatment should be based on the cause of the recurrence.^{9,12)} Coiling may be an efficient retreatment when the main cause of the recurrence is coil compaction. However, when the main cause of the recurrence is regrowth, surgical clipping may be better than coiling from a curability viewpoint. In view of these findings, Dorfer et al. have adopted a policy of surgical management for aneurysm recurrences from aneurysm regrowth whenever technically feasible. On the other hand, they reported that aneurysm recurrences from mechanical coil compaction, without significant changes in size and morphology, were successfully treated using endovascular techniques in their series.¹²⁾ We think that the cause of the recurrence is one of the important factors when deciding the retreatment modality because we should consider not only safety, but also curability.

We agree that stent-assisted coil embolization is a very suitable technique for the treatment of recurrent aneurysms after coil embolization. In addition, utilization of a stent or flow diverter may

expand the indication of endovascular surgery for retreatment although we should consider the risks of thromboembolic complications or dual antiplatelet therapy.²⁰⁾ However, we did not utilize a stent-assisted technique in this study because the benefit was thought to be limited as the P-Com artery originated from the neck in most of the IC-PC aneurysms.

Surgical clipping for recurrent aneurysms after coil embolization is performed with or without the removal of previously embolized coils. In surgical clipping for recurrent aneurysms after coil embolization, removal of previously embolized coils may help to secure enough space for neck clipping, but it contains uncertain and complex elements.¹⁰⁻¹²⁾ Coil extraction during microsurgery for recanalized intracranial aneurysms can be associated with high morbidity.¹¹⁾ Dorfer et al. reported that opening the aneurysm and attempted coil removal resulted in aneurysm rupture at the neck and ultimately led to sacrifice of the ICA in one patient operated on 4 years after the first embolization.¹²⁾ Because extraction of embolized coils may require temporary occlusion of the parent artery or bypass surgery, or may cause intimal injury of the parent artery, clipping without removal of embolized coils is preferable when it is technically feasible.

Predicting whether coil extraction during microsurgery may be necessary has significant implications during preoperative planning.^{9-13,21,22)} For safe neck clipping without removal of embolized coils, the remnant neck should be "tall" in order to allow enough space for neck clipping.^{9,10,22)} Waldron et al. evaluated the ratio of coil width to compaction height (C:H ratio) at retreatment. They suggested that aneurysms with a C:H ratio greater than 2.5 or with minimal compaction (compaction height < 2 mm) were not amenable to clipping without removal of embolized coils.¹⁰⁾ In all the cases retreated using a microsurgical technique in our series, the C:H ratio was less than 2.5 and compaction height more than 2 mm. With our strategy in this study, cases that may have been thought to be difficult for clipping without extraction of embolized coils were treated using coil embolization. As a result, the spaces of the remnant neck for application of a surgical clip may have been enough in the aneurysms treated using a surgical technique. We thought that, even in a small aneurysms series, the height of the neck should be more than 2 mm at least. Otherwise, neck clipping without removal of coils should not be performed.

We should keep in mind that whether or not neck clipping without removal of coils is possible not only depends on the height of the neck, but also on the size of the aneurysm. Especially, in large or giant

aneurysms, the coiled aneurysm prevents observation or dissection of the neck, and the possibility of neck clipping without removal of coils is thought to be low. The fact that the sizes of the aneurysms were relatively small in this study is one of the reasons why we did not experience extraction of embolized coils during clipping surgery.

During surgical procedures, dissection all around aneurysms is not always straightforward because the coil mass cannot be reduced even if we use temporary occlusion of the parent artery. The difficulties associated with microsurgical clip ligation of aneurysms previously treated via endovascular means was already reported by several authors.^{10–13,22)} Tough arachnoid scarring and adhesions surrounding the coiled aneurysms can complicate dissection, and extrusion of the coil into the subarachnoid space and cerebral parenchyma is frequently observed.²³⁾ Coiled aneurysms are relatively immobile, making dissection and visualization in the area around them more difficult.^{10–13,22)} In IC-PC aneurysms, the connective tissue around the exposed coils sometimes adheres to the oculomotor nerve. Because clipping without dissection of this adhesion may damage the oculomotor nerve due to strong torque from the manipulation in applying the clips, the coiled aneurysms should be mobile from the oculomotor nerve.

As neck clipping without removal of coils may cause a longitudinal stretch force along the neck, it is better to prepare temporary occlusion of the parent artery. Also, a donor artery, such as the superficial temporal artery, for bypass surgery should be prepared in case of temporary occlusion of the parent artery during extraction of coils.^{10–13)} During application of the aneurysm clip, it is not necessary to close and release clips many times in order to prevent thromboembolic events because all the recurrent aneurysms after coil embolization are thought to be “thrombosed aneurysms.”

In this study, several limitations should be noted. First, the number of aneurysms was small. Second, the diameters of the aneurysms were relatively small. In large or giant aneurysms, the possibility of neck clipping without removal of coils is thought to be low. The annual retreatment rate after coil embolization was highest during the first year in the CARAT study,³⁾ but in our study it was highest during the third year and the average interval to retreatment was 26 ± 10 months. In our study, retreatment rate during the first year was relatively low because we rarely experienced the cases that needed retreatment in acute or subacute stage. Because the choice of retreatment strongly depended on the individual skills of microsurgery and endovascular surgery

in this study, it is desirable to establish objective criteria for the choice of retreatment.

Conclusion

Management of recurrent lesions of embolized IC-PC aneurysms requires appropriate choice of treatment using both endovascular and surgical techniques. Surgical clipping, especially without removal of embolized coils, plays an important role in safe treatment.

Conflicts of Interest Disclosure

Nothing to report.

References

- 1) Molyneux A, Kerr R, Stratton I, Sandercock P, Clarke M, Shrimpton J, Holman R; International Subarachnoid Aneurysm Trial (ISAT) Collaborative Group: International Subarachnoid Aneurysm Trial (ISAT) of neurosurgical clipping versus endovascular coiling in 2143 patients with ruptured intracranial aneurysms: a randomised trial. *Lancet* 360: 1267–1274, 2002
- 2) Shigematsu T, Fujinaka T, Yoshimine T, Imamura H, Ishii A, Sakai C, Sakai N; JR-NET Investigators: Endovascular therapy for asymptomatic unruptured intracranial aneurysms: JR-NET and JR-NET2 findings. *Stroke* 44: 2735–2742, 2013
- 3) CARAT Investigators: Rates of delayed rebleeding from intracranial aneurysms are low after surgical and endovascular treatment. *Stroke* 37: 1437–1442, 2006
- 4) Campi A, Ramzi N, Molyneux AJ, Summers PE, Kerr RS, Sneade M, Yarnold JA, Rischmiller J, Byrne JV: Retreatment of ruptured cerebral aneurysms in patients randomized by coiling or clipping in the International Subarachnoid Aneurysm Trial (ISAT). *Stroke* 38: 1538–1544, 2007
- 5) Molyneux AJ, Kerr RS, Birks J, Ramzi N, Yarnold J, Sneade M, Rischmiller J; ISAT Collaborators: Risk of recurrent subarachnoid haemorrhage, death, or dependence and standardised mortality ratios after clipping or coiling of an intracranial aneurysm in the International Subarachnoid Aneurysm Trial (ISAT): long-term follow-up. *Lancet Neurol* 8: 427–433, 2009
- 6) Slob MJ, Sluzewski M, van Rooij WJ, Roks G, Rinkel GJ: Additional coiling of previously coiled cerebral aneurysms: clinical and angiographic results. *AJNR Am J Neuroradiol* 25: 1373–1376, 2004
- 7) Kang HS, Han MH, Kwon BJ, Kwon OK, Kim SH: Repeat endovascular treatment in post-embolization recurrent intracranial aneurysms. *Neurosurgery* 58: 60–70; discussion 60–70, 2006
- 8) van Rooij WJ, Sprengers ME, Sluzewski M, Beute GN: Intracranial aneurysms that repeatedly reopen

- over time after coiling: imaging characteristics and treatment outcome. *Neuroradiology* 49: 343–349, 2007
- 9) Kai Y, Hamada J, Morioka M, Yano S, Nakamura H, Makino K, Kuratsu J: Re-treatment of patients with embolized ruptured intracranial aneurysms. *Surg Neurol* 70: 378–385, 2008
 - 10) Waldron JS, Halbach VV, Lawton MT: Microsurgical management of incompletely coiled and recurrent aneurysms: trends, techniques, and observations on coil extrusion. *Neurosurgery* 64: 301–315; discussion 315–317, 2009
 - 11) Romani R, Lehto H, Laakso A, Horcajadas A, Kivisaari R, von und zu Fraunberg M, Niemelä M, Rinne J, Hernesniemi J: Microsurgery for previously coiled aneurysms: experience with 81 patients. *Neurosurgery* 68: 140–153; discussion 153–154, 2011
 - 12) Dorfer C, Gruber A, Standhardt H, Bavinzski G, Knosp E: Management of residual and recurrent aneurysms after initial endovascular treatment. *Neurosurgery* 70: 537–553; discussion 553–554, 2012
 - 13) Izumo T, Matsuo T, Morofuji Y, Hiu T, Horie N, Hayashi K, Nagata I: Microsurgical clipping for recurrent aneurysms after initial endovascular coil embolization. *World Neurosurg* 83: 211–218, 2015
 - 14) Kinouchi H, Yanagisawa T, Suzuki A, Ohta T, Hirano Y, Sugawara T, Sasajima T, Mizoi K: Simultaneous microscopic and endoscopic monitoring during surgery for internal carotid artery aneurysms. *J Neurosurg* 101: 989–995, 2004
 - 15) Raabe A, Nakaji P, Beck J, Kim LJ, Hsu FP, Kamerman JD, Seifert V, Spetzler RF: Prospective evaluation of surgical microscope-integrated intraoperative near-infrared indocyanine green videoangiography during aneurysm surgery. *J Neurosurg* 103: 982–989, 2005
 - 16) Toyota S, Taki T, Wakayama A, Yoshimine T: Unruptured internal carotid-posterior communicating artery aneurysm splitting the oculomotor nerve: a case report and literature review. *J Neurol Surg Rep* 75: e180–e182, 2014
 - 17) Roy D, Milot G, Raymond J: Endovascular treatment of unruptured aneurysms. *Stroke* 32: 1998–2004, 2001
 - 18) Byrne JV, Sohn MJ, Molyneux AJ, Chir B: Five-year experience in using coil embolization for ruptured intracranial aneurysms: outcomes and incidence of late rebleeding. *J Neurosurg* 90: 656–663, 1999
 - 19) Byrne JV: The aneurysm “clip or coil” debate. *Acta Neurochir (Wien)* 148: 115–120, 2006
 - 20) Tähtinen OI, Manninen HI, Vanninen RL, Rautio R, Haapanen A, Seppänen J, Niskakangas T, Rinne J, Keski-Nisula L: Stent-assisted embolization of recurrent or residual intracranial aneurysms. *Neuroradiology* 55: 1221–1231, 2013
 - 21) Lejeune JP, Thines L, Taschner C, Bourgeois P, Henon H, Leclerc X: Neurosurgical treatment for aneurysm remnants or recurrences after coil occlusion. *Neurosurgery* 63: 684–691; discussion 691–692, 2008
 - 22) Bulsara KR, Hoh B, Rosen C, Tanikawa R, Carpenter J: Preliminary observation on predicting the need for coil extraction during microsurgery: the clip-coil ratio. *Acta Neurochir (Wien)* 152: 431–434, 2010
 - 23) Mizoi K, Yoshimoto T, Takahashi A, Nagamine Y: A pitfall in the surgery of a recurrent aneurysm after coil embolization and its histological observation: technical case report. *Neurosurgery* 39: 165–168; discussion 168–169, 1996

Address reprint requests to: Shingo Toyota, Department of Neurosurgery, Kansai Rosai Hospital, 3-1-69 Inabaso, Amagasaki, Hyogo 660-8511, Japan.
e-mail: stshto@aol.com