

# Surgical management of delayed Gartland type III supracondylar humeral fractures in children

## A retrospective comparison of radial external fixator and crossed pinning

Jin Li, MD, PhD<sup>a</sup>, Saroj Rai, MD, PhD<sup>b</sup>, Xin Tang, MD, PhD<sup>a</sup>, Renhao Ze, MD<sup>a</sup>, Ruikang Liu, MD<sup>c</sup>, Pan Hong, MD, PhD<sup>a,\*</sup>

### Abstract

Radial external fixator has been proposed to treat delayed irreducible Gartland type III supracondylar humeral fracture, and this study aims to compare its effects with crossed pinning in a retrospective fashion. Delayed supracondylar humeral fracture is defined as more than 72 hours after injury, 2 or more than 2 times failed attempts of closed reduction can be deemed as irreducible fracture.

Between January 2010 and January 2017, patients of Gartland type III supracondylar fractures of the humerus receiving surgery were all selected and reviewed. Overall, 39 patients fitting the inclusion criteria were chosen for the External Fixator Group and patients for control group of crossed pinning with matched age, sex, and clinical parameters (fracture location, injured side, and fracture type) were selected from the database. Surgery duration, number of intraoperative X-ray images, incidence of ulnar nerve injury, postoperative redisplacement, and function of the elbow joint were recorded and analyzed.

In this study, 39 patients treated with radial external fixator had significantly shorter surgery duration, fewer intraoperative X-ray images, and lower incidence of ulnar nerve injury, and postoperative redisplacement than those receiving crossed pinning. Patients in 2 groups displayed similar range of motion for elbow joint at follow-up.

Radial external fixator is an effective and safe method to treat Gartland type III supracondylar fractures that were diagnosed late.

**Abbreviations:** BA = Baumann angle, CA = carrying angle, CRPP = closed reduction followed by percutaneous pinning, ExFix = external fixation, ROM = range of motion, SHF = supracondylar humeral fractures.

**Keywords:** delayed supracondylar fracture, external fixator, crossed pinning

### 1. Introduction

Supracondylar humeral fractures (SHFs) are among the most common injuries in children.<sup>[1]</sup> Most cases should be reduced and fixated as emergent or urgent operation. But in developing countries, the paucity of full-time pediatric orthopedic surgeon

makes this approach impossible. The definition of delayed SHFs varies in the literature; however, we regarded SHFs beyond 72 hours of injury as delayed SHFs.

Closed reduction followed by percutaneous pinning (CRPP) is the treatment of choice for fresh SHFs yielding excellent outcome in children.<sup>[2]</sup> Crossed pinning configuration (Fig. 1A) provides better stability than lateral entry Kirschner wiring (K-wiring); however, it carries the risk of iatrogenic injury to the ulnar nerve.<sup>[3,4]</sup> Delayed Gartland type III supracondylar fracture is more difficult to be manually reduced than the fresh one (within 8 hours after injury). Pin tract infection and K-wire migration with subsequent loss of reduction are the most frequently observed.

When closed reduction cannot be achieved by such techniques in displaced supracondylar fractures especially in delayed cases, external fixator (ExFix) technique consisting of Schanz screws and antirotation K-wire was proposed by certain authors. Two techniques, including humero-ulnar elbow bridging technique and lateral humero-humero external fixation technique, have been reported by Gris et al and Slongo, respectively.<sup>[5,6]</sup>

Closed reduction for supracondylar fractures is still the first choice for the majority of the pediatric orthopedic surgeons. However, Open reduction and internal fixation (ORIF) is indicated if the displaced fragment cannot be reduced by CRPP in 1 or 2 attempts under general anesthesia. But ORIF in delayed supracondylar fracture is associated with a number of complications, including joint stiffness and myositis ossificans.<sup>[3]</sup> Therefore, humero-humero external fixator (Fig. 1B) was put into use for delayed cases since 2010 in our medical center.

Editor: Johannes Mayr.

The authors have no funding and conflicts of interest to disclose.

<sup>a</sup>Department of Orthopaedic surgery, Union Hospital, Tongji Medical College, Huazhong University of Science and Technology, Wuhan, China, <sup>b</sup>Department of Orthopaedics and Trauma Surgery, National Trauma Center, National Academy of Medical Sciences, Kathmandu, Nepal, <sup>c</sup>First School of Clinical Medicine, Tongji Medical College, Huazhong University of Science and Technology, Wuhan, China.


\*Correspondence: Pan Hong, Department of Orthopaedic surgery, Union Hospital, Tongji Medical College, Huazhong University of Science and Technology, Wuhan 430022, China (e-mail: hongpan2013@foxmail.com).

Copyright © 2020 the Author(s). Published by Wolters Kluwer Health, Inc. This is an open access article distributed under the terms of the Creative Commons Attribution-Non Commercial License 4.0 (CCBY-NC), where it is permissible to download, share, remix, transform, and buildup the work provided it is properly cited. The work cannot be used commercially without permission from the journal.

How to cite this article: Li J, Rai S, Tang X, Ze R, Liu R, Hong P. Surgical management of delayed Gartland type III supracondylar humeral fractures in children: a retrospective comparison of radial external fixator and crossed pinning. *Medicine* 2020;99:10(e19449).

Received: 3 April 2019 / Received in final form: 4 February 2020 / Accepted: 5 February 2020

<http://dx.doi.org/10.1097/MD.00000000000019449>



**Figure 1.** Illustration of 2 fixation techniques for supracondylar humeral fracture in children. (A) Crossed pinning. (B) Radial external fixator with 1 antirotation Kirschner wire.

As a tertiary medical center, most pediatric patients in our hospital are referred from outside, and sometimes the patients get admitted several days after the injury. The delayed injury (over 72 hours) is usually associated with significant soft tissue swelling; in such case, CRPP might not be a better option to achieve adequate reduction.

To verify the hypothesis that radial external fixator is superior to crossed K-wire in the treatment of delayed supracondylar fractures, this study was initiated.

## 2. Materials and methods

### 2.1. Study population

We conducted a retrospective review of patients managed with either external fixation (ExFix) method or CRPP with crossed pinning for Gartland type III supracondylar fracture between January 2010 and January 2017. Thirty-nine patients in each group with matched age, sex, and fracture characteristics were included in the study (Table 1). The preoperative data, including baseline information of the patients, fracture pattern, and types of surgical procedure were collected from the hospital database, and postoperative data were collected during the follow-up visit at the outpatient clinic.

Inclusion criteria were as follows: aged 14 years or younger; Gartland type III fracture, without concomitant injury in the ipsilateral upper extremity; 2-part fracture without comminution or with slight comminution; surgical intervention after 72 hours

of injury; and a follow-up period of more than 12 months. Exclusion criteria comprised: patients aged more than 14 years; severely comminuted fractures; fractures associated with neurovascular injuries requiring ORIF; and pathologic fractures and open fractures.

This study was approved by the Ethics Committee of Tongji Medical College, Huazhong University of Science and Technology (IORG no: IORG0003571) on June 1, 2016. Written consent was obtained from the patient's legal guardians.

### 2.2. Surgical procedures

All the surgeries were performed by a senior surgeon under general anesthesia without a pneumatic tourniquet. With the patient supine, the injured limb was placed on the radiolucent table.

The procedures for ExFix group (Fig. 2) were performed as described by Slongo.<sup>[6]</sup> Before reduction of the fracture, a single Schanz screw was inserted into the lateral aspect of the distal fragment of fracture was inserted under fluoroscopy. The screw was usually inserted in the metaphysis just distal to the fracture line. However, if the fracture was low, it might be inserted intraepiphyseal. A 2nd Schanz screw was inserted independently about 2 cm proximal to the fracture line at the proximal end of the lateral supracondylar ridge in the sagittal plane perpendicular to the long axis of the humeral diaphysis. The surgeon should be careful not to injure the radial nerve as it courses anteriorly after crossing the lateral supracondylar ridge at the diaphyseal-metaphyseal junction.

**Table 1**

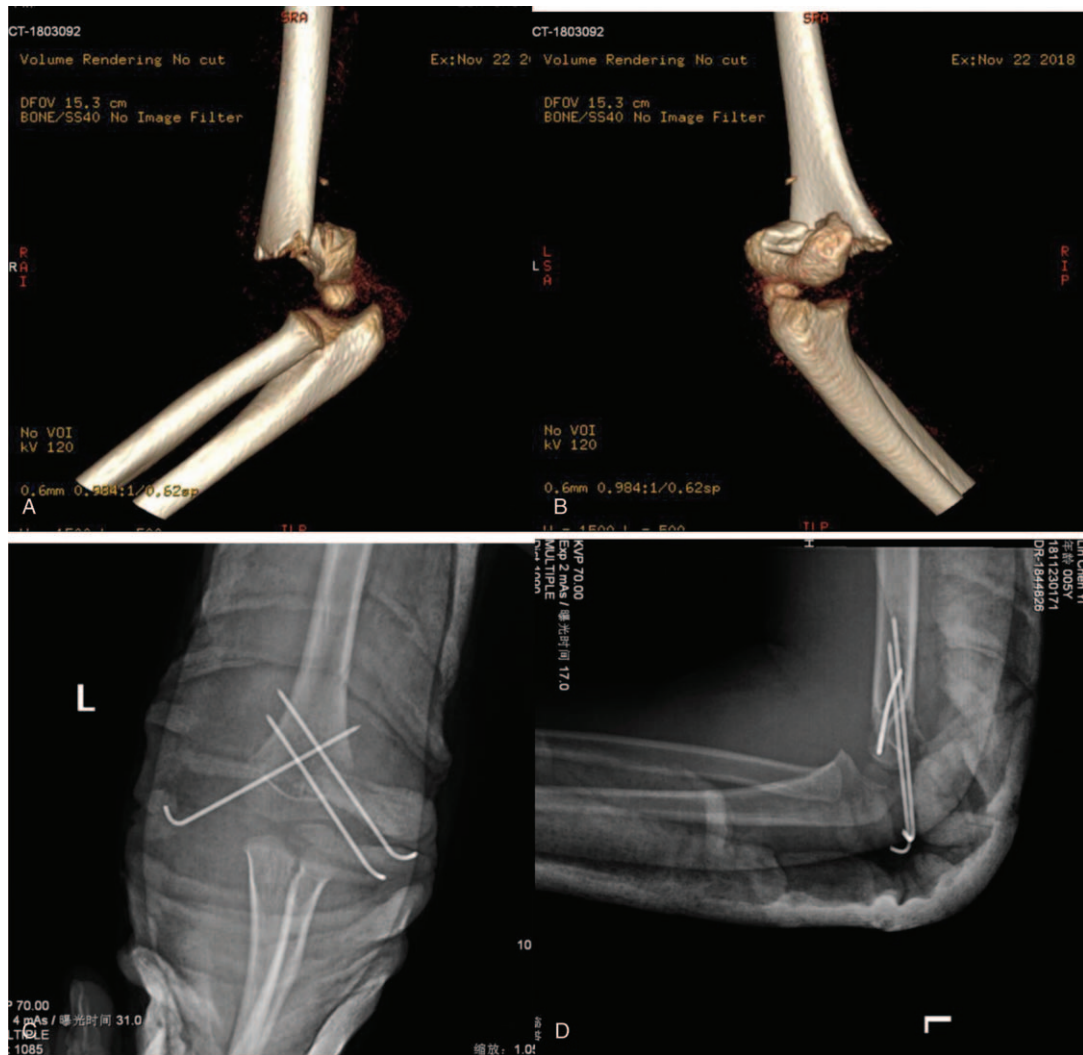
**Clinical data for pediatric patients with Gartland type III supracondylar fractures of the humerus.**

	ExFix group (n=39)	CP group (n=39)	P* value
Age, yrs	6.4±1.9	6.3±2.1	.86
Sex, male:female	26:13	26:13	.79
Affected side, left:right	21:18	21:18	.77
Duration between injury and surgery, d	4.2±1.2	4.3±1.3	.76
Follow-up, mo	14.3±1.9	13.9±1.8	.86
Preoperative neurologic disturbance, number of cases	0	0	.92
Duration of surgery, min	25.28±5.45 (19–35)	37.78±5.95 (31–77)	.007†
Images taken during the operation	17±11 (8–23)	40±9 (20–82)	.006†
Accessory mini incision for reduction, cases	0 (0%)	12 (30.8%)	.005†

Data are shown as mean ± standard deviation (range) or N (%).

\* Chi-squared test for categorical data or Student *t* test for continuous data.

† <.01.

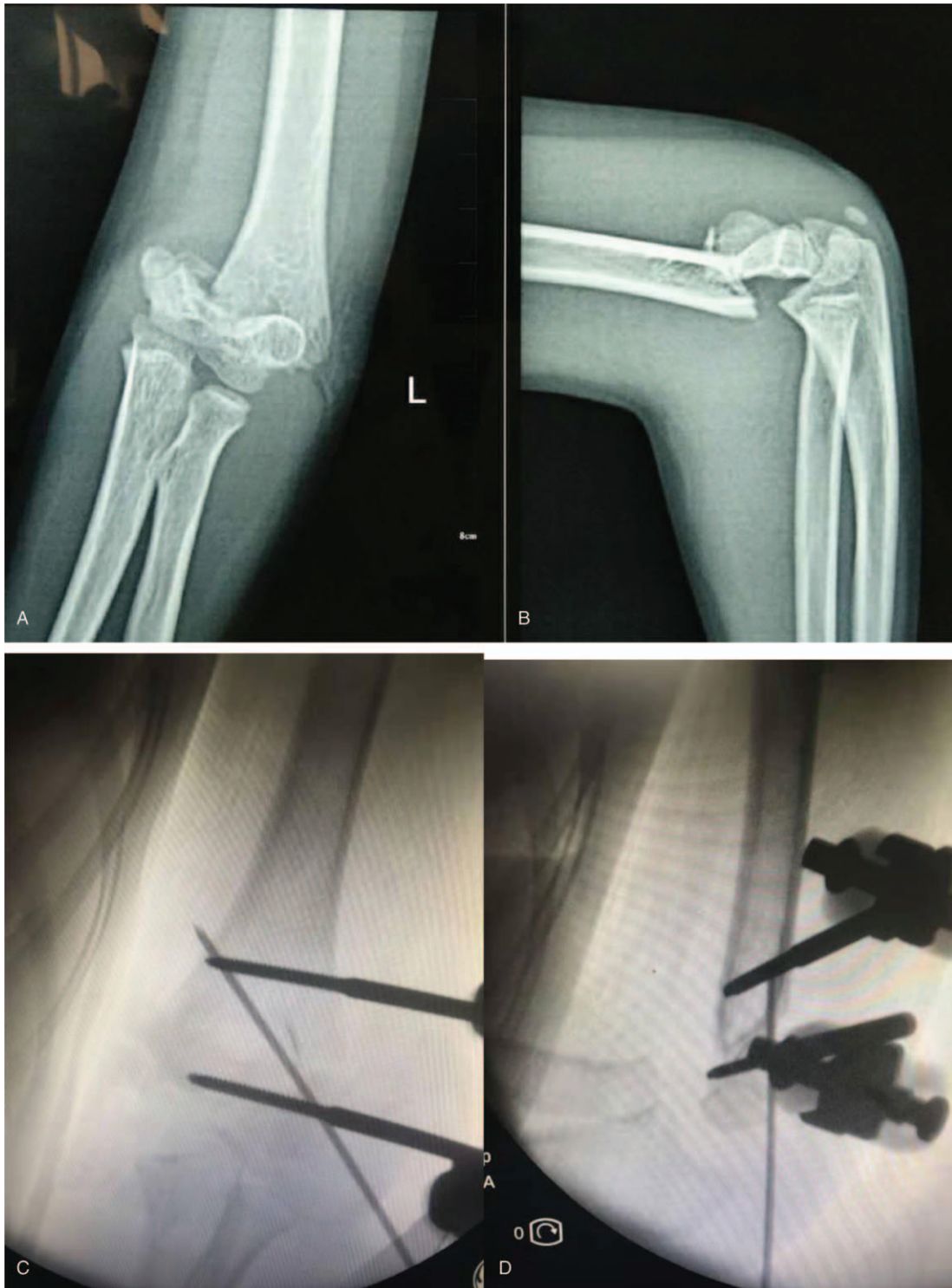

**Figure 2.** Computed tomography (CT) scan and radiograph of supracondylar humeral fracture stabilized by crossed pinning. Supracondylar fractures are diagnosed by the plain films in our department. But sometimes, the CT scan was ordered by the physicians in emergency department. (A) CT reconstruction of Gartland type III supracondylar humeral fracture. (B) CT reconstruction of Gartland type III supracondylar humeral fracture. (C) Anterior-posterior view of crossed pinning of supracondylar humeral fracture. (D) Lateral view of crossed pinning of supracondylar humeral fracture.

Procedures for crossed pinning (Fig. 3) were also performed under fluoroscopy. After an acceptable reduction following manipulation had been achieved, crossed pinning was done with K-wires. If the closed reduction could not be achieved even after several attempts, an accessory mini-incision over the anterior cubital crease or lateral aspect might be necessary for satisfactory reduction.

### 2.3. Postoperative management and evaluation

The patient was discharged in the 1st postoperative day with posterior slab on the operated elbow. The cast was removed after 3 weeks. Oral analgesics were continued until the 1st follow-up visit. The patient's guardians were educated for the regular pin-site dressing to prevent the infection.



**Figure 3.** Radiograph of supracondylar humeral fracture fixed by radial external fixator. (A) Anterior-posterior view of supracondylar fracture. (B) Lateral view of supracondylar fracture. (C) Anterior-posterior view of supracondylar fracture after the operation. (D) Lateral view of supracondylar fracture after the operation.

In each follow-up visit patient was evaluated by radiological and clinical parameters. The radiological parameters included measurement of Baumann angle (BA), the carrying angle (CA), and the progress of union in the anteroposterior and lateral view radiographs. The clinical parameters included range of motion (ROM) and any postoperative complications, such as iatrogenic nerve injury, infection, and cubitus varus. Finally, the patient's outcomes were evaluated cosmetically and functionally according to Flynn criteria,<sup>[7]</sup> and rated as excellent, good, fair, and poor outcome.

#### 2.4. Statistical analysis

The SPSS statistical package program (SPSS 19.0 version; SPSS Inc, Chicago, IL) was used for statistical analysis. The categorical data were analyzed using the Chi-squared test, and the continuous data were analyzed using Student *t* test. Data are presented as mean ± standard deviation (range), median (range), or n (%). *P* < .05 was considered statistically significant.

### 3. Results

As for baseline information or fracture parameters (Table 1), we noted no significant differences between the 2 groups. The duration of operation was significantly shorter in the external fixator group than in the control group (*P* = .007). The number of fluoroscopy images was significantly lower in the external fixator group than in the control group (*P* = .006). The incidence of an accessory mini-incision for reduction in external fixator group was lower than in the crossed pinning group (*P* = .005).

Clinical data on follow-up are presented in Table 2. There existed no significant differences between the 2 groups concerning the healing time and ROM of the elbow joint. The loss of CA and BA was significantly lower in the external fixator group than in the control group (*P* = .009, *P* = .03). There was no cubitus varus in the external fixator group, yet there were 2 cases of mild cubitus varus in crossed pinning group.

Cosmetic and functional outcome evaluations are shown in Table 2. There were no significant differences between ExFix and crossed pinning group in the incidence of excellent and good outcomes (*P* = .68).

There were 4 cases of numbness due to ulnar nerve injury in crossed pinning group, but all neurological deficits resolved 3 to 6 months after the removal of K-wires on the ulnar side. No patients experienced serious postoperative displacement, serious pin tract infection resulting in hardware failure, or neurovascular disturbance.

### 4. Discussion

The most important finding of the present study was that the ExFix method and crossed pinning method can achieve acceptable clinical as well as radiological outcomes in the patients with delayed Gartland type III SHF. However, it is not without complications.

The SHF is common in children, and completely displaced SHF usually require surgical fixation. The optimal surgical technique for management of Gartland type III SHF remains controversial.<sup>[8–10]</sup> Generally speaking, surgical fixation using crossed pinning or divergent lateral pinning is advocated for completely displaced SHFs on emergency basis.<sup>[11]</sup> Adding a medial pin through a minimally invasive approach is associated with longer operative time; however, it limits the risk of secondary displacement without increasing the frequency of iatrogenic nerve injury and improves fracture site stability.<sup>[10]</sup> There were limited reports about the management about the delayed SHFs. Before the introduction of radial external fixator, crossed pinning or sometimes ORIF was adopted in our institute.

Delayed surgery for completely displaced SHF, defined as occurring 72 hours after trauma, is not uncommon in developing countries including China.<sup>[12]</sup> In our institution, most patients were transferred from outside medical facilities with limited treatment. Sometimes, the delay could be more than 5 to 7 days. In this scenario, cast immobilization after closed reduction seems unfeasible. Some authors advocated corrective osteotomy after fracture healing with residual deformity, but it would result in an additional cost for the financially distressed parents. In delayed cases, there is a risk of failure to achieve satisfactory reduction and repeated trials of close reduction might result in a number of postoperative complications. However, several studies still suggested that surgical treatment is a better choice for delayed SHFs.<sup>[13,14]</sup> Therefore, patients who presented <7 days after the injury received surgical intervention in our institute.

**Table 2**  
Radiographic evaluations, ROM, Flynn criteria, and the incidence of cubitus varus deformity.

Parameters	ExFix group (n = 39)	CP group (n = 39)	<i>P</i> value*
BA of the contralateral elbow	69.8 ± 5.2	69.7 ± 4.9	.87
BA of the injured elbow	69.9 ± 3.4	74.1 ± 5.9	.008 <sup>†</sup>
Increase in BA (degrees) of the injured elbow compared with the contralateral elbow	0.9 ± 3.9	5.2 ± 3.8	.009 <sup>†</sup>
CA of the contralateral elbow	15.2 ± 6.7	15.9 ± 4.8	.78
CA of the injured elbow	14.9 ± 2.7	10.9 ± 6.9	.86
Loss of CA of injured elbow compared with the contralateral elbow	1.5 ± 2.7	4.8 ± 4.6	.03 <sup>‡</sup>
ROM of the contralateral elbow	147.7 ± 7.3	147.2 ± 4.9	.75
ROM of the injured elbow	147.2 ± 7.9	143.6 ± 6.9	.65
Flynn criteria, incidence of excellent, and good results	100%	94.9%	.68
Cases of cubitus varus	0 (0%)	2 (5.1%)	.48

Data are shown as mean ± standard deviation (range) or N (%).

BA = Baumann angle, CA = carrying angle, CP = crossed pinning, ExFix = external fixator, ROM = range of motion.

\* Chi-squared test for categorical data or Student *t* test for continuous data.

<sup>†</sup> < .01.

<sup>‡</sup> < .05.

How to achieve a successful reduction without multiple trials represents a challenge for orthopedic surgeons. In fresh cases, CRPP requires no incision, provides less infection risk and even sometimes less operating time. In delayed cases, the closed reduction might not be easily obtained. ORIF is indicated if the surgeon fails to achieve satisfactory reduction following 1 or 2 attempts of closed reduction.<sup>[15]</sup> Previous studies reported that the ORIF following SHFs was associated with a high rate of postoperative complications. But recent studies regarding the open reduction with medial incision or mini-anterior incision have reported a low rate of postoperative complications.<sup>[14,16]</sup> However, closed reduction is still our preferred method.

The CRPP in displaced SHFs is usually challenging, and its disadvantages include iatrogenic nerve injuries, increased radiation exposure, and inability to visualize the quality of reduction directly, demanding more experience.<sup>[17,18]</sup> In delayed cases of severely displaced SHFs, the presence of massive edema and soft-tissue swelling make the CRPP even harder. Repeated and aggressive reduction manipulations may lead to myositis ossificans, joint stiffness, and neurapraxia.<sup>[19]</sup> Although many studies have been reported, more than half of orthopedic surgeons have not changed their approaches to the management of Gartland type III SHFs, particularly with regard to the method of fixation.<sup>[20]</sup>

In delayed fractures, surgery seems a better choice, and closed reduction with external fixator technique could be easily obtained in our practice. To the authors' knowledge, this is the 1st study that compared the clinical effects of surgical intervention on the delayed Gartland type III SHFs in children using radial external fixator or crossed pinning. The manual reduction process is similar in both groups, but the large diameter of Schanz screw in the ExFix group facilitates the reduction process using "joystick technique." Therefore, in our study, shorter surgery duration and a reduced number of fluoroscopy images were recorded in the ExFix group. The external fixator demands a shorter learning curve and displays decreased occurrence of repeated manipulations and switch to open approaches, consistent with the report by Slongo.<sup>[6]</sup> However, all patients displayed excellent and good functional results at follow-up regardless of the fixation technique possibly because of the good intraoperative reduction and early mobilization after cast removal.

There were several limitations in this study. Firstly, the sample size was small. Secondly, other fixation techniques such as open reduction with absorbable rods or divergent lateral pinning were not included in this study. Thirdly, the number of X-ray exposures was recorded, yet the actual irradiation dosage could not be meticulously measured and recorded. Fourthly, the follow-up time was short.

## 5. Conclusion

In this study, both external fixator and crossed pinning are safe and effective methods for treatment of type III SHFs. But external fixator is a better choice in the delayed cases because of its "joystick" technique and stronger purchase to the bone. In summary, delayed SHFs in children remain a challenge in clinical practice.

## Author contributions

**Conceptualization:** Pan Hong.

**Data curation:** Pan Hong.

**Formal analysis:** Xin Tang, Ruikang Liu.

**Investigation:** Pan Hong.

**Methodology:** Saroj Rai, Pan Hong.

**Project administration:** Pan Hong.

**Software:** Xin Tang, Ruikang Liu.

**Supervision:** Jin Li.

**Validation:** Xin Tang.

**Writing – original draft:** Pan Hong.

**Writing – review & editing:** Jin Li, Saroj Rai, Renhao Ze.

Pan Hong orcid: 0000-0003-2674-3016.

## References

- [1] de Neira JZ, Prada-Canizares A, Marti-Circuelos R. Supracondylar humeral fractures in children: current concepts for management and prognosis. *Int Orthop* 2015;39:2287–96.
- [2] Howard A, Mulpuri K, Abel MF, et al. The treatment of pediatric supracondylar humerus fractures. *J Am Acad Orthop Surg* 2012;20:320–7.
- [3] Dekker AE, Krijnen P, Schipper IB. Results of crossed versus lateral entry K-wire fixation of displaced pediatric supracondylar humeral fractures: a systematic review and meta-analysis. *Injury* 2016;47:2391–8.
- [4] Slobogean BL, Jackman H, Tennant S, et al. Iatrogenic ulnar nerve injury after the surgical treatment of displaced supracondylar fractures of the humerus: number needed to harm, a systematic review. *J Pediatr Orthop* 2010;30:430–6.
- [5] Gris M, Van Nieuwenhove O, Gehanne C, et al. Treatment of supracondylar humeral fractures in children using external fixation. *Orthopedics* 2004;27:1146–50.
- [6] Slongo T. Radial external fixator for closed treatment of type III and IV supracondylar humerus fractures in children. A new surgical technique. *Oper Orthop Traumatol* 2014;26:75–97.
- [7] Flynn JC, Matthews JG, Benoit RL. Blind pinning of displaced supracondylar fractures of the humerus in children. Sixteen years' experience with long-term follow-up. *J Bone Joint Surg Am* 1974;56:263–72.
- [8] Hohloch L, Konstantinidis L, Wagner FC, et al. Biomechanical comparison of different external fixator configurations for stabilization of supracondylar humerus fractures in children. *Clin Biomech* 2016;32:118–23.
- [9] Kocher MS, Kasser JR, Waters PM, et al. Lateral entry compared with medial and lateral entry pin fixation for completely displaced supracondylar humeral fractures in children. A randomized clinical trial. *J Bone Joint Surg Am* 2007;89:706–12.
- [10] Pesenti S, Ecalle A, Gaubert L, et al. Operative management of supracondylar humeral fractures in children: comparison of five fixation methods. *Orthop Traumatol Surg Res* 2017;103:771–5.
- [11] Lee S, Park MS, Chung CY, et al. Consensus and different perspectives on treatment of supracondylar fractures of the humerus in children. *Clin Orthop Surg* 2012;4:91–7.
- [12] Yaokreh JB, Odehouri-Koudou TH, Tembely S, et al. Delayed treatment of supracondylar elbow fractures in children. *Orthop Traumatol Surg Res* 2012;98:808–12.
- [13] Tiwari A, Kanojia RK, Kapoor SK. Surgical management for late presentation of supracondylar femoral fracture in children. *J Orthop Surg (Hong Kong)* 2007;15:177–82.
- [14] Tomori Y, Nanno M, Takai S. Clinical results of closed versus mini-open reduction with percutaneous pinning for supracondylar fractures of the humerus in children. *Medicine (Baltimore)* 2018;97:e13162.
- [15] Terry C, Beaty J. *Campbell's Operative Orthopaedics*, 12th ed. Elsevier. Jan 2013:1408-1409.
- [16] Kumar R, Malhotra R. Medial approach for operative treatment of the widely displaced supracondylar fractures of the humerus in children. *J Orthop Surg (Hong Kong)* 2000;8:13–8.
- [17] Prashant K, Lakhota D, Bhattacharyya TD, et al. A comparative study of two percutaneous pinning techniques (lateral vs medial-lateral) for Gartland type III pediatric supracondylar fracture of the humerus. *J Orthopaed Traumatol* 2016;17:223–9.
- [18] Padman M, Warwick AM, Fernandes JA, et al. Closed reduction and stabilization of supracondylar fractures of the humerus in children: the crucial factor of surgical experience. *J Pediatr Orthop B* 2010;19:298–303.
- [19] Pretell-Mazzini J, Rodriguez-Martin J, Andres-Esteban EM. Does open reduction and pinning affect outcome in severely displaced supracondylar humeral fractures in children? A systematic review. *Strategies Trauma Limb Reconstr* 2010;5:57–64.
- [20] Carter CT, Bertrand SL, Cearley DM. Management of pediatric type III supracondylar humerus fractures in the United States: results of a national survey of pediatric orthopaedic surgeons. *J Pediatr Orthop* 2013;33:750–4.