

CASE REPORT



## Metastasis to the pancreas and stomach from a breast cancer primary: a case report

Jason Kliiger<sup>a</sup> and Mayer Gorbaty<sup>b</sup>

<sup>a</sup>Saba University School of Medicine, Airdrie, Canada; <sup>b</sup>Medical Oncology, Northwest Hospital, Randallstown, MD, USA

### ABSTRACT

A 60-year-old female with an unknown family history initially presented with signs and symptoms concerning for gastrointestinal cancer. Regular breast cancer screening and subsequent work-up around this time demonstrated the presence of T2N1 stage II triple positive ductal adenocarcinoma of the left breast. Follow-up imaging for her gastrointestinal symptoms demonstrated a 3.5 cm solitary mass in the pancreas and diffuse thickening of the stomach wall. Biopsies of the gastrointestinal lesions were identified as metastatic foci of the breast cancer primary. Breast cancer metastases to the stomach and to the pancreas are both very rare events. Of the breast cancer primaries that do metastasize to the gastrointestinal system, it is unusual for the primary to be ductal adenocarcinoma. The rapid succession of diagnosing the primary source of breast cancer simultaneously with its metastases is also unusual. Timely identification and appropriate management of these rare metastases was made possible due to routine breast cancer screening.

### ARTICLE HISTORY

Received 2 May 2017  
Accepted 7 August 2017

### KEYWORDS

Breast cancer; metastasis; cancer screening; invasive ductal carcinoma; gastrointestinal cancer

### 1. Case description

A 60-year-old post-menopausal female presented to her primary care provider for intractable nausea, diarrhea, vomiting, and unintentional weight loss of 25lb over 2 months. She had a history of poorly controlled type II diabetes mellitus with peripheral neuropathy, and previous cholecystectomy. The patient was adopted, and thus her family history was unknown. Her physical exam was unremarkable. Her primary care provider referred her to a gastroenterologist for an endoscopy due to her clinical picture and a screening mammogram due to never having received one before.

Screening mammography performed six weeks after her initial encounter showed an oval mass in the upper outer quadrant and focal asymmetry with architectural disturbances in the anterior third of the left breast. Subsequent diagnostic mammography was concerning for breast cancer and biopsies of the mass and suspicious lymph nodes were performed. Her pathology demonstrated the lesion to be grade 2 ER positive (90%), PR positive (2%), HER2/neu positive invasive ductal adenocarcinoma with a Ki67 of 20% (Figure 1). Due to the size of the oval mass and the presence of cancerous cells on lymph node biopsy, her initial stage was T2N1 stage II triple positive adenocarcinoma of the left breast.

A week later, an abdominal ultrasound demonstrated a dilated common bile duct of 14mm without obvious stones. Further work-up included an MRI of her abdomen, which demonstrated liver enlargement

and a 3.5cm mass in the uncinate process of her pancreas, and diffuse thickening of the stomach wall (Figure 2). The MRI also demonstrated enhancing vertebral lesions concerning for metastatic disease. Esophagogastroduodenoscopy was performed, visualizing the lesion in the stomach wall (Figure 3). To determine if the gastrointestinal lesions represented another primary cancer, biopsies of the lesions in the stomach and pancreas were taken. The lesion biopsies were demonstrated to be metastatic breast adenocarcinoma due to immunohistochemical staining positive for estrogen receptors, E-cadherin, and GATA3 (Figure 4).

The patient was ultimately diagnosed as having stage IV triple positive invasive ductal adenocarcinoma of the breast. Once the diagnosis was confirmed, systemic therapy was initiated with docetaxel, pertuzumab, and trastuzumab.

### 2. Discussion

Metastasis to the pancreas is a rare event, but when present the primary lesion is typically renal cell carcinoma, non-small cell lung cancer, colon cancer, or much more rarely, breast cancer [1,2]. Breast cancer accounts for less than 5% of metastatic pancreatic masses [3,4]. Metastasis to the stomach originating from a breast cancer primary is another rare event, but this type of metastatic spread has been observed in 0.3–18% of cases [5]. Typically, invasive lobular

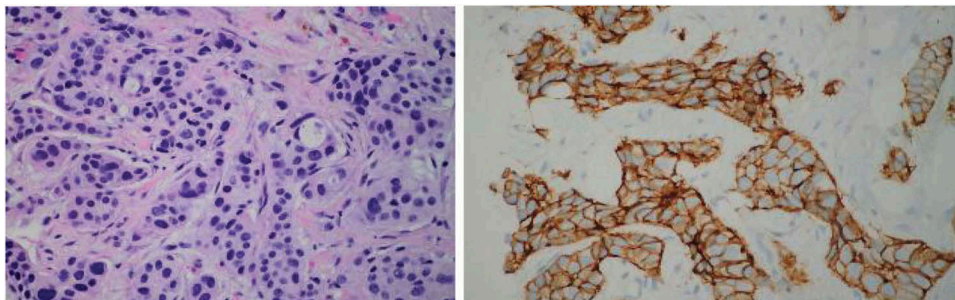


Figure 1. Left: H&E stain of left breast biopsy. Right: Left breast mass biopsy staining for Her2.

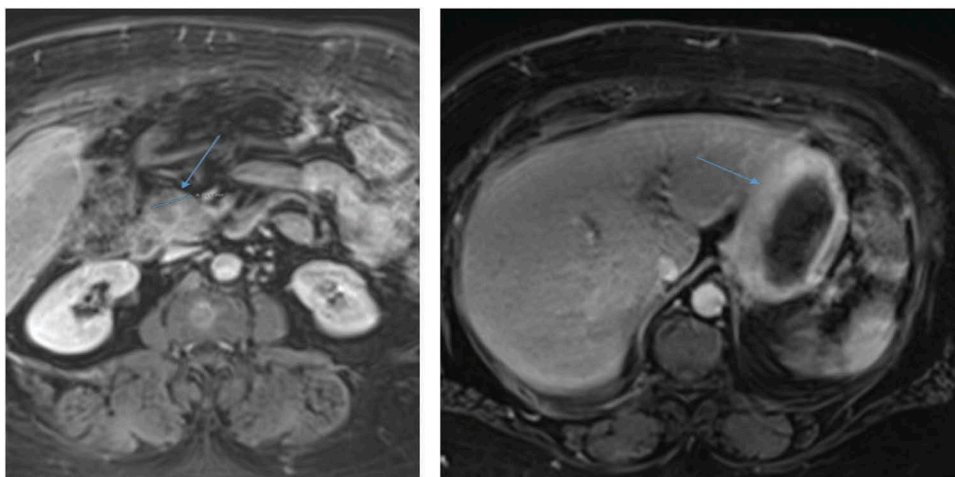


Figure 2. Left: MRI image of solitary 3.5cm mass in uncinus process of pancreas (arrow). Right: MRI image of diffusely thickened stomach wall (arrow).

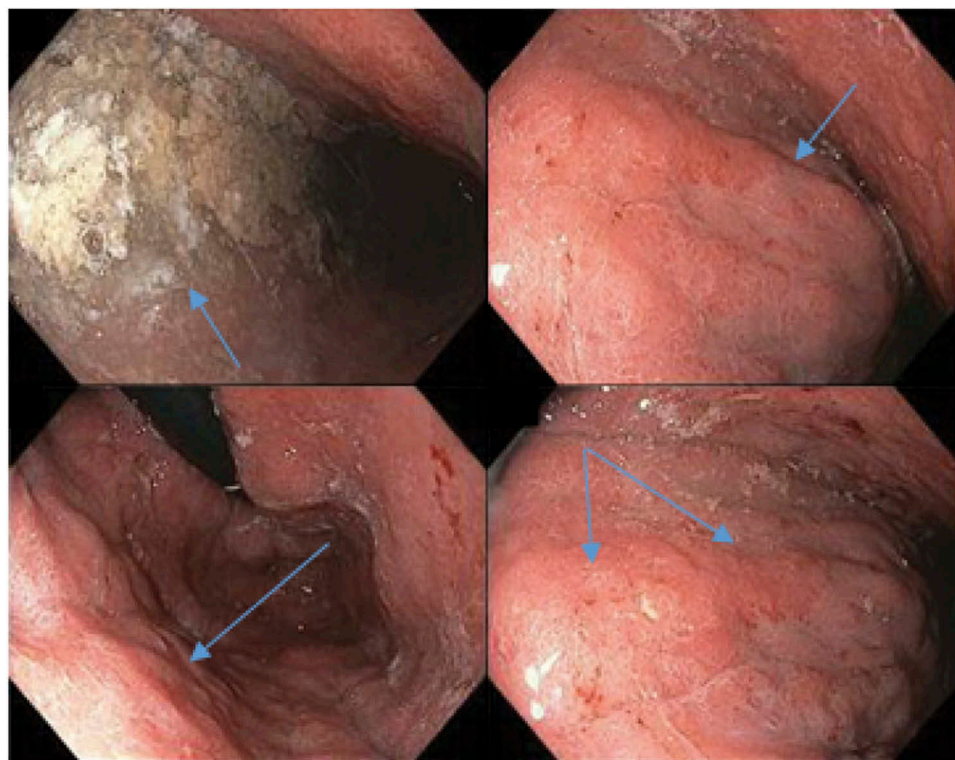
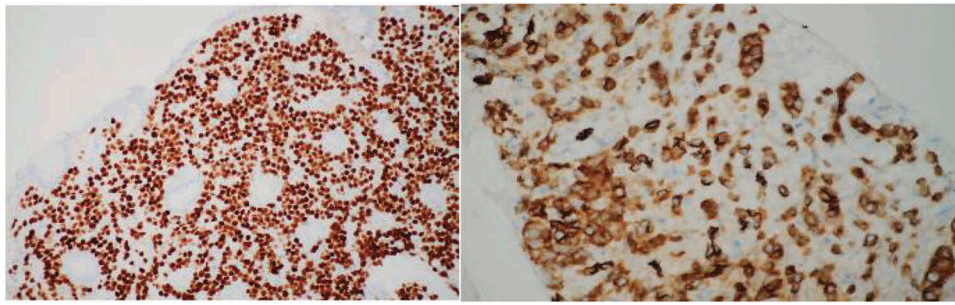


Figure 3. EGD visualizing abnormal lesions in stomach demonstrating areas concerning for malignancy (arrows).



**Figure 4.** Left: stomach lesion biopsy staining for GATA3. Right: pancreatic lesion biopsy staining for E-Cadherin.

breast carcinoma is the breast cancer type that most likely metastasizes to the gastrointestinal tract [6–9]. In this case, the patient had metastatic ductal carcinoma, which is unusual as it typically exhibits solitary metastases and is far less likely to metastasize to the gastrointestinal tract in a diffuse pattern [8–10]. Documented case reports of metastases to the stomach or to the pancreas have been cited; however, an invasive ductal adenocarcinoma of the breast with simultaneous metastases to both the pancreas and stomach have not been reported.

The patient's family history was unknown, but she had late age of menopause at 57 years old. Her chief complaint and clinical picture on her first visit to her primary care physician was suggestive of a gastrointestinal cancer. At the time of her visit to her primary care provider, there was no suspicion whatsoever of the presence of breast cancer. The primary care provider opted to have a screening mammography done because she was long overdue according to both the ACS and USPSTF screening guidelines [11,12]. The timing of her screening mammography suited the circumstances because her breast mass biopsies helped guide the work-up for her gastrointestinal masses. Her synchronous diagnosis of both the primary breast cancer and its metastases to both pancreas and stomach is very rare, and unfortunately also portends a poor prognosis [13–15]. The physician's adherence to screening guidelines was the reason the primary was found when it was, and ultimately helped guide gastrointestinal work-up.

Invasive breast cancer has a 5-year survival rate that is roughly 90% [16]. This is a better prognosis compared to the average 5-year survival rates of primary gastric and pancreatic adenocarcinomas, which stand at 31% and 8% respectively [16]. Once there are distant metastases, typical invasive ductal adenocarcinoma of the breast becomes largely incurable and 5-year survivability drops by more than half to roughly 25% [17]. However, the few patients with invasive ductal adenocarcinoma that have metastasized to the pancreas had a survivability that ranged between 1 and 50 months [13]. Survivability of breast cancer that had metastasized to the stomach also ranged between 4 and 41 months [18]. These distinctions are important because an understanding of the prognosis

based on the rate and pattern of metastatic spread can help guide a clinician's decisions on treatment, communication of expected outcomes, and if palliative care may be warranted. It is also important that an accurate diagnosis of the primary is made as swiftly as possible, because management is vastly different between a pancreatic primary, a gastric primary, and a breast primary. A delay in initiation of effective therapy for invasive ductal adenocarcinoma of the breast because of a clinical presentation that mimics a gastrointestinal primary can lessen the likelihood of a favorable outcome.

While it is more than likely the origin of the metastatic lesions would have been ascertained eventually, the information garnered by screening mammography undoubtedly hastened the process. Knowledge of a T2N1 ductal adenocarcinoma being present at the time of the gastrointestinal biopsies prompted immunohistochemical staining that could rule out their new founded suspicion of breast cancer metastasis. GATA3 immunohistochemical staining was one such test, which is present in breast cancer and lacking in primary cancers of the pancreas and stomach [19]. Prompt identification of the nature and origin of the lesions led to the swift initiation of appropriate systemic therapy. However, despite appropriate systemic therapy, the median survival for breast cancers presenting similarly to this patient ranged from 18 to 24 months, and only 5–10% lived more than 5 years past initial diagnosis [15].

When it comes to treatment of breast cancer metastatic to the pancreas and stomach, the goal of treatment is to prolong survival and improve the patient's overall quality of life [13]. Surgical resection of metastatic tumors in the stomach have been documented, with no real effect on overall survival [6,10]. However, there is some controversy regarding surgical resection of pancreatic metastasis. There are reports that surgical resection of an isolated metastatic tumour of the pancreas can improve survivability and should be first-choice treatment, whereas other authors favor initial systemic therapy due to the significant morbidity and mortality associated with pancreaticoduodenectomy [4,13]. In both cases, surgical resection of the metastasis can be a useful means to palliate symptoms and improve quality of life [17].



Regardless of the site of metastasis, initial systemic therapy is the recommended standard of care for stage IV breast cancer [17]. Dual blockade of HER2/neu receptors in combination with chemotherapy has been shown to provide substantial survival benefit, hence the initiation of pertuzumab, trastuzumab, and docetaxel in this patient [17]. Hormonal therapy is also recommended in the management of ER positive tumours, and was eventually added to the patient's treatment regimen [17]. Targeted therapy against HER2/neu receptors has shown a large improvement in triple positive breast cancer survival, and could easily have been delayed in this case had she not received a screening mammography when she did [17]. Systemic therapy for pancreatic and gastric primaries are drastically different. For a pancreatic primary, first line systemic therapy is either Gemcitabine monotherapy, FOLFIRINOX combination therapy, or Gemcitabine plus Nab-Paclitaxel depending on the tumour status and patient's performance status [20]. A gastric primary is initially treated with surgical resection if the patient is a candidate, coupled with adjuvant chemo-radiation or chemotherapy [21]. If the patient is not a surgical candidate, then palliative chemotherapy with epirubicin, oxaliplatin, and capecitabine, plus or minus trastuzumab, is recommended [21].

In conclusion, this case demonstrates the very rare event of simultaneous metastasis of invasive ductal adenocarcinoma of the breast to both the pancreas and stomach. The case is an excellent educational example of how prognosis of metastatic breast cancer can vary dramatically depending on the pattern and rate of metastasis. This case also illustrates the importance of vigilant adherence to cancer screening recommendations, especially in patients who present with symptoms suggestive of an underlying malignancy. Overall, this case demonstrates how an open mind toward the origin of a finding of cancer, and adherence to screening guidelines can help a clinician arrive at an accurate diagnosis, and thus provide appropriate care, even in the face of a very misleading clinical presentation.

## Acknowledgments

Special thanks to Dr. David Weisman for writing assistance, and to Dr. Christian Hansen for providing pathology slides and writing assistance

## Disclosure statement

No potential conflict of interest was reported by the authors.

## References

- [1] Bednar F, Scheiman JM, McKenna BJ, et al. Breast cancer metastases to the pancreas. *J Gastrointest Surg*. 2013;17:1826–1831.
- [2] Tunio MA, Fatani H, Riaz K, et al. Pancreatic metastasis of breast cancer: a rare cause of obstructive jaundice. *J Dow Uni Health Sci*. 2015;9(1):39–40.
- [3] Alzahrani MA, Schmulewitz N, Grewal S, et al. Metastasis to the pancreas: the experience of a high volume center and a review of the literature. *J Surg Oncol*. 2011;105(2):156–161.
- [4] Bonapasta A, Gregori M, Lanza R, et al. Metastasis to the pancreas from breast cancer: difficulties in diagnosis and controversies in treatment. *Breast Care*. 2010;5:170–173.
- [5] Yamamoto D, Yoshido H, Sumida K, et al. Gastric tumor from metastasis of breast cancer. *Anticancer Res*. 2010;30:3705–3708.
- [6] Almubarak MM, Lae M, Cacheux W, et al. Gastric metastasis of breast cancer: a single centre retrospective study. *Dig Liver Dis*. 2011;43(10):823–827.
- [7] Taal BG, Den Hartog Jager FCA, Steinmetz R, et al. The spectrum of gastrointestinal metastases of breast carcinoma: I. Stomach. *Gastrointest Endosc*. 1992;38(2):130–135.
- [8] Jones GE, Strauss DC, Forshaw MJ, et al. Breast cancer metastasis to the stomach may mimic primary gastric cancer: report of two cases and review of literature. *World J Surg Oncol*. 2007;5:75.
- [9] Nomizu T, Katagata N, Matsuoka T, et al. A case of breast cancer metastatic to the head of the pancreas. *Breast Cancer*. 1999;6:131.
- [10] McLemore EC, Pockaj BA, Reynolds C, et al. Breast cancer: presentation and intervention in women with gastrointestinal metastasis and carcinomatosis. *Ann Surg Oncol*. 2005;12(11):886–894.
- [11] Siu AL. U.S. preventive services task force. screening for breast cancer: U.S. preventive services task force recommendation statement. *Ann Intern Med*. 2016;164(4):279–296.
- [12] Oeffinger KC, Fontham ET, Etzioni R, et al. Breast cancer screening for women at average risk: 2015 guideline update from the American Cancer Society. *J Am Med Assoc*. 2015;314(15):1599–1614.
- [13] Molino C, Mocerino C, Braucci A, et al. Pancreatic solitary and synchronous metastasis from breast cancer: a case report and systemic review of controversies in diagnosis and treatment. *World J Surg Oncol*. 2014;12:2.
- [14] Ochoa AP, Hernaez FS, Fernandez CC, et al. Pancreatic metastases from ductal and lobular carcinomas of the breast. *Clin Transl Oncol*. 2007;9(9):603–605.
- [15] Showalter SL, Hager E, Yeo CJ. Metastatic disease to the pancreas and spleen. *Semin Oncol*. 2008;35(2):160–171.
- [16] American Cancer Society. *Cancer Facts & Figures 2017*. Atlanta (GA): American Cancer Society; 2017.
- [17] Cardoso F, Costa A, Senkus E, et al. 3rd ESO-ESMO International consensus guidelines for advanced breast cancer (ABC 3). *Ann Oncol*. 2017;28:16–33.
- [18] Ambroggi M, Stroppa EM, Mordenti P, et al. Metastatic breast cancer to the gastrointestinal tract: report of five cases and review of the literature. *Int J Breast Cancer*. 2012;2012:8. 4339023.
- [19] Ordóñez NG. Value of GATA3 immunostaining in tumor diagnosis: a review. *Adv Anat Pathol*. 2013;20(5):352–360.
- [20] Thota R, Pauff JM, Berlin JD. Treatment of metastatic pancreatic adenocarcinoma: a review. *Oncol*. 2014;28(1):70–74.
- [21] Waddell T, Verheij M, Allum W, et al. Gastric cancer: ESMO-ESSO-ESTRO clinical practice guidelines for diagnosis, treatment and follow-up. *Eur J Surg Oncol*. 2014;40:584–591.